

Three-Dimensional Color Doppler Ultrasonography Study of Normal Liver Vascular Pattern in Dog

Mohammad Molazem¹ DVM

Alireza Vajhi*¹ DVSc

Sarang Soroori¹ DVSc

Abbas Veshkini¹ Ph.D

Majid Masoudifard¹ DVSc

Sepehr Pedram² DVM

¹Department of clinical Sciences, Faculty of Veterinary Medicine,
Tehran University, Tehran, Iran

²Department of Surgery, Faculty of Medicine, University of Shahed, Tehran, Iran

Abstract

Objective- To create three-dimensional model of the dog's liver vessels by using three-dimensional color Doppler ultrasonography which can be used for surgery planning, tumor detecting, transplantation, and other diagnostic or treatment project.

Design- Descriptive study

Animals- 6 mixed breed dog, 1.6-1.7 years old, 18-20 kg weight

Procedures- The liver was found by two-dimensional scan initially then three-dimensional power and color Doppler scans were taken. Image acquisition was performed with reconstruction and simultaneous display of sectional anatomy in three orthogonal planes or any arbitrary oblique plane and also a 360 degree rotating 3D plane. Images were evaluated for gross anatomical visualizations and characters of the portal vein, caudal vena cava, hepatic vein and artery, and aorta in 10 standard planes.

Results- Three-dimensional ultrasound scans of the liver corresponding to the sagittal and transverse planes were found to be possible in 6 planes in dorsal recumbency.

Conclusion and Clinical Relevance- Three-dimensional color Doppler ultrasonography was used for dog liver and seems to have the potential to provide greater detail of the vascularity associated with abnormal lesion.

Key Words- three-dimensional ultrasonography, color Doppler, liver, dog

* Corresponding author:

Alireza Vajhi, DVSc

Department of clinical Sciences, Faculty of Veterinary Medicine, Tehran University, Tehran, Iran

E-mail address: avajhi@ut.ac.ir

Introduction

Resection or ablation of tumors is one of the treatments available for liver cancer sufferers. This delicate operation consists of removing the tumor(s) and surrounding healthy tissues. The surgery is complicated by the fact that major blood vessels are present in the liver: the surgeon must proceed cautiously. Ultrasonography is used not only to diagnose the presence of tumors in the liver but also to assess whether the patient is suitable for surgery or not. The surgeon needs to find the number of tumors, their size and the physical and spatial relationship between the tumors and the main blood vessels.¹ Extracting this information from the two-dimensional ultrasonography is a time-consuming procedure, which requires manual contouring of the tumor and the main vessels and is complicated by the low special consideration of this technique. The liver is the largest solid organ in the body located in the most cranial portion of the abdomen most of the times protected by the rib cage. 75% of the blood supply to the liver comes from the hepatic portal vein (PV) and 25% from the hepatic artery.² Blood drains into the hepatic vein (HV) and pour into caudal vena cava (CVC) ultimately. The liver is schematically divided into eight independent segments, which have their own vascular inflow, outflow and biliary drainage.³ Each segment can be resected without damaging the others. A liver resection is a complex procedure and care must be taken next to the important liver blood vessels. The aim of this project was to create three-dimensional (3D) model of the dog's liver vessels by using 3D color Doppler ultrasonography which can be used for surgery planning. As each patient is different, 3D color and power Doppler ultrasonography will be an essential imaging tool to "map" the patient's liver and plan the surgery.

Materials and Methods

A total of 6 clinically and hematologically healthy 1.6-1.7 years old, mixed breed, shallow chest dogs (18-20 kg weight) were selected. The dogs got fasted for 12 hours prior to the starting of the study to avoid interference from overlying bowel gas. Plain lateral and venterodorsal radiography were taken initially to confirm normal size of the livers. A protocol was established for the ultrasonographic examination of the liver in the dog. The animal was placed in dorsal recumbency with the bed tilted 30 degrees to the horizon. All the abdominal hair was clipped ventral to the sublumbar muscle and over the last three intercostals spaces. The skin was prepared by cleaning and plenty of acoustic gel. All the cases were put into deep anesthesia by using Acepromazine (0.1 mg/kg, IM), Ketamin (10 mg/kg, IM), Atropine sulfate (0.01 mg/kg, SC), Sodium thiopental (5 mg/kg, IV), and then attached to respiratory ventilator apparatus to avoid respiratory motion by artificial apnea during 3D color Doppler ultrasound (3DCDUS) scanning. For better visualization of the liver the stomach was filled with 10 mg/kg degassed distilled water initially.⁴ The liver was found by 2D scan initially by 3D curve array 3-7 MHz transducers of a GE Voluson 730-Pro ultrasonography machine (GE Kretz, Zipf, Austria) and then after optimizing 2D, color, and power images, 3D power and color Doppler scans were taken. Image acquisition was performed as a volume of data with nearly immediate reconstruction and simultaneous display of sectional anatomy in three orthogonal planes (sagittal plane, transverse, and coronal plane) or any arbitrary oblique plane and also finally a 360 degree rotating 3D plane. Images were evaluated for gross anatomical visualizations and characters of the portal vein, caudal vena cava, hepatic vein and artery, and AO in 10 standard planes.⁵

Results

In 2D ultrasonography the echogenicity and size of the livers were all normal. Using 10 ml/kg degassed water was found to enhance the liver investigation. By using the curve array 3D transducer the following adjustments were almost optimal in all cases:

- In 2D: Harmonic: Low, Focus Number: 1, Focus Depth: 1 cm, Beta View: 0 degree, Power: 2, Gain: 3, Quality: Normal, Line filter: off, Enhance: 1, Dynamic control: 7, Persistence filter: 3, Reject: 5, OTI: normal.
- In color: Quality: high, Gain: 0.2, Frequency: high, Wall Motion Filter: Low 2, PRF: 0.9, Line filter: 2, Baseline: 1, Ensemble: 15, Line density: 5, Smoothing rise: 3, Smoothing fall: 9, Dynamic set: 4, Balance: 115.
- In 3D: Visualization: 3D rendering, 3D CFM program: Glass body, Quality: max, Volume angel: 75.

The best 3D ultrasound scans of the liver corresponding to the sagittal and transverse planes were found to be in 6 planes in dorsal recumbency and are introduced as follow:

Plane-1: Beta view angle based on “Right longitudinal” section in dorsal recumbency as a starting point; the transducer was placed immediately caudal to the last right rib (Beta view 0 degree) longitudinally via the vertebrae while the right kidney with the caudate liver lobe was imaged first. Sometimes the PV could be imaged at the hilus of the liver too. Imaging the PV using this approach was rather difficult and its entire visualization was impossible. This plane was suitable to observe right PV and HV (fig. 1,2).

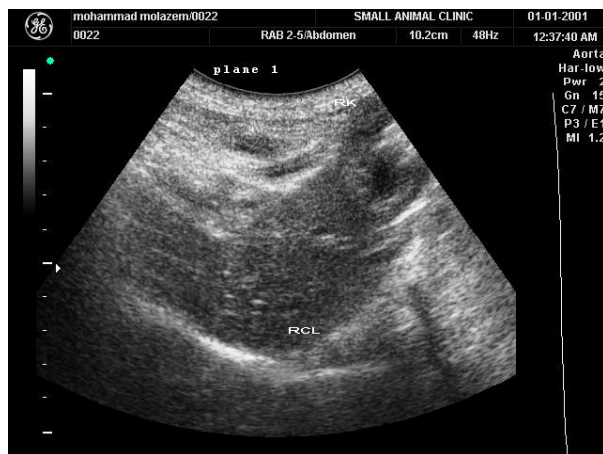

Fig. 1: plane 1, 2D image of the dog's liver. RK: right kidney; RCL: right caudal lobe of the liver.

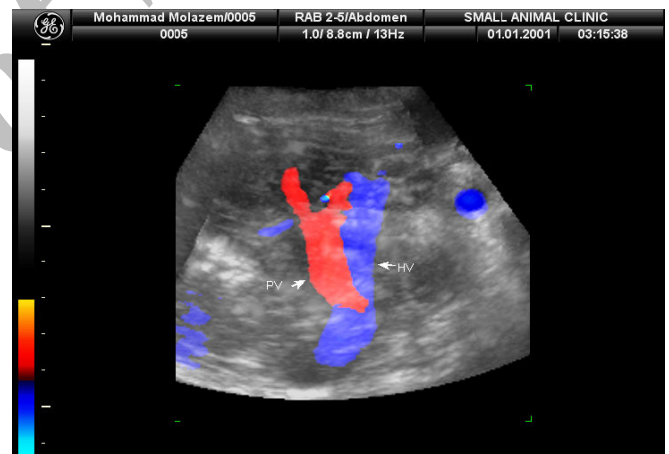


Fig. 2: plane 1, 3D color Doppler image of the dog's liver. To observe right portal (PV) and hepatic veins (HV).

Plane-2: Beta view angle based on “Longitudinal” sections align with the vertebrae in dorsal recumbency; the transducer was placed immediately caudal to xyphoid and slightly tilted toward right side (Beta view 0 degree) until the gall bladder could be seen in its longest length. This plane was best for investigating PV, CVC, and aorta (AO). Firm transducer-pressure was often necessary to image the portal bifurcation (fig 3, 4).

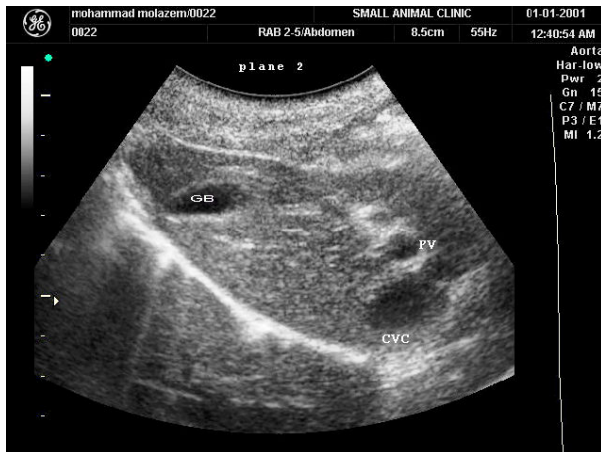

Fig. 3: plane 2, 2D image of the dog's liver. GB: gall bladder, CVC: caudal vena cava, PV: portal vein.

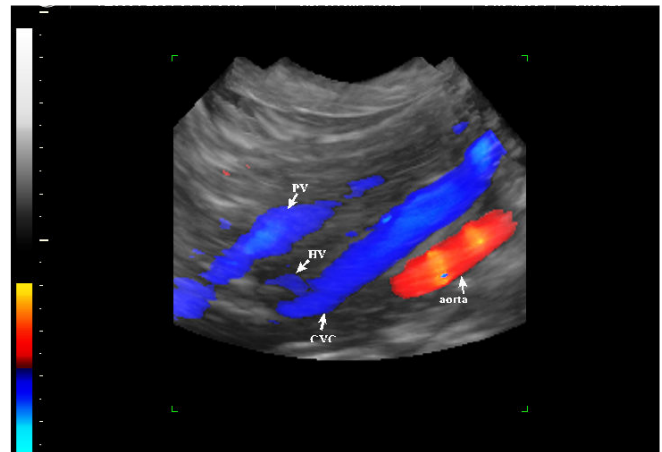


Fig. 4: plane 2, 3D color Doppler image of the dog's liver. This plane was best for investigating portal vein (PV), caudal vena cava (CVC) and aorta; HV: hepatic vein.

Plane-3: Beta view angle based on “Left longitudinal” section in dorsal recumbency to image the left divisions of PV and HV; images of the main left portal branches and left HV were obtained with a transducer placed immediately caudal to the last left rib and directed craniomedially while the cranial part of the spleen could be seen in contact with left lateral liver lobe. To find the PV here, first longitudinal image of the AO was obtained immediately ventral to the vertebrae. By ventral angulation of the transducer, the CVC became visible. Further ventral angulation resulted in the longitudinal image of the PV at the point where the splenic vein entered the PV (fig. 5, 6).

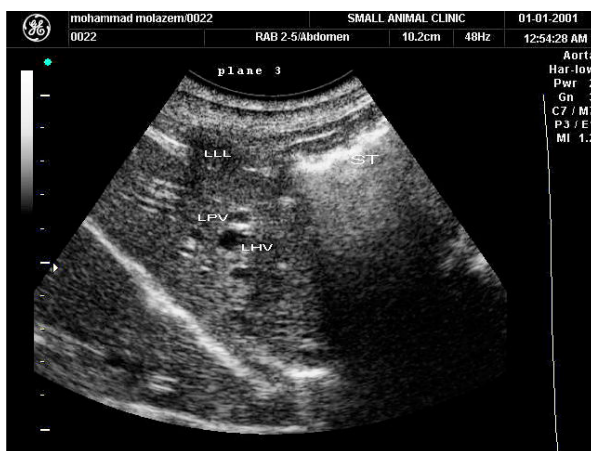

Fig. 5: Plane 3, 2D image of the dog's liver. LLL: left lateral lobe of the liver; LPV: Left portal vein; ST: stomach; LHV: left hepatic vein.

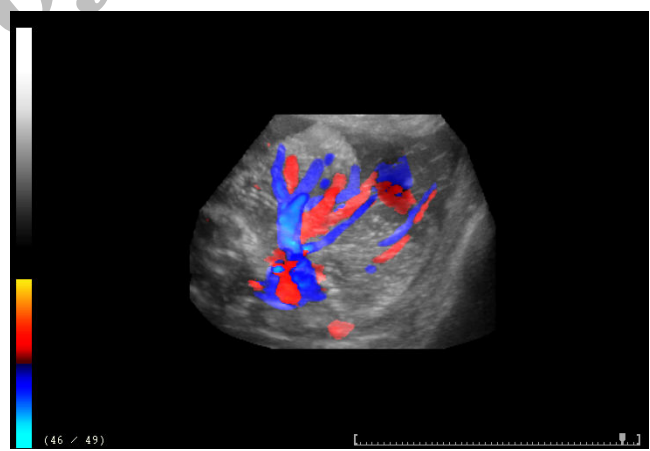


Fig. 6: Plane 3, 3D color Doppler image of the dog's liver.

Plane-4: Beta view angle based on “Right transverse” section in dorsal recumbency to detect entire vessels in the right liver lobes; the transducer was placed between the last 3rd right intercostals space then the 3D image was taken. This plane is good to see the right PVs and HVs in relation to CVC and PV (Fig. 7, 8).

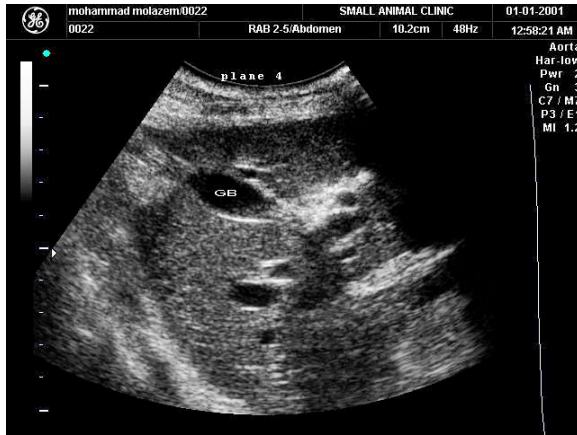

Fig. 7: Plane 4, 2D image of the dog's liver. GB: gall bladder

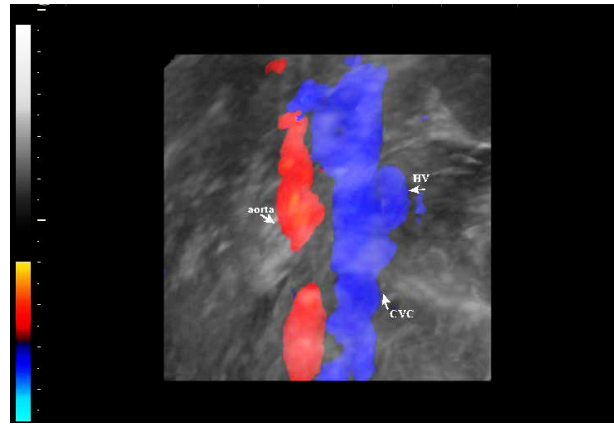


Fig. 8: Plane 4, 3D color Doppler image of the dog's liver. HV: hepatic vein; CVC: caudal vena cava.

Plane-5: Beta view angle based on “Left transverse” section in dorsal recumbency to detect entire vessels in the left liver lobes; the transducer was placed in the last 3rd or 4th left intercostal space then the 3D image was taken. This plane is good to see the left PVs and HVs in relation to CVC and PV (fig. 9, 10).

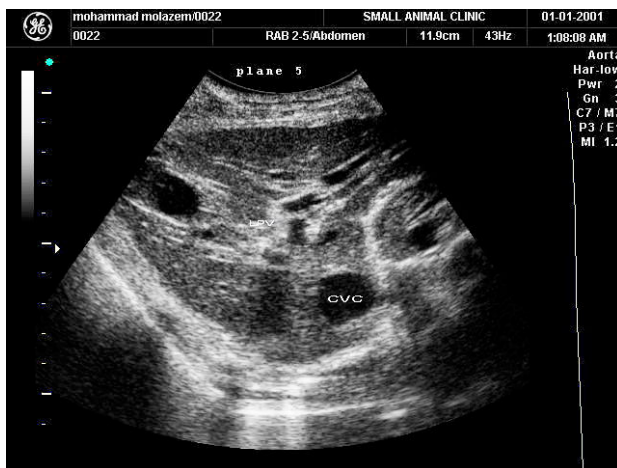

Fig. 9: plane 5, 2D image of the dog's liver. LPV: left portal vein; CVC: caudal vena cava.

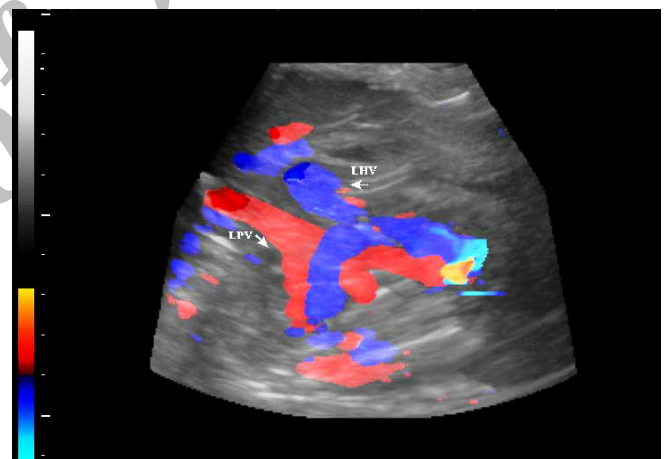


Fig. 10: plane 5, 3D color Doppler image of the dog's liver. LHV: left hepatic vein; LPV: left portal vein.

Plane-6: Beta view angle based on “transverse” section in dorsal recumbency as an additional scan for better visualization of HV and CVC, and sometimes AO. The transducer was placed immediately caudal and perpendicular to the xyphoid with mild transducer pressure dorsally and mild sliding cranially (fig 11, 12).

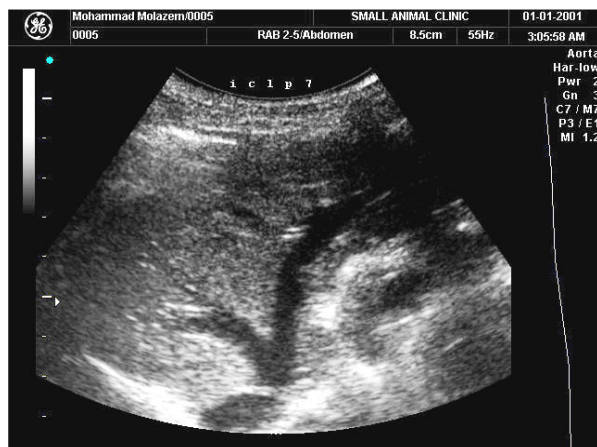

Fig. 11: plane 6, 2D image of the dog's liver. The "V" shape hypoechoic vessel in the middle of the figure is hepatic vein.

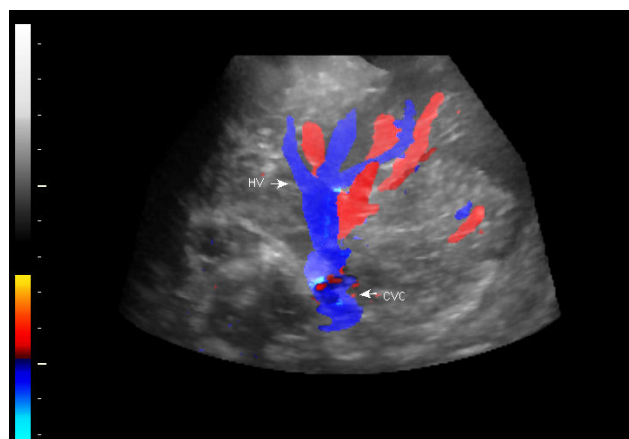


Fig. 12: plane 6, 3D color Doppler image of the dog's liver. HV: hepatic vein; CVC: caudal vena cava.

Discussion

Generally, using 3D ultrasonography technique for vessel assessment is very new and since there are still not plenty amount of ultrasound machines with the ability in the research centers, studies on this subject are a few.

For the first time, Ohishi et al (1998), used 3D US for liver and kidney tumor vascularity and claimed the benefits.⁶ Pairleitner et al (1999), based 3DCDUS in medicine and introduced them as a way to assess vascularity.⁷ Downey (2000), vastly investigated the utilities of 3D ultrasonography and showed that one of the usages of this technique is detecting the vessel anatomic patterns.⁸ Herbay and Haussinger (2001), used this technique to image abdominal organs.⁹ After them, different usages of the technique were showed in human medicine by other authors to diagnose prostatic tumors, polycystic ovaries, mammary tumors, abdominal visceral aneurysm, diagnosing of Portosystemic shunt, hepatocellular carcinoma, in vitro vasculature perfusion, and reproductive medicine and so on.¹⁰⁻²⁶ However, to our knowledge, this must be the first clinical protocol in which 3DCDUS was used for liver in veterinary and medical practice and seems to have the potential to provide greater detail of the vascularity associated with abnormal lesion because conventional color Doppler ultrasound (US) has several disadvantages that 3DCDUS has the potential to rectify.

One of its major disadvantages is operator dependency. The operator sweeps the US beam back and forth across the liver many times while mentally integrating multiple 2D images into a 3D impression of the underlying vessel anatomy and disease. This process is universally acknowledged as time-consuming and inefficient, and there is considerable interobserver variability.²⁷ In contrast, 3D color Doppler images can be reconstructed from data obtained with a single sweep of the US beam across the liver. Both the US information and the relative position of each tomographic section are accurately recorded.⁸ As a result, the exact relationships among the vessels are accurately recorded in the 3D image.

Another disadvantage of conventional color Doppler US is the limited viewing perspective it allows. Sometimes, the patient's anatomy or position makes it impossible to orient the US transducer for optimal visualization of a particular vessel. Three-dimensional color Doppler US allows unrestricted access to an infinite number of viewing planes.²⁸

In addition, 2D color Doppler US is ill suited for monitoring the effects of therapy over a long period of time.⁸ To minimize artifacts, 2D images are usually acquired with nonstandard patient positioning during various phases of respiration. To accurately assess the long-term effects of treatment during follow-up, the ideal would be to replicate the US images that best demonstrated the abnormality. Although it is usually possible to approximate an earlier image, one can never be sure if the changes on a subsequent image are substantive or merely reflect slight differences in imaging technique. Three-dimensional color Doppler US allows comparison of two full data sets over time, thereby improving accuracy of evaluation.

Furthermore, with 2D scan, a “flat” anatomic section is displayed on a video monitor or on film. With 3D color Doppler US different viewing algorithms allow the data to be displayed with a variety of techniques, including color or glass body rendering by color surface or color transparent mode. Finally, if it is necessary, quantitative volume estimates made at 2D images are often based on images that are approximately orthogonal to each other, which may lead to inaccurate and variable results whereas in 3D US it has been shown to provide a more accurate and repeatable method of evaluating anatomic structures and disease entities²⁹⁻³⁰.

Besides the advantages, there are some disadvantages too; including that analyzing of 3DCDUS acquired data are more cumbersome than the conventional US. Also the assemblies in 3D transducers are typically bigger than 2D ones and therefore more difficult for the user to manipulate. The larger data sets produced with 3D US also make data archiving and communication more challenging.

Computer capacity and speed is important too; some produce images almost instantaneously, whereas others require several seconds to produce an onscreen image. The ability to view data with a variety of algorithms and from different perspectives may slow the image interpretation process. Inexperienced users may have to spend extra time finding the best algorithm and perspective for viewing the data. Many of the viewing programs require a considerable amount of image manipulation to obtain high-quality results.

At conventional color Doppler US, there is no need to breathe stopping while data acquisition but it is necessary in 3D scanning which lead to use anesthesia among the study.

In all investigations of noninvasive modalities, contrast angiography would be used as a standard comparison. Although in the present study the mentioned standard was not used, the authors realize that this technique may worth because of the 3D capabilities. However, further investigations can test this claim.³¹

In conclusion, using 3D color Doppler US for dog liver vasculature was feasible, almost easy, and seemed to have the potential to provide greater detail of the vascularity associated with abnormal lesion.

References

1. Doherty M, Bordes N, Hugh T, et al. 3D Visualization of tumours and blood vessels in human liver, in *Proceedings. Pan-Sydney Area Workshop on Visual Information* Sydney, Australia. Conf Res Pract Inform Tech 2002; 22: 27-28.
2. Grady J, Lake JR, Howdle PD. *Comprehensive clinical hepatology*. London: Harcourt Publisher Ltd., 2000; I 1.3-1.6.
3. Sleight DR, Thomford NR. Gross anatomy of the blood supply and biliary drainage of the canine liver. *Anat Rec* 2005;166:153-160.
4. Vajhi AR, Molazem M, Mohammadiar L, et al. Ultrasonography of dog stomach filled with degassed water. *Indian Vet J* 2006;83:780-781.

5. Nyland TG, Mattoon JS, Herrgesell EJ. Liver. In: Nyland TG, Mattoon JS, eds. *Small animal diagnostic ultrasound*. 2nd ed. Philadelphia: WB Saunders Co, 2002;93-127.
6. Ohishi H, Hirai T, Yamada R, et al. Three-dimensional power Doppler sonography of tumor vascularity. *J Ultras Med* 1998; 17(10): 619-622.
7. Pairleitner H, Steiner H, Hasenoehrl G, et al. Three-dimensional power Doppler sonography: imaging and quantifying blood flow and vascularization: *Ultrasound Obstet Gynecol* 1999;14:139-43.
8. Downey DB, Fenster A, Williams JC. Clinical utility of three-dimensional US. *Radiographics* 2000;20:559-571.
9. Herbay A, Haussinger D. Abdominal three-dimensional power Doppler imaging. *J Ultras Med* 2001;20:151-157.
10. Kurtz AB, Tsimikas JV, Tempany CM, et al. Diagnosis and staging of ovarian cancer comparative values of Doppler and conventional US, CT, and MR imaging correlated with surgery and histopathologic analysis. *Radiology* 1999;212:19-27.
11. Downey DB. Three-dimensional power Doppler detection of prostatic cancer. *Am J Roentgenol* 1995;165:741.
12. Campani R, Bottinelli O, Calliada F, et al. The latest in ultrasound: Three-dimensional imaging. *Eur J Radiol* 1998;27 (Suppl 2):183-187.
13. Cohen LS, Escobar PF, Scharm C, et al. Three-dimensional power Doppler ultrasound improves the diagnostic accuracy for ovarian cancer prediction. *Gynecol Oncol* 2002; 84:352-3.
14. Frauscher F, Klauser A, Halpern EJ. Contrast-enhanced transrectal ultrasound of the prostate: Clinical utility and future applications for detection of prostate cancer. *Electromedica* 2000;68:29-34.
15. Jean JH, René G. New developments in ultrasonography for the detection of prostate cancer. *J Endourol* 2001;15:93-104.
16. Liang JD, Yang PM, Liang PC, et al. Three-dimensional power Doppler ultrasonography for demonstrating associated arteries of hepatocellular carcinoma. *J Formos Med Assoc* 2003;102:367-74.
17. Moriwaki Y, Matsuda G, Karube N, et al. Usefulness of color Doppler ultrasonography (CDUS) and three-dimensional spiral computed tomographic angiography (3D-CT) for diagnosis of unruptured abdominal visceral aneurysm. *Hepato-Gastroenterol* 2002;49: 1728-30.
18. Oguz B, Akata D, Balkanci F, et al. Intrahepatic portosystemic venous shunt: diagnosis by colour/power Doppler imaging and three-dimensional ultrasound. *Brit J Radiol* 2003; 76: 487-490.
19. Pan H, Wu M, Cheng Y, et al. Quantification of Doppler signal in polycystic ovary syndrome using three-dimensional power Doppler ultrasonography. *Hum Reprod* 2002;17:201-206.
20. Ritchie CJ, Edwards WS, Mack LA, et al. Three-dimensional ultrasonic angiography using power-mode Doppler. *Ultras Med Biol* 1996;22:277-86.
21. Raine-Fenning NJ, Ramnarine KV, Nordin NM, et al. Quantification of blood perfusion using 3D power Doppler: an *in-vitro* flow phantom study. *J Physics: Conference Series* 1, 2004:181-186.
22. Sauvain JL, Palascak P, Bourscheid D, et al. Value of power Doppler and 3D vascular sonography as a method for diagnosis and staging of prostate cancer. *Eur Urol* 2003; 44:21-30.

23. Svensson WE. The use of color Doppler vascular morphology in improving the ultrasound diagnosis of breast lesions. *Acta Clin Croat* 2002;41 (Suppl):99-100.
24. Yaman TC, Jesacher EK. Three-dimensional power Doppler in the diagnosis of ovarian torsion. *Ultrasound Obstet Gynecol* 2002;20:513-515.
25. Unal D, Sedelaar JP, Aarnink RG, et al. Three-dimensional contrast-enhanced power Doppler ultrasonography and conventional examination methods: the value of diagnostic predictors of prostate cancer. *B J U Int* 2000;86:58-64.
26. Kathy A, Spaulding. A Review of Sonographic Identification of Abdominal Blood Vessels and Juxtavascular Organs. *Vet Radiol Ultrasoun* 1997;38:4-23.
27. Gonçalves LF, Nien JK, Espinoza J, et al. What does two-dimensional add to three- and four-dimensional obstetrical ultrasound? *J Ultras Med* 2006;25:691-699.
28. Fenster A, Downey DB, Cardinal HN. Three-dimensional ultrasound imaging. *Phys Med Biol* 2001; 46: 67-99.
29. Elliot TL, Downey DB, Tong S, et al. Accuracy of prostate volume measurements in vitro using three-dimensional ultrasound. *Acad Radiol* 1996;3:401.
30. Tong S, Cardinal HN, Downey DB, et al. Analysis of linear, area, and volume distortion in 3D ultrasound imaging. *Ultrasound Med Biol* 1998;24:355-373.
31. Leung DA, Hoffmann U, Pfammatter T, et al. Magnetic resonance angiography versus duplex sonography for diagnosing renovascular disease. *Hypertension* 1999; 33:726-731.

بررسی الگوی طبیعی عروق کبد با استفاده از اولتراسونوگرافی سه بعدی داپلر رنگی

دکتر محمد ملازم^۱، دکتر علی رضا وجهی^۱، دکتر سارنگ سروری^۱،
دکتر عباس وشکینی^۱، دکتر مجید مسعودی فرد^۱، دکتر سهیل پدram^۲

^۱گروه آموزشی علوم درمانگاهی دانشکده دامپزشکی دانشگاه تهران، تهران، ایران.
^۲بخش جراحی، دانشکده دامپزشکی، دانشگاه شاهد، تهران، ایران.

هدف: برای تهیه مدل سه بعدی از عروق کبد سگ توسط اولتراسونوگرافی سه بعدی داپلر رنگی برای استفاده در برنامه ریزی پیش از جراحی، بررسی و تشخیص تومورها، انتقال کبد و دیگر موارد تشخیصی و درمانی.

طرح: مطالعه توصیفی.

حیوانات: شش سگ نژاد مخلوط ۱/۶ تا ۱/۷ ساله با وزن ۱۸ تا ۲۰ کیلوگرم.

روش: عروق کبد سگ ها تحت بررسی التراسونوگرافی داپلر رنگی دو بعدی و سه بعدی توسط دستگاه التراسونوگرافی ولوسان ۷۳۰ پرو قرار گرفت.

نتایج: بهترین رهیافت برای ایجاد تصاویر سه بعدی، در دو جهت عرضی و طولی، خوابیده به پشت ارزیابی شد.

نتیجه گیری: این اولین پروتکل درمانگاهی برای استفاده از التراسونوگرافی داپلر رنگی سه بعدی در کبد سگ بود و به نظر می رسد که پتانسیل فراوانی برای بررسی عروق مرتبط با عوارض کبدی داشته باشد.

کلید واژگان: اولتراسونوگرافی سه بعدی، داپلر رنگی، کبد، سگ

Archive of SID