

## Computed Tomographic Anatomy of the Bronchial Tree of the Jebeer Gazelle

Seyed Mohsen Sajjadian<sup>1</sup>, PhD  
Bahador Shojaei<sup>1\*</sup>, PhD  
Mohammad Mehdi Molaei<sup>2</sup>, DVSc

<sup>1</sup>Department of Basic Sciences and <sup>2</sup>Department of Clinical Sciences,  
Faculty of Veterinary Medicine,  
Shahid Bahonar University of Kerman, Kerman, Iran.

---

### Abstract

**Objectives-** to provide a reference anatomy of the bronchial tree of the Jebeer Gazelle by using computed tomographic modality.

**Design-** Experimental study.

**Animals-** Three female Jebeer Gazelle

**Procedures-** Spiral CT images were taken from the thoracic region perpendicular to long axis of the body. CT windows were adjusted as necessary to have optimized images of pulmonary organ. The images were studied serially and compared anatomically with two dissected goat and sheep.

**Results-** Trachea, lobar and some segmental bronchi were identified and labeled according to thoracic vertebrae as landmarks

**Conclusions and clinical relevance-** The results of this study can help better understanding of the lung and bronchial tree in a live animal.

**Keywords:** Jebeer, Gazelle, Anatomy, Computed Tomography, Bronchial tree, Lung

---

### \* Corresponding author:

B. Shojaei, PhD

Faculty of Veterinary Medicine, Shahid Bahonar University of Kerman, Kerman, Iran.

E-mail address: bshojaei@mail.uk.ac.ir

## Introduction

Jebeer Gazelle (*Gazella bennettii*) is one of the species of the genus *Gazella* that lives in south east provinces of Iran and is in danger of extinction.<sup>1</sup> Knowledge of its anatomy is important in breeding, caring and treatment of its diseases. Moreover development of fine paraclinical methods in order to have better diagnosis in diseased cases can be one of the most important priorities for health care and survival of individuals.

Computed Tomography (CT) is an imaging modality which allows radiologists and surgeons to explore the contents of body regions in live animal and makes it possible to have accurate dimensions and relationship of organs in a plating image.<sup>2-6</sup> In order to have a fine interpretation of diseased cases, knowledge of normal CT anatomy of examined region is essential.<sup>2,7</sup> Although the anatomy of the respiratory system of domestic ruminants has well documented<sup>8-9</sup>, we could not find any detailed information about the anatomy of the Jebeer. So we designed a study to provide a reference anatomy of the Jebeer using computed tomographic modality. This study has focused on lung and bronchial tree.

## Materials and Methods

Three female adult healthy Jebeer were used in this study. Each animal was given subcutaneous Atropine (0/04 mg/kg) and after 5 minute was anesthetized by intravenous injection of mixed Ketamine [Ketamin HCL 50 mg/ml, Trittau, Germany] (5 mg/kg) and Xylazine [Rompun, 2%, Bayer, AG, Leverkusen] (0.5 mg/kg). For the maintenance of the anesthesia, the cocktail was injected at half dosage and the same route.

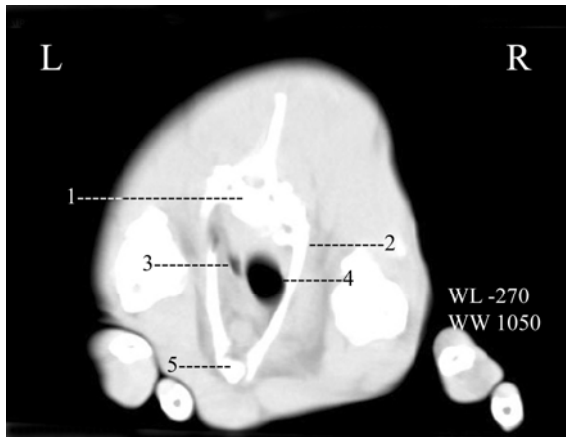
Each animal was restrained in the sternal recumbency in a symmetrical position relative to the plane of image acquisition. X- ray radiation was adjusted by an angle of 90 degrees to the long axis of the vertebrae and tomograms were acquired at a thickness of 1 mm using a general diagnostic CT system (Toshiba Xvision EX). The acquisition parameters were as follows: kVp120, mA 110 and scan-time of 1-S. Different two CT Windows (WW and WL: 690 and -425; 1050 and -270) were used to obtain the optimal image for showing lungs and bronchial tree. According to assumptive similarities of Jebeer and domestic ruminants, one sheep and a goat were euthanized and dissected in order to identify the observed structures of the CT images. The thoracic vertebrae were used as landmarks to describe the location and extension of the structures.

## Results

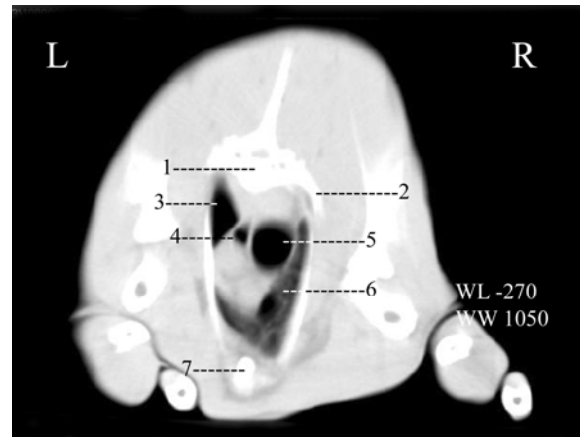
In fig.s 1 to 8, CT images are viewed from cranial to caudal. Transverse images have been presented how the left and dorsal aspects of the animal are in the left and dorsal sides of the viewer respectively. Two different CT windows were used to have the optimal visualization of both minor and major respiratory passages. In these images, the major branches of bronchial tree have been identified and labeled.

Trachea entered the thoracic cavity medial to the right first rib and on the right side of the esophagus (Fig. 1). It was then separated from the right thoracic wall by right apical lobe (Fig. 2). In the cranial half of cranial mediastinum, it was seen in the dorsal half of thoracic cavity (Fig. 1) but according to increase of vertical diameter of this cavity, it gradually displaced to the dorsal

third of this space (Fig. 3). During its course it detached tracheal bronchus to the right apical lobe at T4 (Fig. 3). The latter was bifurcated at T5 into two bronchi which distributed into two parts of cranial lobe (Fig. 4). Trachea coursed caudally and bifurcated dorsal to the heart base into right and left main bronchi at T7 (Fig. 5).



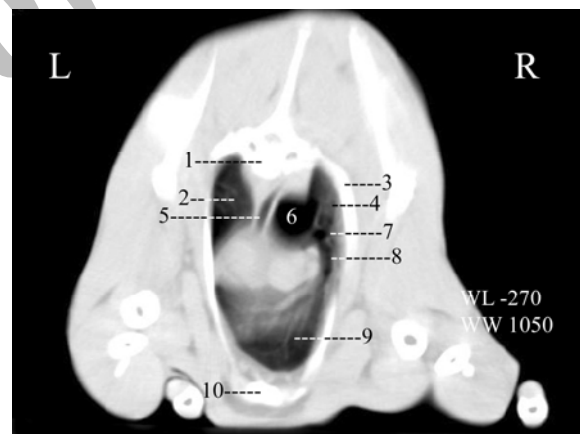
**Figure 1.** 1-T1, 2-1<sup>st</sup> rib, 3-esophagus, 4-trachea, 5-sternum.



**Figure 2.** 1-T3, 2-2<sup>nd</sup> rib, 3-cranial part of left apical lobe, 4-esophagus, 5-trachea, 6- cranial part of right apical lobe, 7- sternum.



**Figure 3.** 1-left apical lobe, 2-trachea, 3-tracheal bronchus, 4- right apical lobe.




**Figure 4.** 1-T5, 2-left apical lobe, 3-3<sup>rd</sup> rib, 4-caudal part of right apical lobe, 5- esophagus, 6-trachea, 7- segmental bronchus to caudal part of right apical lobe, 8-segmental bronchus to cranial part of right apical lobe, 9-cranial part of right apical lobe, 10- sternum.

Following branches were observed sequentially from the right main bronchus during its caudal course.

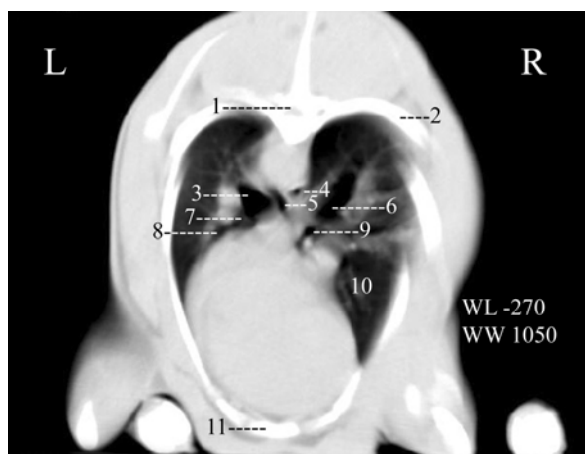- a dorsolateral branch to the dorsal border of the lung at T7 (Fig. 5).
- ventrolateral lobar bronchus to the middle lobe at the caudal part of T7 (Fig. 6).
- ventromedial lobar bronchus to the accessory lobe at the caudal part of the T7 just caudal to the previous branch (Fig. 7).



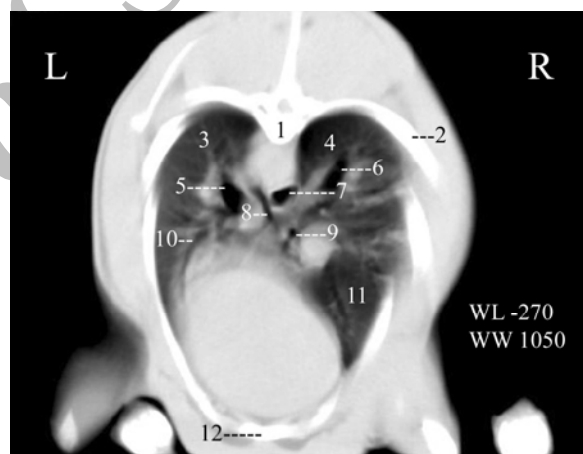
**Figure 5.** 1 and 2-left and right apical lobes, 3-esophagus, 4-main left and right bronchi, 5-dorsolateral bronchus to the dorsal border of right lung, 6- segmental bronchus to cranial part of left apical lobe.



**Figure 6.** 1 and 2- dorsal borders of left and right lungs, 3-left and right main bronchi, 4-dorsolateral branch to dorsal border, 5-left apical lobar bronchus, 6-right middle lobar bronchus, 7-middle lobe.



**Figure 7.** 1-T8, 2-7<sup>th</sup> rib, 3-left diaphragmatic lobar bronchus, 4-esophagus, 5-1<sup>st</sup> medial branch of left diaphragmatic bronchus, 6-right diaphragmatic lobar bronchus, 7-cranial segmental branch of left apical bronchus, 8-caudal segmental branch of left apical bronchus, 9-accessory lobar bronchus, 10-middle lobe, 11-sternum.



**Figure 8.** 1-caudal part of T8, 2-7<sup>th</sup> rib, 3 and 4-left and right diaphragmatic lobes, 5 and 6-left and right diaphragmatic bronchi, 7-esophagus, 8-segmental bronchus, 9-accessory lobar bronchus, 10- caudal segmental branch of left apical bronchus, 11-middle lobe, 12-sternum.

After giving off above branches, the continuation of main bronchus, diaphragmatic lobar bronchus, coursed caudodorsally and detached branches to different parts of diaphragmatic lobe (Fig. 7 and 8 ).

Two first branches of left main bronchus were seen dorsal and ventral to the left pulmonary artery at the caudal part of T7 (Fig. 6). The dorsal branch pursued a dorsolateral route to the dorsal border of the left lung (Fig. 6). The ventral one, left apical lobar bronchus, immediately divided into cranial and caudal segmental bronchi (Fig. 7). Cranial segmental bronchus coursed

laterally and then cranially (Fig. 6 and 5) to ramify in the cranial part of left apical lobe. The caudal one coursed caudoventrally to ventilate caudal part of left apical lobe (Fig. 8). Next branch detached at T8 medially from the left diaphragmatic bronchus in the left side of the esophagus (Fig. 7). It journeyed caudally and then ventrally in the medial side of esophagus to furnish ventilation for caudomedial parts of diaphragmatic lobe (Fig. 8). The parent bronchus coursed caudodorsally more or less similar to its right counterpart to support remainder of the left diaphragmatic lobe (Fig. 7 and 8).

## Discussion

Because of high potential of different organs differentiation, computed tomography is said to be an innovative modality in the imaging of the lung for clinical diagnosis in small animals.<sup>10-12</sup> The superiority of this modality to conventional radiography has also been mentioned in clinical and non clinical studies which have been done on the ruminants.<sup>13-15</sup>

By this technique, to improve the identification of certain structures, modification of the attenuation degree was permitted inside some limits. Because of the wide range of CT numbers that present in the thoracic organs, the abovementioned statement would be appreciated when these organs are analyzed.<sup>16-17</sup> We welcome this ability to manipulate CT windows in the present study to have the best image for different parts of the pulmonary organs.

In this study we took 1 mm interval images which enabled us to follow precisely the tracheal arboring in serial CT images and up to the segmental bronchi. It was so useful especially for detection of origin of bronchi which most of them branched not in continuation with their parent passage and those bronchi which change their direction. In wider intervals<sup>17-18</sup> one may lose some detailed information.

Normal CT features of the thoracic cavity of the small animals have been studied in recent years.<sup>2,3,5,17,19,20</sup> Most of these studies have focused on the thoracic wall and mediastinum, so the window level and width have been adjusted for soft tissue and only trachea and two main bronchi of the bronchial tree have been identified.<sup>2,3,5,19</sup> We could only find one study which has used several CT windows to appreciate the CT appearance of the lungs.<sup>17</sup> We could find few articles that have mentioned CT anatomy of thoracic region in ruminants<sup>18,21</sup> which none of them has focused on the lung. Up to our knowledge this is the first CT work on bronchial tree anatomy in a ruminant.

## Acknowledgement

This work was supported by a grant from the research council, Veterinary Faculty, Shahid Bahonar university of kerman, Iran. The authors are grateful to Dr Madjjid Tahmoresi for his contribution to the computed tomography part of this study.

## References

1. Ziaie H. A field guide to the mammals of Iran. 2<sup>nd</sup> ed. Iran wildlife center 2008; 357-358.
2. Smallwood JE, George II TF. Anatomic atlas for computed tomography in the mesocephalic dog : Thorax and cranial abdomen. *Vet Radiol Ultrasound* 1993;34: 65-84.
3. Samii VF, Biller DS, Koblik, PD. Normal cross-sectional anatomy of the feline thorax and abdomen: comparison of computed tomography and cadaver anatomy. *Vet Radiol Ultrasound* 1998;39:504-511.
4. Olby NJ, Muñana KR, Sharp NJ, et al. The computed tomographic appearance of acute thoracolumbar intervertebral disc herniations in dogs. *Vet Radiol Ultrasound*, 2000;41:396-402.
5. Shojaei B, Rostami A, Vajhi A, et al. Computed tomographic anatomy of the thoracic region of the cat. *Vet Arhiv*, 2003;73:261-269.
6. Shojaei B, Vajhi AR, Rostami A, et al. Computed tomographic anatomy of the abdominal region of cat. *IJVR*, 2006;7:45-52.
7. Jones JC, Cartee RE, Bartels JE. Computed tomographic anatomy of the canine lumbosacral spine. *Vet Radiol Ultrasound*, 1995;36:91-99.
8. Getty R. *Sisson and Grossman's the anatomy of the domestic animals*. Vol. 1, 5<sup>th</sup> ed. Philadelphia: WB Saunders Co, 1975;916-936.
9. Nickel R., Schummer A, Seiferle E. *The viscera of the domestic mammals*. Berlin: Verlag Paul Parey Co;1973;261-271.
10. Johnson VS, Ramsey IK, Thompson H, et al. Thoracic high resolution computed tomography in the diagnosis of metastatic carcinoma. *J Small Anim Pract* 2004;45: 134-143.
11. Morandi F, Mattoon JS, Lakritz J, et al. Correlation of helical and incremental high-resolution thin-section computed tomographic and histomorphometric quantitative evaluation of an acute inflammatory response of lungs in dogs. *Am J Vet Res*, 2004; 65: 1114-1123.
12. Zekas LJ, Crawford JT, O'Brien RT. Computed tomography-guided fine-needle aspirate and tissue-core biopsy of intrathoracic lesions in thirty dogs and cats. *Vet Radiol Ultrasound* 2005; 46: 200-204.
13. Cadore JL, Loubeyre P, Vuillermoz S, et al. Early diagnosis of lentivirus-induced infiltrative lung disease in sheep by high resolution computed tomography. *Eur Respir J* 1997;10:1456-1459.
14. Gerros TC, Mattoon JS, Snyder SP. Use of computed tomography in the diagnosis of a cerebral abscess in a goat. *Vet. Radiol. Ultrasound* 1998;39:322-324.
15. Walker NE, Olszewski ME, Wahle A, et al. Measurement of coronary vasoreactivity in sheep using 64-slice multidetector computed tomography and 3-D segmentation. *International Congress Series*, 1281. Iowa: Iowa State University Press; 2005,1304.
16. Ottesen N, Moe L. An introduction to computed tomography (CT) in the dog. *Eur J Companion Anim Pract* 1998; 8:29-36.

17. Cardoso L, Gil F, Ramírez G, et al. Computed tomography (CT) of the lungs of the dog using a helical CT scanner, intravenous iodine contrast medium and different CT windows. *Anat Histol Embryol* 2007;36:328-31.
18. Alsafy MAM. Computed tomography and cross-sectional anatomy of the thorax of goat. *Small Rumin Res* 2008;79:158-166.
19. Vladova D, Stefanov M, Toneva Y. Computed Tomography study of thoracic Aorta in the cat. *Bulg J Vet Med* 2005a;8:151-156.
20. Vladova D, Toneva Y, Stefanov M. Computed tomography (CT) of the cranial mediastinum in the cat. *Trakia J Sci* 2005b;3:53-57.
21. Shojaei B. Computed tomographic anatomy of the major thoracic vessels in the Rayini goat. *IJVR*, in press.

## بررسی کالبد شناختی تصاویر لایه نگاری رایانه ای درخت نایژه ای جبیر

سید محسن سجادیان<sup>۱</sup>، بهادر شجاعی<sup>۱</sup>، محمد مهدی مولایی<sup>۲</sup>

<sup>۱</sup>گروه علوم پایه و <sup>۲</sup>گروه علوم درمانگاهی دانشکده دامپزشکی، دانشگاه شهید باهنر، کرمان، ایران.

**هدف-** تهیه یک منبع کالبد شناختی از درخت نایژه ای جبیر به کمک لایه نگاری رایانه ای.

**طرح مطالعه -** مطالعه تجربی.

**حیوانات-** سه راس جبیر ماده.

**روش کار-** تصاویر سی تی از ناحیه سینه عمود بر محور طولی بدن تهیه شدند. پنجره های سی تی به نوعی تنظیم شد که بهترین تصویر از ریه به دست آید. تصاویر مطالعه و از نظر کالبد شناختی با یک راس گوسفند و یک راس بز تشریح شده مقایسه شدند.

**نتایج -** نای، نایژه های لبی و برخی از نایژه های قطعه ای مشخص و با توجه به مهره های سینه به عنوان نشانه، نامگذاری شدند.

**نتیجه گیری و کاربرد بالینی -** نتایج این مطالعه می تواند سبب درک بهتری از ساختار شش ها و نایژه ها در جبیر گردد.

**کلید واژگان -** جبیر، کالبدشناسی، لایه نگاری رایانه ای، درخت نایژه ای، ریه.