



Comparative Endoscopic Evaluation of Reconstructive Roux-en-Y With Jejunal Loop Interposition Following Gastrectomy in Dogs

Mahboobeh Abdi¹, DVSc
Jalal Bakhtiari^{1*}, DVSc
Shahram Jamshidi¹, DVSc
Azin Tavakoli², DVSc
Alireza Khalaj³, MD

¹ Department of Clinical Sciences, Faculty of Veterinary Medicine,
University of Tehran, Tehran, Iran,

² Department of Clinical Sciences, Faculty of Veterinary Medicine,
Islamic Azad University, Garmsar Branch, Garmsar, Iran,

³ Department of Clinical Sciences, Faculty of Medicine, University of Shahed, Tehran, Iran.

Abstract

Objective- Comparative endoscopic evaluation of two reconstructive methods (R&Y and jejunal loop interposition) after gastrectomy in dogs.

Design- Experimental study.

Animals- Ten healthy male dogs.

Procedures- The animals were divided randomly in two groups. After a 12 hour food with hold and under general anesthesia laparotomy is performed in all dogs. In group A (R&Y), after dissection and resection of all gastric vessels and ligaments the stomach was resected cranially close to cardia and caudally close to pylorus. After gastrectomy duodenal end was closed in a two layer inverting suture pattern. Then a loop of jejunum 20 cm distal to Treitz ligament was identified and resected. End to side anastomosis was performed between the distal jejunal end and remained part of the stomach. The proximal jejunal end was end to side anastomosed to the rest of jejunum. In group B (JLI), gastrectomy was done in the same manner. The 20 cm length of jejunum was resected from a 20 cm distance to Treitz ligament. The proximal end of the jejunal loop was end to side anastomosed to the remained part of the stomach and the distal end was anastomosed to the proximal jejunum. Finally jejunojejunostomy was performed between the two Jejunal parts. 1 month after surgery, esophagoscopy and gastroscopy evaluation was performed to rule out the reflux esophagitis or gastritis.

* Corresponding author:

J. Bakhtiari, DVSc

Department of Clinical Sciences, Faculty of Veterinary Medicine, University of Tehran, Tehran, Iran.

E-mail address: bakhtiar@ut.ac.ir

Results- Esophagoscopy and gastroscopy thirty days after operation revealed normal appearance at gastroduodenal and duodenojejunal anastomotic junctions. There was no report of enterogastric biliary reflux (EBR) in esophagus or alkaline gastritis. A 2 cm to 2 cm ulcerative mass was observed in the remained part of stomach close to gastrojejunal anastomotic site in one patient in group A. Also regurgitation was noticed in the same patient. A 1 cm to 1 cm ulcer was reported in one patient in group B. Morphology of all anastomotic sites was normal. They were all patent and healed normally without any signs of inflammation.

Conclusion and Clinical Relevance- The results of this study showed that the JLI like R&Y technique is a successful method to prevent reflux esophagitis.

Key Words- Gastrectomy, Gastroscopy, Dog.

Introduction

Complete or partial surgical removal of the stomach is indicated in malignant gastric cancers, which remains the top 10 cause of cancer related deaths in human.^{1,2,3} Since Schlatte in 1897 performed first gastrectomy successfully several bowel reconstructive techniques have been reported but the ideal reconstructive procedure is a matter of controversy. Complications after total gastrectomy include dysphagia, pyrosis, decreased appetite, diarrhea, vomiting and other gastric signs which may lead to body weight loss.^{4,5} Also malnutrition following gastrectomy can be due to rapid bacterial growth that causes mal-absorption, small intestine mucosal erosion, pancreas related enzyme deficiency and decreased small intestine passing time.⁶ Since esophagus is the most sensitive part of the alimentary tract to gastric acid and biliary secretions, esophagitis is the most common complication after gastrectomy.^{5,7} In addition regurgitation of duodenal fluid to stomach and esophagus is associated with destruction of mucosal layer. These may produce signs such as epigastric pain, nausea and vomiting of bile. Unfortunately conservative treatment is mostly ineffective. Therefore Selection of an appropriate reconstructive technique of alimentary tract following gastrectomy is effective in improving food absorption, reducing related complications and finally improving quality of life in these patients.³ Jejunum is frequently used for reconstruction after gastrectomy between esophagus and duodenum. Although jejunal loop interposition is an efficient and feasible reconstructive technique it is not widely introduced as a standard technique. In addition, R&Y is one of the most common reconstructive procedures following gastrectomy.⁸ Its complications include abdominal pain, restlessness, nausea and vomiting.⁹ Delayed gastric emptying is a very frequently observed complication in R&Y technique. It has been reported in 25 to 30% of the patients; however it is an effective way in preventing reflux.¹⁰

The objective of this experiment was to compare the incidence rate of esophagitis reflux, biliary reflux and other probable complications observed endoscopically in two reconstructive techniques, jejunal loop interposition (J.L.I) and Roux en Y (R&Y) following total gastrectomy in dogs.

Materials and Methods

Ten adult healthy male mixed breed dogs weighting 28 ± 3 kg were divided randomly in two groups. After approval was received by the University Research Committee according to animal ethics guidelines, esophagoscopy and gastroscopy with flexible endoscope (Vetvu-Swiss) was

performed in all patients of both groups. After a 12 hour food with hold and under general anesthesia laparotomy is performed in all dogs in the following order:

In group A (R&Y), left gastroepiploic vessel and its branches were ligated and resected. Next gastroepiploic ligament and right gastroepiploic vessels were resected precisely. Then the stomach was freed from all its attachments and gastrectomy was performed. The stomach was resected cranially close to cardia and caudally close to pylorus, so that only 1/5th of the total size of the stomach was remained. After gastrectomy duodenal end was closed in a two layer inverting suture pattern. Then a loop of jejunum 20 cm distal to Treitz ligament was identified and resected. End to side anastomosis was performed between the distal jejunal end and remained part of the stomach. The proximal jejunal end was end to side anastomosed to the rest of the jejunum (Fig. 1).

In group B (JLI), gastrectomy was done in the same manner. Then jejunal loop interposition was used to reconstruct the bowel. The 20 cm length of jejunum was resected from a 20 cm distance to Treitz ligament. The proximal end of the jejunal loop was end to side anastomosed to the remained part of the stomach and the distal end was anastomosed to the duodenum (Fig. 2).

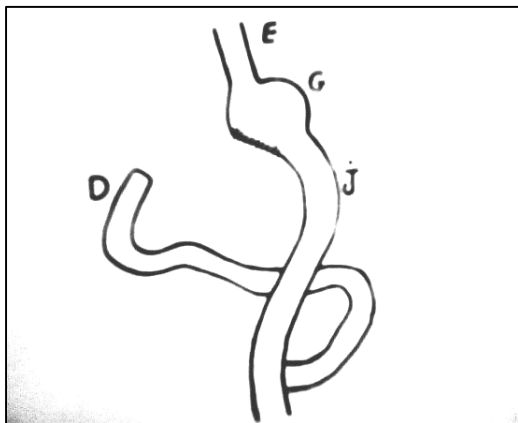


Figure 1. Roux-en-Y Technique.

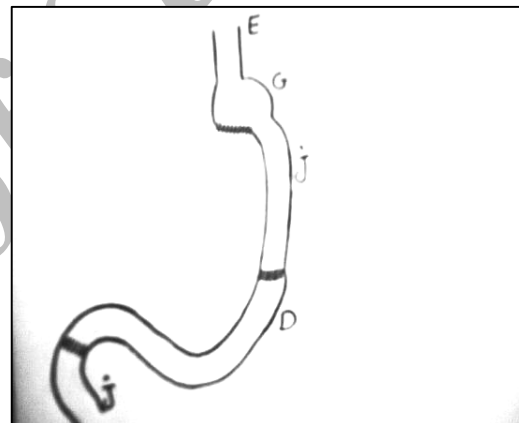


Figure 2. Jejunal Loop Technique.

Finally jejunojejunostomy was performed between the two jejunal parts. The abdomen was lavaged and closed in a routine manner. Food with held was continued two days after surgery. On a 3rd postoperative day patients started to fed with a low volume of soft blended food. Esophagoscopy and gastroscopy were performed 30 days after the surgery in all patients in group A (R&Y) and group B (JLI) to observe morphology of the interposed segment, status of entrogastric biliary reflux (EBR) and presence of esophagitis reflux (ER).

Results

There was no complication during the surgery and all patients recovered. There was no morbidity or mortality in patients of both groups. No preoperative endoscopic evidence of ER or duodenal abnormality was reported (Fig. 3). Esophagoscopy and gastroscopy thirty days after operation revealed normal appearance at gastroduodenal and duodenojejunal anastomotic junctions. There was no report of EBR in esophagus or alkaline gastritis (Fig. 4). A 2 cm to 2 cm ulcerative mass

was observed in the remained part of stomach close to gastrojejunal anastomotic site in one patient in group A (Fig. 5). Also regurgitation was noticed in the same patient. A 1 cm to 1 cm ulcer was reported in one patient in group B (Fig. 6). Morphology of all sites of anastomosis was normal. They were all patent and healed normally without any signs of inflammation.

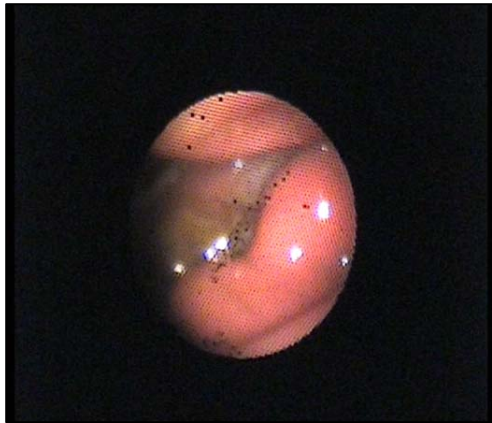

Figure 3. Normal appearance of the anastomotic site.

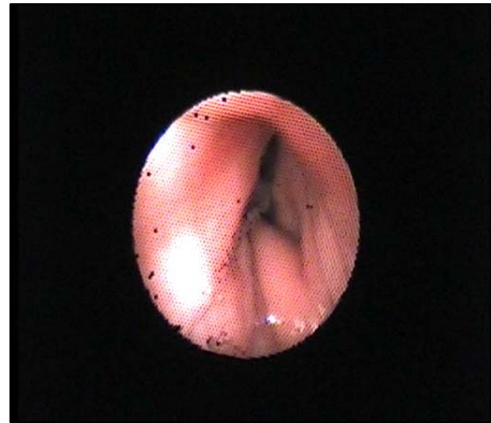

Figure 4. No evidence of reflux esophagitis.

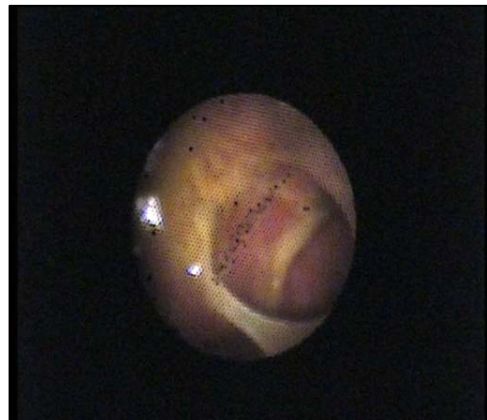

Figure 5. Ulcerative mass in stomach.

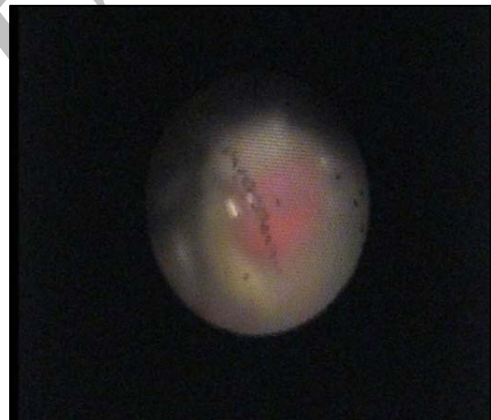

Figure 6. Ulcer noticed in the stomach.

Discussion

Total and partial gastrectomies are performed to treat malignant gastric tumors. Reconstructive technique needs to be performed to maintain the continuity of the bowel. The purpose of reconstruction of alimentary tract following gastrectomy is to prevent reflux esophagitis and also provide an adequate reservoir for food. In patients undergo gastrectomy cardia loses its function to prevent reflux and of the gastric body as a reservoir for food. Thus these patient show complications like ER, dumping syndrome, reduced food intake.^{5,11} Therefore relieving symptoms and improving quality of life are matters of concern in gastrectomized patients. So an optimum reconstructive method for the alimentary tract after total gastrectomy prevents reflux esophagitis and provides a sufficient food reservoir.^{4,5}

ER is a common complication that is mostly complained by patients underwent gastrectomy.^{7,12,14} In this study ER and EBR was studied endoscopically which was easy and feasible to perform. No evidence of ER was reported endoscopically in all patients of both groups. R&Y is the most common surgical reconstructive procedure to prevent ER.^{15,4} However satisfactory results have been reported for JLI in comparison to R&Y.²¹ Similar results were observed in both groups in this study. One patient in group A suffered from regurgitation. JLI is reported to prevent regurgitation because of the isopersaltic property of the jejunal segment. It is believed that the transferred segment of the jejunum not only preserves its peristaltic movements but also has segmental contractions, which prevents regurgitation.⁷ This is in agreement with our findings. There was no report of EBR and alkaline reflux gastritis in patients in both groups. It could be due to decreased biliary salts and lysolectin after jejunal segment was placed between jejunum and stomach.¹⁵ Schumplick et al explained effective biliary reflux prevention in patients undergoing Henley method with alkaline reflux gastritis following gastrectomy.^{16,17} Our findings confirmed this result as well. Surgical correction of alkaline reflux is not always succeeded in resolving signs of reflux. This suggests other involving factors in addition to the amount of EBR in pathophysiology of this clinical symptoms.¹⁸ It is believed that in order to prevent EBR a 45 cm jejunal loop is needed.²⁰ However in an experimental study in pigs it was demonstrated that a 20 cm substituting segment might prevent biliary reflux.¹⁷ In this study the same length of jejunal loop was used. Lack of EBR in our patients suggested that a 20 cm length of jejunal loop transferred for reconstruction is adequate to prevent EBR reflux. Alkaline reflux gastritis is a recognized complication after stomach surgeries that include pylorotomy. This may occur as a result of altered pyloric or duodenal function in patients without gastric surgery.²¹ In the present study two gastric ulcers were observed in both groups. Removing more than 75% of the stomach might lead to higher rate of peptic ulcer incidence.⁷ The presence of ulcer in our study is might because of removal of more than 75% of the total size of the stomach. Similar results in both techniques suggest that JLI reconstructive technique, although is not used as frequent as R&Y technique in patients who undergo total gastrectomy is equally efficient in preventing ER and EBR. However a long term follow up and further investigation is necessary to demonstrate the probability of ulcer incidence and other complications in these patients. It is concluded that the jejunal loop interposition method has the same efficacy and quality compared to R&Y in reducing reflux esophagitis and enterogastric biliary reflux.

Acknowledgment

The authors would like to thank the department of clinical sciences, faculty of veterinary medicine, university of Tehran research council & center of excellence for veterinary research on indigenous domestic animals for their financial support and assistance.

References

1. McCorkle HJ, Harold A, Harper. The Problem of Nutrition Following Complete Gastrectomy. American Surgical Association, Cleveland, Ohio. 1954; 140(4): 467-473.

2. Cristiano GS, Huscher, Andrea Mingoli, et al. Laparoscopic Versus Open Subtotal Gastrectomy for Distal Gastric Cancer, Five-Year Results of a Randomized Prospective Trial. *Ann Surg.* 2005; 241(2): 232-237.
3. William Scott JR, Weidner MG. Total Gastrectomy with Roux-en-Y Esophagojejunostomy in treatment of Gastric Cancer. Southern surgical association, Hot Springs, Virginia. 1956; 143(5): 682-695.
4. Yasushi Nakane, Syunichiro Okumura, Keiji Akehira, et al. Jejunal Pouch Reconstruction after Total Gastrectomy for Cancer, A Randomized Controlled Trial. *Ann Surg.* 1995; 222(1): 27-35.
5. Sakamoto T, Fujimaki M, Tazawa K. Ileocolon Interposition as a Substitute Stomach after Total or Proximal Gastrectomy. *Ann Surg.* 1997; 226(2): 139-145.
6. Nathaniel J, Soper, Lee L, et al. Mastery of Endoscopic and Laparoscopic Surgery. 3rd ed. LIPINCOTT WILLIAMS & WILKINS. 2005; 288-298.
7. Harlowe Skinner H, Alvin Merendino K. An experimental evaluation of an interposed jejunal segment between the esophagus and the stomach combined with upper gastrectomy in the prevention of esophagitis and jejunitis. Public Health Service Project No. C-2186 and the University of Washington Initiative 171 Funds for Research in Biology and Medicine. 1955; 141(2): 201-207.
8. Scurtu R, Groza N, Otel O, et al. Quality of life in patient with esophagojejunal anastomosis after total gastrectomy for cancer. *Romanian J Gastroentero.* 2005; 14(4): 367-372.
9. Qin X, Lei Y, Liu F. Effects of two methods of reconstruction of digestive tract after total gastrectomy on gastrointestinal motility in rats. *World J Gastroentero* 2003; 9(5): 1051-1053.
10. George F. Gowen. Delayed Gastric Emptying After Roux-en-Y due to Four Types of Partial Obstruction. Philadelphia, Pennsylvania. *Ann Surg.* 1992; 215(4): 363-367.
11. Ferguson DJ, Sanchez-Palomera E, Sako Y, et al. Studies on Experimental Esophagitis. *Surg.* 1950; 28(6): 1022-1039.
12. Katalin Kalma'r, Jo'zsef Ne'meth, A'goston. Postprandial Gastrointestinal Hormone Production Is Different, Depending on the Type of Reconstruction Following Total Gastrectomy. *Ann Surg.* 2006; 243(4): 465-471.
13. David M, Sensenig MD, Roger E, et al. Total Gastrectomy with Reference to Chronic Hypokaliemia. *Ann Surg* 1957; 145(1): 81-87.
14. Darrow DC, Miller HC. The Production of Cardiac Lesions by Repeated Injections of Desoxycorticosterone Acetate. *J Clin Invest* 1942; 21(5): 601-611.
15. Jose ES, Sousa MD, Luiz E A, et al. Comparison between Henley Jejunal Interposition and Roux-en-Y Anastomosis as Concerns Enterogastric Biliary Reflux Levels. *Ann Surg* 1988; 208(5): 597-600.
16. Schumpelick V, Schwoy M, Begema NNF, et al. Clinical results of jejunal transposition. *Scand J Gastroentero* 1981; 67: 241-245.
17. Schumpelick V, Stachow R, Schneiber HW. Late results of jejunal interposition. *Scand J Gastroentero* 1984; 92: 227-231.
18. Davidson ED, Hersh T. The surgical treatment of bile reflux gastritis. *Ann Surg.* 1980; 192(2): 175-178.

19. Iannelli A, Gugenheim J. Laparoscopic Roux en-Y Gastric Bypass, but Not Rebanding, Should Be Proposed as Rescue Procedure for Patients with Failed Laparoscopic Gastric Banding. *Ann Surg.* 2005; 241(2): 383-384.
20. Kuzmak LI. A review of seven years' experience with silicone gastric banding. *Obes Surg* 1991; 1(4): 403-408.
21. Demeester TR, Fuchs KH, Ball CS, et al. Experimental and Clinical Results with Proximal End-to-End Duodenojejunostomy for Pathologic Duodenogastric Reflux. *Ann Surg.* 1987; 206(4): 414-426.

Archive of SID

یافته های مقایسه ای آندوسکوپی بعد از بازسازی مسیر گوارشی به روش Roux-en-Y و Jejunal Loop Interposition به دنبال گاسترکتومی در مدل حیوانی سگ

محبوبه عبدی^۱، جلال بختیاری^۱، شهرام جمشیدی^۱، آذین توکلی^۲، علیرضا خلیج^۳

^۱ گروه علوم درمانگاهی، دانشکده دامپزشکی دانشگاه تهران، تهران، ایران،
^۲ گروه علوم درمانگاهی، دانشکده دامپزشکی دانشگاه آزاد اسلامی واحد گرمسار، گرمسار، ایران،
^۳ گروه علوم درمانگاهی، دانشکده پزشکی دانشگاه شاهد، تهران، ایران.

هدف- جهت ارزیابی آندوسکوپی مسیر گوارشی بعد از انجام گاسترکتومی به روش Roux-en-Y و Jejunal Loop Interposition در مدل حیوانی سگ.

طرح مطالعه- مطالعه تجربی.

حیوانات- ۱۰ قلاده سگ نر نژاد مخلوط.

روش کار- بعد از ۱۲ ساعت پرهیز غذایی و انجام بیهوشی، حیوانات در دو گروه ۵ تایی قرار گرفتند. جراحی ساب توتال گاسترکتومی به روش استاندارد و با برداشت بیش از ۴/۵ معده بعد از آزاد کردن آن از اتصالات عروقی و لیگامانها، انجام شد. سپس بازسازی مسیر گوارشی به دو روش Roux-en-Y و Jejunal Loop Interposition در هر گروه انجام شد. یک ماه پس از جراحی نواحی مری و باقیمانده معده تحت بررسی آندوسکوپی قرار گرفتند. ازوفاگوسکوپی و گاستروسکوپی برای ارزیابی مورفولوژی قطعه کارگذاری شده، ریفلاکس مایع صفاوی به مری و حضور ریفلاکس ازوفاژیت انجام شد و مخاط دستگاه گوارشی و محل آناستاموزها تحت بررسی قرار گرفت.

نتایج- نتایج حاصل نشانگر عدم وجود ریفلاکس ازوفاژیت در حیوانات بود و فقط در یک حیوان از گروه Roux-en-Y توده ای به اندازه ۲×۲ سانتی متر در باقیمانده معده در نزدیکی محل آناستاموز معده به ژوژنوم مشاهده گردید.

نتیجه گیری و کاربرد بالینی- نتایج مطالعه حاضر نشان داد روش بازسازی JLI همانند روش R&Y در کاهش ریفلاکس صفا به داخل مری موثر است و قطعه جایگزین شونده ژوژنوم می تواند مری را از ازوفاژیت حفظ کند.

کلید واژگان- گاسترکتومی، گاستروسکوپی، سگ.