

## The Role of Autogenous Bone Marrow in the Healing of Experimental Burn Wound Healing in Rabbits

Mohammad Mehdi Oloumi<sup>1\*</sup>, DVSc  
Amin Derakhshanfar<sup>2</sup>, DVM  
Hani Shemali<sup>1</sup>, DVM  
Marzieh Shavalian<sup>1</sup>, DVM

<sup>1</sup> Department of Clinical Sciences and <sup>2</sup> Department of Pathobiology,  
Faculty of Veterinary Medicine, Shahid Bahonar University of Kerman, Kerman, Iran.

---

### Abstract

**Objective-** To evaluate the role of autogenous bone marrow (BM), in the healing of experimentally induced burn wound in rats.

**Design-** Experimental in-vivo study.

**Animals-** 20 adult male white New Zealand rabbits.

**Procedures-** Two burn wounds were created under general anesthesia using a 100 W electric soldering iron, heated to the point of redness (about 800° C) on each side of the back, 4 cm apart. 2 mg/kg morphine was injected intramuscularly twice daily for four days to control pain. The scab was removed from the wound 48 hours after the wound creation, when daily rinsing the wounds with normal saline began and continued until the end of the study. 48 hours after the wound creation, 1 ml BM was aspirated from left tibial plateau and injected around the wounds of the treatment group at four points, (0.2 ml at each site). The same amount of normal saline was injected around the wounds of the control group. Half of the animals were sacrificed on day 7 and the rest, on day 14 for biomechanical and histopathological evaluations.

**Results-** Histopathologically, on day seven, both groups showed complete necrosis of epidermis and superficial dermis. There was only a mild infiltration of inflammatory cells in treatment group. On day 14, re-epithelialization could be seen in both groups, but it was more prominent in treatment group.

Biomechanically, there was no significant difference between the groups on day seven; whereas, all the biomechanical parameters were significantly more in treatment group, on day 14. It can be concluded that autogenous BM can augment the healing process of burn wounds, experimentally.

---

### \* Corresponding author:

Mohammad Mehdi Oloumi, DVSc

Department of Clinical Sciences, Faculty of Veterinary Medicine, Shahid Bahonar University of Kerman, Kerman, Iran.

E-mail address: oloumi@mail.uk.ac.ir

**Conclusion and Clinical Relevance-** Considering the availability and the ease of harvesting BM, this simple and applicable method can be used to exaggerate burn wound healing in any clinical condition.

**Key Words-** Burn, Bone Marrow, Healing.

## Introduction

Burn can be defined as tissue damage caused by a variety of agents such as heat, chemicals, electricity, sunlight, or nuclear radiation. The most common are burns caused by scalds, building fires, and flammable liquids and gases.<sup>1,2</sup> Thermal burn and related injuries have remained a major cause of death and disability.<sup>3</sup> Although small burns are not usually life threatening, they need the same attention as large burns, in order to achieve functional and cosmetic outcome.<sup>1</sup>

Wound healing is a dynamic and complex programmed process involving complex mechanisms that manifest themselves in various stages from blood clotting to inflammation, cellular proliferation, angiogenesis, and reconstruction of extracellular matrix.<sup>4-7</sup> Biologically, healing of skin wounds undergoes three general stages: inflammatory, proliferative and repair and remodeling. In this complex biological process the interaction of growth factors and some of tissue repair cells such as fibroblasts, epithelial cells and endothelial cells plays a key role.<sup>8-10</sup>

Care of the wound itself should be designed to: promote spontaneous healing, prevent further tissue loss, prevent infection, provide optimal conditions for surgery if required, be as painless as possible, be acceptable to the patient needs.<sup>11</sup> Most of the early treatment modalities include topical application of medicament, mainly aimed at preventing infections. Improving the methods of wound healing and tissue repair offers tremendous opportunities to enhance the quality of life for trauma and burn patients. It may also help to reduce health care cost.<sup>1</sup>

Bone marrow (BM) can be a possible beneficial material for wound healing, because it contains multipotential progenitor cells and produces growth factors.<sup>12</sup> In the field of plastic surgery, there are some experimental evidence of the efficacy of therapeutic angiogenesis by bone marrow cells in salvaging flaps after ischemia-reperfusion injury.<sup>13</sup>

There are some investigations, in which the role of BM and BM progenitor cells in wound healing has been documented.<sup>13,15-17</sup> In this study we have evaluated the role of fresh autogenous bone marrow in the healing of experimental skin burn.

## Materials and Methods

### *Animals*

This study was carried out on 20 adult male white New Zealand rabbits, weighed 1.8-2 Kg. The animals were housed individually under controlled conditions (temperature 22° C, humidity 45% and 12 hours light/dark cycles), and fed standard rodent chop and water *ad libitum*.

### *Wound Creation*

The rabbits were positioned on sternal recumbency and the hair from dorsal thoracic region was removed from an area of 6×2 cm on each side of the animal. Two burn wounds (approximately 1cm<sup>2</sup>) were created under general anesthesia (90 mg/kg Ketamin [Ketamin Hcl 50 mg/ml, Trittau, Germany] plus 10 mg/kg Xylazin [Rompun, 2%, Bayer, AG, Leverkusen]), using a 100 W electric soldering iron, heated to the point of redness (about 800° C) on each side, 4 cm apart. To have a constant pressure when applying the soldering iron, a frame was costumed (fig. 1).

The tip of the iron was kept touched to the skin with a constant pressure for 4 seconds and a burn wound was created on each side of the animal (a total of 80 wounds on 20 rabbits). The wounds on left side of the animals were considered as control and the ones on the right side as treatment (40 wounds for each group).

#### *Postoperative Care and Treatment*

The animals were divided randomly into two equal groups to study the wounds on seven and 14 days. 2 mg/kg morphine (Morphine, 10 mg/ml, Darou Pakhsh, Iran), was injected intramuscularly twice daily for four days to control pain. The scab was removed from the wound 48 hours after the wound creation, when daily rinsing the wounds with normal saline began and continued until the end of the study.


48 hours after the wound creation, under general anesthesia, the left tibial plateau of the animals was surgically prepared, a 0.7 mm hole was drilled on the bone and 1 ml bone marrow (BM) aspirated. The BM was then injected around the wounds of the right side (treatment group) at four points, (0.2 ml at each site), using a gauge 20 needle. The same amount of normal saline was injected around the wounds of the left side (control group).

Half of the animals were euthanized on day 7 by intracardiac injection of 10 mg/kg thiopental sodium (Nesdonal, 500 mg, Specia, Paris), and the rest, on day 14 for biomechanical and histopathological evaluations.

#### *Evaluations*

**Histopathology:** The anterior wounds were considered for histopathological studies. The regenerated tissues were cut in the form of square pieces along with normal skin on either side of the wound and preserved in 10% buffered formalin. Following routine preparation of tissues, sections were stained with hematoxylin and eosin and studied under light microscope.

**Biomechanics:** The posterior wounds were considered for biomechanical studies. A strip of skin, 7 cm long, with the same width of wound diameter, in the manner that the wound was located at the middle of the strip, and perpendicular to the long axis of the body was removed by a double-blade scalpel. The skin was then wrapped in Ringer's soaked gauze, aluminum foils and plastic bags and kept in -20°C freezer until tensile testing. The samples were defrosted by keeping them in room temperature. The samples were then mounted in a Stograph mechanical test frame (Toyoseiky Tensile Testing Unit, model R3, Japan) fitted with appropriate clamps, the distance between the clamps at the start of testing being 4 cm. The strips were loaded with 0-50 kg load cell, with strain rate of 1cm/min, and the load-elongation curves were drawn. The following parameters were measured from the load-elongation curves: yield strength (yield point) (kg), ultimate strength (kg), maximum stored energy (kg.cm), and stiffness (kg.cm).



**Figure 1.** Customized frame to make a constant pressure of soldering iron. The rabbits were put on the lower plate. The upper plate was movable and adjusted so as the tip of iron just touched the skin.

## Results

Histopathology: on day seven, both groups showed complete necrosis of epidermis and superficial dermis. Hair follicles, sebaceous glands and other skin adnexa could not be seen in either group. There was only a mild infiltration of inflammatory cells in treatment group (figs. 2 and 3)

On day 14, re-epithelialization could be seen in both groups, but it was more prominent in treatment group. Acanthosis could also be seen in this group. Like day seven, hair follicles, sebaceous glands and other skin adnexa could not be seen in either group (figs. 4 and 5).

Biomechanics: There was no significant difference between the groups on day seven in each of the biomechanical parameters ( $P>0.05$ ); whereas, all the biomechanical parameters were significantly higher in treatment group, on day 14 ( $P\leq 0.05$ ) (table 1).

## Discussion

There are three mechanisms that energy transfers by: conduction, convection and radiation. All of these mechanisms affecting heat transfer may deliver heat to, or away from, living tissues. Sustained temperatures result in cellular dysfunction and early denaturation of protein. As the temperature or the time of exposure increases, then cell damage increases. Impairment of blood flow in the zone of stasis can occur from shortly after the burn injury up to 48 hours post-burn.<sup>18</sup> If blood flow is compromised, this may lead to the eventual necrosis of cells in this zone.<sup>19</sup> We removed the scab from over the wound 48 hours burn induction, when blood flow in the wound was not still so prominent, because maximum inflammation can be seen in the burn wounds at 7-10 days post-injury,<sup>18</sup> and it has been shown that early burn wound excision and grafting can result in decreased morbidity and mortality.<sup>20-22</sup>

**Table 1.** Biomechanical parameters in treatment and control groups  $\pm$  standard deviation (SD).

	Day 7				Day 14			
	Y.P	U.S.	Stiffness	M.S.E	Y.P.*	U.S.*	Stiffness*	M.S.E*
<b>Treatment</b>	1.32 $\pm$ 0.33	3.75 $\pm$ 0.95	1.07 $\pm$ 0.22	1.51 $\pm$ 0.58	2.37 $\pm$ 0.35	5.63 $\pm$ 1.47	1.61 $\pm$ 0.36	2.87 $\pm$ 0.32
<b>Control</b>	1.15 $\pm$ 0.19	3.42 $\pm$ 1.04	1.03 $\pm$ 0.17	1.31 $\pm$ 0.48	1.85 $\pm$ 0.37	4.21 $\pm$ 0.75	1.05 $\pm$ 0.19	1.81 $\pm$ 0.56

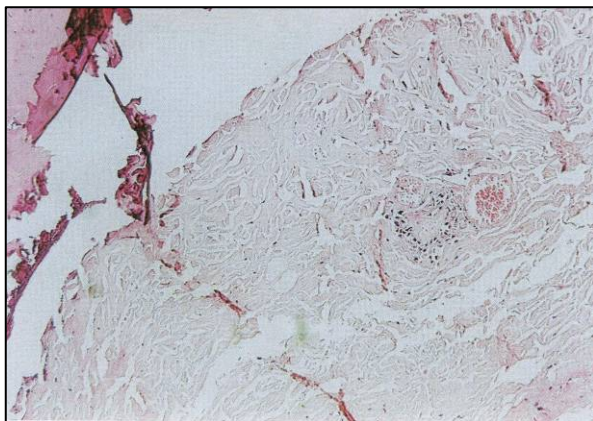
Y.P: Yield Point

U.S: Ultimate Strength

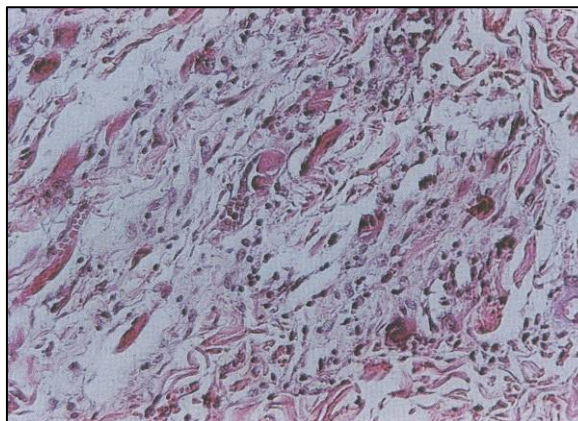
M.S.E: Maximum Stored Energy

\*: Significant difference between the groups ( $P\leq 0.05$ )

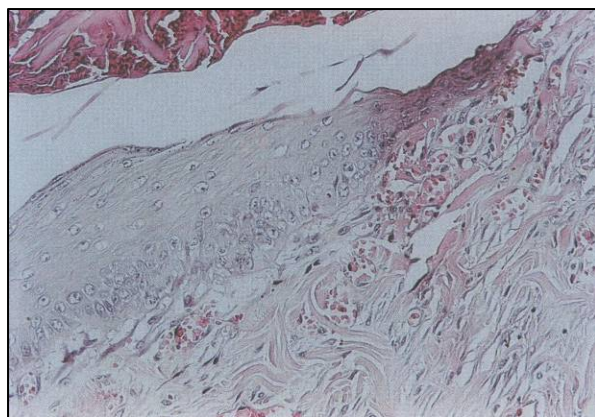
During the wound healing process, an abundant blood supply is necessary to meet the enormous local demands of debridement, fibroblast proliferation, extracellular matrix synthesis, and epithelialization.<sup>23-26</sup> Impairment of blood supply may be a contributing factor in delayed healing, or nonhealing, in chronic wounds such as diabetic foot ulcers, pressure ulcers, and wound caused by chronic and acute arterial occlusion.<sup>23</sup> Recent advances in the understanding of neovascularization have made angiogenesis a prime target for therapeutic manipulation in wound



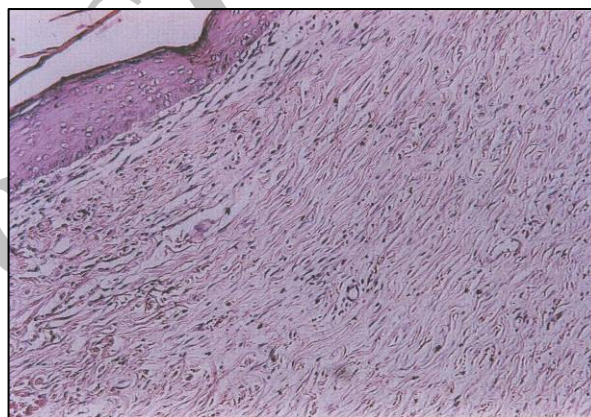
**Figure 2.** Control group, day 7. Necrosis of epidermis and superficial dermis. No hair follicle can be seen. (H&E,  $\times 100$ )



**Figure 3.** Treatment group, day 7. Edema and mild changes in the skin musculature. There is a mild infiltration of inflammatory cells (H&E,  $\times 200$ )



**Figure 4.** Control group, day 14. Beginnig of the re-epithelialization with a mild hyperemia. (H&E,  $\times 200$ )



**Figure 5.** Treatment group, day 14. Re-epithelization is well progressed, and re-organization of the dermis by newly formed collagen fibers. (H&E,  $\times 200$ )

healing. Efforts have been made to induce or stimulate new blood vessel formation in order to reduce the unfavorable tissue effects caused by local ischemia or to enhance tissue repair.<sup>27-29</sup> Ichioka *et al*, showed that bone marrow-impregnated collagen matrix can promote the wound repair process through augmentation of angiogenesis.<sup>12</sup> Bone marrow plays this role possibly because of its multipotential progenitor cells and production of growth factor.<sup>12</sup> Badiavas and Falanga have also reported successful treatment of chronic ulcers in three cases by spreading autogenous bone marrow aspirate directly on the wound and injecting it into the edges of the wound.<sup>14</sup>

In our study there was no difference between the two groups on day seven, histopathologically, except less prominent inflammation on treatment group which can be attributed to the faster healing process in this group. On day 14, the rate of healing and also the quality of healing tissue; manifested by biomechanical parameters was superior in treatment group, which shows the positive effect of BM injection around the wound edge. Higher biomechanical parameters in treatment group is due to enhanced synthesis of collagen. Collagens are the main extracellular

component of the skin. During the proliferative phase of skin wound healing, the synthesis of different proteins of particularly collagen subtypes within wounds increases to replace necrotic tissue.<sup>30,31</sup> Collagen not only confers strength and integrity to the tissue matrix, but also plays an important role in homeostasis and epithelialization at the later phase of healing. Therefore, enhanced synthesis of collagen provides strength to repaired tissue and also healing pattern.<sup>32,33</sup>

Although other reported materials such as growth factors<sup>34,35</sup> and cultured cells<sup>36,37</sup> must also significantly reinforce the ability of collagen matrix to accelerate angiogenesis in wound healing, from a practical standpoint, the use of bone marrow is more attractive because we can use the patient's own fresh cells with routine aspiration technique, allowing minimal systemic side effects.<sup>12</sup>

It can be concluded that this simple method, which is immediately applicable without any processing procedure, and the preservation of the inclusive ability of bone marrow, containing cells and cytokines, can be considered beneficial for the burn wound healing.

### Acknowledgement

The authors would like to thank the Research Council of Shahid Bahonar University of Kerman for funding the research. The authors are also grateful to Mr. Moshrefi, the General Manager of Barez Tire Company, for his kind cooperation in the biomechanical testing.

### References

1. Srivastava P, Durgaprasad S. Burn wound healing property of *Cocos nucifera*: An appraisal. *Indian J Pharmacol* 2008; 40: 144-146.
2. Bingham HG, Hudson D, Popp J. A retrospective review of the burn intensive care admission for a year. *J Burn Care Rehabil* 1995; 16: 56-58.
3. McGill V, Kowal-Vern A, Fisher SG, et al. The impact of substance use on mortality and morbidity from thermal injury. *J Trauma* 1995; 38: 931-934.
4. Xiaobing FU, Zuyao S, Yulin C, et al. Recombinant bovine basic fibroblast growth factor accelerates wound healing in patients with burn donor sites and chronic dermal ulcers. *Chin Med J* 2000; 113: 367-371.
5. Cohen IK. An overview of wound healing biology. In: Ziegler TR, Pierce GF, Herndon DN, eds. *Growth factors and wound healing basic science and potential clinical applications*. New York: Springer, 1997: 3-7.
6. Lazanus GS, Copper DM, Knighton DR, et al. Definition and guidelines for assessment of wounds and evaluation of healing. *Arch Dermatol* 1994; 130: 489-493.
7. Blumenfeld I, Ullmann Y, Laufer D, et al. Enhancement of burn healing by growth factors and IL-8. *Ann Burn Fire Disast* 2000; 8: 34-37.
8. Bennett NT, Schultz GS. Growth factors and wound healing biochemical properties of growth factors and their receptors. *Am J Surg* 1993; 165: 728-773.
9. Bennett NT, Schultz GS. Growth factors and wound healing part II. Role in normal and chronic wound healing. *Am J Surg* 1993; 166: 74-81.
10. Steed DL, Group DUS. Clinical evaluation of recombinant human platelet-derived growth factor for the treatment of lower extremity diabetic ulcers. *Vas Surg* 1995; 21: 71-81.

11. Kavanagh S, de Jong A. Care of burn patient in the hospital. *Burns* 2004; 30: A2-A6.
12. Ichioka S, Kouraba S, Sekiya N, et al. Bone marrow-impregnated collagen matrix for wound healing: experimental evaluation in a microcirculatory model of angiogenesis, and clinical experience. *Br J Plast Surg* 2005; 58: 1124-1130.
13. Ichioka S, Kudo S, Shibata M, et al. Bone marrow cell implantation improves flap viability after ischemia-reperfusion injury. *Ann Plast Surg* 2005; 52: 414-418.
14. Badiavas EV, Falanga V. Treatment of chronic wounds with bone marrow-derived cells. *Arch Dermatol* 2003; 139: 510-516.
15. Velazquez OC. Angiogenesis and vasculogenesis: Inducing the growth of new blood vessels and wound healing by stimulation of bone marrow-derived progenitor cell mobilization and homing. *J Vasc Surg* 2007; 45: 39A-47A.
16. Bauer SM, Goldstrein LJ, Bauer RB, et al. The bone marrow-derived endothelial progenitor cell response is impaired in delayed wound healing from ischemia. *J Vasc Surg* 2006; 43: 134-141.
17. Mori L, Bellini A, Stacey MA. Fibrocytes contribute to the myofibroblast population in wounded skin and originate from the bone marrow. *Exp Cell Res* 2005; 304: 81-90.
18. Nguyen N, Gun R, Sparnon A, et al. The importance of immediate cooling – a case series of childhood burns in Vietnam. *Burns* 2002; 28: 173-176.
19. Schwacha MG, Nickei E, Daniel T. Burn injury-induced alterations in wound inflammation and healing are associated with suppressed hypoxia inducible factor-1 $\alpha$  expression. *Mol Med* 2008; 14: 628-633.
20. Ryan CM, Yarmush ML, Burke JF, et al. Increased gut permeability early after burns correlates with the extent of burn injury. *Crit Care Med* 1992; 20: 1508-1512.
21. Herndon DN, Zeigler ST. Bacterial translocation after thermal injury. *Crit Care Med* 1993; 21: S50-S54.
22. Eaves-Pyles T, Alexander JW. Rapid and prolonged impairment of gut barrier function after thermal injury in mice. *Shock* 1998; 9: 95-100.
23. Liapakis I, Anagnostoulis S, Karayiannkis A, et al. Burn wound angiogenesis is increased by exogenously administered recombinant leptin in rats. *Acta Cir Bras* 2008; 23: 118-124.
24. Thompson WD, Harvey JA, Kazmi MA, et al. Fibrinolysis and angiogenesis in wound healing. *J Pathol* 1991; 165: 311-318.
25. Arnold F, West DC. Angiogenesis in wound healing. *Pharmacol Ther* 1991; 52: 407-422.
26. Bodary PF, Westrick RJ, Wickenheiser KJ, et al. Effect of leptin on arterial thrombosis following vascular injury in mice. *JAMA* 2002; 287: 1706-1709.
27. Konstantinides S, Schafer K, Neels JG, et al. Inhibition of endogenous leptin protects mice from arterial and venous thrombosis. *Arterioscler Thromb Vasc Biol* 2004; 24: 2196-2201.
28. Bodary PF, Shen Y, Ohman M, et al. Leptin regulates neointima formation after arterial injury through mechanisms independent of blood pressure and the leptin receptor/STAT3 signaling pathways involved in energy balance. *Arterioscler Thromb Vasc Biol* 2007; 27: 70-76.
29. Torsney E, Mayr U, Zou Y, et al. Thrombosis and neointima formation in vein grafts are inhibited by locally applied aspirin through endothelial protection. *Circ Res* 2004; 94: 1466-1473.

30. Kondo T. Timing of skin wounds. *Legal Med* 2007; 9: 109-114.
31. Lu WW, Ip WY, Jing WM, et al. Biomechanical properties of thin skin flap after basic fibroblast growth factor (bFGF) administration. *Br J Plast Surg* 2000; 53: 225-229.
32. Oloumi MM, Derakhshanfar A, Molaei MM, et al. The healing potential of oleaster leave water soluble extract on experimental skin wounds in the rat. *IJVS* 2007; 2: 65-73.
33. Nayak BS, Udupu AL, Udupa SL. Effect of *Ixora coccinea* flower on dead space wound healing in rats. *Fitoterapia* 1999; 70: 233-236.
34. Ono I, Tateshita T, Inoue M. Effects of a collagen matrix containing basic fibroblast growth factor on wound contraction. *J Biomed Mater Res* 1998; 6: 621-630.
35. Tateshita T, Ono I, Kaneko F. Effects of collagen matrix containing transforming growth factor (TGF)-beta(1) on wound contraction. *J Dermatol Sci* 2001; 25: 104-113.
36. Kubo K, Kuroyanagi Y. Development of a cultured dermal substitute composed of a spongy matrix of hyaluronic acid and atelo-collagen combined with fibroblasts: cryopreservation. *Artificial Organs* 2004; 28: 182-188.
37. Kuroyanagi Y, Kenmochi M, Ishihara S, et al. A cultured skin substitute composed of fibroblasts and keratinocytes with a collagen matrix: preliminary results of clinical trials. *Ann Plast Surg* 1993; 31: 340-349.



## ارزیابی نقش مغز استخوان خودی در التیام سوختگی تجربی در خرگوش

محمد مهدی علمی<sup>۱</sup>، امین درخشانیفر<sup>۲</sup>، هانی شمالی<sup>۱</sup>، مرضیه شاولیان<sup>۱</sup>

<sup>۱</sup> گروه علوم درمانگاهی و <sup>۲</sup> گروه پاتوبیولوژی، دانشکده دامپزشکی دانشگاه شهید باهنر کرمان، کرمان، ایران.

**هدف** - ارزیابی هیستوپاتولوژیک و بیومکانیک نقش مغز استخوان خودی در التیام سوختگی تجربی در خرگوش.

**طرح مطالعه** - مطالعه تجربی در حیوان زنده.

**حیوانات** - ۲۰ سر خرگوش سفید نیوزیلندی.

**روش کار** - تحت بیهوشی عمومی دو سوختگی متحد الشکل در طرفین پشت حیوانات به فاصله ۴ سانتی متر از یکدیگر با استفاده از هویه (حرارت ۸۰۰ درجه سانتیگراد) ایجاد گردید. برای کنترل درد مورفین (۲ mg/kg, IM) دو بار در روز به مدت ۴ روز تزریق گردید. دلمه زخم ۴۸ ساعت پس از ایجاد زخم برداشته شد و شستشوی زخم با نرمال سایلین روزانه تا پایان مطالعه انجام گرفت. ۴۸ ساعت پس از ایجاد زخم ۱ میلی لیتر مغز استخوان از قسمت فوقانی استخوان درشت نی چپ جمع آوری و در چهار نقطه اطراف زخم های گروه درمان تزریق گردید (۰/۲ میلی لیتر در هر نقطه). همان میزان سایلین نرمال در اطراف زخمهای گروه شاهد تزریق شد. نیمی از حیوانات در روز ۷ و نیم دیگر در روز ۱۴ برای ارزیابی های هیستوپاتولوژیک و بیومکانیک قربانی شدند.

**نتایج** - از نظر هیستوپاتولوژیک در روز ۷ در هر دو گروه نکروز کامل اپیدرم و قسمت سطحی درم مشاهده گردید. در گروه درمان نفوذ ملایم سلول های آماسی مشاهده شد. در روز ۱۴ بازسازی اپیتلیوم در هر دو گروه مشاهده گردید اما شدت آن در گروه درمان بیشتر بود. از نظر بیومکانیک در روز ۷ اختلاف معنی داری بین دو گروه وجود نداشت در حالیکه همه فاکتورهای بیومکانیکی در روز ۱۴ افزایش معنی داری را در گروه درمان نشان دادند. بر این اساس می توان چنین نتیجه گیری نمود که مغز استخوان خودی می تواند سبب تشدید روند التیام زخم های سوختگی گردد.

**نتیجه گیری و کاربرد بالینی** - استفاده از این روش آسان و قابل بکارگیری می تواند در تمامی شرایط برای تسریع روند التیام زخم های سوختگی مد نظر قرار گیرد.

**کلید واژگان** - سوختگی، التیام، مغز استخوان.