



Original Article

**Autologous Platelet Rich Plasma Injection Improves Early Tendon Repair in Rabbits: A
Histopathological and Biomechanical Study**

Sara Javanmardi^{1*}, Amirata Vosough², Raziallah Jafari Jozani¹

Abstract

Objective- The aim of this study was to investigate the PRP effects on the early time-period during tendon healing in rabbits DDF tendon.

Design- Experimental study

Animals- Twenty male New Zealand white rabbits

Procedure- PRP samples were prepared using twice centrifugation method of modification of the Cuarsan technique. Animals were randomly assigned into two equal treatment and control groups. The injury model was unilateral complete transection through the middle one third of deep digital flexor tendon. Immediately after primary repair, either 0.5 mL PRP or placebo was injected intratendously into the suture site in the treatment and control groups, respectively. Operated limbs were immobilized for two weeks. Animals were sacrificed at the third week and the tendons underwent histopathological (H&E and MT staining) and biomechanical evaluation.

Results- The histopathological (H&E) observation showed significant increase in percentage of fibrillar linearity, fibrillar continuity, number of capillaries in epitenon and epitenon thickness in PRP treated group compared to the control group ($P<0.05$). Results from MT staining revealed more collagen deposition, in treatment group in comparison with the control. Results of mechanical testing revealed the significant improvement of force at failure and energy absorption capacity of repair in the PRP group in comparison with the control ($P<0.05$).

Conclusion and clinical relevance- The findings of the present study suggested that PRP was a simple, safe, quick and cost effective way to obtain a natural concentration of autologous growth factors which reduced the risk of rupture after tendon primary repair and improved functional outcomes.

Keywords- Platelet rich plasma, DDF tendon, Rabbits

Received: 20 July 2017; **Accepted:** 26 August 2017; **Online:** 26 September 2017

Introduction

Tendon injuries are among the most prevalent musculoskeletal conditions.¹ Surgical repair of the ruptured tendon is essential, however, the repair is inefficient. The limitation factors of the successful resolution of tendon lesions include: tendon heals slowly

in approximately 8-12 weeks, the structural and mechanical properties of the healed tendon are less satisfactory than the normal tendon, and there is high probability of the occurrence of the lesion.^{2,3} Tendon repair is a complicated process which starts, continues and ends by the means of various mediators.^{4,5}

The growth factors are among the most significant mediators involved in healing that optimize the strength of healed tendons. At the beginning of tendon healing process, growth factors are temporarily elevated in the injured site and initiate and stimulate the healing process and decrease in

¹Department of Clinical Sciences, Faculty of Veterinary medicine, University of Tabriz, Tabriz, Iran.

²Graduated of Veterinary Medicine, Faculty of Veterinary medicine, University of Tabriz, Tabriz, Iran.

Address all correspondence to Sara Javanmardi (DVM, DVSc)

E-mail: s.javanmardi@tabrizu.ac.ir

www.ivsajournals.com © Iranian Journal of Veterinary Surgery, 2017

This work is licensed under the terms of the Creative Commons Attribution (CC BY-NC-SA 4.0)

DOI: 10.22034/ivsa.2017.50348

number with time.^{6,7} Reportedly, a delay of time-dependent decrease in blood derived products, can improve tendon healing.⁸ Exogenous growth factors therapy is regarded to be a means of enhancing cellular response to injury within the tendon, and ultimately the quality of the repair.⁹ Blood platelet released cocktail of growth factors such as the platelet-derived growth factor, transforming growth factor, fibroblastic growth factor, vascular endothelial growth factor, insulin-like growth factor, and epidermal growth factor when activated. PRP is an autologous concentration of platelets in a small volume of plasma.^{10,11} Clinically, there is a great demand to improve and accelerate the early time-period during tendon healing, as the re-rupture of repaired tendons occurs during the early healing stages. Therefore, we aimed to determine whether a local injection of PRP could improve the early stage healing of the tendon in rabbits DDF tendon cut model.

Materials and methods

Animals

Twenty adult male New Zealand White rabbits, weighing 2.2-2.5 kg were used in this study. Rabbits were adapted to handling in the period prior to surgery. The animals were kept in temperature of 22 ± 3 °C, humidity ($60 \pm 5\%$) and a 12h light/dark cycle. The procedures were performed based on the guidelines of the Ethics Committee of the International Association for the Study of pain.¹² The University Research Council approved all of the experiments. The animals were randomly divided into two equal groups with ten rabbits in each group.

PRP preparation

PRP samples were prepared using a modification of the Curasan technique.¹³ The 6 ml autologous blood drawn from each rabbit was combined with 0.5 ml of anticoagulant citrate dextrose phosphate (ACD-A) to prevent coagulation. The blood was centrifuged at 1,200 rpm (160g) for 20 minutes to separate the plasma containing the platelets from the red cells. The plasma was drawn off the top, centrifuged for an additional 15 minutes at 2,000 rpm (400g) to separate the platelets. The platelet poor plasma was separated from the PRP along with the buffy coat. Platelet count was performed on each sample, including a peripheral blood count and PRP count.

Surgical procedure

All rabbits were anesthetized with 35 mg/kg, IM, Ketamine 5% (Alphasan, Woerden, Holand), 5 mg/kg, IM, Xylazine 2% (Alphasan, Woerden, Holand) and 1

mg/kg, IM, Acepromazine 2% (Hoogostraten, Belgium). A longitudinal skin incision was aseptically made exactly over the digital flexor (DDF) tendon. A complete horizontal incision cut was made through the midsubstance of the DDF tendon. This incision was instantly repaired with a locking-loop pattern. Immediately after the primary repair, 0.5 mL PRP and placebo was injected intratendinously, into the suture site in the treatment and control group, respectively. Skin closure was done in a routine manner. The limbs which underwent surgery were immobilized for two weeks. Three weeks after the operation all of the animals were sacrificed with thiopental sodium overdose (50 mg kg^{-1} , IV, Sandoz, Austria) and tendon samples were harvested for histopathological (H&E and Masson's Trichrome staining) and biomechanical evaluations. For biomechanical studies, the DDF tendon samples from both limbs were harvested, wrapped in PBS soaked gauze and immediately stored at -20 °C.

Histomorphometric analysis

Paraffin-embedded longitudinal sections were stained with hematoxylin and eosin (H&E) and Masson's Trichrome and were evaluated under a light microscope based on the following criteria: fibrillar linearity, fibrillar continuity, and angiogenesis in neotendon and epitenon, and epitenon thickness. The healed areas involving the longitudinally aligned collagen fibers were histologically evaluated. In this regard, the total area of neotendon between the severed ends of tendons was measured at $40\times$ magnification and the area consisting the longitudinal pattern of collagen fibers was calculated. The ratio of the values was defined as the percentage of fibrillary linearity for each tendon. The width of the broadest part of neotendon involving the fibers in the direction of those in the original tendon was assessed at $40\times$ magnification in both tendon-neotendon junctions and the ratio of their mean to the mean width of junctions was determined as the percentage of fibrillary continuity for each specimen. To investigate the number of angiogenesis within the neotendon and newly established epitenon, the quantity of blood capillaries was determined at $100\times$ magnification. For this assessment, five randomly chosen files were examined per each tendon sample. The number of capillaries was averaged and reported for each specimen. The epitenon thickness was measured at $100\times$ magnification in three randomly selected points of epitenon on both sides of neotendon and the records were averaged for each specimen.¹⁴

Biomechanical analysis

Ten tendons (five operated and five non-operated from the contralateral limb) from every one of the groups were submitted to the mechanical test of traction. The tendon from the non-operated leg was taken for comparison. Prior to mechanical testing, tendons were permitted to thaw while they were made wet in PBS immersed for 2 hours at room temperature. All tendons from the studied groups were submitted to the mechanical test of traction using the testing machine (Series Z010; Zwick GmbH & Co. KG, Ulm, Germany). In order to prevent tendon slippage during tensile testing, 360 grit sandpaper was attached to the end of each specimen for better clamping. The upper clamp was attached to a 500 N load cell and its displacement was controlled with a computer. The dynamic testing took place under axial tension with a constant speed of 50 mm/minute.¹⁵ The mechanical testing involved a single-cycle-to-failure. The power and elongation of the tendon were repeatedly measured until tendon lost its force. The manner of failure was optically perceived and recorded. For every tendon the force-elongation curve was formed and the following mechanical parameters were gained: force at failure (N), energy absorption capacity (N.mm) and stiffness (N.mm⁻¹). The data were calculated as a percentage of values of healing tendon as non-operated contralateral in comparison with the limb to the same animal rather than using absolute testing values, in order to minimize the biological variation of tensile stress among individuals.¹⁶ The force at failure was determined as the utmost strength assessed in the tendon during the failure test. The values of energy absorption were evaluated by the measurement of the area under the force at maximum slope in the linear part of the force-elongation curve. Stiffness was established as the maximum slope in the linear part of the force-elongation curve.¹⁷

Statistical analysis

Statistical analysis was performed using Student's t-test, employing Graph Pad Prism, version 5.05 (Graph Pad software, San Diego, CA, USA). Experimental results were expressed as mean \pm SD. The differences were regarded to be significant when $p < 0.05$.

Results

Platelet counts

Platelet counts confirmed that the preparation technique used in this study created a source of extremely concerted platelets with the collection efficiency of 35/13% (4.08). The average (standard deviation)

peripheral blood platelet count and average PRP platelet were 273811(43199)/mm³ and 1118006 (131695)/mm³, respectively (Fig. 1).

Clinical results

None of the rabbits died during the study period. There were no evidence of the presence of the clinical complications such as local infection and wound dehiscence. In addition, there was no adhesion formation between the tendons and their surrounding tissue in the PRP group. However, noticeable adhesion was seen in the control group.

Histopathologic results

The histomorphometric results of this study are presented in Table 1. PRP treated tendons showed superior healing process than the controls. Furthermore, the matrix appeared more organized and aligned with the extended axis of the tendon (fibrillar linearity) ($P = 0.027$). In addition, PRP treated group revealed a higher rate of fibrillar continuity at the repaired site in comparison with the control group ($P = 0.0005$) (Fig. 2A vs. 2B). However, the control specimens exhibited remarkable disorganized matrix showing disruption of the normal linear direction of collagen bundles and characterized by displaying fibril in an irregular pattern in comparison with the treatment group. The gradual increase in cellularity was seen in PRP treated group. The orientations of nuclei indicated that, in these areas, the cells in PRP group were arranged in line with the long axis of the tendon and that was not seen in the control group (Fig. 2C vs. 2D). PRP treated group showed greater neovascularization of neotendon than the control group, however, this difference did not reach statistical significance ($P = 0.066$). Epitenon thickness and its neovascularization were also significantly increased in treatment group ($P = 0.013$ and $P = 0.002$), respectively. Finally, more collagen deposition was observed in the PRP treated group in comparison with the control group according to the Masson's trichrome stain tendons sections. The significant difference in collagen deposition was demonstrated in Fig. 3A, B.

Mechanical analysis

PRP treated group showed an increase in force at failure ($P = 0.005$) and energy absorption ($P = 0.031$) as compared to controls. PRP treated group showed greater stiffness than the control group, however, this difference did not reach statistical significance ($P = 0.055$).

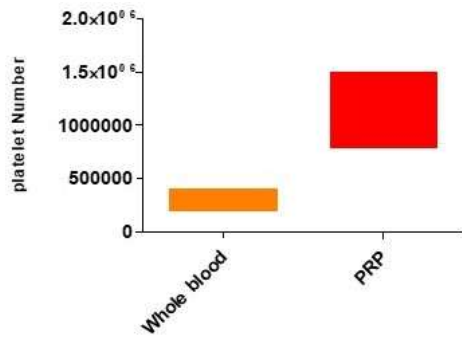


Figure 1. The box plot shows the change in platelet count in the process of PRP preparation

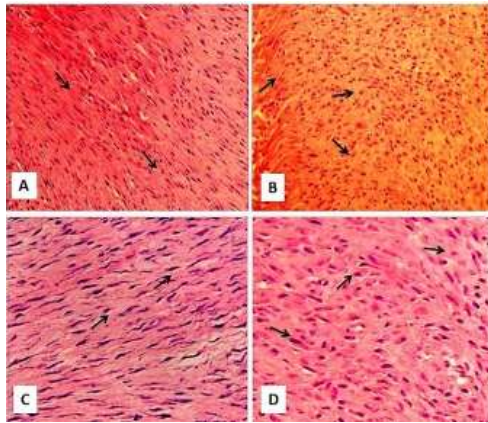


Figure 2. Photomicrographs demonstrating the differences in the histological appearances between the groups. Parallel orientation of collagen fibers in treatments indicating superior remodeling of neotendon (A) compared to controls (B). There was increased cellularity which changes in cell morphology. Arrows show the cells, in PRP group arranged in line with the long axis of the tendon, well oriented collagen clearly was seen. (C) Such a well-organized structure was not seen in control group (D) (H&E, 100×).

Discussion

Circulation-derived mediators such as growth factors have a key role in the healing processes of tissues.⁶ In the initial stage of tendon healing process, growth factors are temporarily elevated in the injured area to initiate the healing process and decrease in number with time. Reportedly, a delay of time-dependent decrease in blood derived products, could improve tendon healing.^{7,8} Therefore, PRP therapy provides possibility of access to an autologous source of growth factors to optimize tendon healing. PRP contains a higher concentration of platelet levels in the whole blood. About 4-5 times more than the baseline concentration was enough to improve tissue healing.^{10, 11, 19} A platelet concentration of




Figure 3. Representative figures for mature collagen synthesis from control group (A) and PRP group (B). Masson's Trichrom stain. Original Magnification x100. Blue staining resembles mature collagen. (B) demonstrates a generally well-structured tendon. (A) shows weaker blue staining than (B) indicating less collagen deposition.

obtained PRP in this study was about 4.08 times higher than the baseline concentration when compared to the whole blood. Not all PRP were the same. PRP that has not been activated may be the appropriate form. Activation of PRP by the thrombin and or calcium before application, however, results in the rapid discharge of growth factors, which may not be ideal. The collagen within musculoskeletal tissues like tendons may activate the platelet slowly, resulting in a sustained release of growth factors.^{19,20}

Therefore, in this study we used the non-activated form of PRP. The results of the present study showed that the injection of PRP to the site of tendon rupture could improve structural and histological properties of rabbits DDF tendon. This effect was probably due to the growth factors that are released from the platelet. Mature tendons were poorly vascularized.²¹ Kakar et al. reported that the early stages of healing were characterized by a marked increase in vascularity, in which neovascularization provides the delivery of the inflammatory mediators to the wound site.²² Wounding promotes the release of the growth factors and cytokines from platelet, macrophages, and other inflammatory mediators. These growth factors prompt the chemotaxis and neovascularization of the fibroblasts and tenocytes. The injection of PRP into the mouse leg ischemia model intensifies the angiogenesis and blood reperfusion of ischemic tissues in comparison with the control group.²³ The neovascularization was greater in the PRP treated group in comparison with the control group, however, this increase was not significant between the groups. The angiogenic effect of PRP is ascribed to the presence of vascular endothelial growth factor and fibroblast growth factor which are crucial for stimulating angiogenesis to bring nutrients and progenitor cells to the injury site.^{24, 25} Both intrinsic and extrinsic mechanisms are likely to play a key role in the healing process in tendon.

Table 1. Results of histomorphometric analysis (mean \pm SD) of repairs three weeks after surgery.

Groups	Treatment 3 W.	Control 3 W.
Fibrillar Linearity (%)	5.26 ^a \pm 53.2	4.09 ^{ab} \pm 35.2
Fibrillar Continuity(%)	2.65 ^a \pm 53.4	3.82 ^b \pm 27.40
No. Of Capillaries In Neotendon	2.6 \pm 29.4	6.7 \pm 23
No. Of Capillaries In Epitenon	5.01 \pm 56.8	3.16 \pm 38.0
Epitenon Thickness	2.24 ^a \pm 21.6	1.77 ^b \pm 8.8

^{ab}Values with different symbol in each column are significantly different (p<0.05).

The intrinsic mechanism involves proliferation of tenocytes from the epitenon and endotenon. These tenocytes help to synthesize the new extracellular matrix. Such innate healing causes less restrictive formation of the adhesions and enhances the biomechanics of neotendon. On the other hand, the extrinsic mechanism includes the movement of inflammatory cells and fibroblasts from the sheath and synovium into the lesion site to engender scar tissue and causes less satisfactory biomechanics and adhesion formation which prevents tendon gliding. Neovascularization and proliferation of fibroblasts in the synovial layer of epitenon and wound site lead to an increase in the epitenon thickness and accelerate the healing of tendon. That is one mechanism which improves the intrinsic healing activity of the tendon.^{26, 27} In this study, in addition to the increased neovascularization in neotendon, the higher rate of angiogenesis within epitenon and also the increase of epitenon thickness was seen in the PRP treated group, which could suggest the positive effects of PRP in the improvement of the intrinsic healing capacity of ruptured tendon. During tendon repair, the defect site is replaced with new tendinous tissue, composed mainly of collagen fibers. This form of neotendon consists of randomly oriented and less organized collagen fibers. With time, collagen fibers are organized in parallel arrays along the line of stress, which take around six weeks, in normal conditions.^{26,28} whereas in the present study PRP injection accelerated the occurrence of this event in the treatment group compared to the control group, as was demonstrated by the significant increase in fibrillar linearity. The goal of tendon repair is the tendon continuity and function, as well as, the intrinsic mechanism which is responsible for the

reorganization of the collagen fibers and the maintenance of fibrillar continuity.²⁹ In the present study, PRP application clearly resulted in an increase in fibrillar continuity in the treatment group. Reportedly, platelet-derived growth factor (PDGF) and transforming growth factor (TGF) increase collagen production by tendons.³⁰ Thus, these growth factors in PRP could increase the synthesis of collagen fibers as was found by more collagen deposition in the Masson's Trichrome staining in PRP treated group in comparison with the control group in this study.³¹ The goal of tendon healing is to produce an anastomosis of great tensile strength.³² Studies have shown that the epitenon is the most proliferative structure in the tendon repair process and plays a crucial role in the healing process via extracellular matrix production, including type I collagen in the repair site.^{26,27} PRP promotes proliferation and activity of epitenon cells that lead to improved collagen synthesis and fiber orientation, results in increased tendon mechanical properties³³, which we found in the present study. Application of PRP in rats Achilles tendons improved not only collagen production in healed tendons, but also their tensile strength.³⁴ Hence, the re-rupture of a repaired tendon which commonly occurs early in the repair process as a rapid increase in mechanical strength is important clinically.^{34,36} The present study demonstrated a significant increase in force at failure and energy absorption of PRP treated tendons. These data were in agreement with the results of other studies.^{35, 37, 38} The increased tensile strength could result from the improvement in production and remodeling of collagen fibers in the treatment group.^{26,39} In the present study collagen synthesis increased, however, the major limitation of this study was the lack of collagen type expression data to support our biomechanical results. A stronger tendon exhibits a higher energy storing to eliminate any damages. If this capacity is not enough, the needs in energy absorption and release may rapidly exceed the tendon capacity and may cause an increased danger of lesion. Accordingly, one of the main points in the treatment of tendon lesions is intensifying the energy absorption capacity of the repaired tendon.^{2,40,41} This study showed that PRP therapy caused a significant increase in the energy absorption capacity in the treatment group in comparison with the control group. The present study did not demonstrate any difference in the tendon stiffness among the groups. Collagen cross-links is a key factor in tendon stiffness. An increase in collagen cross-linking causes an increase in

tendon stiffness. Reportedly, the maturation stage of tendon repair occurs after approximately 10 weeks, which includes an increase in collagen fiber crosslinking and the formation of more mature and stiffer tendon.⁴¹⁻⁴³ Accordingly, in the present study, collagen fibers in repaired tendons did not reach the time for appropriate cross-linking at the time of sampling. This result is in line with the other studies⁴⁴. The better structural and mechanical parameters at three weeks in the treatment group suggested that PRP improved the rate of intrinsic mechanism of tendon healing. On the other hand, intratendinous injection of PRP caused the acceleration of early tendon healing process in the DDF tendon rupture. The results of this study showed that PRP was a simple, safe, quick and cost effective way to obtain a natural concentration of autologous growth factors which decreased the risk of rupture after the primary tenorrhaphy and enhance functional outcomes.

Acknowledgments

This study is for DVM thesis at Tabriz Veterinary Medicine Faculty. Authors would like to acknowledge University of Tabriz for financial support of this study.

Conflicts of interest

None.

References

1. Carpenter JE, Hankenson KD. Animal models of tendon and ligament injuries for tissue engineering applications. *Journal of Biomaterial*, 2004; 25:1715-22.
2. Lin LW, Cardenas L, Soslowsky LJ. Biomechanics of tendon injury and repair. *Journal of Biomechanic*, 2004; 37:865-77.
3. Frank C, Donald D, Shrive N. Collagen fibril diameter in the rabbit medial collateral ligament scar: a longer term assessment. *Journal of Connective Tissue Research*, 1997; 36:21-9.
4. Anitua E, Andia I, Ardanza B, Nurden P. Autologous platelet as a source of proteins for healing and tissue regeneration. *Journal of Thrombosis and Haemostasis*, 2004; 91:4-15.
5. Chan PB, Qin L, Lee KM, Rolf CG, Chan KM. Effect of fibroblast growth factor (bFGF) on early stages of tendon healing. *Journal of Acta Orthopedic Scandinavia*, 1999; 71:513-18.
6. Zhang F, Lineaweaver WC. Growth factors and gene transfer with DNA strand technique in tendon healing. *Journal of Long Term Effects of Medical Implants*, 2002; 12:105-112.
7. Abrahamsson SO, Lundborg G, Lohmander LS. Recombinant human insulin-like growth Factor-I stimulates in vitro matrix synthesis and cell proliferation in rabbit flexor tendon. *Journal of Orthopedic Research*, 1991; 9:495-502.
8. Dahlgren LA, Mohammed HO, Nixon AJ. Temporal expression of growth factor and matrix molecules in healing tendon lesion. *Journal of Orthopedic Research* 2005; 23:84-97.
9. Molloy T, Wang Y, Murrell G. The roles of growth factors in tendon and ligament healing. *Journal of Sports Medicine*, 2003;33(5):381-94.
10. Kon E, Filardo G, Delcogliano M, Presti ML, Russo A, Bondi A. Platelet-rich plasma: new clinical application. A pilot study for treatment of jumper's knee. *Injury* 2009;40(6):598-603.
11. Robert EM. Platelet-rich plasma (PRP): what is PRP and what is not PRP. *J Implant Dentistry* 2001;10(4):225-8.
12. Abbasalipour M, Mirjalili M, Khajavi R, Majidi M. Coated cotton gauze with Ag/ZnO/chitosan nanocomposite as a modern wound dressing. *Journal of Engineered Fibers and Fabrics*, 2014;9:124-130.
13. Weibrich G, Kleis WK, Hafner G, Hitzler WE, Wanger W. Comparison of platelet, leukocyte, and growth factor levels in point-of-care platelet enrich plasma, prepared using a modified Curasan kit, with preparations received from a local blood bank. *Clinical Oral Implants Research*, 2003;14(3):357-62
14. Behfar M, Sarrafzadeh-Rezaei F, Hobbenaghi R, Delirez N, Dalirneghadeh B. Adipose derived stromal vascular fraction improves early tendon healing: an experimental study in rabbits. *Journal of Veterinary Research Forum*, 2011;2(4):248-53.
15. Behfar M, Javanmardi S, Sarrafzadeh-Rezaei F. Comparative study on fictional effects of allotransplantation of bone marrow cells and adipose derived stromal vascular on tendon repair: A biomechanical study in stromal rabbits. *Journal of Cell (Yakhteh)*, 2014;16(3):263-70.
16. Chan KM, Hui WC, Chan LS, Rui YF, Qin L, Hung LK. Radix dipsaci dose note improve tendon healing in a rat model of patellar tendon donor site injury. *Journal of Orthopedic Surgery*, 2010; 2:187-93.

17. Lin TW, Cardenas L, Suslowsky LJ. Biomechanic of tendon injury and repair. *Journal of Biomechanic*,2004, 37:865-877.
18. Luminata SL, Dan C. Clinical review about the role of platelet rich plasma for the treatment of traumatic and degenerative musculoskeletal disorders. *Orthopedics and Rheumatology Open Access Journal*, 2016;2(3):1-9.
19. Gentile P, Cole JP, Cole M, Garcovich S, Bielli A, Scioli MG. Evaluation of Not-Activated PRP in hair loss treatment: Role of growth factor and cytokine concentrations obtained by different collection systems. *International Journal of Molecular Science*, 2017;18(2):408-422.
20. Morizaki Y, Zhao C, Amadio PC. The effects of platelet-rich plasma on bone marrow stromal cell transplants for tendon healing in vitro. *Journal of Hand Surgery*,2010;35(11):1833-4.
21. Timothy M, Yao W, Georg AC. The roles of growth factors in tendon and ligament healing. *Journal of Sport Medicine*, 2003;33(5):381-94.
22. -Kakar S, Khan U, McGrouther DA. Differential cellular response within the rabbit tendon unit following tendon injury. *Journal of Hand Surgery: British* ,1998; 23:627-32.
23. Matsui M, Tabata Y. Enhanced angiogenesis by multiple release of platelet-rich plasma contents and basic fibroblast growth factor from gelatin hydrogels. *Journal of Acta Biomaterial*, 2012;8:1792-1801.
24. Ferrara N. Role of vascular endothelial growth factor in the regulation of angiogenesis. *Journal of Kidney International* ,1999;56(3):794-814.
25. Cross M, Claesson WL. FGF and VEGF function in angiogenesis: signaling pathways, biological responses and therapeutic inhibition. *Journal of Trends in Pharmacological Sciences*, 2001; 2(4):201-7.
26. Docheva D, Muller SA, Majewska M, Evans CH. Biologics for tendon repair. *Journal of Advanced Drug Delivery Reviews*, 2015; 84:22-3
27. Sharma P, Maffulli N. Biology of tendon injury: healing modeling and remodeling. *Journal of Musculoskeletal and neuronal Interaction*, 2006;6(2)181-190
28. Amiel D, Akeson W, Harwood FL, Frank CB. Stress deprivation effect on metabolic turnover of medial collateral ligament collagen. A comparison between nine-and 12-week immobilization. *Journal of Clinical Orthopedic and Trauma*, 1993; 172:265-70.
29. Orhan K, Ozturan A, Guven CK. The effect of extracorporeal shock waves on a rat model of injury to tendo Achillis: ahistological and biomechanical study. *Journal of Bone Joint Surgery: British*, 2004;86-B:613-8 .
30. Wurgler-Hauri C, Dourte L M, Baradet T C,Williams GR, Soslowsky LJ. Temporal expression of eight growth factors in tendon to bone healing in a rat supraspinatus model. *Journal of Shoulder and Elbow Surgery*, 2007; 16(50): S198-S203.
31. Aspenberg P, Vichenko O. platelet concentration improve Achilles tendon repair in rats. *Journal of Acta Orthopedic scandandinavia*, 2004;75(1):93-99.
32. Nordin M, Lorenz T, Campello M. Biomechanis of tendons and ligaments. In: Nordin M, Frankel VH, editors. *Basic biomechanics of the musculoskeletal systems* 3rd ed.Philadelphia:Lippincott Williams & Wilkins, 2001;102-125.
33. Bidder M, Toweler DA, Gelberman RH, Boyer MI. Expression of mRNA for vascular endothelial growth factor at the repair site of healing canine flexor tendon. *Journal of Orthopedic research*, 2000;18(2):147-52.
34. Muto T, Kokubu T, Mifune Y, Inui A, Sakata R, Harada Y et al. Can platelet-rich plasma protect rat Achilles tendons from deleterious effects of triamcinolone acetomid? *Orthopedic Journal of Sport Medicine*, 2015;3(7):1-6.
35. Dimitris NL, Konstantinos K, Dionysis V, Stotirios B, Georg A, Anna K. The effect of platelet-rich plasma gel in the early phase of patellar tendon healing. *Journal of Archives of Orthopedic and Trauma Surgery*, 2009; 129:1577-82.
36. Tony WL, Luis C, Louis JS. Biomechanics of tendon injury and repair. *Journal of Biomechanics*, 2004;37;865-77.
37. Yuan T, Zhang CQ, Wang JH-C. Augmenting tendon and ligament repair with platelet-rich plasma(PRP). *Muscle, Ligaments and Tendon Journal*, 2013;3(3):139-49.

38. Sen B, Guler S, Cecen B, Kumtepe E, Bagriyanik A, Ozkal S. The effect of autologous platelet rich plasma in the treatment of Achilles tendon ruptures: An experimental study on rabbits. *Balkan Medical Journal*, 2016;33(1):94-101.
39. Dahners LE. Mechanical properties of tendons. In: Maffulli N, Renstrom P, Leadbetter WB editors. *Tendon injuries: Basic science and clinical medicine*. 1st ed. London: Springer 2005;13-21.
40. Galloway MT, Lalley AL, Shearn JT. The role of mechanical loading in tendon development, maintenance, injury and repair. *Journal of Bone & Joint Surgery*, 2013; 95:1620-8.
41. Dowling BA, Dart AJ. Mechanical and functional properties of the equine superficial digital flexor tendon. *The Veterinary Journal*, 2005; 170:184-192 .
42. Liu HY. In vivo evaluation of the stiffness of the patellar tendon. Presented for Ph.D., Chapel Hill. University of North Carolina. 2008.
43. Nourissat G, Berenbaum F, Duprez D. Tendon injury: from biology to tendon repair. *Journal of Nature Reviews Rheumatology*, 2015;11(4):223-33 .
44. Hettrich CM, Beamer BS, Bedi A, Deland K, Deng XH, Ying Liang et al. The effect of rhPTH on the healing of tendon to bone in rat model. *Journal of Orthopedic Research*, 2012; 30:769-774

Archive of SID

پلاسمای غنی از پلاکت مرحله ابتدایی التیام زردپی خرگوش را بهبود می دهد: مطالعه هیستوپاتولوژیکی و

بیومکانیکی

سارا جوانمردی^{۱*}، امیر عطا وثوق^۲، رضی الله جعفری جوزانی^۱

^۱ گروه علوم درمانگاهی، دانشکده دامپزشکی، دانشگاه تبریز، تبریز، ایران
^۲ دانش آموخته دکتری عمومی دامپزشکی، دانشگاه تبریز، تبریز، ایران

هدف- هدف این مطالعه بررسی اثرات پلاسمای غنی از پلاکت بر مراحل ابتدایی التیام تاندون خم کننده عمقی بندهای انگشت خرگوش بود.
طرح مطالعه- مطالعه تجربی

حیوانات- بیست سر خرگوش سفید نیوزلندی

روش کار- پلاسمای غنی از پلاکت با استفاده از سانتریفوژ دو مرحله تکنیک تغییر یافته کوراسان تهیه شد. حیوانات به طور تصادفی در دو گروه مساوی کنترل و درمان تقسیم شدند. عمل جراحی تنوتومی کامل تجربی بر روی زردپی خم کننده عمقی بندهای انگشتان انجام شد. بلافاصله پس از ترمیم اولیه تاندون ۰/۵ سی سی PRP، هم حجم آن نرمال سالیین به ترتیب در گروه درمان و کنترل در محل ضایعه بصورت داخل زردپی و همچنین اطراف ضایعه تزریق گردید. اندامهای حرکتی در حیوانات جراحی شده در هر دو گروه به مدت دو هفته گچ گیری شدند. در هفته سوم بعد از جراحی نمونه ها برای ارزیابی های هیستوپاتولوژیکی (رنگ آمیزی هماتوکسیلین - اتوزین و ماسون تری کروم) و بیومکانیکی اخذ گردید

نتایج- نتایج ارزیابی کمی و کیفی هیستوپاتولوژیکی افزایش در تمام پارامترهای مورد مطالعه در گروه درمان شده با نسبت به گروه کنترل نشان داد: که این افزایش در اندیس آرایش طولی رشته های کلاژن جدید، اندیس اتصال رشته های کلاژن جدید و قدیمی، ضخامت اپی تنون، میانگین تعداد مقاطع عروقی در بافت جوانه ای و اپی تنون از نظر آماری معنی دار بود ($P < 0.05$). نتایج ارزیابی بیو مکانیک بهبود چشمگیر در حداکثر میزان نیرو و ظرفیت جذب انرژی در نقطه شکست در گروه تحت درمان با پلاسمای غنی از پلاکت در مقایسه با گروه کنترل را نشان داد ($P < 0.05$).

نتیجه گیری و کاربرد بالینی- یافته های مطالعه حاضر نشان می دهد که PRP یک روش ساده، ایمن، سریع و مقرون به صرفه برای به دست آوردن یک غلظت طبیعی از فاکتورهای رشد خودی است که باعث کاهش احتمال پارگی تاندون پس از ترمیم اولیه آن و بهبود نتایج عملکردی می شود.

کلمات کلیدی- پلاسمای غنی از پلاکت، تاندون خم کننده عمقی بند های انگشت، خرگوش