



## ORIGINAL ARTICLE

## Contrast Radiography in Zarudni's Spur-thighed Tortoises (*Testudo graeca zarudnyi*) by Gastrografin®

Mahna Mansoori<sup>1\*</sup>, Dariush Vosough<sup>2</sup>, Mahdieh Rezaei<sup>2</sup>

<sup>1</sup> Graduated Student of Veterinary Medicine, Faculty of Veterinary Medicine, Shahid Bahonar University of Kerman, Kerman, Iran.

<sup>2</sup> Department of Clinical Sciences, Faculty of Veterinary Medicine, Shahid Bahonar University of Kerman, Kerman, Iran.

Received: 6 February 2018

Accepted: 26 May 2018

Available Online: 18 July 2018

### Keywords:

Tortoise;  
Gastrografin;  
Transit time;  
Radiograph.

### Abstract

**Objective-** In this study, the general anatomical features of the digestive tube and the transit time of the digestive tube of the Zarudni's spur-thighed tortoises were examined by contrast radiology.

**Design -** Experimental study.

**Animals -** 4 adult female Zarudni's Spur-thighed Tortoises (*Testudo graeca zarudnyi*).

**Procedures-** At a temperature of 25-27°C a set of dorsoventral radiograph was taken to locate the Gastrografin position.

**Results-** The normal gastric, small intestine and large intestine anatomy were obtained and the mean gastric, small intestine and large intestine transit times were 0.2 hr, 2.1 hr, and 27 hr, respectively. Our results showed some differences in the gastrointestinal transit time with that of other species.

**Conclusion and Clinical Relevance-** The noninvasive diagnostic imaging techniques provide detailed information concerning gastrointestinal tract. Since there have not been any anatomical and radiological studies on this species in Iran, results of this study can use as a reference in this species.

\* Correspondence to: Mahna Mansoori, Graduated Student of Veterinary Medicine, Faculty of Veterinary Medicine, Shahid Bahonar University of Kerman, Kerman, Iran.

E-mail: [mahna.mansoori@yahoo.com](mailto:mahna.mansoori@yahoo.com)

[www.ivsajournals.com](http://www.ivsajournals.com)© Iranian Journal of Veterinary Surgery, 2018

This work is licensed under the terms of the Creative Commons Attribution (CC BY-NC 4.0)

DOI: 10.22034/IVSA.2018.118006.1140

## 1. Introduction

Zarudni's spur-thighed tortoises (*Testudo graeca zarudnyi*) are land-dwelling, herbivorous and poikilothermic reptiles native to eastern Iran and they are in the vulnerable group of the IUCN red list and since there have not been any anatomical and radiological studies on this species in Iran,<sup>1</sup> it is necessary to recognize their normal anatomy to preserve and survive them in the environment. On the other hand, in the turtles, routine examinations that performed in other animals are limited due to the presence of carapaces, so the imaging diagnostic techniques are very practical.<sup>3</sup> Contrast radiography is a safe and noninvasive method that is useful for 1. Evaluation of integrity and size of the gastrointestinal tract. 2. An absence of the foreign body. 3. Measurement of the transit time of contrast agent.<sup>4</sup>

The aim of the present study was to characterize the radiographic anatomy and the normal transit time of digestive tube by contrast radiography in Iranian native turtle (Zarudni's spur-thighed tortoises) that would use as a reference in this species.

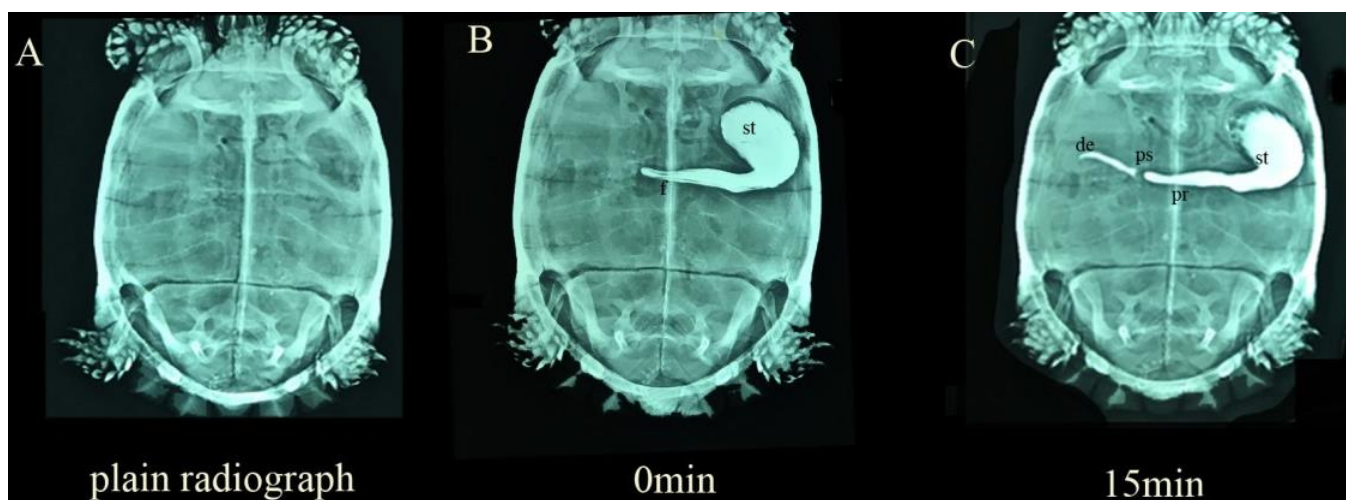
## 2. Materials and Methods

In this study 4 clinically healthy adult Zarudni's spur-thighed tortoises with the mean weight of  $2.25 \pm 0.2$  kilograms derived from nature were selected and studied at the Faculty of Veterinary Medicine, Shahid Bahonar University of Kerman. These turtles were housed indoors with a 12 hours light and 12 hours dark cycle. The ambient temperature and humidity range in the room were 23–27°C, 20–30%, respectively. The tortoises were kept from food 48 hours before contrast administration. The animals were manually restrained in ventral recumbency without sedation to the administration of the Gastrografin (660mg diatrizoate meglumine and 100mg diatrizoate sodium/ml) at a dosage of 1 ml/200 g body weight.<sup>5</sup> The Gastrografin

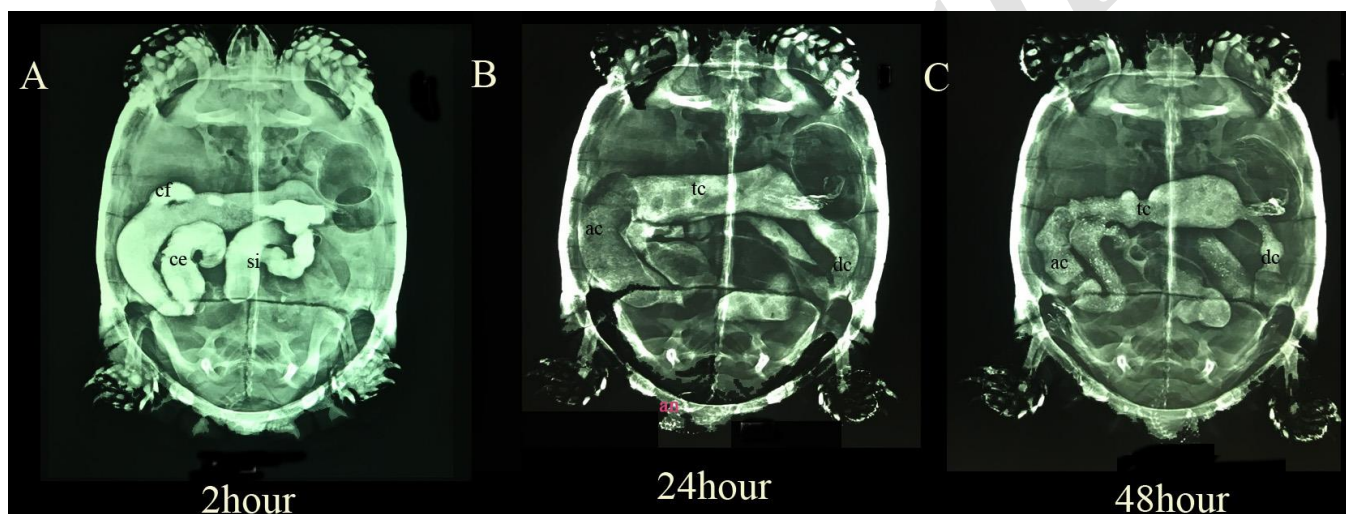
was administered with a 5 French rubber feeding tube. Dorsoventral radiographs were taken pre-administration of the contrast medium, immediately after Gastrografin administration and at 5, 15, 30, 60, 90, 120, and 150 min and 3, 4, 6, 10, 12, 24, 28, 36, 48, 96 and 120 hours postadministration by the digital radiography system (1,9 mAs; 72 kVp). Gastric, small intestinal and total transit times were defined as the time from initial contrast administration to its first appearance in the duodenum, cecum, and cloaca, respectively. Initial GET was defined as the time between the first appearances of contrast medium in the stomach until all the gastrografins were out of the stomach.

## 3. Results

The anatomical study of the gastrointestinal tract revealed that the stomach was located on the left side and had two parts, one a large pouch, and another pyloric region that transversely progressed to the right and had longitudinal mucosal folds. The pyloric sphincter was easily detected with Gastrografin so that it created a space between the stomach and duodenum (figure 1). The duodenum originated from the pyloric sphincter and divided by two flexure into three parts and soon after the duodenum, the longer and more coiled region, located in the middle of the coelomic cavity, was considered the jejunum/ileum, which comprises the largest portion of the small intestine. The transition from the small to the large intestine was characterized by dilation, the cecum, on the right side of the coelomic cavity. The large intestine forming initially the ascending colon, then a transverse colon, and finally the descending colon on the left. In all segments of the gastrointestinal tract, peristalsis movements were visible (figure 2).



**Figure 1.** Normal dorsoventral radiographs of Zarudni's Spur-thighed Tortoises (A) plain radiograph, (B) immediately after administration of Gastrografin®, (C) 15 minute after administration of Gastrografin®. st, stomach; f, longitudinal mucosal folds; pr, pyloric region of stomach; ps, pyloric sphincter.



**Figure 2.** Normal dorsoventral radiographs of Zarudni's Spur-thighed Tortoises 2 h (A), 24 h (B), and 48 h (C) after administration of Gastrografin®. si, small intestine; ce, cecum; cf, cranial flexure; ac, ascending colon; tc, transverse colon; dc, descending colon; an, anus.

The measured transit times are shown in Table 1.

**Table 1.** Gastrointestinal transit times of Gastrografin (1ml/200g body weight) in four Zarudni's Spur-thighed tortoises.

| Species                        | Contrast media | Gastric transit time (h) |       | Small intestine transit time (h) |       | Gastric emptying time (h) |         | Large intestine transit time (h) |       |
|--------------------------------|----------------|--------------------------|-------|----------------------------------|-------|---------------------------|---------|----------------------------------|-------|
|                                |                | mean                     | Range | mean                             | Range | mean                      | Range   | mean                             | Range |
| <i>Testudo graeca zarudnyi</i> | Gastrografin   | mean                     | Range | mean                             | Range | mean                      | Range   | mean                             | Range |
|                                |                | 0.2                      | 0-0.2 | 2.1                              | 2-2.5 | 2.3                       | 1.5-2.5 | 27                               | 24-36 |

## 4. Discussion

In chelonians, Contrast radiography is a useful technique to evaluate gastrointestinal morphology and function. Besides, it can use for therapeutic and diagnostic purposes. According to previous studies, interpretation of Lateral radiograph was extremely difficult due to a greater degree of overlap between gastrointestinal tract and other soft tissue organs and therefore we just use dorso-ventral radiographs.<sup>6</sup>

In the present study, we use Gastrografin as a contrast media.

It is reported that Gastrografin as a contrast media travels faster than barium sulfate, thus the diagnosis is made more quickly and having lower harmful effects on serosal surfaces, so it is a good choice whenever a gastrointestinal perforation is suspected but it should not be administered to dehydrated animals because of hyperosmolar properties.<sup>5,7</sup>

In this study, the dose of Gastrografin was 1ml/200g body weight according to our previous studies on red-eared slider and it could provide a good visualization of all parts of the gastrointestinal tract.<sup>5</sup> The administration method was also appropriate because none of the cases shown any reflux of contrast agent into the esophagus.

Anatomically, we observed that the stomach located in the left side of celomic cavity and the pyloric region was well defined, the small intestine was long and coil and the large intestine begun with a pouch that was called cecum and these specifications are consistent with the earlier researches on red-eared slider, leopard tortoise and have some minor differences with *Podocnemis unifilis*, *Caretta caretta*, and *Eretmochelys imbricate*.<sup>5,6,8,9</sup>

According to Marcela, in the sea species like *Caretta caretta* and *Eretmochelys imbricata* the cecum was not observed, and in *Podocnemis unifilis* the stomach located in the middle of celomic cavity.<sup>8,9</sup> It is reported that, in contrast radiography, we could not distinguish between each region of the small intestines and for this purpose, histological methods should be used.<sup>10</sup> Gastrointestinal transit time in most chelonians, especially herbivorous species is dependent on the temperature, season, nutritional status and species and this time in the Zarudni's spur-thighed tortoises are longer than those reported for mammals and green iguana.<sup>11,12</sup>

The transit time in the sea turtles like loggerhead<sup>13,14</sup> and semi-aquatic turtles like *Podocnemis unifilis*<sup>8</sup> and red-eared slider<sup>5</sup> is longer than the time that we measured at 27°C, Which is due to differences in living environment, food

habits, and metabolic rate; however in the land turtles some similarities are seen, especially between Zarudni's spur-thighed tortoises and Greek tortoises.<sup>7</sup> The mean transit time in the leopard tortoises<sup>6</sup>, the land turtle, was relatively long and this is due to the difference in the contrast agent used and the use of succinylcholine as the chemical immobilizer before the oral administration of contrast media.

## Acknowledgment

This study was supported by Faculty of Veterinary Medicine, Shahid Bahonar University of Kerman.

## Conflict of interests

None

## References

1. Rastegar-Pouyani N, Kami HG, Rajabzadeh HR, Shafiei S, Anderson SC. Annotated checklist of amphibians and reptiles of Iran. *Iranian Journal of Animal Biosystematics*, 2011; 4:43-66.
2. IUCN Red List of Threatened Species website. Tortoise & Freshwater Turtle Specialist Group. Available at: <http://www.iucnredlist.org/details/21646/1,2010>.
3. Martorell J, Espada Y, Ruiz DG. Normal echoanatomy of the red-eared slider terrapin (*Trachemys scripta elegans*). *The Veterinary Record*, 2004; 155:417-420.
4. Krautwald-Junghanns ME, Pees M, Reese S, Tully T. *Diagnostic Imaging of Exotic Pets: Birds, Small Mammals, Reptiles*, 2010:314-320.
5. Long CT, Page RB, Howard AM, McKeon GP, Felt SA Comparison of Gastrografin to Barium Sulfate as a gastrointestinal contrast agent in Red-eared slider turtles (*Trachemys Scripta Elegans*). *Veterinary Radiology & Ultrasound*, 2010; 51:42-47.
6. Taylor SK, Citino SB, Zdziarski JM, Bush RM. Radiographic anatomy and barium sulfate transit time of the gastrointestinal tract of the leopard tortoise (*Testudo pardalis*). *Journal of Zoo and Wildlife Medicine*, 1996; 1:180-186.
7. Meyer J. Gastrografin® as a gastrointestinal contrast agent in the Greek tortoise (*Testudo*

- hermanni*). *Journal of Zoo and Wildlife Medicine*, 1998; 1:183-189.
8. Quagliatto Santos AL, Gomes Ferreira C, Souza Pinto JG, Paula Lima CA, Gonçalves Vieira L, Moraes Machado Brito F. Radiographic anatomy aspects and gastrointestinal transit time in *Podocnemis unifilis* troschel, 1848 (*Testudines, Podocnemididae*). *Biological Sciences*, 2010; 32:431-435.
  9. Magalhães MD, Santos AJ, Silva NB, de Moura CE. Anatomy of the digestive tube of sea turtles (Reptilia: Testudines). *Zoologia (Curitiba)*, 2012; 29:70-76.
  10. Work TM. Manual de necropsia de tortugas marinas para biólogos en refugios o áreas remotas. *US Geological Survey, National Wildlife Health Center, Hawaii Field Station, Honolulu, Hawaii*. 2000: 9-26.
  11. Mans C. Clinical update on diagnosis and management of disorders of the digestive system of reptiles. *Journal of Exotic Pet Medicine*, 2013; 22:141-162.
  12. Smith D, Dobson H, Spence E. Gastrointestinal studies in the green iguana: technique and reference values. *Veterinary Radiology & Ultrasound*, 2001; 42:515-520.
  13. Valente AL, Marco I, Parga ML, Lavin S, Alegre F, Cuenca R. Ingesta passage and gastric emptying times in loggerhead sea turtles (*Caretta caretta*). *Research in Veterinary Science*, 2008; 84:132-139.
  14. Di Bello A, Valastro C, Staffieri F, Crovace A. Contrast radiography of the gastrointestinal tract in sea turtles. *Veterinary Radiology & Ultrasound*, 2006; 47:351-354.

نشریه جراحی دامپزشکی ایران  
سال ۲۰۱۸، جلد ۱۳ (شماره ۱)، شماره پیاپی ۲۸

چکیده

### کنتراست رادیوگرافی در لاک‌پشت مهمیز دار شرقی با استفاده از گاستروگرافین

مهنا منصوری<sup>۱\*</sup>، داریوش وثوق<sup>۲</sup>، مهدیه رضایی<sup>۲</sup>

<sup>۱</sup> دانش‌آموخته دکتری عمومی دامپزشکی، دانشکده دامپزشکی، دانشگاه شهید باهنر کرمان، کرمان، ایران

<sup>۲</sup> گروه علوم بالینی، دانشکده دامپزشکی، دانشگاه شهید باهنر کرمان، کرمان، ایران

**هدف:** در مطالعه حاضر سعی شده است تا با استفاده از کنتراست رادیولوژی، زمان عبور ماده حاجب و همچنین آناتومی طبیعی دستگاه گوارش لاک‌پشت مهمیز دار شرقی (Zarudni's Spur-thighed Tortoise) را به دست آوریم.

**طرح مطالعه:** مطالعه تجربی.

**حیوانات:** ۴ لاک‌پشت مهمیز دار ماده بالغ با میانگین وزن ۲/۵ کیلوگرم.

**روش کار:** بعد از آماده‌سازی حیوانات، رادیوگراف‌هایی دوسوئترال قبل و بعد از خوراندن ماده حاجب برای تعیین موقعیت ماده حاجب در دستگاه گوارش تهیه گردید.

**نتایج:** پس از بررسی تصاویر تهیه‌شده، زمان طبیعی عبور ماده حاجب و آناتومی طبیعی دستگاه گوارش لاک‌پشت مهمیز دار شرقی به دست آمد که این نتایج دارای تفاوت‌هایی با سایر گونه‌ها بود.

**نتیجه‌گیری و کاربرد بالینی:** تکنیک‌های تصویربرداری تشخیصی از جمله کنتراست رادیوگرافی روش‌هایی غیرتهاجمی‌اند که اطلاعات فراوانی در مورد دستگاه گوارش لاک‌پشت ارائه می‌دهند و با توجه به عدم انجام مطالعات آناتومی و رادیولوژی بر روی لاک‌پشت مهمیز دار شرقی از نتایج این مطالعه می‌توان به‌عنوان مرجعی مطالعاتی برای شناخت این گونه استفاده نمود.

**کلمات کلیدی:** لاک‌پشت، گاستروگرافین، زمان عبور ماده حاجب، رادیولوژی.