



Iranian Veterinary Surgery Association

IRANIAN JOURNAL OF VETERINARY SURGERY

Journal homepage: www.ivsajournals.com

CLINICAL REPORT

Clinicopathological Features of Contagious Ecthyma-Like Lesion in a Dog

Monireh Khordadmehr^{1*}, Seyedhosein Jarolmasjed², Javad Ashrafi-Helan¹, Morteza Hooshyar³

¹ Department of Pathobiology, Faculty of Veterinary Medicine, University of Tabriz, Tabriz, Iran.

² Department of Clinical Sciences, Faculty of Veterinary Medicine, University of Tabriz, Tabriz, Iran.

³ DVM student, Department of Clinical Sciences, Faculty of Veterinary Medicine, University of Tabriz, Tabriz, Iran.

Received: 16 July 2018
Accepted: 24 September 2018
Available Online 29 September 2018

Keywords:

Contagious ecthyma;
Dog;
Skin lesions;
Zoonosis disease.

Abstract

Background- Contagious ecthyma or orf is a poxviral disease of goat and sheep, with incidental infection appearing in humans, cows, camels, and many wild ruminants, and very rarely in dogs.

Case description- In the present paper was described gross morphology and histopathology of contagious ecthyma in a dog with a large ulcerated cutaneous mass in the neck (under the collar) which was managed by local surgery.

Clinical findings- The mass was solitary, soft, well circumscribed and grey to brown color. Cut surfaces of the mass contained discrete, round without any lobulation and liquefied foci in the centers. Histologically, there were vacuolar degeneration of keratinocytes in the stratum spinosum, marked epidermal proliferation associated with deep epidermal pegs and dermal papilla, and accumulation of scale-crust with ortho- and parakeratotic hyperkeratosis. Dermal lesions included superficial edema, marked capillary dilation, and an influx of neutrophils, followed by a marked accumulation of lymphocytes. It is guessed that the dog was fed with infected carcass.

Clinical relevance- As regards the virus has zoonotic potential, it should be given more attention.

* Correspondence to: Monireh Khordadmehr, Department of Pathobiology, Faculty of Veterinary Medicine, University of Tabriz, Tabriz, Iran.

E-mail: khordadmehr@tabrizu.ac.ir

1. Introduction

Contagious pustular dermatitis- caused by Parapoxvirus- is a highly contagious and zoonotic skin disease that mainly affects sheep and goats.¹⁻³ The skin lesions mostly are painful and occur on the muzzle and mouth, where those can result anorexia or starvation. This disease has also been reported in other ungulates including alpacas, reindeer (*Rangifer tarandus*), musk oxen (*Ovibos moschatus*), Japanese serows (*Capricornis crispus*), bighorn sheep (*Ovis canadensis*), Sichuan takin (*Budorcas taxicolor tibetana*), deer, pronghorn (*Antilocapra americana*) and wapiti/ elk (*Cervus canadensis*), camels (*Camelus dromedarius*), and it is suspected to occur in some wild chamois (*Rupicapra rupicapra*).⁴⁻⁹ Mice and rabbits could be infected experimentally with similar self-limiting local skin lesions.¹⁰ Up to now, there are rare reports of contagious ecthyma in dogs and cats which those were infected by eating contaminated carcasses.^{11,12}

Infected animals or contagious ecthyma live vaccines can infect humans by direct contact.¹³ Also, the vaccine viruses are contagious when shed from early immunized animals. Human-to-human transmission has reported in very rare cases, which done by direct contact with lesions or a fomite that contacted both lesions and broken skin. Most infections in humans are localized and heal spontaneously; however, large, poorly healing lesions can occur in people who are immunosuppressed.¹⁴

The present paper described morpho-pathological characteristics of natural contagious ecthyma in ventral surface of the neck of a male, middle-age and medium-breed dog which the surgery was the treatment of choice for this animal.

2. Case Description and Clinical Findings

A cutaneous mass with 5×8 cm in size was observed in ventral surface of the neck and under the collar (Figure 1 A, B) of a male four year- old dog which managed with excisional surgery.

The surgery was performed under general anesthesia using cocktail of Ketamine (5.5 mg/kg, Alfasan, The Netherlands) and Diazepam (0.3 mg/kg, Caspian, Iran) and the mass was removed completely. The cutaneous removal mass was processed for histopathological evaluation. The tissue sample was fixed in 10% neutral buffered formalin and processed routinely.

Sections of 5 µm in thickness were stained with hematoxylin and eosin (H&E) and examined by light microscopy.

3. Results

The most significant feature of the gross lesion was the layer of thick brown-gray crust that evaluated 3-4 mm above the skin surface (Figure 1 A, B). Macroscopically, the mass was solitary, soft, well circumscribed and grey to brown color associated with superficial ulceration. Cut surfaces of the mass contained discrete, round and relatively homogeneous without any lobulation and necrotic or liquefied foci in the centers. Microscopically, swelling and vacuolation of keratinocytes in the stratum spinosum, significant epidermal proliferation especially in rete pegs (epidermal pegs), intraepidermal microabscesses, and accumulation of scale-crust were observed. Also, there were a thick layer of ortho- and parakeratotic hyperkeratosis, degenerating neutrophils, cellular debris and bacterial colonies. In addition, dermal lesions included edema, marked capillary dilation, and neutrophil infiltration, followed by accumulation of dendritic cells and lymphocytes which mainly presented in superficial dermis. Moreover, there was a small amount of eosinophilic intracytoplasmic inclusion bodies in some keratinocytes (Figure 1 C, D). In post-operation monitoring, the general condition of the surgical treated dog was normal after two months.

4. Clinical Relevance

Contagious ecthyma has been reported worldwide in all countries that raise sheep. As mentioned previously, sheep, goats and some other domesticated and wild ruminants have been affected by this highly contagious, zoonotic disease. According to the author knowledge, there is only one report of contagious ecthyma in dogs in 1970 which have eaten infected lamb carcasses. The present paper is the second report of this disease in the dog with a single local proliferative skin lesion. While in the previous report, these lesions were observed mainly around the head with circular areas of acute moist dermatitis accompanying with ulcer and scab.¹¹ Orf usually occurs in humans as a single skin lesion or a few lesions which initially is a small, firm and red papule at the site of virus penetration, most often on a fingers and hands.^{13,14} In experimentally infected rabbits and mice, mild to moderate self-limited local skin lesions observed which included erythema, macules, papules, small vesicles and pustules.¹⁰ Contagious ecthyma in cats reported on the feet which in consist of ulcerative proliferative skin lesion, and on the face and back associated with multiple scabs. It was reported that these cats had close contact with infected small ruminants in the farms.¹²

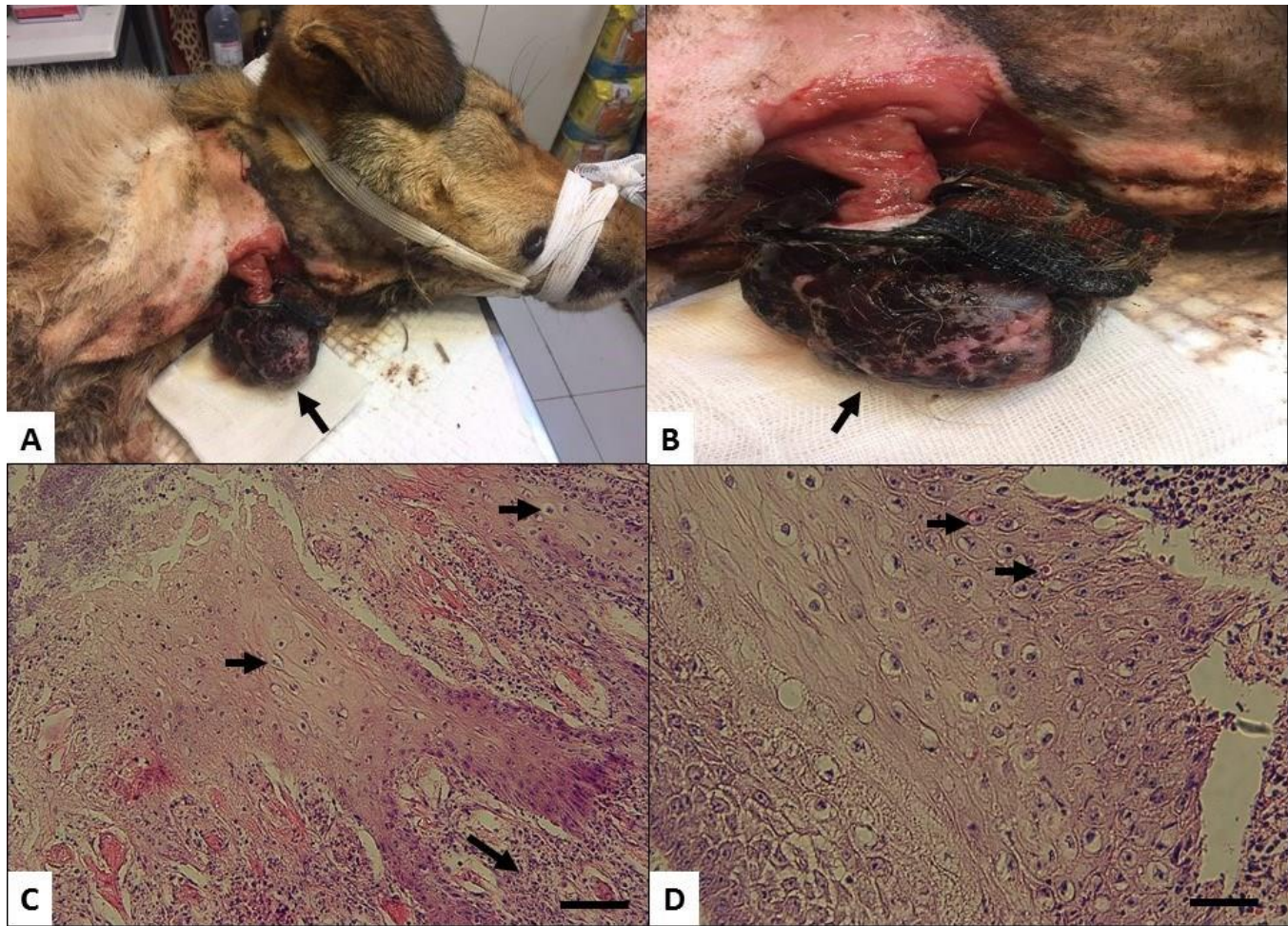


Figure 1. Contagious ecthyma, ventral surface of neck, dog. **A, B:** The mass (arrows) was round, solitary, soft, well circumscribed and grey to brown color associated with superficial ulceration and a layer of thick brown-gray crust that evaluated 3-4 mm above the skin surface. **C:** vacuolar degeneration (short arrows) of keratinocytes in the stratum spinosum, significant epidermal proliferation, and accumulation of scale-crust were observed. In addition, dermal lesions included edema, marked capillary dilation, and neutrophil infiltration, followed by accumulation of dendritic cells and lymphocytes (long arrow) which mainly presented in superficial dermis (H&E, bar= 60 μ m). **D:** A small amount of eosinophilic intracytoplasmic inclusion bodies was observed in some keratinocytes (arrows), (H&E, bar= 30 μ m).

The orf virus find in skin lesions of infected animals and it can enter to the skin by direct contact through cuts and erosions. Also, it can also be spread by fomites. The virus is very resistant in the environment and remains viable on wool and hides for approximately one month after the lesions have healed. Moreover, clinically normal sheep as well as sick animals may carry the virus.¹ It seems that the orf virus entered to the damaged broken skin of the present dog due to the collar contact on the ventral surface of the neck region.

Indeed, gross appearance of the present case was more resemble to chronic ulcerative lesion or cutaneous neoplasia such as squamous cell carcinoma, basal cell tumor and trichoblastoma. Surprisingly, there were not cancerous features at histological evaluation and we observed characteristic lesions of contagious ecthyma in

tissue sections comprising epidermal proliferation of keratinocytes associated with cell swelling, hydropic and vacuolar degeneration, ortho and parakeratosis, a small amount of eosinophilic inclusion bodies, superficial dermatitis with infiltration of different inflammatory cells and dermal capillary dilation which were observed typically in the present infected dog and were made a certain diagnosis.

Infections in goats and sheep are usually diagnosed symptomatically should be discriminated from other viral vesicular disease such as blue tongue, pox and vesicular stomatitis. The diagnosis can be confirmed by electron microscopy of the scabs, which should be collected from animals in an early stage of the disease; however, this technique cannot distinguish the orf virus from other parapoxviruses. Histopathology is also helpful and

satisfactory. PCR tests may be available from some laboratories. A loop-mediated isothermal amplification assay has also been published. Virus isolation is uncommonly used. But, it can be attempted in a variety of cell cultures or embryonated eggs. However, orf virus grows slowly and cannot always be isolated. Serological tests that have been described include serum neutralization, ELISAs, agar gel immunodiffusion (AGID), complement fixation and agglutination. Antibody reactions are generally short-lived.¹⁵

Due to the zoonotic aspects of this disease, there is an increased hazard to the veterinarian and animal owner alike unless the true nature of such skin disease is clearly diagnosed differentially from other skin diseases and dermatopathies.

Acknowledgment

The authors are grateful to the Faculty of Veterinary Medicine, University of Tabriz, Tabriz, Iran for the financial support.

Conflict of interests

None.

References

1. Fenner F, Bachmann PA, Gibbs EPJ, Murphy FA, Studdert MJ and White DO. *Veterinary virology (Orf)*. San Diego, CA: Academic Press Inc.; 1987; 397.
2. de la Concha BA, Guo J, Zhang Z and Waldron D. Severe persistent orf in young goats. *Veterinary Diagnostic and Investigation*, 2003; 15: 423-431.
3. de Oliveira CH, Assis FL, Neto JD, Oliveira CM, Lopes CT, Bomjardim Hdos A, Vinhote WM, Silva AG, Abrahão JS and Kroon EG. Multifocal cutaneous orf virus infection in goats in the Amazon region, Brazil. *Vector-Borne Zoonotic Disease*, 2012; 12(4): 336-340.
4. Kapil S, Yeary T and Evermann JF. Viral diseases of new world camelids. *Veterinary Clinics of North America Food Animal Practice*, 2009; 25(2): 323-337.
5. Klein J and Tryland M. Characterisation of parapoxviruses isolated from Norwegian semi-domesticated reindeer (*Rangifer tarandus tarandus*). *Virology Journal*, 2005; 2: 79.

6. Tryland M, Klein J, Berger T, Josefsen TD, das Neves CG, Oksanen A and Åsbakk K. Experimental parapoxvirus infection (contagious ecthyma) in semi-domesticated reindeer (*Rangifer tarandus tarandus*). *Veterinary Microbiology*, 2013; 162(2-4): 499-506.
7. Vikøren T, Lillehaug A, Akerstedt J, Bretten T, Haugum M and Tryland M. A severe outbreak of contagious ecthyma (orf) in a free-ranging musk ox (*Ovibos moschatus*) population in Norway. *Veterinary Microbiology*, 2008; 127(1-2): 10-20.
8. Inoshima Y, Ito M and Ishiguro N. Spatial and temporal genetic homogeneity of orf viruses infecting Japanese serows (*Capricornis crispus*). *Journal of Veterinary Medical Science*, 2010; 72(6): 701-707.
9. Khalafalla AI, Agab H and Abbas B. An outbreak of contagious ecthyma in camels (*Camelus dromedarius*) in eastern Sudan. *Tropical Animal Health and Production*, 1994; 26(4): 253-254.
10. Cargnelutti JF, Masuda EK, Martins M, Diel DG, Rock DL, Weiblen R and Flores EF. Virological and clinico-pathological features of orf virus infection in experimentally infected rabbits and mice. *Microbial Pathogenesis*, 2011; 50(1): 56-62.
11. Wilkinson GT, Prydie J and Scarnel J. Possible "Orf" (Contagious pustular dermatitis, Contagious ecthyma of sheep) infection in the dog. *Veterinary Record*, 1970; 87: 766-767.
12. Fairley RA, Whelan EM, Pesavento PA and Mercer AA. Recurrent localized cutaneous parapoxvirus infection in three cats. *New Zealand Veterinary Journal*, 2008; 56(4): 196-201.
13. Kuhl JT, Huerter CJ, Hashish H. A case of human orf contracted from a deer. *Cutis*. 2003; 71: 288-290.
14. Acha PN and Szyfres B. (Pan American Health Organization [PAHO]). Zoonoses and communicable diseases common to man and animals. Volume 2. Chlamydiosis, rickettsioses, and viruses. 3rd ed. Washington DC: PAHO; 2003. Scientific and Technical Publication No. 580. Contagious ecthyma, 2003; 80-83.
15. Centers for Disease Control and Prevention [CDC]. Orf virus (sore mouth infection) [online]. CDC; 2015 May. Available at: <http://www.cdc.gov/poxvirus/orf-virus/>.

نشریه جراحی دامپزشکی ایران
سال ۲۰۱۸، جلد ۱۳ (شماره ۲)، شماره پیاپی ۲۹

چکیده

ویژگی‌های بالینی-پاتولوژی شبیه اکتیمای واگیر در سگ

منیره خردادمهر^۱، سید حسین جارالمسجد^۲، جواد اشرفی هلان^۱، مرتضی هوشیار^۳

^۱ گروه پاتوبیولوژی، دانشکده دامپزشکی، دانشگاه تبریز، تبریز، ایران

^۲ گروه علوم درمانگاهی، دانشکده دامپزشکی، دانشگاه تبریز، تبریز، ایران

^۳ دانشجوی دامپزشکی، گروه علوم درمانگاهی، دانشکده دامپزشکی، دانشگاه تبریز، تبریز، ایران

پیش‌زمینه: بیماری اکتیمای واگیر یا ارف یک بیماری ویروسی از خانواده پاکس ویروس در گوسفند و بز می‌باشد که بروز اتفاقی آن در انسان، گاو، شتر و نشخوارکنندگان وحشی رخ می‌دهد، ولی در سگ بسیار نادر است.

توصیف بیماری: در مطالعه حاضر مورفولوژی ماکروسکوپی و هیستوپاتولوژی بیماری اکتیمای واگیر در یک قلاده سگ شرح داده شده است که به صورت یک توده جلدی بزرگ و زخمی در ناحیه گردن (زیر قلاده) بروز کرده و به وسیله جراحی موضعی برداشته شد. توده جراحی شده به شکل جامد، نرم، با محدوده مشخص و به رنگ خاکستری تا قهوه‌ای بود.

یافته‌های بالینی: در سطح برش توده مذکور، ظاهر گرد و محدود شده بدون وجود لبولاسیون و نکروز آبکی مشاهده شد. در مطالعه میکروسکوپی، دجنراسیون واکوتله در کراتینوسیت‌های لایه خاردار اپیدرم پوست، پرولیفراسیون مشخص اپیدرم همراه با عمیق شدن پاپیلاهای درمی و ستیغ‌های اپیدرمی، حضور دلمه‌های سطحی و هایپرکراتوز به شکل پاراکراتوز و اورتوکراتوز مشاهده شد. ضایعات درمی به صورت ادم سطحی، اتساع واضح مویرگی، نفوذ نوتروفیل‌ها و تجمع مشخص لنفوسیت‌ها بود. به نظر می‌رسد که سگ مبتلا به وسیله لاشه آلوده تغذیه شده باشد.

کاربرد بالینی: با توجه به اینکه بیماری اکتیمای واگیر یک بیماری مشترک بین انسان و حیوان است، بروز و تشخیص آن باید بیشتر مورد توجه قرار گیرد.

واژه‌های کلیدی: اکتیمای واگیر، سگ، ضایعات جلدی، بیماری مشترک