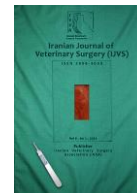



Iranian Veterinary Surgery Association

# IRANIAN JOURNAL OF VETERINARY SURGERY

Journal homepage: [www.ivsajournals.com](http://www.ivsajournals.com)

## CLINICAL REPORT

### An Incidental Finding of a Rare Urinary Bladder Fibrosarcoma with a Cystolith in a Dog

Amir Amniattalab<sup>1\*</sup>, Kambiz Valiei<sup>2</sup><sup>1</sup> Young Researchers and Elite Club, Urmia Branch, Islamic Azad University, Urmia, Iran.<sup>2</sup> Department of Clinical Sciences, Veterinary Faculty, Urmia Branch, Islamic Azad University, Urmia, Iran.

Received: 30 December 2018

Accepted: 6 August 2019

Online: 9 August 2019

**Keywords:**Dog;  
Urinary bladder;  
Fibrosarcoma;  
Cystolith;  
Pathology.**Abstract**

**Case description-** This report describes the simultaneous occurrence of fibrosarcoma and urolith in the urinary bladder of a 12-year-old female terrier dog that was confirmed by pathology after excisional surgery.

**Clinical findings-** The dog had some clinical signs such as frequent urination, hematuria and dysuria with anorexia and urinary tenesmus. Radiography confirmed the presence of a cystolith that was removed by surgery. During surgery, a solitary, pedunculated and round mass that had grown from mucosal tissue to the bladder space was observed. The mass was removed by excisional surgery and its pathologic section was prepared and stained by Hematoxylin and Eosin (H&E) and Masson's trichrome methods. Microscopic findings in the tissue of the mass such as spindle fibroblastic cells with mild to moderate cellular pleomorphism and nuclear hyperchromasia, presence of mild mitosis figures, and chronic inflammation revealed the nature of the mass as a low-grade fibrosarcoma.

**Treatment and outcome-** The cystolith was removed during depletion of the bladder and fibrosarcoma was removed by surgery to prevent further enlargement of the tumor and occupy the bladder space. Moreover, antibiotic therapy to avoid secondary infection was performed. Post-operation monitoring of the patient showed that there was no evidence for recurrence of the tumor within 3 months after surgery.

**Clinical relevance-** Given the findings of this report, an occurrence of bladder fibrosarcoma has non-specific clinical signs that may challenge its differential diagnosis from other urinary-tract lesions.

\* Correspondence to: Amir Amniattalab, Young Researchers and Elite Club, Urmia Branch, Islamic Azad University, Urmia, Iran. E-mail: [a.amniattalab@iaurmia.ac.ir](mailto:a.amniattalab@iaurmia.ac.ir)



## 1. Introduction

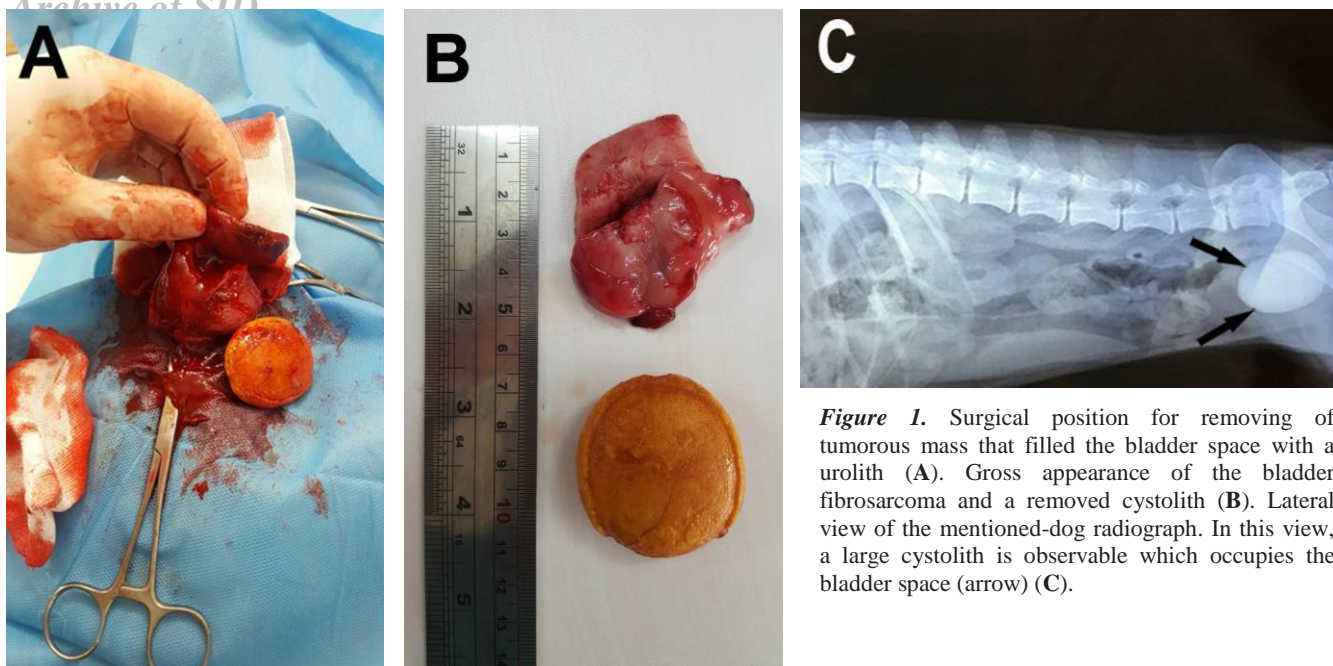
The prevalence of canine urinary bladder neoplasia is low and its rate has been reported about 1 percent or less among all the tumors of dogs. These tumors cause various problems in accurate diagnosis because of their different clinical signs.<sup>1</sup> On the other hand, incidence of malignant tumors in urinary bladder of dogs have been reported about 2 percent of all the canine malignancies.<sup>2</sup> Bladder located tumors has been considered as the most occurred neoplastic lesions in canine urinary tract (73.1%). Moreover, carcinoma has been reported as the most frequent of them (60%) in urinary bladder.<sup>3</sup> Indeed, fibrosarcomas, leiomyosarcomas and other type of soft tissue sarcomas occur with too less prevalence.<sup>4</sup> On the other hand, simultaneous occurrence of bladder fibrosarcoma with uroliths inside it has not been reported in dog until now. The present report characterizes a rare canine bladder fibrosarcoma with a urolith spontaneously that the mentioned tumor and urolith were removed surgically and the tumor was diagnosed pathologically. Post-operation monitoring was revealed that no sign of recurrence or metastasis of the tumor was found in the treated dog within 3 months.

## 2. Case Description and Clinical Findings

A 12-year-old intact female terrier dog weighing 8 kg was referred to the veterinary clinic of Islamic Azad University, Urmia branch in April 2018. According to the explanations of the owner, the dog had frequent urination from about one year ago and sometimes hematuria was also added to her problem in urination. Until recently, the dog had anorexia and tenesmus with frequent howling. Given the clinical signs, the presence of urolith in the urinary bladder was confirmed by radiography (Figure 1C). Thus, the animal was referred to the department of surgery. The obtained blood sample from cephalic vein of the mentioned dog was collected in an EDTA-containing tube and submitted to the laboratory for differential white blood cell

count. The blood smear was stained by Gimsa method. Moreover, the amount of blood urea nitrogen (BUN) and creatinine were measured using commercial kits (Pars Azmoon Inc., Iran) routinely.

Surgical procedure: After considering overnight fasting, sedation of the mentioned dog was induced by using xylazine (1.1 mg/kg IM) (Alfasan, the Netherlands) followed by Acepromazine (0.02 mg/kg IM) (Alfasan, the Netherlands). Then, Ketamine (10 mg/kg IM) (Alfasan, Netherlands) with Diazepam (0.2 mg/kg IV)(Caspian Tamin Pharmaceutical Co., Iran) were initially used for anesthesia induction and followed by Ketamine (2 mg/kg IV) for anesthetic maintenance.<sup>5</sup> After making incision through *linea alba* and providing access to the bladder, intraoperative bladder emptying and cystotomy was done. Given the presence of chronic cystitis, bladders' wall has been found much thickened. The urethra was catheterized before surgery until 7 days after that. During urine drainage, we encountered a large, yellow-colored and smooth-borders urolith (5×3×1.5 cm) and also a firm, pink, round, solitary and pedunculated mass (5.5×3.5×2.5 cm) in the bladder (Figure 1A,B). The mentioned mass was located in the bladder trigone that was excised by elliptical and deep cut. Finally, the wall of the bladder was sutured with a simple continuous pattern in mucosa only followed by a single layer Cushing pattern. To prevent infection, Amikacin (10 mg/kg IM) (Exir company, Iran) and Cefazolin (25 mg/kg IM) (Loghman pharma, Iran) were administered postoperatively for 3 and 6 days respectively. Additionally, a single dose of Dexamethasone (0.2 mg/kg IM) (Osvah pharma, Iran) was injected to reduce post-operative pain and as an anti-inflammatory drug. For preventing catheter obstruction we replaced it one day after surgery. Hematuria was discontinued on third day after surgery. There was no interruption of urination or dysuria during one week after surgery according to owner explanations in post-operation monitoring. Moreover, given the normal health status of the dog and disinclination of the owner post-operation radiologic check-up was not



**Figure 1.** Surgical position for removing of tumorous mass that filled the bladder space with a urolith (A). Gross appearance of the bladder fibrosarcoma and a removed cystolith (B). Lateral view of the mentioned-dog radiograph. In this view, a large cystolith is observable which occupies the bladder space (arrow) (C).

performed. During 3 months after surgery regarding normal health status of the dog and absence of abnormal urinary tract clinical signs, recurrence of the tumor was not observed and the dog gained her healthy status. The removed mass was placed in 10% buffered formalin for fixation and was submitted to the histopathology laboratory at Islamic Azad University, Urmia branch. After completing the stages of tissue processing procedures (dehydration, clearing and impregnation), the paraffinized block was prepared. Tissue section was cut into 4  $\mu\text{m}$  thickness by a rotary microtome (Leica RM2125 RTS) and stained by Hematoxylin and Eosin (H&E) and also Masson's trichrome staining methods according to their routine protocol. Moreover, monoclonal mouse anti-cow Vimentin (Clone: Vim 3B4, Dako, USA) was used for immunohistochemical staining by the EnVision + Dual Link System-HRP method according to the manufacturer suggested protocol.

### 3. Treatment and Outcome

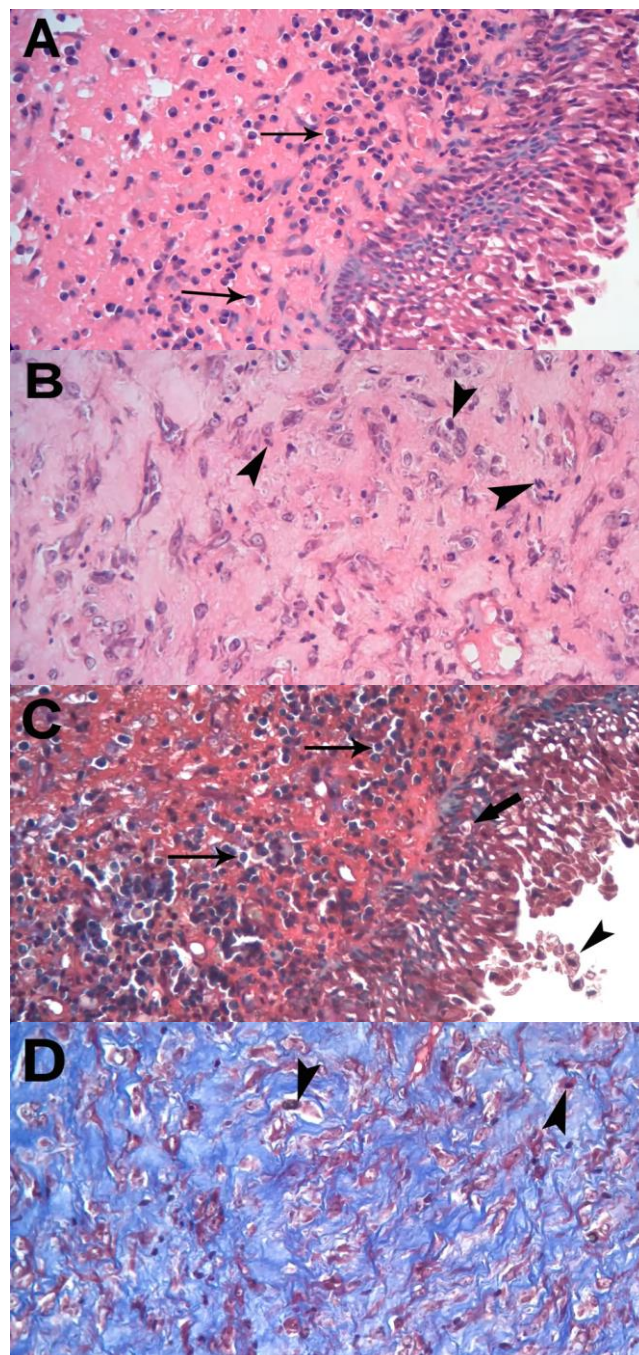
The result of differential white blood cell count showed monocytosis ( $1.63 \times 10^3/\mu\text{l}$ ; reference range: 0.15-

$1.4 \times 10^3/\mu\text{l}$ ). Moreover, blood biochemical analysis revealed a mild increase in blood urea nitrogen (BUN) (34.21 mmol/l; reference range, 7.14-17.65 mmol/l) and creatinine (210.35  $\mu\text{mol/l}$ ; reference range 44.2-132.6  $\mu\text{mol/l}$ ). The stained pathologic section was evaluated by a light microscope (Olympus CX 23). Microscopic findings of the mentioned mass in H&E stained section revealed that nature of the mass was a soft tissue sarcoma. For differentiation of the collagen and muscle fibers, the stained section by Masson's trichrome method was studied. Dominance of the collagen fibers (blue stained) compared to smooth muscle fibers (red stained) confirmed its nature as fibrosarcoma. Other findings in microscopic evaluation were included as follow: severe increase of inflammatory cells in the tumor stromal tissue that type of the mentioned cells were mononuclear lymphocytic cells in the underlay of the transitional epithelium (as tumor epithelial tissue) while there were neutrophils in fewer numbers in center of tumor tissue. No stromal hemorrhage and necrosis were seen. Moreover, there was no epithelial atypia while hydropic degeneration in basic epithelial cells with sloughing of the superficial epithelial cells were observed. The major constituent cells' type of the tumor were well

differentiated spindle fibroblastic cells with mild to moderate nuclear pleomorphism and presence of hyperchromasia in some of them. Mitotic index (MI) in this tumor was recorded 1.1 (mitoses number in 10 high-power fields)<sup>6</sup> and according to the mentioned characteristics, tumor was graded as low-grade fibrosarcoma (Figure 2).

According to the various non-specific clinical signs during urinary infection, cystitis, uroliths, and neoplasms differential diagnosis of the bladder's tumor may be difficult.<sup>7</sup> There are different reported methods for the diagnosis of bladder's growths such as fine-needle aspiration biopsy (FNAB) and ultrasonography.<sup>7</sup> Given the staging and type of malignant tumors in urinary bladder, prognosis and treatment of them will be varied, whereas prognosis of the bladder's malignancies, which originate from or invade to trigone area, is poor. Despite the explanations of Capasso *et al.* (2015), although fibrosarcoma is excised from bladder's trigone, it had no metastatic behavior within 3 months after surgery in the current report. It may be due to the fact that the grade of the mentioned tumor was diagnosed as low-grade malignancy. In our case, we used radiography and pathology for diagnosing of the bladder's fibrosarcoma. In other research, immunohistochemical markers together such as vimentin, S100, smooth muscle actin (SMA), and desmin have been used for the diagnosis of a fibrosarcoma which is located in urinary bladder of a cat.<sup>7</sup> In our report positive immunoreaction of the fibroblastic tumor cells confirmed histopathologic diagnosis of the fibrosarcoma (Figure 3).

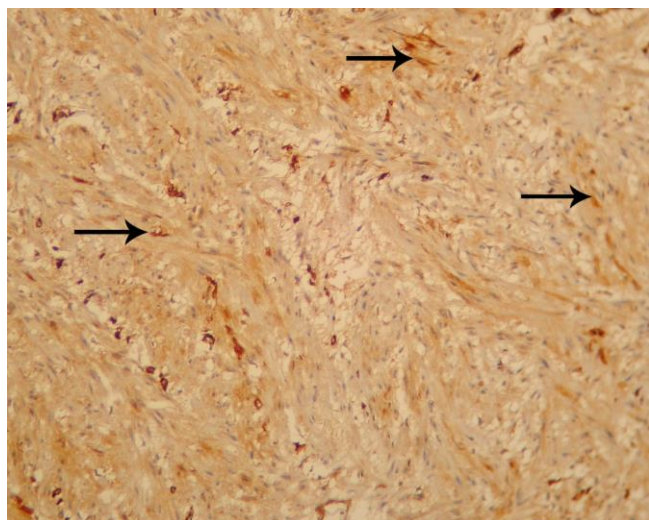
There are multiple factors that contribute to the incidence of bladder tumors. For example, a research reports that the average age of dogs with bladder malignant tumors is between 8 and 10.<sup>8</sup> Moreover, exposure to the insecticides, obesity, breed, as well as female sex are other risk factors in occurrence of the canine bladder tumors. Scottish terrier is more susceptible to be affected by bladder tumor in comparison to other breeds.<sup>9</sup>



**Figure 2.** Microscopic feature of a low-grade fibrosarcoma in the urinary bladder of dog. Presence of mononuclear lymphocytic inflammatory cells (thin arrow) in the dermal layer, epidermal hydropic degeneration (thick arrow), spindle fibroblastic tumor cells in a stroma abundant with blue-colored collagen fibers (**D**), and moderate cellular pleomorphism with some nuclear mitotic figures (arrowhead) are observable in the tumor tissue. (**A** and **B**: H&E,  $\times 400$ ; **C** and **D**: Masson's trichrome,  $\times 400$ ).

Our dog in the present report possessed some risk factors to be affected by bladder tumor such as age (12 year), breed (terrier) and sex (female). The urolith type in the present report was not determined although

macroscopically the stone was much resembled to struvite uroliths. Results of the previous animal studies have revealed that urolithiasis in the urinary tract can lead to tumor formation in the mentioned tract.<sup>10</sup> Moreover, the presence of carcinogens as concentrated materials in calculi may has an important role in the tumorigenesis of urinary bladder. Additionally, induction of uroliths by chronic infection or inflammation and conversely, along with obstructive lesions probably are effective in tumor growth in a way that some mediators or cytokines have shown that it could act as a relative link between chronic inflammation and tumor formation.<sup>10</sup>



**Figure 3.** Positive immunoreactivity of spindle fibroblastic cells of the fibrosarcoma for Vimentin (arrow) (IHC,  $\times 100$ ).

#### 4. Clinical Relevance

According to the mentioned possible causes for tumor induction, in the current report, it seems that given the results of differential white blood cell count and pathology of the bladder, chronic cystitis may contribute to the tumor formation as a cause of bladder-calculus induction. Regarding the short survival time of the affected dogs in the previous research, the prognosis of bladder tumors is poor.<sup>11</sup> However, in the current report, the dog treated by surgery had a good-health condition during the 3 months after the post-operation monitoring. Nevertheless, it is reported that 2 dogs died after 2 weeks and after 9 months

of diagnosis due to the metastasis of bladder fibrosarcoma.<sup>7</sup> In conclusion, due to absence of specific signs for incidence of bladder's malignant tumors such as fibrosarcoma it may occur a challenge in the differential diagnosis of them. On the other hand, cystoliths should be considered as the potential causes for tumor induction in urinary bladder of dogs. Although the malignant tumors of canine bladder have a poor prognosis, excisional surgery is the choice method for treatment of them.

#### Acknowledgement

The authors appreciate Mr. Jafari (Pathology laboratory, Urmia University of Medical Sciences) for the preparation of the pathologic sections.

#### Conflict of Interests

None.

#### References

1. Burnie AG, Weaver D. Urinary bladder neoplasia in the dog; a review of seventy cases. *Journal of Small Animal Practice*, 1983; 24: 129-143.
2. Kim S, Kim Y, Kim W, Choi M, Yoon J. Ultrasonographic assessment of transitional cell carcinoma of the urinary bladder in dogs: a perspective of tumor size change. *Korean Journal of Veterinary Research*, 2017; 57: 205-208.
3. Ciaputa R, Kandefer-Gola M, Nowak M, Madej J. Prevalence of tumours in domestic animals in the lower Silesia (Poland) in 2009-2011. *Bulletin of the Veterinary Institute in Pulawy*, 2013; 57: 53-59.
4. Manjuntha DR, Anilkumar MC, Nagaraju N, Girish BC, Basavaraj B, Vasanth MS. Surgical management of urinary bladder leiomyosarcoma in a dog. *Indian Journal of Canine Practice*, 2016; 8: 55-57.
5. Ashegh H, Pedram MS, Abdi M, Abarkar M, Hejazi M, Maghari MM, Rezaee J, Tavakoi H. Epidural xylazine reduced ketamine anesthetic requirements in laparoscopic ovariohysterectomy in the dog. *Iranian Journal of Veterinary Surgery*, 2010; 12,13: 101-108.
6. Dennis MM, McSparran KD, Bacon NJ, Schulman FY, Foster RA, Powers BE. Prognostic factors for cutaneous and subcutaneous soft tissue sarcomas in

Archive of SID  
dogs. *Veterinary Pathology*, 2011; 48: 73-84.

7. Capasso A, Raiano V, Sontuoso A, Olivero D, Greci V. Fibrosarcoma of the urinary bladder in a cat. *Journal of Feline Medicine and Surgery*, 2015, 1-6.
8. Olausson A, Stieger SM, Lofgren S, Gillingstam M. A urinary bladder fibrosarcoma in a young dog. *Ultrasound*, 2005, 46: 135-138.
9. Sommer BC, Dhawan D, Ratliff TL, Knapp DW. Naturally-Occurring canine invasive urothelial carcinoma: A model for emerging therapies. *Bladder Cancer*, 2018, 4: 149-159.
10. Shih CJ, Chen YT, Ou SM, Yang WC, Chen TJ, Tarng DC. Urinary calculi and risk of cancer. *Medicine*, 2014; 93, 1-8.
11. Norris AM, Laing EJ, Valli VEO, Withrow SJ, Nacy DW, Ogilvie GK, Tomlinson J, McCaw D, Pidgeon G, Jacobs RM. Canine bladder and urethral tumors: A retrospective study of 115 cases (1980-1985). *Journal of Veterinary Internal Medicine*, 1992, 6: 145-153.

## چکیده

## یافته اتفاقی فیبروسارکوم نادر مثانه همراه با یک سنگ مثانه در یک قلاده سگ

امیر امنیت طلب<sup>۱</sup>، کامبیز ولیی<sup>۲</sup>

<sup>۱</sup> باشگاه پژوهشگران جوان و نخبگان، واحد ارومیه، دانشگاه آزاد اسلامی، ارومیه، ایران.

<sup>۲</sup> گروه علوم درمانگاهی، دانشکده دامپزشکی، واحد ارومیه، دانشگاه آزاد اسلامی، ارومیه، ایران.

**توصیف بیمار** - این گزارش وقوع هم‌زمان فیبروسارکوم و سنگ ادراری در مثانه یک سگ تریر ماده ۱۲ ساله را توصیف می‌کند که پس از برداشت جراحی، توسط آسیب‌شناسی تأیید شد.

**یافته‌های بالینی** - سگ برخی از علائم بالینی مثل تکرر ادرار، خون‌شاش، ادرار کردن دردناک همراه با بی‌اشتهایی و زورپیچ ادراری را داشت. رادیوگرافی وجود یک سنگ مثانه را که با جراحی برداشته شد، تأیید کرد. در طی جراحی، یک توده منفرد، پایه‌دار و گرد که از بافت مخاطی به‌طرف فضای مثانه رشد کرده بود، مشاهده شد. توده با برداشت جراحی حذف شد و مقطع آسیب‌شناسی آن آماده و با روش‌های هماتوکسیلین و انوزین و نیز تری کروم ماسون رنگ‌آمیزی شد. یافته‌های میکروسکوپی در بافت توده مثل یاخته‌های فیبروبلاستی دوکی همراه با پلئومورفیسم سلولی خفیف تا متوسط، وجود خفیف اشکال میتوزی و التهاب مزمن، ماهیت توده را به‌عنوان یک فیبروسارکوم با درجه پایین آشکار نمودند.

**درمان و نتیجه** - در طی تخلیه مثانه، سنگ خارج شد و فیبروسارکوم نیز برای جلوگیری از رشد و اشغال بیشتر فضای مثانه، توسط جراحی برداشته شد. علاوه بر این، درمان آنتی‌بیوتیکی برای جلوگیری از عفونت ثانویه انجام شد. ارزیابی بیمار پس از جراحی نشان داد که هیچ شاهدی برای عود مجدد تومور در طی ۳ ماه بعد از جراحی وجود ندارد.

**کاربرد بالینی** - با توجه به یافته‌های این گزارش، وقوع فیبروسارکوم مثانه علائم بالینی غیراختصاصی دارد که ممکن است تشخیص تفریقی آن را از سایر ضایعات دستگاه ادراری به چالش بکشد.

**واژه‌های کلیدی** - سگ، مثانه، فیبروسارکوم، سنگ مثانه، آسیب‌شناسی