



Iranian Veterinary Surgery Association

# IRANIAN JOURNAL OF VETERINARY SURGERY

Journal homepage: [www.ivsajournals.com](http://www.ivsajournals.com)

## CLINICAL REPORT

### Surgical Correction of Complicated Buccal Food Impaction in a Four-Year Old Kurdish Ewe

Niloofer Seydi\*, Ali Ghashghaii

*Department of Clinical Sciences, Faculty of Veterinary Medicine, Razi University, Kermanshah, Iran.*

Received: 6 August 2019  
Accepted: 22 October 2019  
Online: 26 October 2019

#### Keywords:

Buccal food impaction;  
Chipmunk cheeks;  
Ewe.

#### Abstract

**Case description-** A four-year-old Kurdish ewe was referred to the Animal Clinic of Faculty of Veterinary Medicine of Razi University (Kermanshah, Iran) with cheek swallowing, infection wound and impaction of the food in right cheek for several weeks.

**Clinical findings-** Clinical examination revealed stretching and laxity of the cheek muscles with buccal food impaction and skin infection of this area because of previous unprofessional incision by her owner. No dental or other oral cavity abnormalities were observed on examination or palpation after manual expelling of the impacted feed and irrigation of the mouth cavity.

**Treatment and outcome-** After treatment of the animal by Intramuscular penicillin-streptomycin solution (20000 IU + 10 mg/kg bw) and flunixin meglumine (2 mg/kg bw) for three days; the defect was surgically repaired under sedation and local infiltration anesthesia. No post-surgical complications were encountered during three months post-surgery.

**Clinical relevance-** This report describes a complicated buccal food impaction in a ewe and some causes of this disorder and its surgical correction, which it may be the first written report in the sheep in Iran. It could be hypothesized that dietary causes, may be a contributing factor to the development of buccal food impaction in this case.

\* Correspondence to: Niloofer Seydi, Department of Clinical Sciences, Faculty of Veterinary Medicine, Razi University, Kermanshah, Iran. E-mail: [nseydi@razi.ac.ir](mailto:nseydi@razi.ac.ir)



## 1. Case Description

A four-year old Kurdish ewe referred to the Animal clinic of Faculty of Veterinary Medicine of Razi University (Kermanshah, Iran) with a history of cheek swallowing, infection wound and impaction of food in right cheek for several weeks. On presentation, the patient was in a good body condition with the history of grazing on the stubble pasture during recent months.

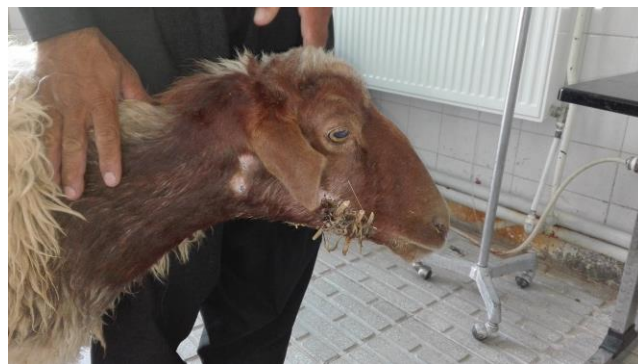
## 2. Clinical Findings

Examination revealed stretching and laxity of the cheek muscles with buccal food impaction and skin infection of this area because of previous unprofessional incision and suture by her owner for relieving of the food impaction problem (Figures 1 and 2). No dental or other oral cavity abnormalities were observed on clinical examination following manual expelling of the impacted feed and irrigation of the mouth cavity. The clinical and laboratory parameters of the animal were in the normal range.

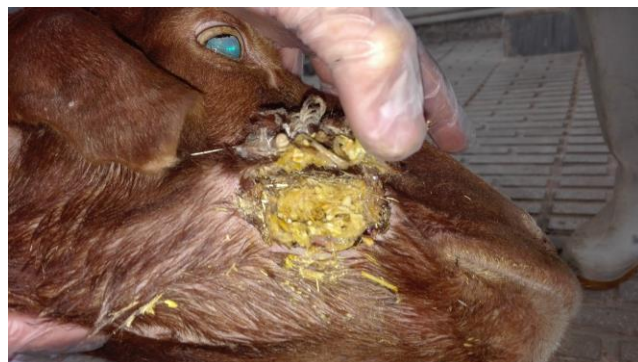## 3. Treatment and Outcome

Because of the local infection, the animal was treated preoperatively for three days by Intramuscular penicillin-streptomycin solution (20000 IU + 10 mg/kg bw) and flunixin meglumine (2 mg/kg bw) and daily irrigation of the wound was done. Then she was subjected to the surgery. The animal was sedated by intravenous injection 0.1 mg/kg, xylazine HCl (Alfasan, Woerden, The Netherlands). The operation site was prepared surgically (povidone-iodine 10% solution for surrounding of the wound and 0.5% solution for the wound site) and the affected site was anesthetized using 10 ml of 1% lidocaine HCl infiltration (Shahid Ghazi, Tabriz, Iran). After surgical site preparation and draping, the wound was irrigated, and the skin was undermined from the underlying buccinator muscle. The underlying submucosa and buccinator muscle were sutured with size 2-0 polyglactin 910 (Pezeshkyaran,

Tehran, Iran) in a simple continuous pattern in two separate layers. The skin was closed with nylon 0 (Pezeshkyaran, Tehran, Iran) in vertical mattress pattern. The ewe was discharged after surgery without any problems. Healing of the wound was desirable, and the ewe did not show any postoperative complication during three months post-surgery.



*Figure 1.* An unprofessional suture the cheek that had been done by the sheep owner.



*Figure 2.* Ewe with buccal food impaction in the right cheek and sign of partially cheek necrosis due to unprofessional suture by the sheep owner.

## 4. Clinical Relevance

Buccal food impaction commonly being referred to as "chipmunk cheeks". Although; it seemed to be not a rare condition in domestic animals such as sheep, but we found a few documents about it, in veterinary literatures. This condition has many causes such as; infectious or inflammatory origin, dental disease or misalignment, nutritional imbalance, or a congenital condition suggesting a potential hereditary component.<sup>1</sup> It has been reported in horses in association with cheek tooth fracture. Among a

total of 60 maxillary and 17 mandibular idiopathic cheek tooth fractures were diagnosed in 68 horses, buccal food impaction was observed in 12% of cases, but other clinical signs also were observed.<sup>2</sup>

Doerr and Dieterich also reported that trauma, alveolar abscesses, and periodontal disease are more likely causes of mandibular lesions in Western Arctic Herd caribou and increasing wear of the teeth may result in a higher possibility of food impaction or gum abrasion and may raise the chance of invasion by infectious organisms.<sup>3</sup>

In the southeastern United States, sublingual food impactions, which are unique to white-tailed deer, have been reported only from areas where E. Schneider is enzootic in whitetails. Food impaction could be due to other causes that produce lesions in any cephalic structure important in mastication.<sup>4</sup>

Buccal food impaction has also been reported in white-tailed deer and is proposed to begin with an irritation of the oral tissues with material such as plant barbs or awns, causing inflammation and pain in the mouth. This pain may cause the animal to move its jaw less, allowing food to accumulate within the cheek pouch.<sup>5</sup>

Assessment of the teeth roots via radiography may have been valuable for a complete examination, but was unavailable in this case. It could be hypothesized that dietary causes, such as long-fibered feed, including rough,

coarse forages, may be a contributing factor to the development of buccal food impaction in this case. This report that describes surgical correction of a complicated buccal food impaction in ewe, may be the first written report of surgically treated disorder in the sheep in Iran.

### Conflict of Interest

The authors have no conflict of interest to declare.

### References

- 1- Holliday B, Doyle A, Oakley M, Wilson R. Buccal feed impaction and surgical correction in captive reindeer. *Canadian Veterinary Journal*, 2017; 58(6): 582-584.
- 2- Dixon PM, Barakzai SZ, Collin NM, Yates J. Equine idiopathic cheek teeth fractures: Part 3: A hospital based survey of 68 referred horses (1999–2005). *Equine Veterinary Journal*, 2007; 39(4): 327-332.
- 3- Doerr GJ, Dieterich A. Mandibular lesions in the western Arctic Caribou herd of Alaska. *Journal of Wildlife Diseases*, 1979; 15(2): 309-318.
- 4- Couvillion CE, Nettles VF, Rawlings CA, Joyner RL. Elaeophorosis in white-tailed deer: Pathology of the natural disease and its relation to oral food impactions. *Journal of Wildlife Management*, 1986; 22(2): 214-223.
- 5- Cass J. Buccal food impaction in whitetailed deer and *Actinomyces necrophorus* in big game. *Journal of Wildlife Management*, 1947; 11: 91-94.

## چکیده

اصلاح عارضه انباشتگی مواد غذایی در ناحیه گونه‌های حفره دهانی به روش جراحی در یک رأس میش  
چهار ساله نژاد کردی

نیلوفر صیدی، علی قشقایی

گروه علوم درمانگاهی، دانشکده دامپزشکی، دانشگاه رازی، کرمانشاه، ایران.

**توصیف بیمار** - یک رأس میش چهار ساله نژاد کردی با تورم گونه، زخم عفونی و تجمع مواد غذایی در گونه سمت راست به کلینیک دانشکده دامپزشکی دانشگاه رازی (کرمانشاه، ایران) ارجاع شد.

**یافته‌های بالینی** - معاینات بالینی نشان‌دهنده کشیدگی و شل شدن عضلات گونه همراه با تجمع مواد غذایی و عفونت پوست در این ناحیه به دلیل دوختن توسط صاحب دام به صورت غیرحرفه‌ای، به منظور رفع مشکل انباشتگی غذا در بین گونه و دندان‌ها بود. پس از خارج کردن مواد غذایی و شستشوی محوطه دهانی، در معاینه بالینی، مشکلی در محوطه دهانی و دندان‌ها مشاهده نشد. پارامترهای بالینی و آزمایشگاهی هم در محدوده طبیعی قرار داشتند.

**درمان و نتیجه** - پس از سه روز درمان با تزریق داخل عضلانی محلول پنی‌سیلین-استرپتومایسین (۲۰۰۰۰ واحد بین‌المللی + ۱۰ میلی‌گرم/کیلوگرم وزن بدن) و فلونیکسین مگلو مین (۲ میلی‌گرم/کیلوگرم وزن بدن) ضایعه گونه تحت آرام‌بخشی و بی‌حسی موضعی انتشاری، به روش جراحی اصلاح شد. بعد از جراحی نیز هیچ‌گونه عارضه‌ای در طول سه ماه پس از جراحی گزارش نشد.

**کاربرد بالینی** - این مقاله که انباشتگی مواد غذایی در ناحیه گونه‌های حفره دهانی در یک رأس میش، همراه با مرور علل این عارضه و درمان آن را به روش جراحی توصیف می‌کند، شاید اولین گزارش مکتوب این عارضه در گوسفند در ایران باشد. می‌توان این فرضیه را مطرح کرد که علت‌های تغذیه‌ای، در این مورد می‌تواند یک عامل مؤثر در ایجاد عارضه انباشتگی مواد غذایی در ناحیه گونه‌های حفره دهانی باشد.

**واژه‌های کلیدی** - تجمع مواد غذایی گونه‌ای، صورت موش خرمايي، میش