



## ORIGINAL ARTICLE

## Development of Risedronate-Loaded Nano Capsules for Calvaria Healing in Rabbit: Histopathological Assessment

Hesam Aldin Hoseinzadeh<sup>1</sup>, Ahmad Asghari<sup>1\*</sup>, Gholamreza Abedi<sup>1</sup>, Abolfazi Akbarzadeh<sup>2,3</sup>, Reza Sedaghat<sup>4</sup>

<sup>1</sup>Department of Clinical Science, Faculty of Veterinary Medicine, Science and Research Branch, Islamic Azad University, Tehran, Iran.

<sup>2</sup>Drug Applied Research Center, Tabriz University of Medical Sciences, Tabriz, Iran.

<sup>3</sup>Universal Scientific Education and Research Network (USERN), Tabriz, Iran.

<sup>4</sup>Department of Anatomy and Pathology, Faculty of Medicine, Shahed University, Tehran, Iran.

### Abstract

**Objective-** Bone regeneration is a multifactorial phenomenon which contributed to several factors. It is reported that risedronate is effective for musculoskeletal diseases. The current study was to determine effectiveness of the risedronate-loaded nano capsules for calvaria healing in rabbit.

**Design-** Experimental study.

**Procedures-** 15 white adult male New Zealand rabbits were used. Four full-thickness skull defects were created in the calvarial bone. The first defect kept unfilled (control). The second was filled with nano risedronate capsules. The third hole was filled using an autogenous bone. The fourth hole was filled with nano risedronate capsules+ autogenous bone. At 4, 8 and 12 weeks after surgery, inflammation level, bone vitality grade, bone type and foreign body were determined.

**Results-** According to the results, the most inflammation was found in control and the lowest in the nano autograft ( $p<0.05$ ). Bone formation in the nano autograft group was significantly faster after 4 weeks ( $p<0.05$ ). Typical bone type II was observed in all of the groups. After 8 weeks, the grade II inflammation was detected in the control group ( $p<0.05$ ). After 8 weeks, The highest grade of inflammation rate were seen as I and 0 in autograft and nano risedronate + autograft groups, respectively ( $p<0.05$ ). After 12 weeks, grade III bone viability was higher in nano risedronate + autograft group compared to the autograft group ( $p<0.05$ ). After 12 weeks, the positive foreign body was detected in control and nano groups. No foreign body was seen in nano risedronate + autograft and autograft groups.

**Conclusion and clinical relevance-** The achieved results suggested have risedronate-loaded nano capsules have positive effects on bone formation and viability in calvaria healing in rabbit which be diminishing osteoclast activity improves bone formation.

Received: 19 October 2018

Accepted: 8 February 2019

Available Online: 23

February 2019

### Keywords:

Nano-capsules;  
Risedronate;  
Calvaria healing;  
Rabbit.

\* Correspondence to: Ahmad Asghari, Department of Clinical Science, Faculty of Veterinary Medicine, Science and Research Branch, Islamic Azad University, Tehran, Iran.

E-mail: [dr.ahmad.asghari@gmail.com](mailto:dr.ahmad.asghari@gmail.com)

[www.ivsajournals.com](http://www.ivsajournals.com)© Iranian Journal of Veterinary Surgery, 2019

This work is licensed under the terms of the Creative Commons Attribution (CC BY-NC 4.0)

DOI: 10.22034/IVSA.2019.152867.1163

## 1. Introduction

Fresh autogenous cancellous bone grafts are currently the “gold standard” treatment for bone regrowth. They are the most effective agents for rapid bone graft healing, without triggering an immune response. They also provide maximum compatibility with the host tissue. Several studies have been conducted to generate materials to promote bone regeneration. However, due to the unavailability of autogenous bone and the associated problems with surgery, non-autogenous, alternative material remains as a treatment option.<sup>1</sup> Clinical research has shown that the combination of bone grafts with other treatments can increase engraftment, formation of bone tissue and bone defect healing.<sup>2</sup> It is recommended that bone graft materials can be as osteoconductive, osteoinductive and osteogenicis.<sup>3-4</sup>

Application of biological agents as mediators of bone regeneration is one of the safe technique. Bisphosphonates are phosphonate backbone molecules with different side chains. At least two groups of bisphosphonates have been identified, including non-amino-bisphosphonates such as etidronate, elodronate and tiludronate without nitrogen atoms and amino-bisphosphonates such as risedronate and alendronate, which have a nitrogen atom in their structure. It is reported that the antiresorptive activity of etidronate (Didronel) and risedronate is thousands-fold higher than that of alendronate.<sup>5</sup> Bisphosphonates are the most common and effective antiresorptive agents for treatment of musculoskeletal diseases and bone remodeling. Bisphosphonates exert their antiresorptive activity by interacting with osteoclasts<sup>6</sup> using hydroxyapatite.<sup>7</sup> Also, bisphosphonates cause jaw osteonecrosis, skeletal muscle pain as well as gastrointestinal and liver symptoms.<sup>8</sup>

Risedronate displays characteristics similar to other bisphosphonates. It can interact with calcium phosphate and hydroxyapatite crystals, crystal growth and mineralization. During heterotopic ossification, risedronate treatment blocks the progression of bone loss. Risedronate inhibits abnormal calcium uptake of the bones and minimize calcium flow from the bone into the blood in malignancy.<sup>9</sup>

Some of the studies have been carried out on the effectiveness of bisphosphonates in bone graft treatment and bone formation previously.<sup>10-11</sup> However, there are few reports on the effects of the nano-materials in bone formation. Therefore, the aim of the current study was to determine the effectiveness of risedronate-loaded nano capsules for calvaria healing in rabbit.

## 2. Materials and Methods

### Materials

The e-Caprolactone (e-Cl), Stannous octoate (Sn(Oct)<sub>2</sub>:stannous 2-ethylhexanoate), polyethylene glycol (PEG), dimethyl sulfoxide and Risedronate powder were purchased from the Sigma Aldrich (St. Louis, MO). The e-Cl recrystallized using ethyl acetate.

### Preparation of Risedronate encapsulated with PCL-PEG copolymer

Risedronate was encapsulated with PCL1000-PEG2000-PCL1000 copolymer using the double emulsion method (w/o/w) as previously described<sup>12</sup>. Risedronate solution (10 mg/2 mL) was emulsified in dichloromethane (5 mL) and 400 mg of the copolymer, using a probe homogenizer at 20000 rpm for 30 seconds. The emulsion was transferred into polyvinyl alcohol 0.1% (40 mL) and probe-homogenized at 72,000 rpm for 1 minute. The emulsion was stirred at room temperature until evaporation of the organic phase was completed (Heidolph Instruments). The nanoparticles were purified using two cycles of centrifugation at 12,000 rpm for 1 hour in Biofuge 28 RS, Heraeus Centrifuge, UK. Then nanoparticles were reconstituted with deionized water. The nanoparticles filtered through 1.2 mm filter (Millipore, Bedford, MA). In order to increase risedronate entrapment in the nanoparticles, the external aqueous phase during the second emulsification step was saturated with risedronate.<sup>12</sup>

### Animals

Fifteen adult male New Zealand white rabbits (3-3.5 kg) were purchased from the Razi Vaccine and Serum Research Institute (Tehran, Iran). For adaptation the animals with new experiment condition, they kept in individual cages in the laboratory at constant and optimum environmental and nutritional conditions (temperature, humidity) with a 12-hour light/dark cycle. During the study animals provided *ad libitum* commercial chew pellet and tap water. Study procedures were done during the 10:00–17:00 h light phase and executed in accordance with the Guide for the Care and Use of Laboratory Animals to Investigate Experimental Pain in Animals and National Institutes of Health (USA) and the current laws of the Iranian government. All experiment procedure was approved based on the guidelines for the animal care board of the Islamic Azad University, Faculty of Veterinary

Medicine. Besides, the current study was approved by the university ethics committee (Ethic code: 25876).

### *Surgical Protocol*

Six hours before the beginning of surgery, animals were food deprived and 1 hour before surgery fasted from drinking. Then animals were anesthetized with an intramuscular (IM) injection of ketamine hydrochloride (10%, 40 mg/kg) and 2% xylazine (Alafason, Woeden, Holland, 5 mg/kg) and then were placed in sternal recumbency position on the operating table.

The head of the rabbit was shaved and scalp prepped with povidone iodine solution. A longitudinal anteroposterior incision (10 cm) was made along the midline of the skull from the midpoint of the base of ears using No. 15 surgical blade.

Before incising the periosteum, the skin was retracted by a surgical mosquito and then using a periosteal elevator periosteum was separated from the bone surface in orientation of cranial to caudal. Four bone defects (internal 8 mm diameter) were created in the calvaria bone. Electric 2000 rpm hand piece and 8 mm diameter milling round surgical trephine was used to create defects on both sides of the sagittal suture without crossing the midline. To prevent overheating until holes reached the meningeal membrane (the soft meningeal membrane was palpable) 0.9% physiologic saline solution was used.<sup>13</sup>

The bone fragments created during the drilling, were used as autogenous bone. The first defect was maintained unfilled and kept as control. The second defect was filled with nano risedronate capsules. The third hole was filled using an autogenous bone and the fourth hole was filled with nano risedronate capsules + autogenous bone. Materials were placed in the pits slowly in a counterclockwise direction without pressure to ensure the particles did not enter to the meningeal space. After placing the materials, the periosteum was sutured with 0-4 simple absorbable sutures.

The calvarium was sutured with 0-3 nylon sutures and skin was sutured with a single simple suture. After animal was coming out of anesthesia, they transferred to a warm place to full consciousness. To prevent infection and relieve pain, postoperative day, cefazolin (20 mg/kg; IM) and tramadol (20 mg/kg; IM) were injected. If there was edema or inflammation in the surgery area, the sutures were removed and the presence of infection or discharge was evaluated. The skin sutures were removed 10 days after surgery.<sup>13</sup>

### *Assessment of the bone regrowth*

At 4, 8, and 12 weeks after surgery, animals were euthanized with pentobarbital (88 mg/kg IV) and tissue specimens were collected in 10% for neutral buffered formalin solution to evaluate bone regrowth. After fixation, bone tissues were decalcified in 5% nitric acid. Then embedding were performed and 5-micron sections were cut. Then tissue sections were stained by hematoxylin eosin (H&E) and trichrome staining methods. The sections were examined to assess the extent and intensity of inflammation, bone formation status and foreign body reaction. For each section 10 microscopic fields were evaluated.<sup>14</sup>

### *Evaluation of the bone formation*

Inflammation was graded using a five-tiered grading system as follows: (0): no inflammatory cells, (I): little and scattered inflammation, (II): focal inflammation with 5 to 10 inflammatory cells, (III): focal inflammation with 10 to 50 inflammatory cells and (IV) focal inflammation with more than 50 inflammatory cells. Foreign body reaction or absorbed material was determined by presence of the multinucleated giant cells in the granulomatous response.<sup>14</sup> Bone formation was evaluated by the presence of primary and secondary bone and divided into 4 degrees qualitatively as follows: (0) lack of the bone formation; (I) poor formation of the bone (primary bone); (II) medium formation of the bone (both primary and secondary bone); and (III) proper formation of the bone (secondary bone).<sup>14</sup>

### *Statistical analysis*

Data were prepared in excel, the parametric data analyzed with two-way analysis of variance (ANOVA) using SPSS 16.0 for Windows (SPSS, Inc., Chicago, IL, USA). Data were expressed as mean values  $\pm$  SD. Where heterogeneity occurred, the groups were separated using Duncan Multiple Range Test. The Kruskal Wallis test was used to compare group medians for histopathological scores.  $p < 0.05$  was considered to denote significant differences between groups.

## **3. Results**

The results of the risedronate-loaded nano capsules on the autograft bone and calvaria healing during 4-12 weeks in rabbit are presented in figures 1-2. According to the results, inflammation was observed in all of the defects

after 4 weeks. The highest inflammation rate was found in the control and the lowest of that was observed in the nano autograft ( $p>0.05$ ) and autograft defects ( $p<0.05$ ). There was significant difference between the treated groups and combination samples ( $p<0.05$ ). In addition, significant difference was seen on inflammation levels in the experimental defects compared to the control defects ( $p<0.05$ )

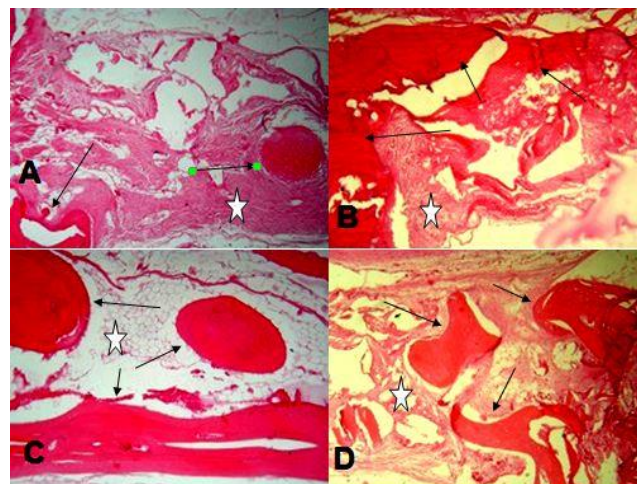
According to Table 1, the bone formation rate was higher in the nano autograft group than the other groups after 4 weeks ( $p<0.05$ ). Moreover, significant difference was seen between the control and autograft group ( $p=0.03$ ). According to the results, most of the bone (80%) formation was type I in the control group while the typical bone type II was observed in the other groups after 4 weeks. Given in the table, the higher rate of the foreign body was detected in control group. There was no significant difference in positive and negative foreign body between autograft and nano-autograft groups. After 8 weeks, the inflammation grade II was detected only in control group ( $p<0.05$ ). There was significant difference on inflammation grade between groups while the higher grade I of the inflammation rate was seen in autograft group and the grade 0 in nano autograft group ( $p<0.05$ ). In nano autograft group, inflammation grade 0 was observed ( $p<0.05$ ).

According to the Table 1, grade I of the bone viability was seen in the control group ( $p<0.05$ ). The higher grade II and III of the bone viability in the nano and autograft ( $p>0.05$ ) and autograft group ( $p>0.05$ ). Indeed, the higher grade III of the bone viability was detected only in nano risedronate capsules + autogenous bone group ( $p<0.05$ ).

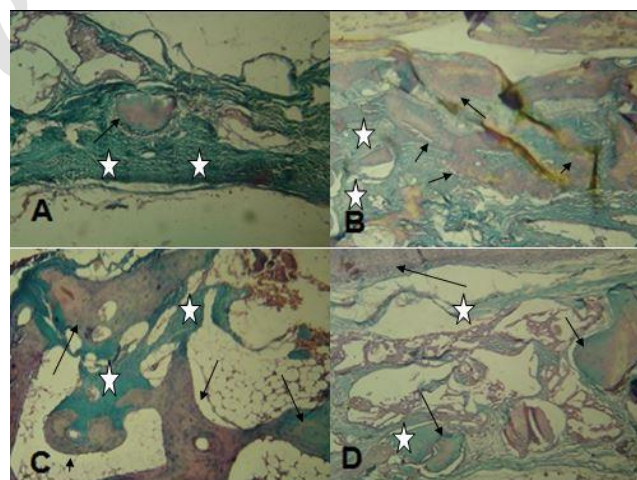
According to the results, only type II bone was detected in all of the groups. Based on the Table 1, no foreign body was detected in the control and autograft groups while that was seen in both autograft and nano risedronate capsules + autogenous bone groups. After 12 weeks, no significant differences were observed in inflammation rate between the groups. This point was due to the long time lapse between the groups in terms of creating surgical inflammation.

The results of the bone viability-grade rate after 12 weeks post-surgery is presented in Table 1. Given that, in the control group, only grade I bone viability was detected ( $p>0.05$ ). In addition, in nano and autograft groups, the same level of the grade II was detected. However, in 2 section of the nano autograft group, grade II was detected ( $p>0.05$ ). A significant difference was seen in distribution of the grade III bone viability which number of animals with grade III bone viability was higher in nano autograft group compared to the autograft group ( $p<0.05$ ).

According to the results, only type II bone was detected in all of the groups. After 12 weeks, foreign body was observed in control and nano groups while nano autograft and autograft groups had no foreign body. The histopathological results of the nano risedronate capsules + autogenous bone on the bone and calvaria healing in rabbit are presented in Figures 1-2.



**Figure 1.** Photo micrographs of bone repair after 12 weeks indifferent groups (A) Control (B) nano-capsules of risedronate sodium (C) autograft (D) nano-capsules of risedronate sodium and autograft. Arrowheads indicating of lamellar bone and asterisks for collagen (H & E,  $\times 100$ ).



**Figure 2.** Photo micrographs of bone repair after 12 weeks indifferent groups. (A) control (B) nano-capsules of risedronate sodium (C) autograft (D) nano-capsules of risedronate sodium and autograft. Arrowheads indicating of lamellar bone and asterisks for collagen (Masson's trichrome,  $\times 100$ ).

#### 4. Discussion

To the best of our knowledge, this is the first report on the effect of nano-capsules containing risedronate on the

**Table 1.** Effect of risedronate-loaded nano capsules on inflammation, bone validity, bone formation and foreign body on calvaria healing in rabbit

Groups	Inflammation			Bone Viability			Bone type			Foreign body		
	First Month	Second Month	Third Month	First Month	Second Month	Third Month	First Month	Second Month	Third Month	First Month	Second Month	Third Month
<b>Control</b>	3±0.02 <sup>a</sup>	2±0.04 <sup>a</sup>	1±0.03 <sup>a</sup>	3±0.21 <sup>a</sup>	2±0.07 <sup>a</sup>	1±0.09 <sup>a</sup>	2±0.14 <sup>a</sup>	2±0.11 <sup>a</sup>	2±0.17 <sup>a</sup>	1±0.23 <sup>a</sup>	2±0.13 <sup>a</sup>	1±0.23 <sup>a</sup>
<b>Autograft</b>	1±0.02 <sup>b</sup>	1±0.05 <sup>b</sup>	1±0.07 <sup>a</sup>	1±0.24 <sup>b</sup>	1±0.09 <sup>b</sup>	1±0.05 <sup>a</sup>	2±0.15 <sup>a</sup>	2±0.12 <sup>a</sup>	2±0.21 <sup>a</sup>	1±0.18 <sup>a</sup>	2±0.17 <sup>a</sup>	2±0.21 <sup>a</sup>
<b>Nano</b>	2±0.04 <sup>c</sup>	1±0.07 <sup>b</sup>	1±0.02 <sup>a</sup>	2±0.22 <sup>c</sup>	1±0.04 <sup>b</sup>	1±0.02 <sup>a</sup>	2±0.13 <sup>a</sup>	2±0.15 <sup>a</sup>	2±0.14 <sup>a</sup>	1±0.15 <sup>a</sup>	1±0.12 <sup>a</sup>	1±0.19 <sup>a</sup>
<b>Nano+ Autograft</b>	0 <sup>d</sup>	0 <sup>c</sup>	0 <sup>b</sup>	0 <sup>d</sup>	0 <sup>c</sup>	0 <sup>b</sup>	2±0.12 <sup>a</sup>	2±0.09 <sup>a</sup>	2±0.19 <sup>a</sup>	1±0.12 <sup>a</sup>	1±0.07 <sup>a</sup>	2±0.14 <sup>a</sup>

Different superscripts in each column indicates significant difference ( $p < 0.05$ )

calvaria healing. In the current research, the most inflammation was found in the control group and the lowest of that was observed in the nano-autograft group. Bisphosphonates are effective in the treatment of musculoskeletal disorders. They are currently used in the control of bone and joint disorders, cancer (breast and prostate), developmental disorders, fibrosis, dysplastic, arthropathy, sympathetic dystrophy and aseptic osteomyelitis.<sup>15</sup> It has been reported risedronate has ability to decrease cartilage swelling and synovial inflammation.<sup>16</sup> Risedronate suppressed expression of pro-osteoclastic inflammatory factors derived from bone marrow adipocytes.<sup>16</sup> Risedronate also inhibits pro-osteoclastic cytokine expression in differentiated in bone marrow.<sup>17</sup> Izumi *et al.*<sup>18</sup> have reported that oral administration of risedronate is effective for recovery of the ADT-induced bone loss in patients. Perhaps, possible mechanisms for the improvement of the pain by bisphosphonates are mediates via inhibition of the osteoclast activity and an anti-inflammatory activity. It is thought that, bisphosphonates may suppress substance P production via the TNF- $\alpha$  pathway.<sup>19</sup>

According the results, bone formation in the nano autograft group was faster than the other groups after 4 weeks. These results suggest nano autograft has positive effects on bone formation and viability in calvaria healing in rabbit. During the study, typical bone type II was observed in all of the groups. After 8 weeks, the inflammation grade II was only detected in control group. After 12 weeks, significant difference was seen in distribution of the grade III bone viability where grade III bone viability was higher in nano-autograft group. Xiong *et al.* (2010), in a study on the effect of alendronate on bone resorption and angiogenesis in mice have reported that bone resorption and osteoclast number decreased without effect in angiogenesis after 2 and 4 weeks.<sup>20</sup> Matos *et al.* (2010) have reported that zoledronate administration improved tissue and trabecular bone, immature bone mass and periosteal fibrosis level in the osteotomy healing of rabbits.<sup>20</sup> A greater bone

formation was observed in human periodontitis treated with 1% alendronate gel plus mechanical treatment (scaling and root planning).<sup>22-23</sup> Luckish *et al.* (2007) revealed that oral risedronate treatment improved arterial elasticity in 68 patients.<sup>24</sup> Furthermore, Libouban *et al.* (2007) reported that risedronate had protective effect on trabecular bone loss in castrated rats.<sup>25</sup> Oral risedronate helps to improve bone growth and mineral content in rats.<sup>26</sup> Alendronate increased bone density in distraction osteogenesis<sup>27</sup> and decreased the percentage of filling defects in bone cavities caused by periodontal disease in rabbits.<sup>28</sup> Despite the direct mechanism for effects of the risedronate still unclear, perhaps risedronate inhibited bone marrow adipogenic differentiation of the Human mesenchymal stem cells (hMSCs) and suppress receptor activator of nuclear factor kappa-B ligand (RANKL) but not osteoprotegerin (OPG) expressions in adipocytes.<sup>17</sup> The balance between RANKL and OPG has a key role in osteoclast differentiation.<sup>17</sup> Risedronate prevents the bone loss via preserving trabecular bone mass and trabecular network connectivity in the metaphyseal region.<sup>25</sup> According to the results of current research, after 12 weeks, foreign body was detected in control and nano groups while all samples in nano-autograft and autograft groups had no foreign body. In this regard, beneficial effect of risedronate on increasing low bone mineral density from baseline for the femoral trochanter and total hip after 12 months was reported risedronate has no efficacy for 24 months.<sup>29</sup> Risedronate leads to decrease remodeling space and increase bone density which improves biomechanical properties of the skeleton and fracture risk.<sup>30</sup> However, there is scarce information regarding whether risedronate improves the bone mass. Autogenous bone has certain limitations to use as a gold standard; thus, bone substitute and grafting biomaterials are becoming increasingly important for all aspects of the surgery.<sup>31</sup> Given the our results neither foreign body reaction nor severe inflammation was seen in the nano risedronate treated defects. Sharma and Pradeep<sup>32</sup> reported

delivery of 1% alendronate stimulates a significant increase in probing depth reduction, clinical attachment level gain, and improved bone fill in the treatment of aggressive periodontitis. Several modes of action have been investigated including bisphosphonates -mediated inhibition of the development of osteoclasts, induction of osteoclastic apoptosis, reduction of activity, prevention of the development of osteoclasts from hematopoietic precursors and stimulation of production of an osteoclast inhibitory factor.<sup>33</sup> Bisphosphonates increase intracellular calcium levels in an osteoclast-like cell line. Sarcoma cell lines to various second generation bisphosphonates and observed a down regulation of bone resorption that correlated with inhibition of matrix metalloproteinases.<sup>34</sup> Also, bisphosphonates not only induce the osteoblasts to secrete inhibitors of osteoclast-mediated resorption but also stimulate the formation of osteoblast precursors and mineralized nodules, thereby promoting early osteoblastogenesis.<sup>34</sup> Bisphosphonates release from bounded bone mineral during bone resorption by osteoclasts. This could lead to a localized accumulation of bisphosphonates, which could directly disturb osteoclastic activity or indirectly target osteoblasts and macrophages, resulting in decreased osteoclastic chemotaxis and activity.<sup>35</sup> In conclusion, our results suggest results suggest nano capsule containing risedronate is effective for bone regeneration. However, the mechanisms for this effect of the nano capsule risedronate against bone loss are not fully elucidated.<sup>16</sup> Osteonecrosis of the jaw can occur more frequently when bisphosphonates are given with glucocorticoids because bacterial infection leads to exacerbation of inflammation in the mandible. However, few studies have been conducted regarding the relationship between the analysis of bacteria, such as those involved in periodontal disease and osteonecrosis of the jaw.<sup>36</sup> Using standardized defects (8 mm diameters) in the parietal bones of rabbit calvaria allowed large increases in their interface with bone graft materials without any effect on the other defects.<sup>37</sup> Further researches needed to determine direct cellular and molecular mechanisms of action for application of risedronate in clinical trials.

## Acknowledgments

The authors thank Department of Veterinary Surgery, Science and Research Branch, Islamic Azad University, Tehran, Iran.

## Conflict of interests

None.

## References

1. Lindhe J, Nyman S, Ericsson I, Lindhe J, Lang N, Karring T. Trauma from occlusion: Periodontal tissues. Lindhe J, Lang NP, Karring T. *Clinical Periodontology and Implant Dentistry* 5<sup>th</sup> ed Oxford: Blackwell Munksgaard. 2008; 363-373.
2. Marx RE. Platelet-rich plasma: evidence to support its use. *Journal of Oral and Maxillofacial Surgery*, 2004; 62(4):489-496.
3. Bauer TW, Muschler GF. Bone Graft Materials: An Overview of the Basic Science. *Clinical Orthopaedics and Related Research*, 2000; 371:10-27.
4. Salgado AJ, Coutinho OP, Reis RL. Bone tissue engineering: state of the art and future trends. *Macromolecular Bioscience*, 2004; 4(8):743-765.
5. Newman MG, Takei H, Klokkevold PR, Carranza FA. Carranza's clinical periodontology: Elsevier health sciences; 2011.
6. Toker H, Ozdemir H, Ozer H, Eren K. A comparative evaluation of the systemic and local alendronate treatment in synthetic bone graft: a histologic and histomorphometric study in a rat calvarial defect model. *Oral surgery, Oral Medicine, Oral Pathology and Oral Radiology*, 2012; 114(5):S146-S152.
7. Fleisch H. Bisphosphonates: mechanisms of action. *Endocrine Reviews*, 1998; 19(1):80-100.
8. Dannemann C, Grätz K, Riener M, Zwahlen R. Jaw osteonecrosis related to bisphosphonate therapy: a severe secondary disorder. *Bone*, 2007; 40(4):828-834.
9. Russell RGG. Bisphosphonates: mode of action and pharmacology. *Pediatrics*, 2007; 119(Suppl 2):S150-S162.
10. Houshmand B, Rahimi H, Ghanavati F, Alisadr A, Eslami B. Boosting effect of bisphosphonates on osteoconductive materials: a histologic in vivo evaluation. *Journal of Periodontal Research*, 2007; 42(2):119-123.
11. Srisubut S, Teerakapong A, Vattaphodes T, Taweechaisupapong S. Effect of local delivery of alendronate on bone formation in bioactive glass grafting in rats. *Oral Surgery, Oral Medicine, Oral Pathology, Oral Radiology, and Endodontology*, 2007; 104(4):e11-e16.
12. Al Khouri Fallouh L N, Roblot-Treupel L, Fessi H, Devissaguet JPh, Puisieux F. Development of a new process for the manufacture of polyisobutylcyanoacrylate nanocapsules. *International Journal of Pharmaceutics*, 1986; 28(2-3):125-132.

13. Betoni-Junior W, Dechichi P, Esteves JC, Zanetta-Barbosa D, Magalhães AEO. Evaluation of the bone healing process utilizing platelet-rich plasma activated by thrombin and calcium chloride: a histologic study in rabbit calvaria. *Journal of Oral Implantology*, 2013; 39(1):14-21.
14. Paknejad M, Rohn A, Rouzmeh N, Heidari M, Titidej A, Kharazifard MJ, *et al.* Histologic evaluation of bone healing capacity following application of inorganic bovine bone and a new allograft material in rabbit calvaria. *Journal of Dentistry* (Tehran, Iran). 2015; 12(1):31.
15. Bijvoet O, Frijlink W, Jie K, Van Linden HD, Meijer C, Mulder H, *et al.* Apd in paget's disease of bone role of the mononuclear phagocyte system? *Arthritis & Rheumatism*, 1980; 23(10):1193-1204.
16. Permuy M, Guede D, López-Peña M, Muñoz F, González-Cantalapiedra A, Caeiro J-R. Effects of glucosamine and risedronate alone or in combination in an experimental rabbit model of osteoarthritis. *BMC Veterinary Research*, 2014; 10(1):1.
17. Jin J, Wang L, Wang X-k, Lai P-l, Huang M-j, Zhong Z-m, *et al.* Risedronate inhibits bone marrow mesenchymal stem cell adipogenesis and switches RANKL/OPG ratio to impair osteoclast differentiation. *Journal of Surgical Research*, 2013; 180(1):e21-e29.
18. Izumi K, Mizokami A, Sugimoto K, Narimoto K, Miwa S, Maeda Y, *et al.* Risedronate recovers bone loss in patients with prostate cancer undergoing androgen-deprivation therapy. *Urology*, 2009; 73(6):1342-1346.
19. Ohtori S, Akazawa T, Murata Y, Kinoshita T, Yamashita M, Nakagawa K, *et al.* Risedronate decreases bone resorption and improves low back pain in postmenopausal osteoporosis patients without vertebral fractures. *Journal of Clinical Neuroscience*, 2010; 17(2):209-213.
20. Xiong H, Wei L, Hu Y, Zhang C, Peng B. Effect of alendronate on alveolar bone resorption and angiogenesis in rats with experimental periapical lesions. *International Endodontic Journal*, 2010; 43(6):485-491.
21. Matos MA, Tannuri U, Guarniero R. The effect of zoledronate during bone healing. *Journal of Orthopaedics and Traumatology*, 2010; 11(1):7-12.
22. Sharma A, Pradeep A. Clinical efficacy of 1% alendronate gel in adjunct to mechanotherapy in the treatment of aggressive periodontitis: a randomized controlled clinical trial. *Journal of Periodontology*, 2012; 83(1):19-26.
23. Pradeep A, Sharma A, Rao NS, Bajaj P, Naik SB, Kumari M. Local drug delivery of alendronate gel for the treatment of patients with chronic periodontitis with diabetes mellitus: a double-masked controlled clinical trial. *Journal of Periodontology*, 2012; 83(10):1322-1328.
24. Luckish A, Cernes R, Boaz M, Gavish D, Matas Z, Fux A, *et al.* Effect of long-term treatment with risedronate on arterial compliance in osteoporotic patients with cardiovascular risk factors. *Bone*, 2008; 43(2):279-283.
25. Libouban H, Blouin S, Moreau M-F, Baslé MF, Audran M, Chappard D. Effects of risedronate in a rat model of osteopenia due to orchidectomy and disuse: densitometric, histomorphometric and microtomographic studies. *Micron*, 2008; 39(7):998-1007.
26. Fujita Y, Watanabe K, Uchikanbori S, Maki K. Effects of risedronate on cortical and trabecular bone of the mandible in glucocorticoid-treated growing rats. *American Journal of Orthodontics and Dentofacial Orthopedics*, 2011; 139(3):e267-e277.
27. Küçük D, Ay S, Kara MI, Avunduk MC, Gümüş C. Comparison of local and systemic alendronate on distraction osteogenesis. *International Journal of Oral and Maxillofacial Surgery*, 2011; 40(12):1395-1400.
28. Veena H, Prasad D. Evaluation of an aminobisphosphonate (alendronate) in the management of periodontal osseous defects. *Journal of Indian Society of Periodontology*, 2010; 14(1):40.
29. Soo I, Siffledeen J, Siminoski K, McQueen B, Fedorak RN. Risedronate improves bone mineral density in Crohn's disease: a two year randomized controlled clinical trial. *Journal of Crohn's and Colitis*, 2012; 6(7):777-786.
30. Eriksen E, Melsen F, Sod E, Barton I, Chines A. Effects of long-term risedronate on bone quality and bone turnover in women with postmenopausal osteoporosis. *Bone*, 2002;31(5):620-625.
31. Götz W, Gerber T, Michel B, Lossdörfer S, Henkel KO, Heinemann F. Immunohistochemical characterization of nanocrystalline hydroxyapatite silica gel (NanoBone®) osteogenesis: a study on biopsies from human jaws. *Clinical Oral Implants Research*, 2008; 19(10):1016-1026.
32. Sharma A, Pradeep AR. Clinical efficacy of 1% alendronate gel in adjunct to mechanotherapy in the treatment of aggressive periodontitis: a randomized controlled clinical trial. *Journal of Periodontology*, 2012; 83:19-26.
33. Colucci S, Minielli V, Zambonin G, *et al.*

- Alendronate reduces adhesion of human osteoclast-like cells to bone and bone protein-coated surfaces. *Calcified Tissue International*, 1998; 63:230-235.
34. Giuliani N, Pedrazzoni M, Negri G, Passeri G, Impicciatore M, Girasole G. Bisphosphonates stimulate formation of osteoblast precursors and mineralized nodules in murine and human bone marrow cultures in vitro and promote early osteoblastogenesis in young and aged mice in vivo. *Bone*, 1998; 22:455-461.
35. Pradeep AR, Sharma A, Rao NS, Bajaj P, Naik SB, Kumari M. Local drug delivery of alendronate gel for the treatment of patients with chronic periodontitis with diabetes mellitus: a double-masked controlled clinical trial. *Journal of Periodontology*, 2012; 83:1322-1328.
36. Fujita Y, Watanabe K, Uchikanbori S, Maki K. Effects of risedronate on cortical and trabecular bone of the mandible in glucocorticoid-treated growing rats. *American Journal of Orthodontics and Dentofacial Orthopedics*, 2011; 139:e267-e277.
37. Takauti ACY, Futema F, de Brito Junior RB, Abrahão AC, Costa C, Queiroz C. Assessment of bone healing in rabbit calvaria grafted with three different biomaterials. *Brazilian Dental Journal*, 2014; 25(5):379-384.

Archive of SID



نشریه جراحی دامپزشکی ایران  
سال ۲۰۱۹، جلد ۴۳ (شماره ۱)، شماره پیاپی ۳۰

## چکیده

### استفاده از نانو کپسول حاوی رزیدرونات برای ترمیم کالواریوم در خرگوش

حسام‌الدین حسین زاده<sup>۱</sup>، احمد اصغری<sup>۱</sup>، غلامرضا عابدی<sup>۱</sup>، ابوالفضل اکبرزاده<sup>۲</sup>، رضا صداقت<sup>۴</sup>

<sup>۱</sup> گروه علوم درمانگاهی، دانشکده دامپزشکی، واحد علوم و تحقیقات، دانشگاه آزاد اسلامی، تهران، ایران

<sup>۲</sup> مرکز تحقیقات دارویی، دانشگاه علوم پزشکی تبریز، تبریز، ایران

<sup>۳</sup> مرکز تخصصی آموزش و تحقیقات (USERN)، تبریز، ایران

<sup>۴</sup> بخش آناتومی و پاتولوژی، دانشکده پزشکی، دانشگاه شاهد، تهران، ایران

**هدف-** بازسازی استخوانی یک فرایند پیچیده بوده که فاکتورهای زیادی در آن دخیل هستند. بیان شده است که رزیدرونات اثرات سودمندی برای بیماری‌های استخوانی عضلانی دارد.

**طرح مطالعه-** هدف از مطالعه حاضر بررسی کارایی استفاده از نانو کپسول پر شده با رزیدرونات برای ترمیم کالواریوم در خرگوش بود. **روش کار-** ۱۵ خرگوش سفید نیوزلندی نر در این مطالعه استفاده شد. چهار حفره توسط میکرو موتور روی استخوان کالواریوم ایجاد گردید. حفره اول خالی نگه داشته شد (گروه کنترل). حفره دوم با نانو کپسول رزیدرونات سدیم پر شد. حفره سوم با استخوان اتوگرافت و حفره چهارم با مخلوطی از داروی نانو و استخوان اتوگرافت پر گردید. در پایان هفته‌های ۴، ۸ و ۱۲ سطح التهاب، درجه زیست پذیری استخوان، نوع استخوان و وجود جسم خارجی مورد ارزیابی قرار گرفت.

**نتایج-** با توجه به نتایج بیشترین التهاب در گروه کنترل و کمترین در گروه اتوگرافت دیده شد ( $p < 0.05$ ). تشکیل استخوان در گروه نانواتوگرافت پس از گذشت ۴ هفته به‌طور معناداری سریع‌تر بود ( $p < 0.05$ ). در تمامی گروه‌ها استخوان نوع ۲ دیده شد. پس از ۸ هفته، در گروه کنترل التهاب نوع ۲ دیده شد ( $p < 0.05$ ). پس از ۸ هفته، بیشترین التهاب درجه صفر و ۱ به ترتیب در گروه‌های اتوگرافت و داروی نانو بعلاوه استخوان اتوگرافت دیده شد ( $p < 0.05$ ). پس از ۱۲ هفته، درجه زیست پذیری ۳ در گروه داروی نانو بعلاوه استخوان اتوگرافت بیشتر از گروه اتوگرافت بود ( $p < 0.05$ ). پس از ۱۲ هفته، جسم خارجی در گروه‌های کنترل و نانو کپسول دیده شد. در گروه‌های داروی نانو بعلاوه استخوان اتوگرافت و گروه استخوان اتوگرافت وجود جسم خارجی منفی بود.

**اهمیت بالینی-** بر اساس نتایج حاصل‌شده، نانو کپسول حاوی نانو ذرات رزیدرونات اثر مثبتی بر تشکیل استخوان و زیست پذیری استخوان در فرایند ترمیم استخوان کالواریوم در خرگوش دارد که به دلیل کاهش فعالیت استوکلاست‌ها بازسازی استخوان بهتر می‌شود.

**کلمات کلیدی-** نانو کپسول، رزیدرونات، ترمیم استخوان کالواریوم، خرگوش