



Iranian Veterinary Surgery Association

IRANIAN JOURNAL OF VETERINARY SURGERY

Journal homepage: www.ivsajournals.com

CLINICAL REPORT

Diagnostic Imaging Features of Haemangiopericytoma at Presumed Location of Vaccine-Site in a Dog: A Report of a 13 Years Old Spitz

Mohammad Molazem¹, Mohammad Reza Esmaili-Nejad¹, Roshanak Mokhtari^{1*},
Rana Vafaei², Solmaz Chegini²

¹Department of Radiology and Surgery, Faculty of Veterinary Medicine, University of Tehran, Tehran, Iran.

²Department of Internal Medicine, Faculty of Veterinary Medicine, University of Tehran, Tehran, Iran.

Received: 27 April 2016
Accepted: 5 February 2019
Available Online: 22
February 2019

Keywords:

Haemangiopericytoma;
CT-Scan angiography;
Ultrasonography.

Abstract

Case Description- A 13 years old neutered female spitz dog was presented to the Small Animal Veterinary Teaching Hospital, University of Tehran for appearance of a soft tissue mass in the interscapular region in about 9 months ago with a progressive increase in the size of the mass.

Clinical Finding- The mass was solid, cold and non-painful in physical examination. Radiography, Computed tomography angiography and ultrasonography were performed for evaluation of the volume and angiogenesis of the mass.

Treatment and Outcome- Treatment was consist of surgical excision of the mass. The patient was fine up to 6 months after surgery, then recurrence at the same site was observed, therefore the owner requested for euthanasia.

Clinical Relevance- In this record, we presented diagnostic imaging characteristics of a mass presumed at the injection site in a dog. Few records have been published in veterinary literature about injection site tumors in dogs, however, there are plenty of those in relation with feline injection-site sarcoma (FISS).

* Correspondence to: Roshanak Mokhtari, Department of Radiology and Surgery, University of Tehran, Tehran, Iran.

E-mail: r.mokhtari@ut.ac.ir

1. Case Description

A 13 years old, neutered female spitz dog was presented for appearance of a soft tissue mass in the interscapular region in about 9 months ago with a progressive increase in the size of the mass (Figure 1).

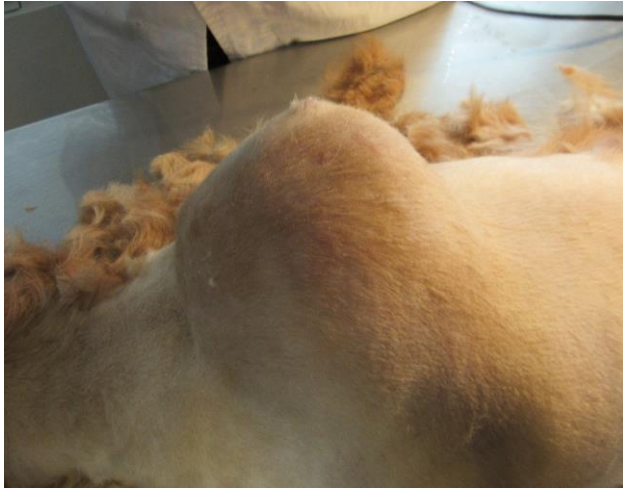

Figure 1. Mass appearance in interscapular region.

2. Clinical Findings

The mass did not have the characteristics of an abscess, it was solid, cold and non-painful in physical examination. The case was referred to the radiology department for further investigations. Radiography, Computed tomography angiography and two-dimensional (2D) and three-dimensional (3D) ultrasonography were performed for evaluation of the structure, volume and angiogenesis of the mass.

Both right and left lateral and ventrodorsal radiographs were obtained from the thoracic cavity using (Carestream, Direct view Classic CR, Kodac Carestream IP) and the technical factors were 60 KV, 400 MS, and 0.04 mA. A lobular soft tissue opacity with some regions of mild calcification was detected in the interscapular region, no sign of invasion to near bony structures such as left and right scapulas were perceived (Figure 2). The lung parenchyma was checked for structured metastatic masses and the result was negative.

Ultrasonography of the abdominal cavity and mass were achieved by the aid of (GE Voluson 730 Pro unit equipped, Austria, with multi-frequency linear electronic transducer 5-17 MHz and 4D linear electronic transducer 6 – 18 MHz). In abdominal sonography, the left adrenal gland width (12 mm) was significantly larger than right adrenal (4 mm) and has become round in shape and had a hypoechoic echogenicity the blood supply was rich both

in peripheral and central areas. The right adrenal gland was normal in shape and echogenicity. A focal anechoic region without any significant blood supply was also located in liver parenchyma. The mass in interscapular region had a heterogeneous echogenicity with hyperechoic linear septas. In 3D color Doppler examination, the blood supply was high (Figure 3). Fine needle aspiration of the mass under ultrasonography guidance was done.

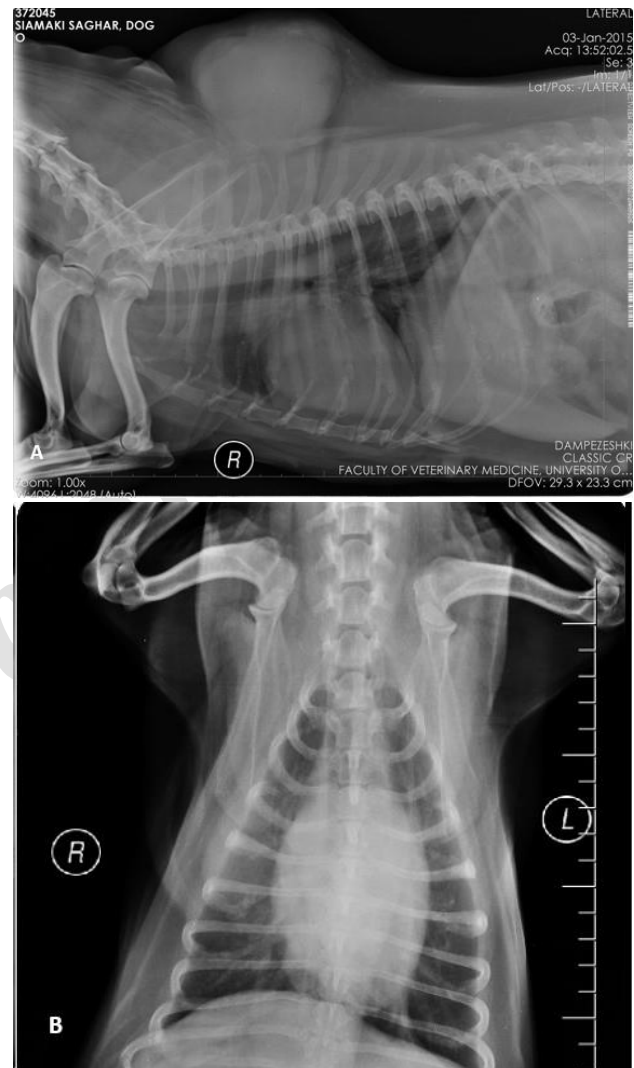


Figure 2. A- Right lateral and B- ventrodorsal. Radiograph views of the thoracic region, a round soft tissue mass is detectable in dorsal aspect no sign of bone involvement and metastatic structure is seen.

Plain CT-Scan and CT-scan Angiography (Omnipaque 240 mg /ml injectable Iohexol 750 mg/kg body weight with administration rate of 2 ml/s) were performed using (Siemens Somatom®) 2 detector scanner. The images were obtained in sagittal, transverse, coronal and 3D reconstruction images were achieved by the aid of

Somaris 5.5 Syngo CT 2010 reconstruction program and the technical factors were KV, mA, slice thickness, and pitch. The exact protocol was done two times, immediately after complete injection of 3 ml/kg contrast medium via power injector (Sinopower-S Sino Medical-Device Technology Co., LTD) and 60 seconds later (delay phase) to allow the contrast medium to reach the suspected mass for CT-scan angiography achievement.¹ At the window level of 80 and window width of 700, the mean Hounsfield unit of the mass was 50.6. The mass was mixed-attenuate and had a lobular architecture with the width of 8.15 cm and the maximum height of 7.9 cm in transverse view and the maximum length is 7.29 cm in the sagittal view the overall volume was determined 169.45 cm³. No sign of invasion to near soft tissues and bones were seen. Very high angiogenesis was one of the most important characteristics of the suspected mass, make enhancement of the lobular structure (Figure 4).

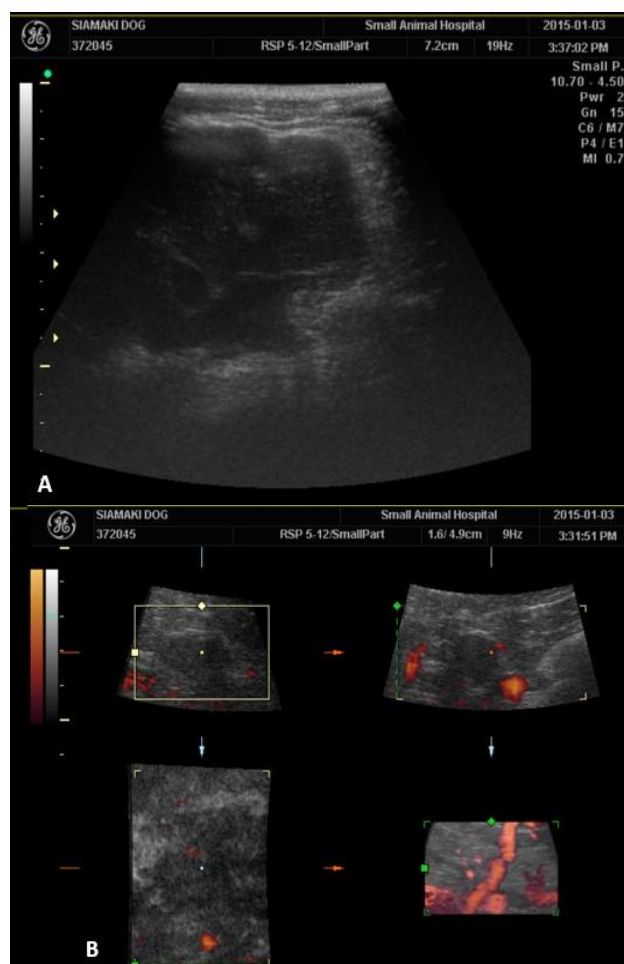


Figure 3. A- B-mode ultrasonographic appearance of the suspected mass shows a heterogeneous appearance. B- 3D color Doppler examination of the mass shows high central and peripheral angiogenesis.

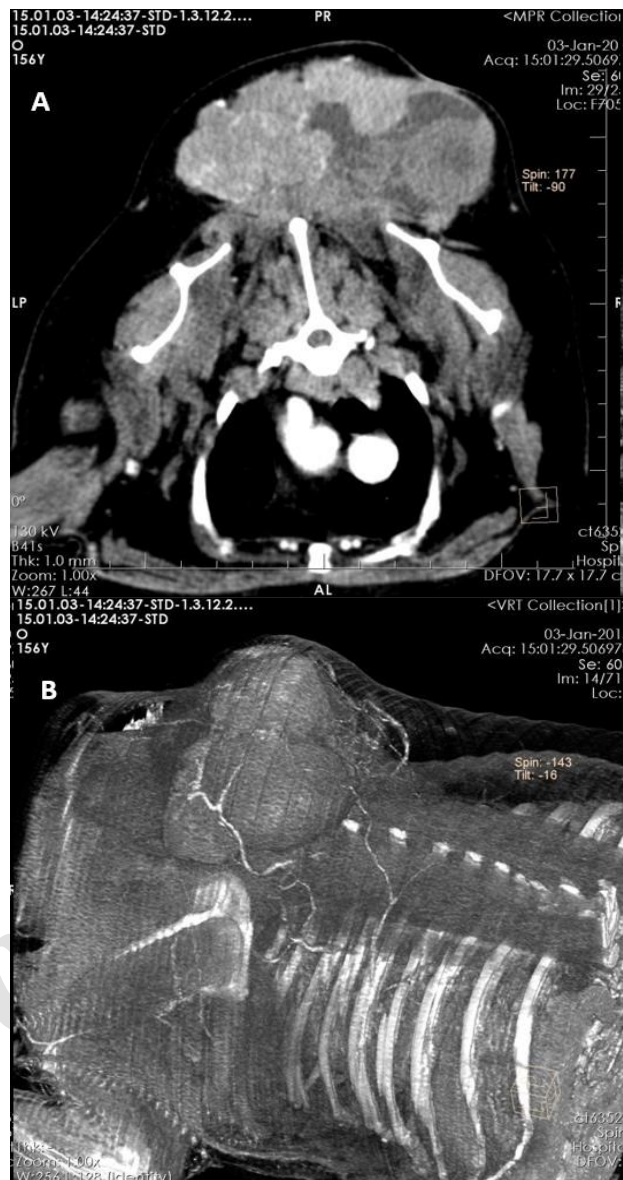

Figure 4. A- CT-Scan angiography transverse view. The mass has a lobular structure with enhancement parenchyma after contrast medium injection. B- 3D reconstruction of mass after injection of the contrast medium

For cytology evaluation of the mass, aspirated specimens by ultrasound guided FNA method were prepared and stained with Giemsa. Numerous single or clusters of oval and round cells, associated with uniform oval nuclei were present. A few number of mitotic figures were observed in the cytology sample.

The tissue specimen for histopathology examination was obtained by excisional biopsy from different locations of the mass. The sample was stored and fixed in 10% formalin. Paraffinized tissue section was cut into 4 μ m thickness and stained by hematoxylin and eosin (H&E method).

The neoplastic spindle-shaped cells were almost uniform with a moderate amount of cytoplasm and round to oval nuclei. Some clusters of epithelioid cells were present as well. Fingerprint pattern of cells adjacent to endothelium and perivascular hyalinization were also notable. Lymphocytes and plasma cells were infiltrated among the neoplastic cells. Mitotic rate was low and there was no sign of hemorrhage or necrosis (Figure 5).

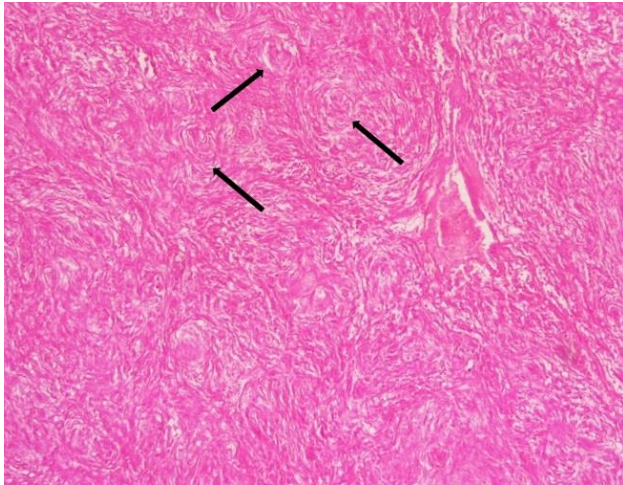


Figure 5. Tissue section. Classic fingerprint whorls of neoplastic cells around capillaries from the mass. Arrows indicate fingerprint pattern (H&E; IP).

3. Treatment and Outcome

Treatment was consist of surgical excision of the mass (Figure 6). The patient was fine up to 6 months after surgery, then recurrence at the same site was observed, therefore the owner requested for euthanasia.

4. Clinical Relevance

Subcutaneous inflammation is a frequent finding in dogs and cats being vaccinated by aluminum-based adjuvant vaccines which were first described by Hendrick.² Feline injection site sarcoma (FISS) has collected attention overpass 10 years accompanying new protocols for rabies vaccination. Recent studies have shown that other subcutaneous injectable materials such as long-acting antibiotic, steroids or still microchips can also make a focal inflammatory response, leading to a neoplastic condition.^{3,4} Diagnosis of the injection site sarcomas based on observation of the a rapid growing mass in presumed location of the injection site (interscapular region) as vaccine-associated feline sarcoma task force (VAFSTF) suggested that any rapid growing mass with size of more than 2 cm which is persist more than 3 months has to be

biopsied for checking the FISS.⁵ Complete blood work, urinalysis, abdominal ultrasonography, thoracic radiography, CT-scan and MRI are suggested for more evaluation of the mass and treatment planning. CT-scan angiography is an accurate modality for assessment of the mass extension and near metastasis.

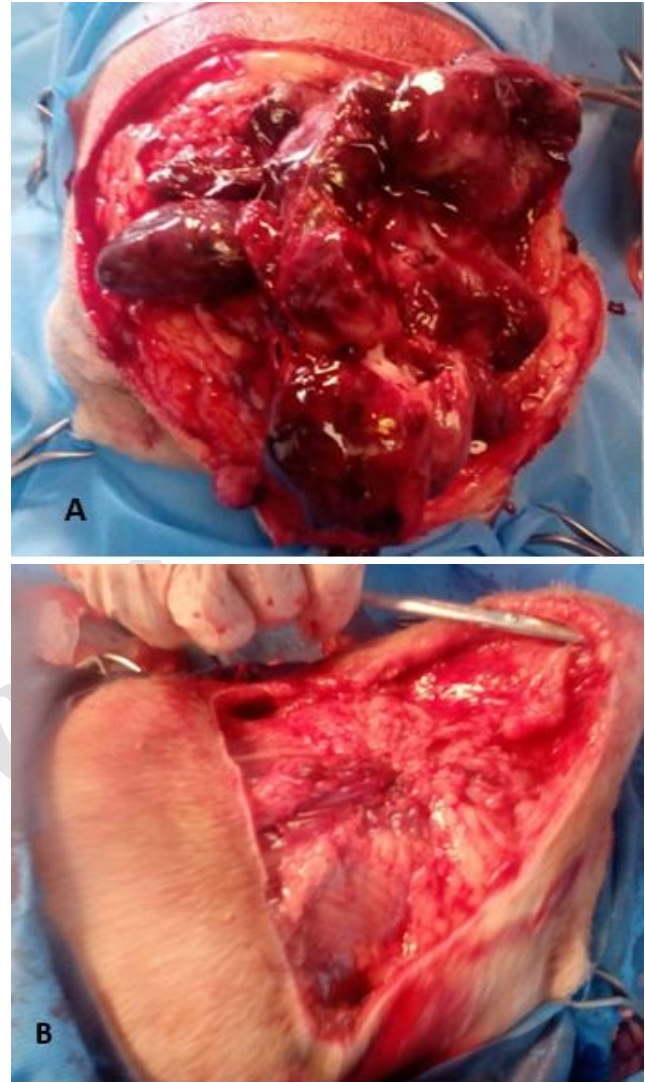


Figure 6. A- Gross appearance of the tumor. B- No sign of adjacent tissues invasion is seen after complete resection of the tumor.

In this record, we presented diagnostic imaging characteristics of a mass presumed at the injection site in a 13-years-old neutered dog. Few records have been published in veterinary literature about injection site tumors in dogs, however, there are plenty of those in relation with FISS.

Radiographic features of the mass indicate a round soft tissue mass located in dorsal of the thoracic region. For more investigation of the soft tissue masses,

ultrasonography is a non-invasive, available and cheap modality which can be used in the second step but cannot distinguish malignant from benign masses solely, nonetheless the malignant tumor has more tortuous and randomly disturb vascularization pattern. Another factor which can be used in determining the malignancy is central necrosis areas.⁶ In present case, heterogeneous appearance and mixed echogenicity pattern were seen during B-mode ultrasonography. Color Doppler examination showed high centrally and peripherally angiogenesis of the suspected mass. Volumetric computed tomography is an almost new, non-invasive and highly sensitive technology which can be used for monitoring the angiogenesis of the tumors.⁷ Although MRI is a gold technique for evaluating soft tissue involvement but CT-scan is a valuable diagnostic modality which can be used for determining tissue mineralization, tissue opacity and its Hounsfield unit, the degree of vascularization and adjacent tissues invasion.⁸ Distinguishing a malignant tumor from benign has been made by the aid of CT-scan for decades.⁸ In this study, a heterogeneous and multi-lobular mass with high vascularization that didn't have evidence of mineralization or adjacent musculoskeletal involvement was detected. In one study, histopathological findings after surgical removing of a subcutaneous mass on right leg of a dog manifest, the spindle-shaped cells constituted whorls resembling fingerprint pattern. These cells were having eosinophilic cytoplasm, associated with some prominent nucleoli.⁹ In another case report, histopathological features of a mass in left flank of a dog revealed that cells appeared to be spindle shaped around a central capillary together with a fingerprint pattern. The predominant cells had eosinophilic cytoplasm with prominent nuclei and the mitotic figures were scarce.¹⁰ These results are similar to our case, based on histopathological findings. In conclusion, although histopathologic examination is the best procedure for the definitive diagnosis of soft tissue tumors kind, but use of CT-scan technique for clinical evaluation of structure and nature of the mass is effective and can be helpful for a surgical approach.

Acknowledgments

The authors would like to thank the Small Animal Teaching Hospital, Faculty of the Veterinary Medicine, University of Tehran for their support and cooperation.

Conflict of interests

None declared.

References

1. Pollard R, Puchalski S. CT contrast media and applications. In Veterinary Computed Tomography, Saunders J and Schwarz T, Wiley-Blackwell, 2011; 58.
2. Hendrick MJ. Historical review and current knowledge of risk factors involved in feline vaccine-associated sarcomas. *Journal of the American Veterinary Medical Association*, 1998; 1422-1423.
3. Daly MK, Saba CF, Crichik S, Howerth E, Kosarek E, Cornell KK. fibrosarcoma adjacent to the site of microchip plantation in a cat. *Journal of Feline Medicine and Surgery*, 2008; 202-205.
4. Kass PH, Spangler W, Hendrick J, McGill LD, Esplin D, Lester S. Multicenter case-control study of risk factors associated with the development of vaccine-associated sarcomas in cats. *Journal of the American Veterinary Medical Association*, 2003; 1283-1292.
5. Morrison W, Starr R. Vaccine-Associated Feline Sarcoma *Journal of the American Veterinary Medical Association*, 2001; 218:697-702.
6. Andre d-Anjou M, Blond L. Musculoskeletal system. In Atlas of small animal ultrasonography, by Marc-Andre d Anjou and Dominique Penninck, Wiley-Blackwell, 2015; 534-535.
7. Kiessling F, Greschus S, Lichy M, Bock M, Fink C, Vosseler S. Volumetric computed tomography (VCT): a new technology for noninvasive, high-resolution monitoring of tumor angiogenesis. *Nature Medicine*, 2004; 1133-1138.
8. Subhawong T, Swart J, Fishman E, Carrino J, Attar S, Fayad L. Soft Tissue Masses and Mass Like Condition: what does CT-Scan add to diagnosis and management. *American Journal of Roentgenology*, 2010; 1559-1567.
9. Coskan A, Onal B, Alcigir M, Kutsal O. A canine hemangiopericytoma case: Fine needle aspiration (FNA) cytology and histopathological findings. *Ankara Üniversitesi Veteriner Fakültesi Dergisi*, 2013; 151-153.
10. Namazi F, Abbaszadeh Hasiri M, Oryan A, Moshiri A. Hemangiopericytoma in a young dog: Evaluation of histopathological and immunohistochemical features. *Journal of Veterinary Research Forum*, 2014; 5:157-160.

نشریه جراحی دامپزشکی ایران

سال ۲۰۱۹، جلد ۱۴ (شماره ۱)، شماره پیاپی ۳۰

چکیده

گزارش موردی همانژیوپرپرسیتوما در محل تزریق واکسن در سگ با استفاده از تکنیک تصویربرداری تشخیصی

محمد ملازم^۱، محمدرضا اسماعیلی نژاد^۱، روشنک مختاری^۱، رعنا وفایی^۲، سولماز چگنی^۲

^۱گروه جراحی و رادیولوژی، دانشکده دامپزشکی دانشگاه تهران، تهران، ایران.

^۲گروه داخلی، دانشکده دامپزشکی دانشگاه تهران، تهران، ایران.

توصیف بیمار- یک قلابه سگ اسپیتز ماده عقیم شده ۱۳ ساله با سابقه حضور یک توده در ناحیه پشتی قفسه سینه به بیمارستان دام‌های کوچک دانشکده دامپزشکی دانشگاه تهران ارجاع داده شد.

یافته‌های بالینی- بعد از معاینه کامل بالینی، با استفاده از رادیوگرافی دیجیتال، تصاویر سی‌تی‌اسکن ساده و آنژیوگرافی و همچنین سونوگرافی نوع ساختار، سایز و خون‌رسانی توده مشکوک مورد ارزیابی قرار گرفت.

درمان و نتیجه- توده مذکور در جراحی به‌صورت کامل از محل ضایعه برداشته شد و یک نمونه بافتی برای ارزیابی هیستوپاتولوژی از توده گرفته شد، حیوان ۶ ماه بعد از پروسه جراحی به دلیل رشد مجدد توده در همان ناحیه، به درخواست صاحبش یوتانازی شد.

کاربرد بالینی- این گزارش توصیف مشخصات تصویربرداری تشخیصی و هیستوپاتولوژی همانژیوپرپرسیتوما در محل تزریق واکسن در یک قلابه سگ می‌باشد که می‌تواند تصویری دقیق جهت پروسه جراحی برداشت تومور را دربر داشته باشد. این عارضه در سگ‌سانان نسبت به گربه‌سانان رایج نیست.

کلمات کلیدی- همانژیوپرپرسیتوما، سی‌تی‌اسکن آنژیوگرافی، اولتراسونوگرافی