

Successful Treatment of Infective Endocarditis in Four Kidney Transplant Recipients

Fatemeh Pour-Reza-Gholi, Farhat Farrokhi, Behzad Einollahi, Eghlim Nemati

Department of Kidney Transplantation, Shaheed Labbafinejad Medical Center, Shaheed Beheshti Medical University, Tehran, Iran

Keywords. kidney transplantation, endocarditis, heart valvular diseases, cytomegalovirus, infection

Infective endocarditis (IE) is a serious complication in kidney transplantation, leading to graft loss and a high mortality rate. We report 4 successfully managed cases of IE in kidney transplant recipients. Blood culture revealed *Enterococcus* in 2 patients, group D *Streptococcus* in 1, and no bacteria in 1. All of the patients were diagnosed based on at least 2 major Duke criteria for diagnosis of IE. Although a mild increase in the serum creatinine level was observed in 3 out of 4 patients, no graft rejection occurred during the follow-up. Early diagnostic and therapeutic intervention, particularly intensive antibiotic therapy and surgical management can preserve the patient and the kidney allograft. Studies on previous recurrent infections and simultaneous diseases such as cytomegalovirus in these patients are warranted.

IJKD 2007;1:43-5
www.ijkd.org

INTRODUCTION

Infective endocarditis (IE) has been reported as a serious complication following kidney transplantation that can lead to graft loss and a high mortality rate.¹ However, the exact role of kidney transplantation as a potential risk factor of endocarditis is not elucidated. Moreover, the incidence of the IE and its common pathogens has not been studied yet. We report 4 successfully managed cases of IE in our kidney transplant recipients.

CASE REPORT

Case 1

A 28-year-old woman was admitted with fever and tachycardia 6 months after kidney transplantation. She had suffered from recurrent urinary infections, once with a positive urine culture for *Enterococcus*. Laboratory investigations showed anemia (serum hemoglobin, 7.2 g/dL; hematocrit, 0.23; and serum creatinine, 1.46 mg/dL). Electrocardiography was only indicative of sinus tachycardia. The patient

was started on empirical antimicrobial therapy. On day 5 of admission, productive cough and headache began and a positive serum cytomegalovirus antigen (CMV Ag) was detected. Mild to moderate renal impairment was reported on renal scintigraphy and the serum creatinine increased up to 2.39 mg/dL. Transthoracic echocardiography (TTE) was negative for specific signs of the IE. On day 14, thrombocytopenia, leucopenia, pleural effusion and diffused infiltration on plain chest radiography were found. Blood culture was positive for *Enterococcus*, sensitive to vancomycin in 2 samples. Transesophageal echocardiography (TEE) revealed multiple vegetations on the mitral valve, the largest one up to 1.5 × 1.5 cm, and a single vegetation on the aortic valve (Figure 1). After the administration of vancomycin the patient became asymptomatic and pancytopenia was improved at discharge. Elective aortic and mitral valve replacement surgery was performed successfully 1 month later. After a 1-year follow-up, she had no complications and the latest serum creatinine level was 2.0 mg/dL.

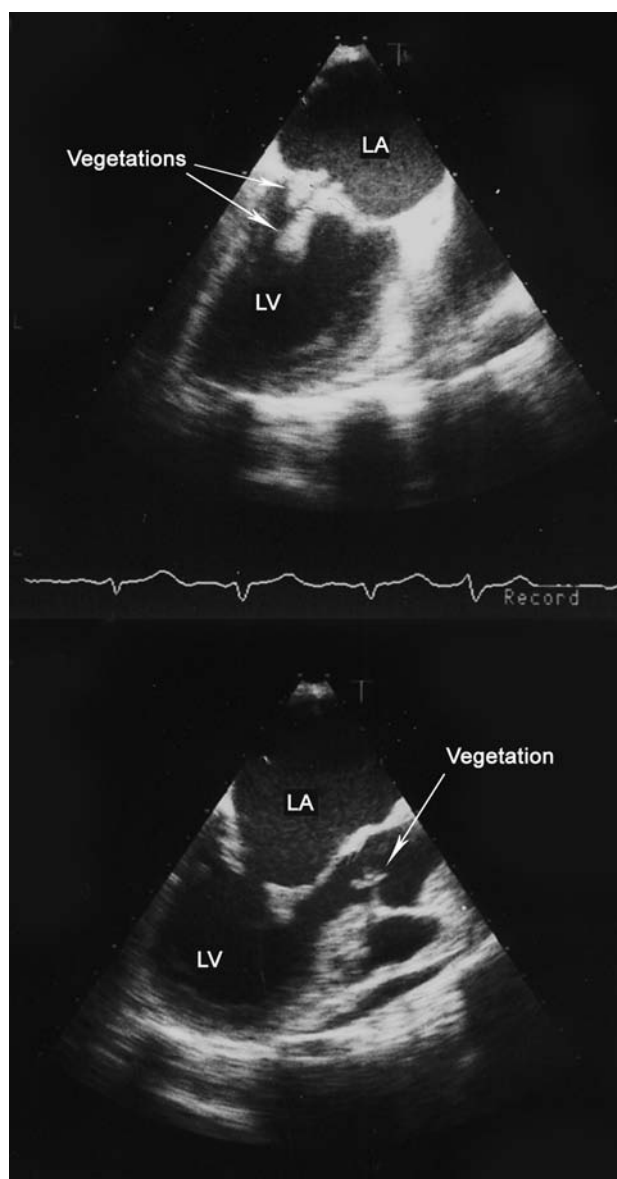


Figure 1. Multiple vegetations on the mitral valve and single vegetation on the aortic valve were detected by transesophageal echocardiography in a 28-year-old woman 6 months after kidney transplantation.

Case 2

A 22-year-old man presented with fever, nausea, headache, and cough, 5 months after kidney transplantation. Laboratory tests showed hypochromic anemia (hemoglobin, 7.7 g/dL) and a mild serum creatinine elevation (2.0 mg/dL). On physical examination, a systolic murmur of mitral valve was auscultated. He had a positive blood culture for *Enterococcus* sensitive to ampicillin. Mild mitral regurgitation and aortic insufficiency were found on TTE. Ampicillin (2 g/d) was administered, but fever recurred after

3 days. Subsequently, vancomycin and amikacin were added. Micofenolate mofetil was held on day 7. Multiple large vegetations on the aortic valve were detected by TEE on the 9th day. The patient was referred for emergent aortic valve replacement therapy. One month thereafter, the patient was referred back to our center. While he was asymptomatic, CMV infection was detected and ganciclovir was started. In the next 3 months, serum creatinine was stable (up to 2.18 mg/dL) and no complication was observed.

Case 3

A 33-year-old man with a second kidney transplant and a history of recurrent urinary tract infections was referred with lateralized symptoms due to an infarction in the right hemisphere of the brain, fever, hemiparesis, vertigo, and dyspnea. He had been hospitalized 1 month earlier with intermittent fever, weight loss, and serum creatinine elevation, but empirical pulse steroid therapy had been discontinued due to a suspicion of infection. On physical examination, systolic and diastolic murmurs of the mitral valve were detected. Laboratory tests results were as follows: hemoglobin, 9.3 g/dL; platelet count, $141 \times 10^9/L$; and serum creatinine, 1.9 mg/dL. Electrocardiography was indicative of a severe left ventricular hypertrophy and TTE showed mild dilatation of the left ventricle, pericardial effusion, and a moderate aortic regurgitation. Blood cultures were negative for bacteria. The patient was started on cefazolin and amikacin. Fever was relieved on the second day, but a mild creatinine increase developed. Transesophageal echocardiography was obtained and large vegetations on the aortic valve were observed (Figure 2). The patient was referred for emergent surgery. Forty-two months after aortic valve replacement, his kidney allograft function did not change, but hemiparesis remained.

Case 4

A 19-year-old man with a kidney allograft presented with intermittent fever on the 4th posttransplant month. His laboratory tests results were: hemoglobin, 9.9 mg/dL; platelet count, $123 \times 10^9/L$; white blood cell count, $8.2 \times 10^9/L$; and serum creatinine, 0.9 mg/dL. After detection of aortic regurgitation by TTE, an aortic valve vegetation (10 × 3 mm) was seen on TEE.

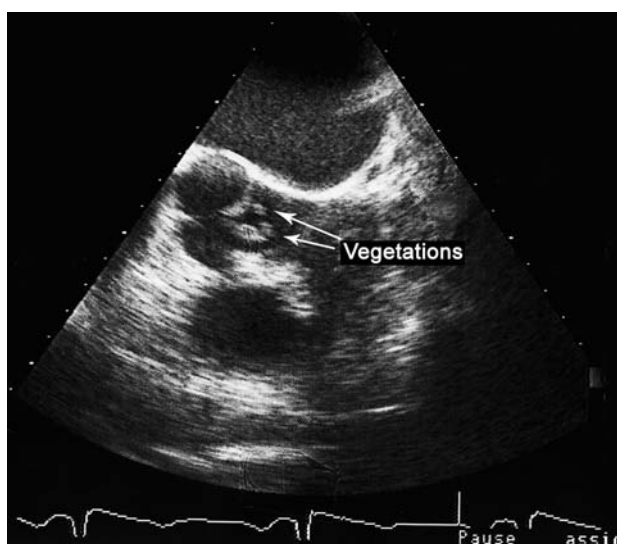


Figure 2. Transesophageal echocardiography revealed large vegetations on the aortic valve in a 33-year-old man with a second kidney transplant.

Vancomycin, ceftriaxone, and amikacin were administered empirically and fever was alleviated. Blood culture was positive for group D *Streptococcus* in 2 samples, sensitive to vancomycin. On day 7, CMV infection was detected and the patient was started on ganciclovir. The patient was discharged after a 1-month hospitalization he was asymptomatic and serum CMV Ag test was negative. However, he was hospitalized again for chest pain episodes, and aortic valve replacement was performed 1 month afterwards. On the last follow-up visit (11 months) serum creatinine level was 1.1 mg/dL.

DISCUSSION

While fungi and *Staphylococcus aureus* seem to be the most common pathogens of IE in kidney transplant patients,^{1,2} many other organisms are anticipated to be responsible in this group of patients. Two out of 4 patients in our series had bacteremia with *Enterococcus*. One case of vancomycin-resistant *Enterococcus faecium* was reported by Thompson and colleagues in 2003.³ They treated the patient by combination therapy including high-dose ampicillin. One of our patients responded to vancomycin, but the other did not improve by antibiotic therapy and subsequently underwent emergent surgery. Group D *Streptococcus*, which was observed in 1 case, has been reported in 4.1% of cases.¹ Our report agrees with the studies that have shown that gram-positive organisms are more common in kidney recipients with IE.¹

In a retrospective registry study on 73 kidney recipients with IE in the United States, a history of hospitalization for a valvular heart disease was associated with posttransplant IE. However, no significant history of heart disease was reported in our 4 patients, but recurrent urinary infections in 2 and concurrent CMV infection in 3 were noticeable. Such a nebulous association of CMV and IE in kidney recipients has been reported before.^{1,4} Further immunosuppression by CMV infection may have a role.⁴

Aortic and mitral valve replacements are the most required surgeries for the kidney recipients with IE (6.9% and 5.5%, respectively).¹ Although more than 50% mortality is reported in these patients,⁽⁵⁾ we could manage all the 4 patients and the graft outcome was desirable. All of the patients were diagnosed based on at least 2 major Duke criteria for diagnosis of IE, and TEE confirmed our diagnoses. Finally, a prompt and intensive antimicrobial treatment strategy should be considered.

REFERENCES

1. Abbott KC, Duran M, Hypolite I, Ko CW, Jones CA, Agodoa LY. Hospitalizations for bacterial endocarditis after renal transplantation in the United States. *J Nephrol.* 2001;14:353-60.
2. Paterson DL, Dominguez EA, Chang FY, Snyderman DR, Singh N. Infective endocarditis in solid organ transplant recipients. *Clin Infect Dis.* 1998;26:689-94.
3. Thompson RL, Lavin B, Talbot GH. Endocarditis due to vancomycin-resistant *Enterococcus faecium* in an immunocompromised patient: cure by administering combination therapy with quinupristin/dalfopristin and high-dose ampicillin. *South Med J.* 2003;96:818-20.
4. Viertel A, Ditting T, Pistorius K, Geiger H, Scheuermann EH, Just-Nubling G. An unusual case of *Aspergillus* endocarditis in a kidney transplant recipient. *Transplantation.* 1999;68:1812-3.
5. Bishara J, Robenshtok E, Weinberger M, Yeshurun M, Sagie A, Pitlik S. Infective endocarditis in renal transplant recipients. *Transpl Infect Dis.* 1999;1:138-43.

Correspondence to:

Fatemeh Pour-Reza-Gholi, MD
 Department of Nephrology, Shaheed Labbafinejad Medical Center, 9th Boushan, Pasdaran, Tehran, Iran
 Tel: +98 21 2256 7222
 Fax: +98 21 2256 7282
 E-mail: pourrezagholi@unrc.ir

Received December 2007

Revised January 2007

Accepted March 2007