

Successful Treatment of Mucormycosis After Kidney Transplantation

Amirhossein Miladipour,¹ Esmat Ghanei,¹ Alireza Nasrollahi,¹ Habibollah Moghaddasi²

¹Division of Nephrology, Department of Internal Medicine, Shohada-e-Tajrish Hospital, Shahid Beheshti University (MC), Tehran, Iran

²Department of Head and Neck Surgery, Loghman-e-Hakim Hospital, Shahid Beheshti University (MC), Tehran, Iran

Keywords. mucormycosis, sinusitis, kidney transplantation, amphotericin B

Fungal infections are rare but represent serious complications following organ transplantation. We present a case of mucormycosis primarily affecting the paranasal sinuses in a 51-year-old man with a kidney allograft. The patient presented with headache, left facial and orbital pain, nasal discharge, and elevation of serum creatinine 18 months after kidney transplantation. Laboratory tests revealed cyclosporine nephrotoxicity, cytomegalovirus infection, and prediabetes. Imaging findings were compatible with left maxillary, ethmoidal, and sphenoidal sinusitis. Diagnosis was made based on pathologic findings and detection of typical fungal hyphae in the infected tissues. The patient was successfully treated by discontinuation of cyclosporine and mycophenolate mofetil, initiation of systemic amphotericin B, and aggressive surgical debridement.

IJKD 2008;2:163-6
www.ijkd.org

INTRODUCTION

Fungal pathogens, although a rare cause of infection, remain a major diagnostic challenge and are associated with high mortality rate in kidney transplant recipients. The incidence of fungal infection after kidney transplantation is somewhat higher in countries with hot climates such as Iran.

Mucormycosis is usually a rapidly progressive and frequently fatal infection in kidney transplant recipients.¹ Rhinocerebral, pulmonary, cutaneous, and gastrointestinal lesions together with sinusitis are the most common forms of mucormycosis infection in these patients.² We describe a case of a kidney allograft recipient who developed rhinocerebral mucormycosis and was treated successfully.

CASE REPORT

A 51-year-old man with end-stage renal disease due to chronic hypertension underwent kidney transplantation from a living unrelated donor in 2004. His postoperative course was uneventful

up to the 18th month, when he was admitted to our center for headache, general weakness, nasal discharge, and elevated serum creatinine level. He had a history of left maxillary dental extraction and antibiotic therapy 2 weeks ago, and also, a history of headache, left orbital pain, and nasal discharge from 10 days earlier. Immunosuppression protocol consisted of cyclosporine, 250 mg/d, mycophenolate mofetil, 2 g/d, and prednisolone, 5 mg/d.

Physical examination did not reveal any specific sign and he was afebrile. His laboratory tests results were as follow: serum creatinine, 4.6 mg/dL; blood urea, 70 mg/dL; and fasting blood glucose, 118 mg/dL. Other laboratory tests including urinalysis, complete blood count, liver enzymes, and serum bilirubin were normal. Serum cyclosporine levels, as measured by whole blood radioimmunoassay, were markedly elevated (trough level, 524 ng/mL, 2-hour postdose level, 1374 ng/mL). Cyclosporine dose was immediately reduced, and subsequently, serum creatinine level decreased to 2.2 mg/dL.

Radiography of the paranasal sinuses revealed opacification of the left ethmoidal and maxillary sinuses. Therefore, the patient was treated with ceftriaxone and metronidazole. On day 6, he had worsening of his headache and left facial and orbital pain. Brain computed tomography (CT), electroencephalography, and neurological and ophthalmologic examination did not show any abnormality. On day 10, the patient became febrile (temperature, 38°C) and cytomegalovirus antigen became positive. Ganciclovir, 250 mg/d, was started on and cyclosporine and

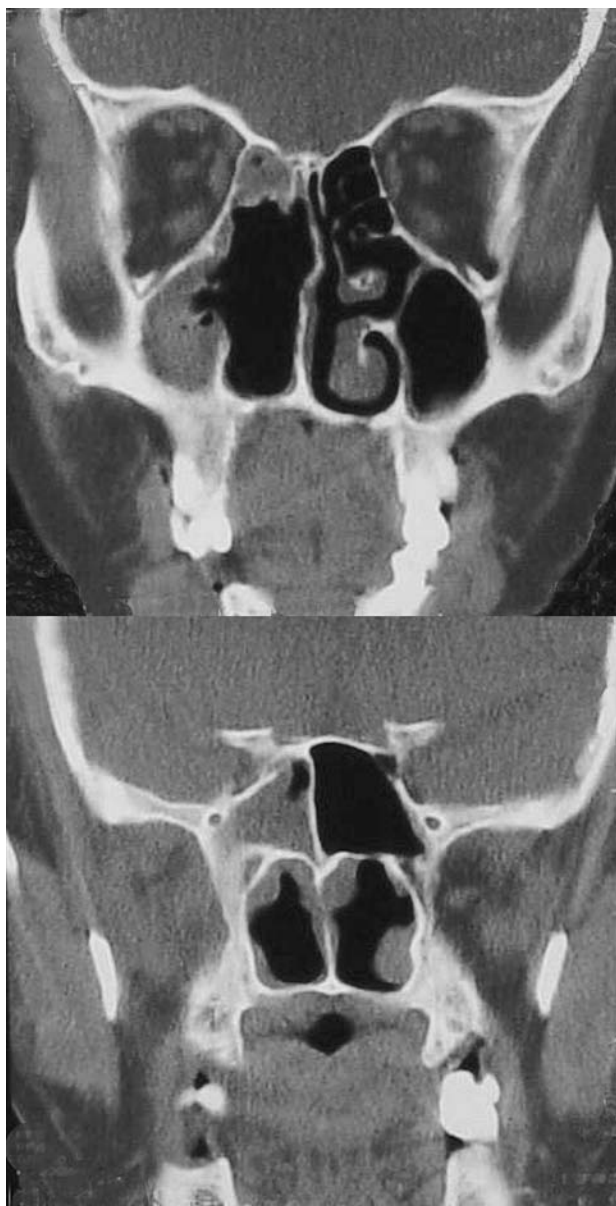

Figure 1. Coronal computed tomography scan with opacification of the left-sided sinuses (maxillary, ethmoidal, and sphenoidal).

mycophenolate mofetil doses were decreased to 100 mg/d and 1 g/d, respectively. He also developed hyperglycemia which was managed by exogenous insulin.

On day 14, because of fever, pain, and edema on the left side of his face, the patient underwent a CT of the sinuses that showed opacification of the left maxillary, ethmoidal, and sphenoidal sinuses (Figure 1). Therefore, he underwent functional endoscopic sinus surgery. Definite diagnosis of mucormycosis was then made by pathologic examination (Figure 2). Metronidazole, ceftriaxone, cyclosporine, and mycophenolate mofetil were discontinued, and amphotericin B, 15 mg/d, was started on. Amphotericin dose gradually increased up to 50 mg/d within 3 days. Also, prednisolone dose was increased to 20 mg/d. The patient underwent aggressive surgical debridement.

On day 24, the patient became afebrile, and cyclosporine, 100 mg/d, was started again. On day 45, the patient complained of pleuritic chest pain, and fever. Laboratory data and CT revealed pulmonary abscess in the left lower lobe and empyema. Culture result of the pleural effusion showed *Klebsiella* that was treated with appropriate antibiotic and chest tube indwelling.

After 70 days of hospital stay, the patient was discharged with a good condition. Serum creatinine level was 1.6 mg/dL. After a 3-year follow-up, he had no complications, and serum creatinine level was 1.5 mg/dL. Immunosuppressive drugs consisted of cyclosporine, 125 mg/d, Azathioprine, 50 mg/d, and prednisolone, 5 mg/d.

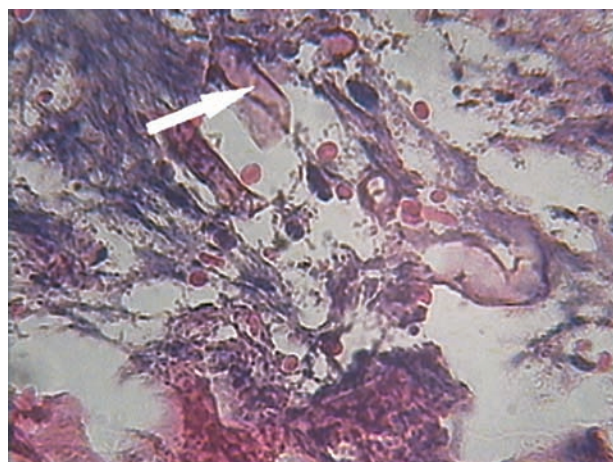


Figure 2. The arrow shows aseptate broad fungal hyphae within the necrotic area (hematoxylin-eosin, × 40).

DISCUSSION

Mucormycosis is a fungal infection due to organisms in the order Mucorales. These organisms belong to the general class Zygomycetes, which are ubiquitous. They can be found in decaying vegetables, spoiled food (for example bread mould). These organisms can occasionally be cultured from noninfected individuals. Risk factors of mucormycosis include hematologic malignancies, diabetes mellitus—particularly when associated with ketoacidosis—, steroids and immunosuppressive agents used in bone marrow, solid organ transplantation, broad-spectrum antibiotics, cytotoxic chemotherapy, burns, and dialysis.^{1,3}

Mucormycosis can have multiple clinical presentations. The most common manifestation is the rhinocerebral form, involving the nose, paranasal sinuses, orbits, and central nervous system. Others include cutaneous, gastrointestinal, pulmonary, and disseminated forms. The rhinocerebral form has been subclassified into rhinomaxillary and rhinocerebralorbital by some.⁴ There are a few case reports of rhinocerebral or maxillary mucormycosis after dental extractions.^{4,5} There are also rare case reports of mixed infection of cytomegalovirus and mucormycosis and potentiation of mucormycosis by cytomegalovirus in kidney transplant recipients.^{6,7}

The fungus enters the body through either the respiratory tract, the gastrointestinal tract, or a damaged skin barrier. Augmented immunosuppression for treatment of rejection, mainly in the form of steroids, may accelerate the course of infection. An important characteristic feature of *Mucor* hyphae is their propensity to invade the blood vessels, causing thrombosis and multiple infarctions and hemorrhages of the visceral organs. Usually, these pathologic changes are associated with minimal inflammatory response, because the specific cells are depleted or their function is impaired. Vessel thrombosis by *Mucor* fungi and tissue necrosis are 2 major hallmarks of mucormycosis.¹ Rhinocerebral mucormycosis typically begins with invasion of the hyphae to the paranasal sinuses or the oronasal cavity of a susceptible host. Early symptoms may include perinasal paresthesias, periorbital edema, cellulitis, rhinorrhea, nasal crusting, unilateral headache, facial swelling and pain, and ophthalmoplegia.

These features are quickly superseded by eschar formation and necrosis of the nasofacial region. Advancing infection can quickly result in cavernous sinus thrombosis, carotid artery or jugular vein thrombosis (Lemierre Syndrome) and death.^{3,4}

The diagnosis is based on history, clinical examination, diagnostic radiography, and biopsy.⁴ Since mucormycosis is a rare disease in transplant recipients, a high index of suspicion is required, which should be followed by an aggressive attempt to obtain tissue for histologic and bacteriologic studies from affected organs. Extract of fungal elements from body fluids (sputum, urine, sinuses, etc) is difficult. The hallmark of mucormycosis includes the typical, wide, ribbon-like, hyaline, predominantly aseptate hyphae with wide-angle branching within nodular and necrotic areas of infection. These can be demonstrated using hematoxylin-eosin staining; however, more specific fungal stains are usually helpful.¹

Therapy with amphotericin B, surgical debridement, and correction of the underlying predisposing condition offers the best chance for survival.⁸ Intravenous amphotericin B remains the gold standard for successful treatment of zygomycosis. However, its usage is limited by potentially severe side effects such as kidney dysfunction. The liposomal preparation of amphotericin B such as posaconazole may alleviate this problem to a considerable extent. Furthermore, it tends to be superior to the conventional amphotericin B in efficacy, tolerability, curative effect, fungal clearance rate, and adverse effects.^{9,10}

Invasive fungal infections are among the most severe complications which carry a high mortality rate. There are only a few reports of survival in cases of mucormycosis affecting kidney transplant recipients.¹¹ In a review of 106 cases in the literature, the overall mortality was 49%. While rhino-sino-orbital disease had the best prognosis, rhinocerebral disease had a higher mortality rate (93%) comparable to disseminated disease. A favorable outcome is associated with limited involvement, surgically accessible disease, early surgical intervention, and amphotericin B administration.¹²

Our patient was a kidney allograft recipient with predisposing factors of immunosuppression, prediabetes, cytomegalovirus infection, cyclosporine nephrotoxicity, and history of maxillary dental

extraction. He was treated with amphotericin B and aggressive surgical debridement. The outcome was excellent with survival of the patient and the graft and no morbidity. We emphasize considering a high index of suspicion, leading to early diagnosis. In our experience, initiation of antifungal treatment and aggressive surgical debridement are keys to a favorable outcome.

CONFLICT OF INTEREST

None declared.

REFERENCES

1. Chkhotua A, Yussim A, Tovar A, et al. Mucormycosis of the renal allograft: case report and review of the literature. *Transpl Int*. 2001;14:438-41.
2. Chacko B, David VG, Tamarasi V, Deepti AN, John GT. Pulmonary mucormycosis in a nondiabetic renal allograft recipient successfully managed by medical therapy alone. *Transplantation*. 2007;83:1656-7.
3. Ladurner R, Brandacher G, Steurer W, et al. Lessons to be learned from a complicated case of rhino-cerebral mucormycosis in a renal allograft recipient. *Transpl Int*. 2003;16:885-9.
4. Fogarty C, Regennitter F, Viozzi CF. Invasive fungal infection of the maxilla following dental extractions in a patient with chronic obstructive pulmonary disease. *J Can Dent Assoc*. 2006;72:149-52.
5. Kim J, Fortson JK, Cook HE. A fatal outcome from rhinocerebral mucormycosis after dental extractions: a case report. *J Oral Maxillofac Surg*. 2001;59:693-7.
6. Ju JH, Park HS, Shin MJ, et al. Successful treatment of massive lower gastrointestinal bleeding caused by mixed infection of cytomegalovirus and mucormycosis in a renal transplant recipient. *Am J Nephrol*. 2001;21:232-6.
7. Andrews PA, Abbs IA, Koffman CG, Ogg CS, Williams DG. Mucormycosis in transplant recipients: possible case-case transmission and potentiation by cytomegalovirus. *Nephrol Dial Transplant*. 1994;9:1194-6.
8. Al Soub H, El Deeb Y, Almaslaman IM, Al Khuwaiter JY. Zygomycosis in Qatar: a retrospective review of six cases. *Eur Ann Allergy Clin Immunol*. 2004;36:387-91.
9. Jayasuriya NS, Tilakaratne WM, Amaratunga EA, Ekanayake MK. An unusual presentation of rhinofacial zygomycosis due to *Cunninghamella* sp. in an immunocompetent patient: a case report and literature review. *Oral Dis*. 2006;12:67-9.
10. Tobon AM, Arango M, Fernandez D, Restrepo A. Mucormycosis (zygomycosis) in a heart-kidney transplant recipient: recovery after posaconazole therapy. *Clin Infect Dis*. 2003;36:1488-91.
11. Aslani J, Eizadi M, Kardavani B, et al. Mucormycosis after kidney transplantations: report of seven cases. *Scand J Infect Dis*. 2007;39:703-6.
12. Almyroudis NG, Sutton DA, Linden P, Rinaldi MG, Fung J, Kusne S. Zygomycosis in solid organ transplant recipients in a tertiary transplant center and review of the literature. *Am J Transplant*. 2006;6:2365-74.

Correspondence to:

Amirhossein Miladipour, MD

Department of Internal Medicine, Shohada-e-Tajrish Hospital, Tajrish Sq, Tehran, Iran

Tel: +98 21 8878 0083

Fax: +98 21 6643 0888

E-mail: amiladi@hotmail.com

Received December 2007

Revised March 2008

Accepted April 2008