

Hereditary Spherocytosis With Immunoglobulin A Nephropathy

Nese Karaaslan Biyikli,¹ Ibrahim Gokce,¹ Fulya Cakalagaoglu,²
Emine Turkkan,³ Harika Alpay¹

¹Department of Pediatric Nephrology, Marmara University School of Medicine, Istanbul, Turkey

²Department of Pathology, Marmara University School of Medicine, Istanbul, Turkey

³Department of Pediatric Hematology, Okmeydani Research and Training Hospital, Ministry of Health, Turkey

Keywords. IgA glomerulonephritis, hereditary spherocytosis, child, hemolytic anemia

Hereditary spherocytosis is a familial hemolytic anemia. Immunoglobulin A (IgA) nephropathy associated with hereditary spherocytosis has not been reported in children. Here, we report a case of a 17-year-old boy with IgA nephropathy and hereditary spherocytosis. The patient was diagnosed with hereditary spherocytosis at the age of 12 years and splenectomy was done at the age of 15 years. Later, the patient presented with macroscopic hematuria and proteinuria. Kidney biopsy of the boy was consistent with IgA nephropathy. Treatment with angiotensin-converting enzyme inhibitor was started. The patient became free of proteinuria after the 6th month of therapy.

IJKD 2010;4:78-81
www.ijkd.org

INTRODUCTION

Hereditary spherocytosis is an inherited hemolytic anemia characterized by anemia, jaundice, and splenomegaly. Clinical severity of the disease is variable. Some individuals are asymptomatic, whereas others have severe hemolytic anemia requiring erythrocyte transfusion.¹ The primary lesion in hereditary spherocytosis is loss of membrane surface area that results in reduced deformability due to defects in the membrane proteins ankyrin, band 3, beta spectrin, alpha spectrin, or protein 4.2. Band 3 and spectrin deficiencies are the most common protein abnormalities.¹ The association of hereditary spherocytosis with glomerular diseases such as minimal change disease, focal glomerulosclerosis, and membranoproliferative glomerulonephritis has been reported in the literature.² To our knowledge, immunoglobulin A (IgA) nephropathy associated with hereditary spherocytosis has not been reported before. Here, we describe a patient with hereditary spherocytosis who presented with macroscopic hematuria and proteinuria, diagnosed with IgA nephropathy.

CASE REPORT

A 17-year-old boy presented with macroscopic

hematuria. For the past 2 years, he had been complaining of recurrent episodes of macroscopic hematuria at the time of an upper respiratory tract infection. He was born to a second-degree related intermarried parents and had 2 healthy older brothers. The patient had a history of recurrent jaundice in the past, and a diagnosis of hereditary spherocytosis with hemolytic jaundice had been made at the age of 12 years. He had undergone splenectomy at the age of 15 years and had not had any episodes of jaundice, subsequently. There was no family history of renal or hematological disease.

Physical examination revealed weight and height in the 10th percentile. Blood pressure was normal. Systemic examination did not reveal any other abnormality, and there was no evidence of any systemic infection. Laboratory data included a white blood cell count of $8 \times 10^9/L$, haemoglobin of 13 g/dL, hematocrit of 38%, and a platelet count of $450 \times 10^9/L$. Peripheral smear showed microspherocytes and acanthocytes. The osmotic fragility was increased. The total serum protein concentration was 7.6 g/dL, with a serum albumin level of 4.5 g/dL. Serum creatinine level was 0.6 mg/dL. Serum lipids, bilirubin, lactate dehydrogenase, and hepatic transaminases were

all within reference ranges for age. The Coombs' test showed negative results, and reticulocyte count was 1.2%. Hemoglobin electrophoresis was normal. Serum iron, ferritin, vitamin B12, and folic acid levels were within reference ranges. Erythrocyte sedimentation rate was 16 mm/h. Glomerular filtration rate was 144 mL/min/1.73 m². Urinalysis showed macroscopic hematuria and hyaline casts. Urine and blood culture findings were negative for microorganisms. Daily proteinuria was 12 mg/m²/h to 35 mg/m²/h. Results of serological tests were as follows: serum complement 3 level was 110 mg/dL (70 mg/dL to 210 mg/dL) and serum complement 4 level was 24 mg/dL (10 mg/dL to 40 mg/dL). Serum IgA, IgG, IgM, and IgE levels were within reference range. Markers of autoimmunity (antineutrophilic cytoplasmic antibody, antinuclear antibody, and anticardiolipin antibodies), viral serology (hepatitis A, hepatitis B, cytomegalovirus, Epstein-Barr virus, and human immune deficiency virus) were absent, and antistreptolysin O titer produced negative results. Findings of the purified protein derivative test were negative. Abdominal ultrasonography showed normal-sized kidneys with bilateral grade 1 hyperechogenicity. The spleen was not visualized.

A percutaneous kidney biopsy was performed. Light microscopy of the specimen showed focal proliferation in the mesangial matrix of the glomeruli (Figure 1). Grade one interstitial fibrosis

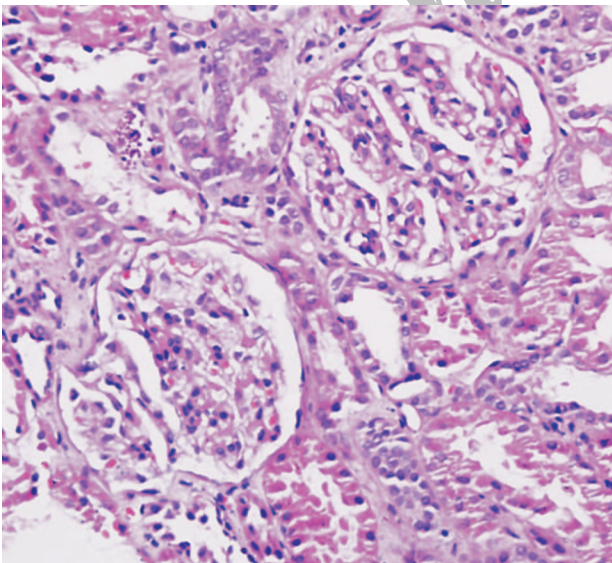


Figure 1. Light microscopic examination of the kidney biopsy specimen showed focal proliferation in cells and matrix of the glomeruli (hematoxylin-eosin, × 20).

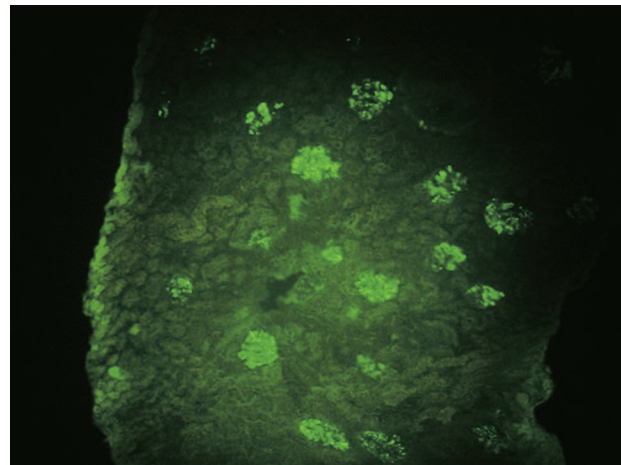


Figure 2. Immunofluorescence microscopy showed mesangial staining for IgA (FITC antihuman IgA, × 400).

was observed. There was no crescent. Hemosiderin staining was negative. Immunofluorescence microscopy demonstrated IgA (2+), IgG (1+), and complement 3 (1+) in the mesangial area (Figure 2). Electron microscopy confirmed dense deposits in the paramesangial area. The pathologic findings were consistent with IgA nephropathy, World Health Organization Class II.

Treatment with an angiotensin-converting enzyme inhibitor (enalapril, 0.1 mg/kg/d) was started. Proteinuria improved after 6 months of renoprotective therapy. On the last follow-up visit of the patient at the age of 19 years, serum creatinine was 0.8 mg/dL and recurrent macroscopic hematuria without persistent proteinuria continued.

DISCUSSION

To our knowledge, the present report is the first in the English literature reporting the coexistence of hereditary spherocytosis and IgA nephropathy. Disorders of red blood cell enzymes, membranes, and hemoglobin cause hereditary hemolytic anemia.¹ Nephropathy has seldomly been reported in patients with hemolytic anemias. Sickle cell nephropathy is the most common and known form of kidney disease occurring in hemolytic anemias.² Renal tubular acidosis, papillary necrosis, cortical infarction, glomerular enlargement, and chronic glomerulonephritis are the reported renal syndromes in sickle cell disorders.³ The proposed mechanisms responsible for kidney impairment in sickle cell nephropathy include iron overload and deposition in the

kidneys, causing renal hemochromatosis, continued intracapillary fragmentation and phagocytosis of sickled erythrocytes, immune complex formation, hyperfiltration, and/or intrinsic glomerular capillary injury.³⁻⁵ Focal segmental glomerulosclerosis-like and membranoproliferative glomerulonephritis-like diseases without immune complex deposits were the most frequently identified structural glomerular abnormalities in patients with sickle cell anemia.³ Membranoproliferative glomerulonephritis type 1 with immune complex deposition has been documented in only 12 cases in the literature.^{4,5}

Glomerular disease was also observed in experimental animal model studies of chronic hemolysis. Mice, *Afgkan pika*, and owl monkeys were the species that showed the coexistence of hemolytic anemia and glomerular disease.⁶⁻⁸ Mutant mice with congenital hemolytic anemia showed glomerulonephritis.⁶ Histopathological examination of the kidneys showed mild to marked membranoproliferative glomerulonephritis with mesangial proliferation, capillary wall thickening, and focal splitting of peripheral basement membrane. The deposition of IgA, IgM, complement 3, and IgG was present in the anemic mice. This immune complex-type glomerulonephritis was attributed to continued erythrocyte fragmentation and exposure to occult antigens, leading to a persistent immune response.

Human kidney diseases reported in patients with hereditary spherocytosis are focal segmental sclerosis, minimal change disease, and membranoproliferative glomerulonephritis.² The coexistence was attributed to an immunological cross-reaction between the erythrocyte membrane proteins and glomerular capillary membrane proteins, alterations in intracellular or cell-membrane-associated proteins in the renal glomerular cells leading to chronic antigenemia, and/or circulating immune complexes.² Many conditions have been reported to be associated with the development of IgA deposits, with associated glomerular histologic changes and clinical manifestations.⁹ Conditions associated with secondary IgA nephropathy are rheumatic and autoimmune diseases, gastrointestinal diseases, hepatic diseases, lung diseases, malignancy, and infections.⁹ No cases of hemolytic anemias are reported with secondary IgA nephropathy. The kidney biopsy of the presented case was consistent with IgA nephropathy. Although

we could not measure the circulating immune complexes in this patient, the deposition in the mesangial areas support the pathogenetic role of immune complex-mediated disease in this patient. Splenectomy might be attributed to the development of IgA nephropathy by impairing the clearance of circulating immune complexes. The role of splenectomy in the eradication of circulating immune complexes was studied by Donadi and coworkers.¹⁰ They noted a distinctive pattern of circulating immune complexes containing factor B in patients who had undergone splenectomy for nonmalignant conditions. Morino and colleagues observed IgA nephropathy in a 14-year-old boy who had splenectomy at the age of 2 years for idiopathic thrombocytopenic purpura.¹¹ Decreased clearance of circulating immune complexes or impaired immune function might be the consequences of splenectomy leading to susceptibility to IgA nephropathy.¹¹ However, we cannot exclude the probability of the existence of these two diseases by chance.

It has been reported that angiotensin converting enzyme inhibitors decrease proteinuria in sickle cell nephropathy. In this case, we gave enalapril in a dose of 0.1 mg/kg/d that resulted in the improvement of proteinuria in 6 months. During the 2-year follow-up, recurrent macroscopic hematuria without persistent proteinuria continued with normal kidney function tests. In summary, this is the first child, to our knowledge, reported with concurrent hereditary spherocytosis and IgA nephropathy.

CONFLICT OF INTEREST

None declared.

REFERENCES

1. Perrotta S, Gallagher PG, Mohandas N. Hereditary spherocytosis. *Lancet*. 2008;372:1411-26.
2. Mathew A, Varghese J, Kurian G, Unni VN. Hereditary spherocytosis with nephrotic syndrome. *Indian J Nephrol*. 2007;17:174-5.
3. Pham PT, Pham PC, Wilkinson AH, Lew SQ. Renal abnormalities in sickle cell disease. *Kidney Int*. 2000;57:1-8.
4. Iskandar SS, Morgan RG, Browning MC, Lorentz WB. Membranoproliferative glomerulonephritis associated with sickle cell disease in two siblings. *Clin Nephrol*. 1991;35:47-51.
5. Pardo V, Strauss J, Kramer H, Ozawa T, McIntosh

- RM. Nephropathy associated with sickle cell anemia: an autologous immune complex nephritis. II. Clinicopathologic study of seven patients. *Am J Med.* 1975;59:650-9.
6. Maggio-Price L, Russell R, Wolf NS, Alpers CE, Engel D. Clinicopathological features of young and old *spha/spha* mice. Mutants with congenital hemolytic anemia. *Am J Pathol.* 1988;132:461-73.
 7. Okudaira H, Terada E, Ito T, et al. Autoimmune glomerulonephritis and hemolytic anemia in a new laboratory animal, the Afghan pika. *Clin Immunol Immunopathol.* 1981;21:375-86.
 8. Chalifoux LV, Bronson RT, Sehgal P, Blake BJ, King NW. Nephritis and hemolytic anemia in owl monkeys (*Aotus trivirgatus*). *Vet Pathol.* 1981;18:23-37.
 9. Freehally J. IgA nephropathy and Henöch-Schönlein nephritis. In: Johnson RJ, Feehally J, editors. *Comprehensive clinical nephrology.* Philadelphia: Mosby, Harcourt Publishers; 2000. p. 5.26.1.
 10. Donadi EA, Carvalho IF, Falcao RP. Circulating immune complexes after splenectomy. *J Clin Pathol.* 1989;42: 69-71.
 11. Morino M, Inami K, Shibuya A, Sasaki N. IgA nephropathy and idiopathic thrombocytopenic purpura with splenectomy: a case report. *Pediatr Nephrol.* 1994;8: 345-46.

Correspondence to:

Nese Karaaslan Biyikli, MD
Kozyatagi, Sinanercan cd, Oztor sitesi, C Blok, 38/38
34736, Istanbul, TURKEY
Tel: + 90 533 425 7909
E-mail: nesebiyikli@superonline.com

Received July 2009
Revised September 2009
Accepted September 2009

Archive of SID