

# Guide Wire Migration During Femoral Vein Catheterization

Mohammad Reza Khatami, Rozita Abbasi, Gelareh Sadigh

Department of Nephrology,  
Imam Khomeini Hospital,  
Tehran University of Medical  
Sciences, Tehran, Iran

**Keywords.** acute kidney  
failure, catheterization,  
hemodialysis

Central vein catheterization is a routine and relatively safe procedure in critically ill patients. Complications with this procedure depend to the site of catheterization and the skill of the operator. In addition to the common complications with femoral vein catheterization there are some rare usually preventable side effects related to guide wire and catheter. In our patient who underwent femoral catheterization for acute hemodialysis, we report migration of guide wire through the systemic circulation from the femoral vein to the jugular vein. This is a very rare complication that is a human error and is totally preventable by doing the procedure by a skilled doctor and considering the standards described for central vein catheter insertion.

IJKD 2010;4:333-5  
www.ijkd.org

## INTRODUCTION

Central vein catheterization may be a life-saving procedure in critically ill patients. It is also a routine relatively safe procedure for emergent hemodialysis, providing that all safety measures describing in guidelines being considered.<sup>1-3</sup> Femoral vein catheterization is introduced as an alternative venous access, and different complications have been reported for this approach. Infection and deep vein thrombosis are the most frequent side effects of femoral vein catheterization,<sup>4,5</sup> but anecdotal reports are about some rare and bizarre complications related to guide wire and catheter per se.<sup>6</sup> Complications such as migration of guide wire to the pulmonary artery,<sup>7</sup> entrapping of fractured guidewire,<sup>8</sup> knotting of guide wire during catheter insertion,<sup>9</sup> and formation of femoral arteriovenous fistula<sup>10</sup> have also been reported. We report a rare complication of catheter insertion which was the migration of guide wire through the circulating system from the femoral vein to the jugular vein.

## CASE REPORT

A 28-year-old man was admitted to the emergency department of our hospital because of fever, chills, nausea, vomiting, jaundice, and abdominal pain. In his medical history, he had chronic hepatitis B

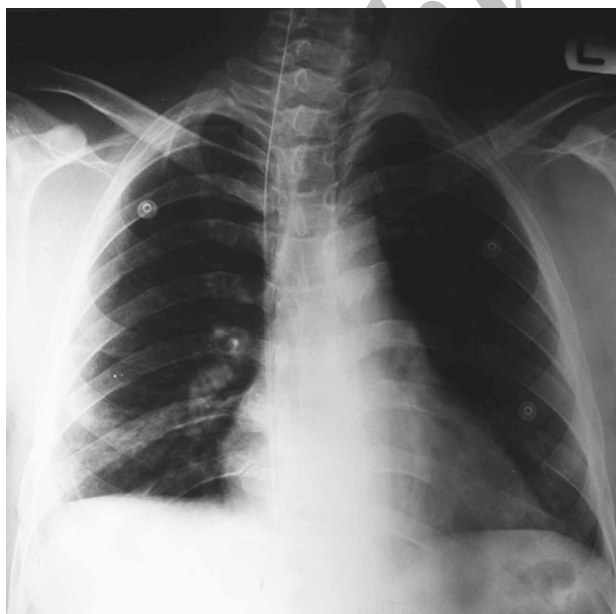since 2 years ago and he had been treated with interferon.

At the time of admission, the patient's temperature was 37.0°C, his pulse rate was 96 per minute, and the respiratory rate was 24 per minute. Blood pressure was 118/74 mm Hg. The patient weighed 73 kg. On examination, the patient was somnolent but responsive to vocal stimulus. He was icteric and a few petechia and purpuric lesions were present in the skin of neck and the lower extremities. The lungs were clear. On examination of the abdomen, there was mild tenderness and the spleen was just palpable. No hepatomegaly or lymphadenopathy was found. Neurologic evaluation was unremarkable. Laboratory tests results were as follows: blood leukocyte count,  $26 \times 10^9/L$ ; hemoglobin, 10.4 g/dL; platelets count,  $183 \times 10^9/L$ ; blood urea, 300 mg/dL; serum creatinine, 10.1 mg/dL; serum potassium, 4 mEq/L; serum lactate dehydrogenase, 493 IU/L; serum creatine kinase, 245 IU/L; serum alkaline phosphatase, 314 IU/L; prothrombin time, 15 sec; and international normalized ratio, 1.2. The urine sample taken from a fixed catheter was positive for blood (2+) and protein (1+). Ultrasonographic examination of the abdomen and pelvis revealed the right and left kidneys length to be 130 mm and

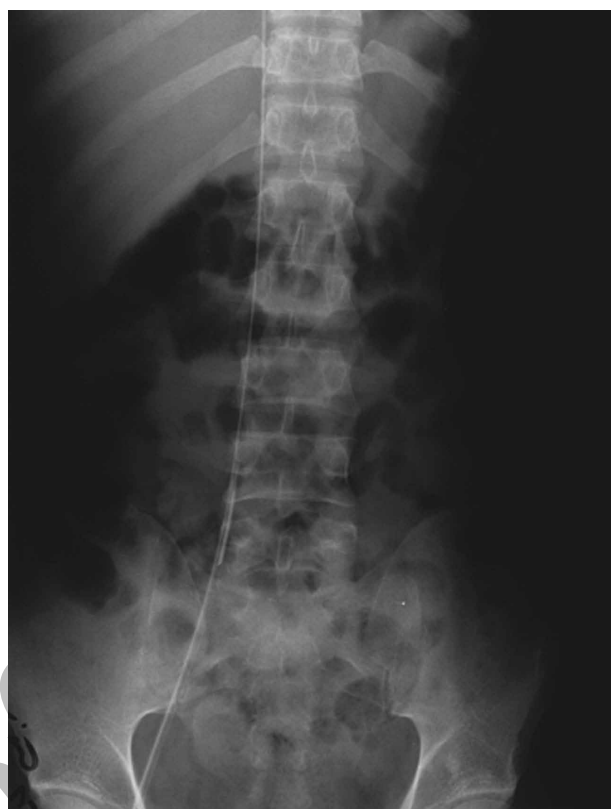
136 mm, respectively, with normal parenchymal echogenicity. The spleen was 15 cm in length. Other findings were normal.

The etiology of kidney failure was deemed to be ischemia and infection together. In order to provide emergent hemodialysis, a double-lumen catheter (12 F, 16 cm) was inserted into the right femoral vein by an internal medicine resident under the supervision of the chief resident who had done many such a catheterization. It was done after 3 attempts. Hemodialysis was performed for 2 hours with 2000 unit of heparin without any problem. The blood flow was set 180 mL/min.

Four hours after dialysis, the patient's abdominal pain aggravated. Blood pressure dropped to 78/48 mm Hg. On examination, there was rebound tenderness over the abdomen. Hemoglobin level was 6.4 g/dL. Plain abdominal and chest radiographies revealed the guide wire left in the right femoral vein, while the tip of the catheter was in the jugular vein (Figures 1 and 2). With the diagnosis of acute abdomen, the patient underwent abdominal exploration, which showed retroperitoneal bleeding and hematoma. No visible leakage or venous lesions were detected. Thus, no obvious cause of bleeding was confirmed, but it was deemed to be due to a very subtle perforation during the procedure which was not visible. It was impossible for the surgeon to take the guide



**Figure 1.** Chest radiography shows guide wire in the inferior vena cava extending into the superior vena cava and then the right internal jugular.



**Figure 2.** Plain abdominal radiography shows guide wire in the right femoral vein and the lower part of the inferior vena cava to the diaphragm level.

wire out using the abdominal approach; therefore, through an intravascular procedure, the guide wire was removed percutaneously using neck approach. The patient was discharged in good condition and with normal kidney function after 1 week.

## DISCUSSION

Many complications have been reported during and after central venous catheterization. Insertion complications become less likely as the operator gains experience. The incidence of serious insertion complications is higher for subclavian vein and internal jugular vein cannulation than femoral vein cannulation. The most common insertion complications are local bleeding and hematoma, heart dysrhythmias, arterial puncture, hemothorax, pneumothorax, air embolism, perforation of the central vein or cardiac chamber, and pericardial tamponade. The infection and venous thrombosis are two important and the most frequent complications, but they happen later after insertion of the catheter.

To our knowledge, this is the second case reporting the migration of the guide wire as a complication

of femoral vein catheter insertion. Akazawa and colleagues<sup>7</sup> reported unrecognized migration of guide wire in jugular vein catheterization. It was incidentally recognized 56 days after catheterization on chest radiography obtained for another purpose. Our case is the first one in femoral catheterization that guide wire migrating from the femoral vein to the jugular vein and diagnosed at the same day of procedure because it was accompanied by symptomatic retroperitoneal bleeding.

It seems that these kinds of complications can be prevented by following all rules of catheter insertion including the checking of the catheter tray after finishing the procedure and doing radiography at the end to evaluate the position of the catheter and its possible complications. Now by the availability of hand-held real-time ultrasonography, the frequency of insertion complications should be very low.

In conclusion, although catheter insertion for emergent hemodialysis is a simple and relatively safe procedure, it can be hazardous if performed without considering the basic rules of catheterization, particularly if it is done by an unskilled operator. We recommend the central vein catheterization be done under direct ultrasonic visualization with a catheter length as short as possible and by a skilled person.

#### CONFLICT OF INTEREST

None declared.

#### REFERENCES

1. Albuquerque Jr FC, Vasconcelos PR. Technical aspects of central venous catheterization. *Curr Opin Clin Nutr Metab Care*. 1998;1:297-304.
2. Paoletti F, Ripani U, Antonelli M, Nicoletta G. Central venous catheters. Observations on the implantation technique and its complications. *Minerva Anesthesiol*. 2005;71:555-60.
3. Taylor RW, Palagiri AV. Central venous catheterization. *Crit Care Med*. 2007;35:1390-6.
4. Durbec O, Viviani X, Potie F, Vialet R, Albanese J, Martin C. A prospective evaluation of the use of femoral venous catheters in critically ill adults. *Crit Care Med*. 1997;25:1986-9.
5. Joynt GM, Kew J, Gomersall CD, Leung VY, Liu EK. Deep venous thrombosis caused by femoral venous catheters in critically ill adult patients. *Chest*. 2000;117:178-83.
6. Schwartz AJ, Horrow JC, Jobes DR, Ellison N. Guide wires—a caution. *Crit Care Med*. 1981;9:347-8.
7. Akazawa S, Nakaigawa Y, Hotta K, Shimizu R, Kashiwagi H, Takahashi K. Unrecognized migration of an entire guidewire on insertion of a central venous catheter into the cardiovascular system. *Anesthesiology*. 1996;84:241-2.
8. Darwazah AK, Abu Sham'a RA, Yassin IH, Islim I. Surgical intervention to remove an entrapped fractured guidewire during angioplasty. *J Card Surg*. 2007;22:526-8.
9. Teba L, Zakaria M, Schiebel F. Guide wire complication during central vein catheterization. *Anesth Analg*. 1985;64:460.
10. Kuramochi G, Ohara N, Hasegawa S, Moro H. Femoral arteriovenous fistula: a complication of temporary hemodialysis catheter placement. *J Artif Organs*. 2006;9:114-7.

Correspondence to:

Mohammad R Khatami, MD

Nephrology Research Center, Imam Hospital, Keshavarz Blvd, Tehran, Iran

Tel: +98 21 6119 2659

Fax: +98 21 2281 8133

E-mail: khatami@hbi.ir

Received November 2009

Revised May 2010

Accepted July 2010