

# Immunohistochemical Detection of p53 Protein Expression as a Prognostic Factor in Wilms Tumor

Farzaneh Jadali,<sup>1</sup> Delaram Sayadpour,<sup>2</sup> Mohammad Rakhshan,<sup>3</sup> Abdollah Karimi,<sup>1</sup> Mohsen Rouzrokh,<sup>4</sup> Bibi Shahin Shamsian,<sup>5</sup> Ahmad Reza Shamshiri<sup>1</sup>

<sup>1</sup>Mofid Children's Hospital and Pediatric Infectious Research Center, Shahid Beheshti University of Medical Sciences, Tehran, Iran

<sup>2</sup>Department of Pediatric Pathology, Mofid Children's Hospital and Pediatric Infectious Research Center, Shahid Beheshti University of Medical Sciences, Tehran, Iran

<sup>3</sup>Department of Pathology, Loghman Hospital, Shahid Beheshti University of Medical Sciences, Tehran, Iran

<sup>4</sup>Department of Surgery, Mofid Children's Hospital, Shahid Beheshti University of Medical Sciences, Tehran, Iran

<sup>5</sup>Department of Hematology and Oncology, Mofid Children's Hospital, Shahid Beheshti University of Medical Sciences, Tehran, Iran

**Keywords.** tumor suppressor protein p53, Wilms tumor, prognosis

**Introduction.** Histological typing, especially the evidence of anaplasia and stage of the tumor are two major prognostic indicators in Wilms tumor, but some genetic factors have recently been noted. Mutations in *TP53*, which is a tumor suppressor gene, have been demonstrated to be associated with poor prognosis in some malignancies. There are also few studies which have confirmed the correlation between p53 protein overexpression and advanced course in Wilms tumor. This study was conducted to determine the correlation p53 immunoexpression and prognosis and outcome of Wilms tumor.

**Materials and Methods.** The overexpression of p53 in 44 specimens of children (26 boys and 18 girls) with Wilms tumor (median age, 36 months; range, 4 to 96 months) was assessed in Mofid Children's Hospital, Tehran, Iran. The overexpression of p53 was determined by immunohistochemistry with antihuman p53 antibody.

**Results.** A positive immunostaining for p53 was detected in 24 of the 44 cases (54.7%). The grade of the tumor and anaplasia were associated with p53 positivity, but there was no association of p53 with the tumor stage. In comparison to p53 negatives, week-moderate and high p53-expressing tumors had significantly decreased the overall survival (hazard ratio, 3.75 and 8.61;  $P = .05$  and  $P = .01$ , respectively).

**Conclusions.** Overexpression of p53 protein in Wilms tumor is an indicator of poor prognosis, because it is correlated with unfavorable histology tumors and a shorter survival period.

IJKD 2011;5:149-53  
www.ijkd.org

## INTRODUCTION

Wilms tumor is the most common renal tumor of childhood and is a highly responsive tumor to chemotherapy as though the survival for patients with Wilms tumor is currently greater than 90%.<sup>1,2</sup> Although it is obvious that histological typing, especially the evidence of anaplasia and stage, are the major criteria predicting the clinical outcome of the tumor, but it has recently been recognized that new clinical and genetic risk factors are should

also be considered regarding this subject.<sup>3,4</sup>

The p53 tumor suppressor gene (*TP53*) is located on chromosome 17p13.1. Several studies have been carried out to determine the role of this protein expression as a prognostic factor in patients harboring Wilms tumor. Most of these surveys have confirmed the correlation of *TP53* overexpression with anaplasia in Wilms tumor.<sup>5-8</sup> This study was conducted on 44 patients with Wilms tumor in our center to determine the

incidence and the relationship between p53 protein immunoexpression and the patients' age, sex, and outcome. If p53 immunopositivity correlates with prognosis, alteration in chemotherapy based on p53 expression might enhance survival.

## MATERIALS AND METHODS

### Studied Samples

In this cross-sectional study, 44 cases of confirmed Wilms tumor were retrieved from the archives of the Department of Pathology at Mofid Children's Hospital, Shahid Beheshti Medical University, diagnosed during the period of 1999 to 2009. Histological classification, grading, and clinicopathologic staging of the tumors were based on the National Wilms Tumor Study guidelines. All the cases were formalin fixed and paraffin embedded. Basic clinical and paraclinical data were extracted from the patients' records.

### Histopathological Assessment

One or two paraffin blocks from the most histologically aggressive parts of each tumor were selected for review and immunohistochemistry staining. Immunoperoxidase staining for p53 was performed on all the 44 specimens. Four-micron sections were cut from each selected paraffin block on to Poly L Lysine coated slides. Sections were then dewaxed and rehydrated to distilled water. Endogenous peroxidase activity was blocked by placing sections in 3% hydrogen peroxide for 5 minutes and washed 3 times in distilled water. Then, the slides were incubated with DO-7 antihuman p53 monoclonal antibody (DAKO, Glostrup, Denmark) for 60 minutes at room temperature, followed by two 5-minute washes of phosphate buffered saline. The sectioned specimens were incubated with biotinylated link antimouse and antirabbit immunoglobulin for 30 and 15 minutes, respectively, and washed with phosphate buffered saline twice, followed by 30 minutes incubation with streptavidin-biotin-horseradish peroxidase complex (DAKO LSAB 2 system, Glostrup, Denmark). Sections were washed in phosphate buffered saline for 45 minutes and bound antibody complex was visualized by reaction in diaminobenzidine. Finally, the sections were counterstained with hematoxyline, dehydrated, and mounted.<sup>9,10</sup>

The slides were reviewed with light microscopy by 2 pathologists separately and scored for

number of positive cells and the intensity of immunopositivity. The proportion of neoplastic cells with nuclear positivity was quantified as zero, 1% to 25%, 26% to 50%, 51% to 75%, and > 75%. The intensity of staining was graded as strong when the nuclei showed a dark brown color; moderate, with intermediate golden brown color; and weak, with light brown nuclei. The weak and moderate staining ones were taken as a same category, named as weak-moderate.

### Statistical Analyses

Quantitative variables are summarized as mean  $\pm$  standard deviation, and qualitative variables as absolute frequency and percentage. The association between categorical variables was analyzed by the chi-square test. Survival rates were calculated with the Kaplan-Meier method. Survival rates comparison between different groups were performed by the log-rank test. The effect of ordinal variables (changed to a set of dummy variables) on overall survival were evaluated by the Cox regression and the effects were expressed as hazard ratio (HR). *P* values of less than .05 were considered significant.

## RESULTS

Forty-four cases of histologically confirmed Wilms tumor, diagnosed during the 10 year period between March 1999 and February 2009 were studied. The specimens belonged to were 26 boys and 18 girls with a male-female ratio of 1.43:1. The patients' age at presentation ranged from 4 months to 8 years, and the mean age was 3 years and 2 months. The overall follow-up period ranged from 1 month to 10 years, with a median duration of 28 months. Twenty-nine patients were alive at last follow-up and 15 had died. Thirty-three specimens had been determined to have favorable histology and 11, unfavorable. Seven tumors were stage I, 12 were stage II, 13 were stage III, 12 were stage IV, and none were stage V.

Twenty-four tumors (54.7%) were p53 positive. A normal kidney tissue, whenever present, did not show immunopositivity for p53. There was no relationship between age and sex with p53 expression. Fifteen of 26 boys and 9 of 18 girls had p53 positive tumors (*P* = .74). When comparing p53 expression with histology, all tumors with unfavorable histology showed strong p53 positivity

(Figure 1), while only 13 of 33 tumors with favorable histology (39.3%) were p53 positive, containing weak-moderate intensity (Figure 2;  $P < .001$ ). The percent of tumoral cells positive for p53 significantly correlated with histologic findings; all cases of unfavorable histology demonstrated immunopositivity in more than 25% of the tumoral cells, but only 9 of favorable histology cases (27.5%) showed this expression ( $P < .001$ ). With respect to the predominant component in histology of tumors, we observed that in the group of tumors with a predominant blastemal component, 12 (63%) were p53 positive. Of the tumors with predominant epithelial component, 2 (66%) were p53 positive and none of the tumors containing predominant stromal component was p53 positive ( $P = .14$ ).

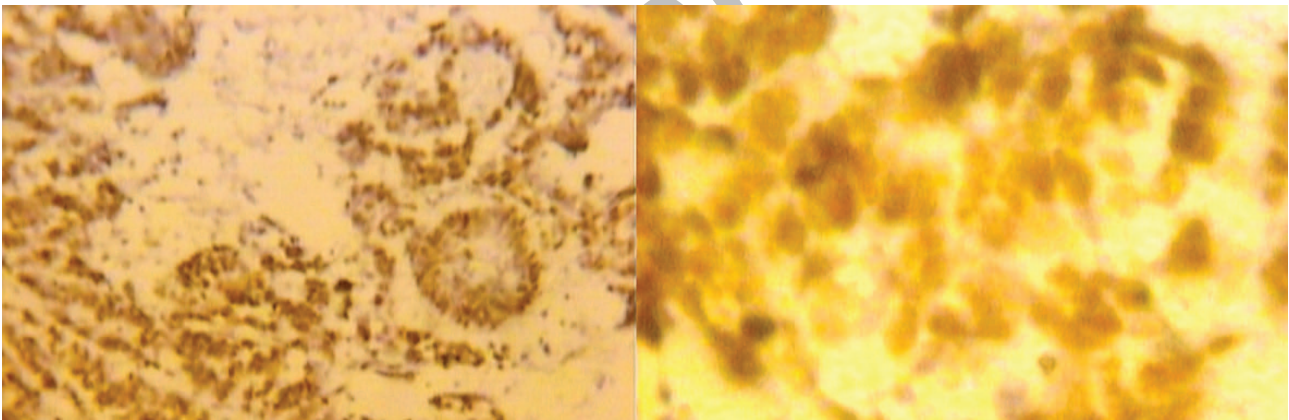
The 2-year overall survival rate was 89.2% for p53-negative patients and 55.7% for p53 positives ( $P = .01$ ). The mean survival was 46 months in p53 negatives and 26 months in p53 positives ( $P = .02$ ). With increasing staining score, the

survival rate was shortened; in comparison with p53 negatives, tumors with weak-moderate and high p53 expression had an HR of 3.75 ( $P = .05$ ) and 8.61 ( $P = .01$ ), respectively. As compared with p53 negatives, those with 1% to 50% positive cells and those with more than 50% positive cells had HRs of 3.99 ( $P = .05$ ) and 4.72 ( $P = .03$ ), respectively.

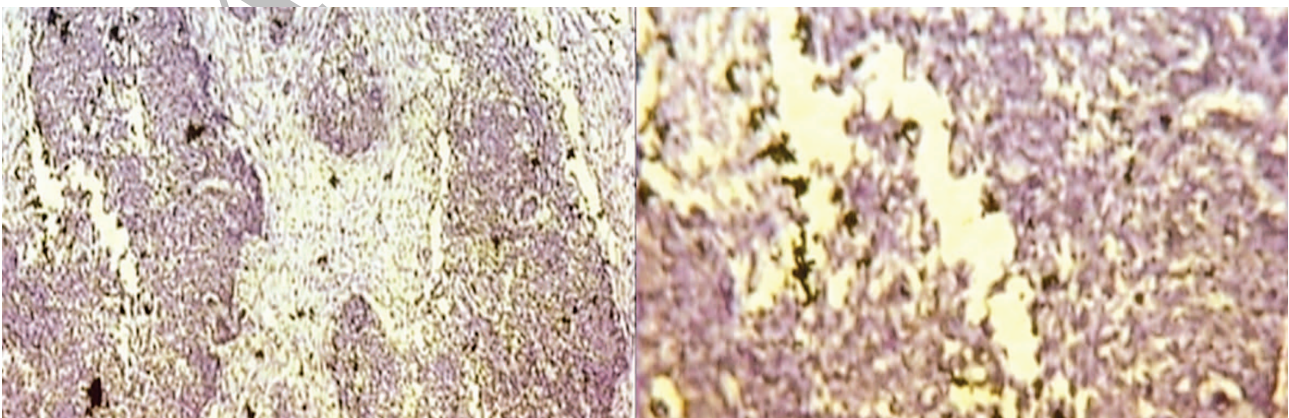
No significant correlation was observed between clinicopathological stage of the tumor and p53 expression. Eight of 16 patients with stage IV (metastatic) disease were p53 positive, while 4 of 16 cases with stage I to III (non metastatic) disease were p53 immunopositive ( $P = .02$  and  $P = .40$  for intensity and percent of cell positivity for p53, respectively).

## DISCUSSION

In this cross-sectional study on 44 Wilms' tumor cases, we found that there was a significant correlation between p53 protein overexpression and the histology of the tumor and survival of the



**Figure 1.** An example of Wilms tumor with unfavorable histology showing strong positive immunostaining for p53 (anti-p53,  $\times 25$  and  $\times 100$ ).



**Figure 2.** An example of Wilms tumor with favorable histology showing negative immunostaining for p53 (anti-p53,  $\times 25$  and  $\times 100$ ).



patient. Although stage and histology are the most known prognostic factors in Wilms tumor, several genetic aberrations have recently been recognized with a role in pathogenesis and outcome of this childhood tumor including aberrations in *WT1* mapped on 11p13 and *WT2* on 11p15, and loss of heterozygosity of 16q and 1p markers.<sup>3</sup> There are also many studies regarding some controversies about the possible role of p53 gene mutation or protein overexpression in the prognosis of Wilms tumor. In this study we investigated the importance of immunohistochemical detection of p53 as a prognostic indicator in Wilms tumor.

In our study 44 patients of Wilms tumor were evaluated. There was no significant correlation between sex and age of the patients with p53 immunopositivity. The study by Sredni and colleagues showed no relationship between demographic features (sex, age, and race) and p53 expression.<sup>8</sup> We found 24 cases of 44 studied ones (54.7%) as p53 immunopositive in our series. All unfavorable histology tumors and 39.3% of favorable histology ones were p53 positive. This significant correlation between histological grade and p53 immunopositivity is in agreement with previous studies; Robles-Frias and colleagues reported that p53 mutations were detected in approximately 75% of Wilms tumors with anaplastic histology and were very uncommon in favorable histology tumors.<sup>11</sup> Beniers and colleagues showed a significant correlation of p53 expression with anaplasia.<sup>12</sup> Govender and coworkers studied on 93 cases of Wilms tumor and revealed that anaplasia was associated with high levels of p53 expression.<sup>13</sup> There was no correlation between predominant histological component of the tumor and p53 immunopositivity. Sredni and colleagues observed a relationship between histology and p53 expression,<sup>8</sup> while Skotnicka-Klonowicz and associates and Cheah and colleagues found that the blastemal and epithelial components of the tumor showed greater immunopositivity of p53.<sup>6,14</sup> The survival period in our patients was shorter for p53-positive tumors. Beniers and coworkers showed a significant correlation of p53 to survival.<sup>12</sup> Govender and coworkers found that the survival period is shorter for high p53-expressing tumors.<sup>12</sup> Wen and colleagues and Skotnicka-Klonowicz and colleagues reported a higher frequency of recurrences and metastasis in tumors with

immunopositivity for p53.<sup>4,14</sup> If we consider that the high p53 immunopositivity is due to p53 mutations, this mutant p53 may activate multidrug resistant gene and result in shorter survival among the p53-positive patients. There was no relationship between p53 immunopositivity and the disease stage in our study. Zabolnejad and colleagues studied on 48 cases and D'Angelo and associates revealed no correlation of p53 immunopositivity and tumor stage in favorable histology Wilms tumors.<sup>2,9</sup> Sredni and colleagues demonstrated that there was a correlation between stage and p53 expression in Wilms tumors.<sup>8</sup> Malkin and coworkers and Huang and colleagues revealed that p53 mutations in Wilms tumors were associated with advanced disease.<sup>5,8</sup> This discrepancy is most likely because of the economic and cultural differences between the countries. The findings demonstrated that while more than half of our patients had favorable histology tumors, most of them presented with higher stages of disease.

## CONCLUSIONS

High expression of p53 protein in our pediatric Wilms tumor patients is an indicator of poor prognosis like most of Wilms tumors around the world, because it correlated firstly with unfavorable histology tumors and secondly with a shorter survival period. However, there was no association with our patients' demographic features. Furthermore, establishment of the role of p53 overexpression in Wilms tumor might have therapeutic implications in the future.

## CONFLICT OF INTEREST

None declared.

## REFERENCES

1. Peres EM, Savasan S, Cushing B, Abella S, Mohamed AN. Chromosome analyses of 16 cases of Wilms tumor: different pattern in unfavorable histology. *Cancer Genet Cytogenet.* 2004;148:66-70.
2. D'Angelo MF, Kausik SJ, Sebo TJ, Rathbun SR, Kramer SA, Husmann DA. p53 immunopositivity in histologically favorable Wilms tumor is not related to stage at presentation or to biological aggression. *J Urol.* 2003;169:1815-7.
3. Davidoff AM. Wilms' tumor. *Curr Opin Pediatr.* 2009;21:357-64.
4. Wen JG, van Steenbrugge GJ, Egeler RM, Nijman RM. Progress of fundamental research in Wilms' tumor. *Urol Res.* 1997;25:223-30.

5. Malkin D, Sexsmith E, Yeger H, Williams BR, Copes MJ. Mutations of the p53 tumor suppressor gene occur infrequently in Wilms' tumor. *Cancer Res.* 1994;54:2077-9.
6. Cheah PL, Looi LM, Chan LL. Immunohistochemical expression of p53 proteins in Wilms' tumour: a possible association with the histological prognostic parameter of anaplasia. *Histopathology.* 1996;28:49-54.
7. Lahoti C, Thoner P, Malkin D, Yeger H. Immunohistochemical detection of p53 in Wilms' tumors correlates with unfavorable outcome. *Am J Pathol.* 1996;148:1577-89.
8. Sredni ST, de Camargo B, Lopes LF, Teixeira R, Simpson A. Immunohistochemical detection of p53 protein expression as a prognostic indicator in Wilms tumor. *Med Pediatr Oncol.* 2001;37:455-8.
9. Huang J, Soffer SZ, Kim ES, et al. p53 accumulation in favorable-histology Wilms tumor is associated with angiogenesis and clinically aggressive disease. *J Pediatr Surg.* 2002;37:523-7.
10. Zabolinejad N, Sharifi N, Tabatabaee A, et al. Immunohistochemical expression of p53 protein in histologically favorable wilms' tumor and its relationship to tumor stage at presentation. *IJBMS.* 2006;9:70-4.
11. Robles-Frias MJ, Biscuola M, Castilla MA, Lopez-Garcia MA, Sanchez-Gallego F, Palacios J. Wilms' tumour: a complex enigma to decipher. *Clin Transl Oncol.* 2008;10:457-61.
12. Beniers AJ, Efferth T, Fuzesi L, Granzen B, Mertens R, Jakse G. p53 expression in Wilms' tumor: a possible role as prognostic factor. *Int J Oncol.* 2001;18:133-9.
13. Govender D, Harilal P, Hadley GP, Chetty R. p53 protein expression in nephroblastomas: a predictor of poor prognosis. *Br J Cancer.* 1998;77:314-8.
14. Skotnicka-Klonowicz G, Kobos J, Los E, Trejster E, Szymik-Kontorowicz S, Daszkiewicz P. Prognostic value of p53 expression in Wilms' tumor in children. *Med Sci Monit.* 2001;7:1224-9.

## Correspondence to:

Farzaneh Jadali, MD  
 Mofid Children's Hospital, Dr Shariati Ave, Tehran, Iran  
 Tel: +98 21 2222 7035  
 Fax: +98 21 8830 5545  
 E-mail: fjadali@hotmail.com

Received May 2010

Revised January 2011

Accepted January 2011

Archive of SID