

Vascular Calcification in Chronic Kidney Disease

Mechanisms and Clinical Implications

Shahrzad Ossareh

Department of Nephrology,
Hasheminejad Clinical
Research Development Center,
Tehran University of Medical
Sciences, Tehran, Iran

Keywords. renal dialysis,
vascular diseases, calcium
metabolism disorders,
cardiovascular diseases

Vascular calcification is a well-known complication of chronic kidney disease and one of the main predictors for increased cardiovascular morbidity and mortality in these patients. It may happen in 2 main types of intimal calcification, as a part of diffuse atherosclerosis, and medial calcification, which is generally focal in distribution, unrelated to atherosclerotic risk factors, and seen in younger hemodialysis patients. Pathogenesis may be genetic, mineral metabolism related, or nonmineral metabolism related. Increased calcium, phosphorus, and calcium-phosphorus product; decreased parathyroid hormone level; and overzealous use of active vitamin D supplements are the main mineral metabolism-related mechanisms of vascular calcification. Other mechanisms are formation of matrix vesicles and cellular apoptosis, with generation of hydroxyapatite crystals within vesicles and apoptotic bodies. The interplay of various activator proteins of vascular calcification such as bone morphogenetic proteins and receptor activator of nuclear factor-kappa B ligand, or inhibitor proteins like matrix Gla protein, bone morphogenetic protein-7, osteopontin, osteoprotegerin, fetuin-A, Smad6, and pyrophosphate are important in establishment of vascular calcification. Vascular calcification is related to all-cause and cardiovascular mortality both in general population and dialysis patients. Minimizing traditional risk factors of vascular calcification, prevention of hypercalcemia, and avoidance of high doses of calcium-based phosphate binders and vitamin D analogues are important measures for prevention or attenuation of progression of vascular calcification. Sevelamer and cinacalcet may prevent progression of vascular calcification. With the evolving knowledge of the pathogenesis of vascular calcification, we can look forward to emergence of novel therapies for this complication in the future.

IJKD 2011;5:285-99
www.ijkd.org

INTRODUCTION

Cardiovascular disease is an important predictor of mortality in patients with end-stage renal disease (ESRD) and accounts for almost 50% of deaths in these patients.¹ Approximately, 20% of this can be attributed to coronary artery disease. Arterial calcification and especially coronary artery calcification is known as a risk factor for cardiovascular disease in these

patients, and cross-sectional and longitudinal studies on ESRD patients have shown that arterial calcifications are associated with cardiovascular morbidity and are an independent predictor of all-cause and cardiovascular mortality.^{2,3} Arterial medial calcification has been shown as a strong prognostic marker of all-cause and cardiovascular mortality in hemodialysis patients, independent of

classical atherogenic factors.² One study showed 2.5 to 5 times higher grades of coronary artery calcification in dialysis versus nondialysis patients, with rapid progression of calcification in dialysis patients.⁴ Also, cardiac valvular calcification was reported in more than 50% of dialysis patients in this study. They explained the principal effect of arterial medial calcification on arterial function through increased arterial stiffness.

The main question is what causes and drives this early and extensive vascular calcification in patients with chronic kidney disease (CKD), and what the main strategies are to prevent or possibly reverse it. In this review we will try to elucidate the principal mechanisms of vascular calcification in CKD, and to summarize the main available strategies to prevent or treat vascular calcification, as one of the main causes of cardiovascular events in these patients.

EPIDEMIOLOGY

Increased frequency of vascular calcification has been reported in patients with CKD, even in predialysis era and before widespread use of calcium and vitamin D supplements and calcium-containing phosphate binders.^{5,6} Widespread soft tissue calcification was observed in more than 60% of children with CKD and ESRD, and systemic calcinosis and vascular calcifications, in 36% of them.⁷ Coronary artery calcification has been shown in up to 92% of young ESRD adults with sequential computed tomography with electrocardiography gating.⁸ Using electron beam computed tomography, a high prevalence of coronary artery calcification has been reported among CKD patients, which was significantly greater among diabetic CKD patients versus nondiabetic CKD controls (94% versus 59%, $P < .001$).⁹ Even conventional radiographic studies could reveal vascular calcification in about 60% of patients with ESRD and 57% progression over time.¹⁰ The same investigators later reported some degrees of vascular calcification in about 50% of patients undergoing continuous ambulatory peritoneal dialysis.¹¹ Therefore, it seems that vascular calcification is and has been a frequent finding among CKD and ESRD patients in predialysis and postdialysis eras, in different stages of CKD, and before and after widespread use of the calcium-containing phosphate binders and vitamin D supplement.¹²

DEFINITION

Calcium taken from arterial calcification of uremic patients is made up of hydroxyapatite crystals ($\text{Ca}_{10}[\text{PO}_4]_6[\text{OH}]_2$), same as the type found in skeleton, or it consists of brushite (calcium [magnesium] phosphate or whitlockite) in calcified stenotic regions of arteriovenous fistula and human aorta.^{13,14} Calcification of arterial walls may occur in intimal or medial layers, with different pathogenic mechanisms and clinical significance. Intimal calcification typically occurs in atherosclerotic lesions of muscular arteries such as coronary arteries and the aorta and usually starts in infancy in the form of small collections of macrophages filled with lipid droplets, which will later develop into *pre-atheromas* and ultimately atherosclerotic lesions.¹⁵ Pre-atheromas contain small pools of lipid droplets and dead cell remnants as well as macrophage foam cells.¹⁵ Atheromas contain a lipid core, increased extracellular lipid displacing smooth muscle cells, and calcium granules.¹⁵

Medial calcification may occur in elastic lamina of large- and medium-sized arteries, ie, muscular-type arteries (Monckeberg's arteriosclerosis), such as femoral, tibial, and uterine arteries, in a focal distribution and almost exclusively associated with vascular smooth muscle cells (VSMCs).^{16,17} It has a pipe-like or tram-line appearance and is considered as a noninflammatory process.^{18,19}

Intimal calcification occurs in atherosclerotic lesions and is seen with advancing age and other typical risk factors associated with atherosclerosis such as hypertension, diabetes, dyslipidemia, and smoking.^{2,20} It is a patchy and discontinuous process and involves VSMCs and macrophages in lipid-rich regions.²⁰ Medial calcification is more commonly observed in young and middle-aged patients without conventional atherosclerotic risk factors and has been shown to be closely associated with the duration of hemodialysis and calcium-phosphate disorders, including the oral dose of elemental calcium prescribed as phosphate binder (CaCO_3).² Intimal calcification may occur independently of medial calcification and vice versa and in patients with ESRD, a mixture of both types has been observed in affected vessels.²¹

PATHOGENESIS

Pathogenesis of vascular calcification in CKD and ESRD patients can be arbitrarily divided into 3

entities of genetic susceptibility, mineral metabolism related, and mineral metabolism unrelated (Table).

Genetic Susceptibility

Genetic studies have shown susceptibility of certain inbred mice to myocardial cell necrosis and calcification (dystrophic cardiac calcinosis) and aortic calcification in the presence of a single major locus, *Dyscalc*, located on proximal chromosome 7 in a region syntenic with human chromosomes 19q13 and 11p15.²²⁻²⁴ Other described models of genetic predisposition to vascular calcification are apolipoprotein E deficient mice, in which osteopontin deficiency may attenuate atherosclerosis and aggravate vascular calcification²⁵; low density lipoprotein (LDL)- receptor deficient mice, in which macrophage migration inhibitory factor deficiency may prevent atherosclerosis²⁶; spontaneous calcification of arteries and cartilage in mice lacking matrix Gla protein²⁷; and in vitro enhanced susceptibility of smooth muscle cells deficient in osteopontin to calcification.²⁸ Mice knocked out in the membrane protein Klotho, carbonic anhydrase inhibitor, or Fetuin A (an important calcification inhibitor protein) are further examples

of susceptibility to vascular calcification.²⁹⁻³¹

In human studies, increased platelet reactivity due to single nucleotide polymorphism on chromosome 9p21.3 has been associated with increased vascular calcification.³² Variations in human lipoxygenase gene pathway have been associated with subclinical atherosclerosis in diabetic patients.³³ Patients with parathyroid gene AA variant have been found to have a higher prevalence of calcific aortic stenosis.³⁴ Single nucleotide polymorphism of bone morphogenetic protein (BMP) have been associated with inverse relationships between bone mineralization and calcification in the coronary, carotid, and abdominal aorta in a diabetes-enriched cohort of European Americans.³⁵ Many other genetic predispositions to vascular calcification have also been described in non-kidney-failure population.³⁶⁻³⁹ However, there are few pieces of data in patients with kidney failure. Polymorphism in a glucose transporter gene (GLUT-1 XbaI) has been shown to be more prevalent in nondiabetic uremic patients with vascular calcification (30.7% versus 4.5%, $P = .001$).⁴⁰ Glucose transporters mediate the facilitative uptake of glucose into cells, with GLUT-1 being the

Summary of Pathogenic Mechanisms of Vascular Calcification

Mechanism	Description
Genetic Susceptibility	
Murine Models	Dyscalc gene Apolipoprotein E null Low-density lipoprotein-receptor null Matrix Gla protein null Klotho null Carbonic anhydrase inhibitor null Fetuin-A null
Human examples	Single nucleotide polymorphism on chromosome 9p21.3 Human lipoxygenase gene pathway variations Parathyroid gene AA variant Single nucleotide polymorphism of bone morphogenetic protein Polymorphism in glucose transporter-1 XbaI gene
Mineral metabolism related	Increased calcium level Increased phosphate level Decreased parathyroid hormone level Active vitamin D supplement (high dose?)
Mineral metabolism unrelated	
Activators	Bone morphogenetic protein 2 Receptor activator of nuclear factor-kappa B ligand
Inhibitors	Matrix Gla protein Bone morphogenetic protein 7 Osteopontin Osteoprotegerin Fetuin-A Smad6 Pyrophosphate

predominant isoform in vascular VSMCs. Clones of human cells overexpressing the GLUT-1 transporter showed a high increase in intracellular glucose concentrations, mimicking the diabetic milieu. It is possible that high intracellular glucose together with uremic factors may play an important role in vascular calcification by transforming VSMCs into osteoblast-like cells.

Mineral Metabolism Related

Increased calcium and phosphate levels.

Abnormalities in mineral metabolism have been accused for the development of vascular calcification in patients with CKD and ESRD. Increased phosphate level due to decreased phosphate excretion is generally observed in advanced CKD, and together with increased calcium and calcium-phosphate product, it has been attributed to development of vascular calcification in these patients.^{2,4142} Various studies have reported that increased calcium intake may directly increase vascular calcification in patients with ESRD and murine models of CKD,⁴³⁻⁴⁵ although a direct correlation between vascular calcification as represented by carotid intima-media thickness has not been approved in all studies.⁴⁶ On the other hand, in a number of studies, reversal of hyperphosphatemia and hypercalcemia with sevelamer has been shown to decrease vascular calcification in ESRD patients.⁴⁷⁻⁴⁹

Two different mechanisms are proposed to explain the occurrence of vascular calcification in calcium-phosphate disorders: (a) a passive, direct calcium-phosphate precipitation in the vasculature, and (b) an active induction of the expression of bone-associated genes in VSMCs.⁵⁰ Yang and colleagues showed that increase in either calcium level, phosphorus level, or both can induce mineralization of human smooth muscle cells in vitro via enhancing the sodium-dependent phosphate cotransporter-dependent mineralization pathway.⁵¹ Hyperphosphatemia and long-term elevated calcium level upregulate the type III sodium-dependent phosphate cotransporter, Pit-1.^{51,52} Interestingly, phosphonoformic acid, an inhibitor of this system, completely blocks calcium- as well as phosphorus-induced mineralization in human smooth muscle cells.⁵¹ These findings emphasize the importance of hyperphosphatemia and calcium load in the development of vascular

calcification in CKD patients, although several lines of evidence indicate the effect of other factors in development of vascular calcification in these patients.

Parathyroid hormone level. The role of parathyroid hormone (PTH) in vascular calcification is not yet clear. Chertow and colleagues showed that lower PTH levels are associated with more extensive calcification in calcium-treated subjects, whereas higher PTH levels are associated with calcification in sevelamer-treated subjects.⁴⁴ They hypothesized that exogenous calcium loading and/or unintended suppression of PTH may contribute to progressive calcific vascular disease in hemodialysis patients. Adragao and colleagues could not show any relationship between PTH level and a vascular calcification score defined according to radiographic findings of the pelvis and hands in a group of 123 hemodialysis patients.⁵³ Also in the studies by our group⁴⁶ and by Oh and colleagues,⁵⁴ carotid intima-media thickness did not correlate with PTH level. However, Oh and colleagues showed coronary calcium scores to be strongly correlated with time-averaged mean serum PTH as well as C-reactive protein (CRP) level, *Chlamydia pneumoniae* seropositivity, and plasma homocysteine level. In the study by Kraśniak and colleagues, neither carotid intima-media thickness nor the number of atherosclerotic plaques were predicted by PTH level in multivariate analysis⁵⁵; however, Goldsmith and colleagues showed hyperparathyroidism to be a determinant of severity and rate of progression of vascular calcification in long-term hemodialysis patients.⁵⁶ On the contrary, Shao and colleagues could inhibit vascular calcification and aortic osteogenic differentiation with PTH supplementation (teriparatide) via a direct effect on osteopontin in the diabetic LDL receptor-deficient mice.⁵⁷

Generally, PTH and PTH-related protein are assumed to induce bone demineralization on the one hand and inhibit vascular calcification on the other hand, in concert with other inhibitors of mineralization of VSMCs such as fetuin-A, matrix Gla protein, and vitamin K.⁵⁸ To summarize, most authorities suggest that PTH may have a protective effect against vascular calcification, and the severity of vascular calcification may increase in conditions of adynamic bone disease and low PTH.⁵⁹

Vitamin D. Most human tissues, including

endothelial and VSMCs, contain vitamin D receptors and both endothelial cells and VSMCs possess 1α -hydroxylase and can synthesize active vitamin D metabolites locally.^{60, 61} Zehnder and colleagues confirmed the presence of 1α -hydroxylase in human umbilical vein endothelial cells and showed the induction of this enzyme by inflammatory cytokines such as tumor necrosis factor (TNF)- α and consequent increased adhesion of monocytes to endothelial cells.⁶¹ They hypothesized that the rapid induction of endothelial 1α -hydroxylase activity by inflammatory cytokines suggests a novel autocrine/paracrine role for the enzyme, possibly as a modulator of endothelial cell adhesion.

The impact of vitamin D on vascular calcification is not clearly known. Watson and colleagues showed a significant negative correlation between 1,25-dihydroxyvitamin D3 level and coronary calcification in 173 patients with normal kidney function and high risk for coronary artery disease.⁶² Braam and colleagues showed the beneficial effect of supplemental vitamin D plus vitamin K on elastic properties of the common carotid artery in a group of postmenopausal women and explained it by increased activity of matrix Gla protein, which is a potent inhibitor of vascular calcification and dependent on vitamin D and Vitamin K for its action.⁶³

On the other hand, many researchers have shown increased vascular calcification as the result of active vitamin D therapy in uremic patients and murine models.^{56, 64-69} Goldsmith and colleagues found a significant positive correlation between the extent of vascular calcification, assessed by radiographic findings, and vitamin D concentration in a group of chronic hemodialysis patients.⁵⁶ Briese and colleagues showed a positive correlation between both cumulative calcitriol intake and active vitamin D metabolite levels and left ventricular mass index, as a surrogate marker for cardiovascular disease, although only cumulative calcium-phosphate binder intake and not calcitriol intake, was correlated with intima-media thickness.⁶⁴ In a systematic review by McCullough and colleagues, among 30 studies over 20 years, 3 related treatment with vitamin D analogues to vascular calcification.⁶⁵ In a rat model of secondary hyperparathyroidism, both calcitriol and cinacalcet were successful in control of hyperparathyroidism; however, only calcitriol-induced hypercalcemia increased calcium-

phosphorus product and vascular calcification.⁶⁶ High-dose calcitriol treatment in uremic rats with hyperparathyroidism could induce hypertension, left ventricular hypertrophy, and diffuse aortic intimal and medial calcification in the absence of hypercalcemia and increased calcium-phosphorus product, compared to vehicle-treated uremic rats and sham operated rats.⁶⁷ Also, studies have shown that fibroblast growth factor 23- and Klotho-knockout mice develop widespread soft tissue and vascular calcification due to uninhibited production of active vitamin D and increased serum calcium and phosphorus levels.^{68, 69}

Shroff and colleagues showed that both low and high levels of 1,25-dihydroxyvitamin D are associated with abnormal vascular structure and calcification, possibly through a dual effect on calcium phosphate homeostasis and inflammation.⁷⁰ In their study, both carotid intima-media thickness and calcification scores showed a U-shaped distribution across 1,25-dihydroxyvitamin D levels, and patients with both low and high 1,25-dihydroxyvitamin D had significantly greater carotid intima-media thickness and calcification scores than those with normal levels. Low 1,25-dihydroxyvitamin D levels were also associated with higher levels of high-sensitivity CRP. Overall, it seems that there is a delicate balance between the protective effect of vitamin D on cardiovascular system and its vascular calcifying effect, which may itself occur with either high or low doses of vitamin D supplement.

Mineral Metabolism Unrelated

Molecular mechanisms. Vascular calcification, previously thought to be a degenerative process, is a cell-regulated ossification, which is primarily osteogenic in human and chondrogenic in mice.⁷¹ Various proteins involved in osteogenesis have been shown to be present in VSMCs and atherosclerotic lesions such as osteopontin, BMP2 and matrix Gla protein.⁷²⁻⁷⁴ Arterial calcification is the result of a complex interplay between stimulating proteins such as BMP2 and receptor activator of nuclear factor-kappa B (RANK) ligand and inhibitory proteins such as matrix Gla protein, BMP7, osteoprotegerin, fetuin-A, and osteopontin.⁷⁵

Bovine aortic smooth muscle cells de-differentiate and lose their smooth muscle cell specific markers when placed under calcifying conditions and

subsequently gain osteogenic phenotype.⁷⁶ More than 30 years before, Chamley-Campbell and colleagues proposed the paradigm that medial VSMCs exist in differentiated “contractile” phenotype that is de-differentiated into a “synthetic” phenotype with migration into intimal layer as a repair response to injury.^{77,78} Formation of a VSMC-rich fibrous cap may act as a barrier between the lipid-rich prothrombotic plaque and blood flow.⁷⁹ During the phenotypic change, VSMCs may acquire characteristics of a diverse range of mesenchymal lineages, including osteoblastic, chondrocytic and adipocytic.⁸⁰ Multiple members of transforming growth factor- β 1 superfamily act in concert to modulate VSMC phenotype.⁸¹ A feature of the osteogenic transformation is upregulation of the transcription factor, core binding factor alpha1/runt-related transcription factor 2 (Cbfa1/Runx2), which is an obligate transcription factor in the regulation of bone (osteoblastic) differentiation.⁸⁰

Vascular calcification starts in the cells with formation of matrix vesicles, which are extracellular 100-nm-diameter membrane-derived particles selectively located in the matrix of the bone, cartilage, and predentin.⁸² They contain the necessary calcium-binding proteins and phosphatases for nucleation of hydroxyapatite. The vesicles are the initial site of calcification in all skeletal tissue, and hydroxyapatite crystals are generated in them during a phosphatase-dependent (including alkaline phosphatase) phase 1 mineralization.⁸² Phase 2 of mineralization begins with breakdown of matrix vesicle membranes, exposing preformed hydroxyapatite to the extracellular fluid, after which mineral crystal proliferation is governed by extracellular conditions.⁸² Matrix vesicles have been detected in VSMCs of human arteries and it seems that the same calcification process is effective in atherosclerosis.^{83,84}

Another important factor in initiation of vascular calcification is apoptosis of VSMCs. Isner and colleagues⁸⁵ first showed the role of apoptosis in pathogenesis of human atherosclerotic lesions, which was further confirmed by the work of their group and others.⁸⁵⁻⁸⁸ Vascular smooth muscle cells from normal vessel walls demonstrate little basal cell proliferation or apoptosis. In plaque tissue, however, inflammatory cells, cytokines, modified LDL cholesterol, and altered blood pressure and flow may change the fine balance between proliferation

and cell death and increase the sensitivity of these cells to apoptosis.⁸⁹ Apoptosis is triggered by interaction of VSMCs with inflammatory cells that express cell surface death ligands or secrete proapoptotic cytokines such as TNF- α and through activation of death receptors such as Fas.^{80,89,90} Apoptosis precedes human vascular calcification in vitro, and VSMC-derived apoptotic bodies can concentrate and crystallize calcium.⁸⁸ Some studies have implied that apoptotic bodies in atherosclerotic plaques are similar to matrix vesicles and that these may initiate calcification.⁹¹

An interesting finding by Reynolds and colleagues is the role of serum calcium and phosphorus level in the calcification process.⁸⁴ They showed that although vascular calcification was initiated by the release of membrane-bound matrix vesicles from living VSMCs and also by the release of apoptotic bodies from dying cells, this could not happen in the presence of serum with mineralization inhibitors, such as fetuin-A and matrix Gla protein. On the other hand, vesicles released by VSMCs after prolonged exposure to calcium and phosphorus contained preformed basic calcium phosphate and calcified extensively.

Plasma Proteins. There are a number of proteins involved in vascular calcification acting either as inhibitors or inducers of this process.

Matrix Gla protein was first introduced by Price and colleagues and is a bone matrix protein with 5 to 6 residues of the vitamin K-dependent amino acid, gamma-carboxyglutamic acid.⁹² It is mainly known as an inhibitor of calcification by inhibiting mesenchymal cell differentiation to the osteogenic lineage by preventing the action of the potent osteogenic and chondrogenic differentiation factor, BMP2.⁹³ Spontaneous calcification of arteries and cartilages, together with osteoporosis and pathologic fractures, have been shown in mice lacking matrix Gla protein.⁹⁴ Thus, it seems that matrix Gla protein is required to both promote normal bone formation and inhibit vascular calcification. Matrix Gla protein gamma-carboxylation is a vitamin K-dependent process; therefore, vitamin K deficiency can inhibit matrix Gla protein action and enhance vascular calcification.⁹⁵

Serum levels of matrix Gla protein in dialysis patients did not show any correlation with coronary artery or aortic calcification score by spiral computed tomography; however, examining

the sections of inferior epigastric artery of dialysis patients showed that matrix Gla protein expression correlated with the presence of calcification.⁹⁶ Low levels of vitamin K have been shown in the majority of dialysis patients, and decreased level of circulating matrix Gla protein has been proposed to serve as a predictor of mortality in dialysis patients.⁹⁷ Whether vitamin K supplementation improves outcomes requires further study.

Osteopontin is another matrix protein with inhibitory action on calcification. It is an acidic phosphoprotein normally found in mineralized tissues such as bones and teeth, as well as in the kidney and epithelial linings of the body.⁹⁸ Addition of purified osteopontin to bovine aortic smooth muscle culture media has been shown to inhibit calcification.⁹⁹ Osteopontin levels are associated with the presence and level of coronary artery calcification in dialysis patients,¹⁰⁰ and recombinant osteopontin facilitates resorption of ectopic bone implanted in muscle.¹⁰¹ Osteopontin acts through self-aggregation and adhesion to apatite crystals through specific amino acid moieties.⁷¹

Fetuin-A or $\alpha 2$ -Heremans-Schmid glycoprotein is also an important calcification inhibitor. This protein has been identified by Leberthon and colleagues as a negative acute-phase reactant, more than 30 years earlier.¹⁰² Fetuin-A interacts directly with matrix vesicle release and may thus modulate vascular calcification processes locally and at early stages.¹⁰³ Fetuin-A molecules form stable colloidal spheres with calcium and phosphorus, so-called "calciprotein particles," which inhibit hydroxyapatite precipitation.¹⁰⁴ It also decreases macrophage activation and release of proinflammatory cytokines, antagonizes the action of transforming growth factor- β , and opsonizes apoptotic bodies and promotes their phagocytosis.¹⁰⁵

Fetuin-A levels are significantly lower in dialysis patients and this has been correlated with higher rates of vascular calcification, cardiovascular mortality, and malnutrition and inflammation states, as assessed by subjective global assessment and CRP levels, respectively.¹⁰⁶⁻¹⁰⁸ Results of these studies suggest fetuin-A as both a calcification inhibitor protein and a negative acute-phase reactant, as a link between inflammation atherosclerosis in patients with CKD.

Osteoprotegerin which was first identified by Simonet and colleagues as a glycoprotein and

member of TNF receptor superfamily, inhibits osteoclast maturation and protects bone from normal osteoclast remodeling.¹⁰⁹ It functions as a soluble decoy receptor for RANK ligand (osteoprotegerin ligand) and shares homologies with other members of the TNF receptor superfamily.¹¹⁰ Osteoprotegerin is present in cultured VSMCs, and in rat models, selective inhibition of bone resorption by osteoprotegerin prevents vascular calcification induced by warfarin and vitamin D treatment.¹¹¹ This finding is another support for the link between vascular calcification and bone resorption. However, in human studies, both in normal population and dialysis patients, high levels of osteoprotegerin have been associated with coronary artery disease and vascular calcification.^{112,113} It seems that vascular role of osteoprotegerin is multifaceted and depends on the interplay of osteoprotegerin with its ligands; RANK ligand and TNF-related apoptosis-inducing ligand; and a bidirectional modulation involving osteogenic, inflammatory, and apoptotic responses.¹¹⁴ Morena and colleagues could show that among hemodialysis patients with high CRP levels, both low and high levels of osteoprotegerin strongly associated with all-cause mortality, producing a U-shaped relationship.¹¹⁵

Other proteins necessary to be mentioned in this context are BMP2 and BMP7. Bone morphogenetic protein 7 treatment has been shown to decrease vascular calcification in BMP7 deficient rats,¹¹⁶ while BMP2 antagonizes BMP7, promoting differentiation of VSMCs into the osteoblast-like phenotype.¹⁰⁵ Smad6 antagonizes BMP signaling and loss of its inhibition in Smad6 knockout mice causes aortic ossification.¹¹⁷

Pyrophosphate, a well-known inhibitor of hydroxyapatite formation in urine, is also produced by vessels and inhibits vascular calcification.¹¹⁸ Lomashvili and colleague showed reduced pyrophosphate levels in a group of hemodialysis patients, which may contribute to vascular calcification.¹¹⁹ Pyrophosphate is hydrolyzed by alkaline phosphatase and alkaline phosphatase deficiency increases pyrophosphate levels.¹²⁰ However, no correlation was found between alkaline phosphatase and pyrophosphate levels in Lomashvili and colleagues' study, and they suggested that either hydrolysis of pyrophosphate in tissues (not correlated with plasma level of alkaline phosphatase), decreased PPI synthesis or

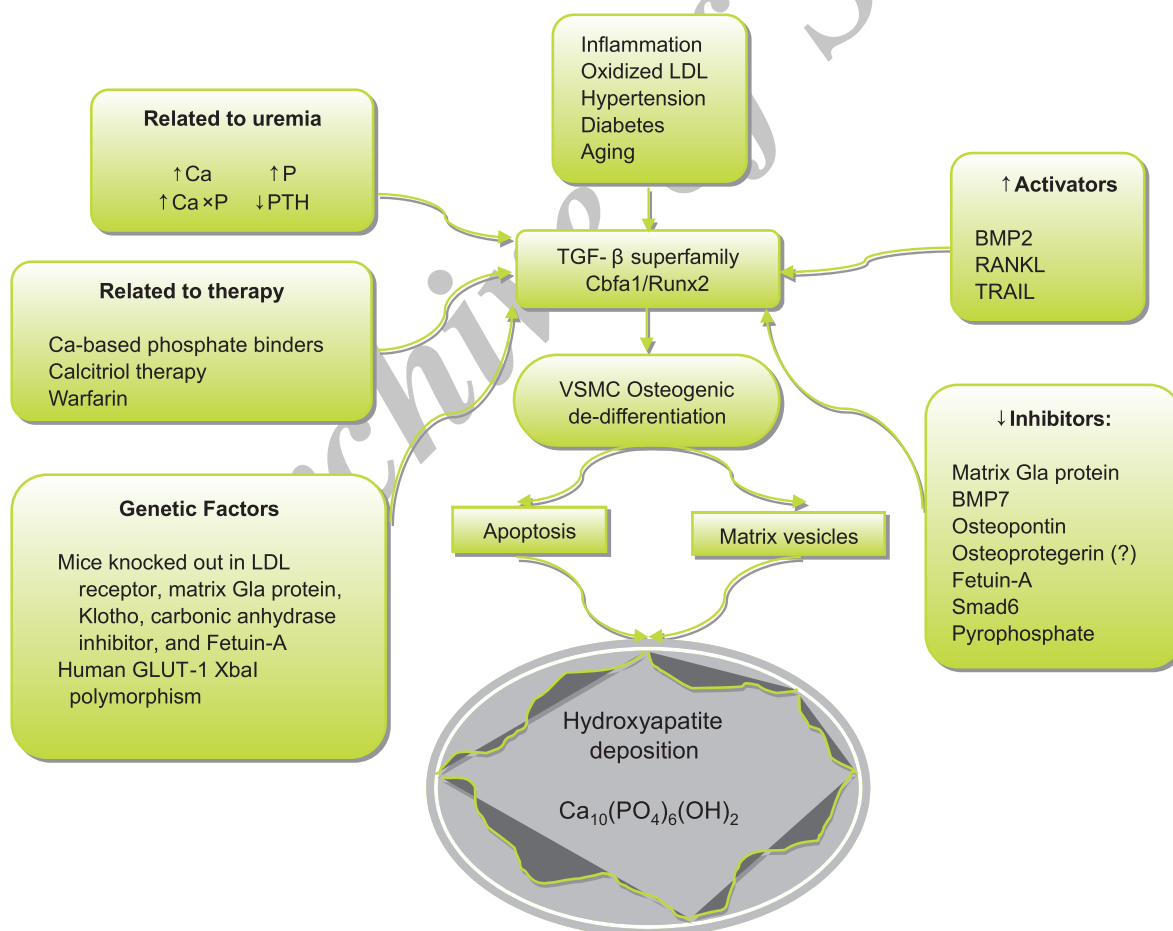
increased nondialytic, or extrarenal clearance may cause decreased pyrophosphate levels in dialysis patients.¹¹⁹

The Figure shows a simplified schema of the abovementioned mechanisms.

CLINICAL IMPLICATIONS

Many studies in general population have shown aortic calcification to increase overall and cardiovascular mortality.¹²¹⁻¹²³ In hemodialysis patients, aortic stiffness, represented by aortic pulse wave velocity and carotid distensibility, are strong independent predictors of cardiovascular and all-cause mortality.¹²⁴⁻¹²⁷ Safar and colleagues were the first to show that carotid pulse pressure, as a measure of central pulse pressure, and mostly the disappearance of pulse pressure amplification were strong independent predictors of all-cause,

including cardiovascular, mortality.¹²⁸ Furthermore, in a therapeutic trial, Guerin and colleagues showed that the lack of aortic pulse wave velocity decrease in response to drug-induced decrease in blood pressure was a significant predictor of cardiovascular death in patients with ESRD.¹²⁹ London and colleagues studied the effect of arterial intimal and medial calcification on mortality of 202 hemodialysis patients.² Compared to patients with intimal calcification, patients with medial calcification had a longer survival, but in turn, their survival was significantly shorter than that of patients without calcifications. They showed arterial medial calcification to be a strong prognostic marker of all-cause and cardiovascular mortality in hemodialysis patients, independent of classical atherogenic factors, principally acting through increased arterial stiffness. The same group, in a



Pathogenic mechanisms of vascular calcification. LDL indicates low-density lipoprotein; Ca, calcium; P, phosphorus; Ca×P, calcium-phosphorus product; PTH, parathyroid hormone; TGF, transforming growth factor; BMP, bone morphogenetic protein; RANKL, receptor activator of nuclear factor-kappa B ligand; TRAIL, tumor necrosis factor-related apoptosis-inducing ligand; VSMC, vascular smooth muscle cell; and GLUT-1, glucose transporter gene-1.

previous study on 110 hemodialysis patients, had shown that the presence and extent of vascular calcifications, detected by ultrasonography and abdominopelvic radiography, were strong predictors of cardiovascular and all-cause mortality.³ Adjusted hazard ratios of all-cause and cardiovascular mortality for an increase of 1 unit in calcification score were 1.9 and 2.6, respectively ($P = .001$ for both) in this study.

Even after kidney transplantation, vascular calcification is an important determinant of cardiovascular events. In a clinical trial on 112 kidney transplant recipients, DeLoach and colleagues showed that aortic calcification, diagnosed by electron beam computed tomography, was prevalent and could predict future cardiovascular events.¹³⁰ They suggested screening of aortic calcification for assessment of cardiovascular risk in asymptomatic kidney transplant recipients.

A large prospective clinical trial is being carried out on more than 4000 CKD patients in Spain (the NEFRONA study), which will examine the predictive value of several noninvasive imaging techniques and novel biomarkers of cardiovascular disease, including vascular calcification markers, for prediction of cardiovascular morbidity and mortality in CKD.¹³¹

DIAGNOSIS

The gold standard for diagnosis of vascular calcification would be histological examination of the arterial specimens, which is not clinically feasible. The other recommended diagnostic techniques are electron beam computed tomography, which is more of research interest and not accessible in most centers of the world; ultrasonographic measurement of pulse wave velocity or carotid intima-media thickness; and plain radiography of the abdominal aorta.^{128,132-137}

The Kidney Disease Improving Global Outcomes 2009 guidelines suggest a lateral abdominal radiography or an echocardiography for detection of the presence or absence of vascular or valvular calcification, respectively, in patients with CKD stages 3 to 5.¹³⁸ However, screening for vascular calcification is not yet recommended by many authorities due to uncertainty on the sensitivity and specificity of the recommended screening methods, cost versus benefit of these methods, and lack of effective treatment modalities.^{139,140}

TREATMENT STRATEGIES

A significant interaction has been found between dosage of calcium-containing phosphate binders and bone activity, and calcium load has been shown to significantly influence on aortic calcifications and stiffening in the presence of adynamic bone disease.¹⁴¹ Lower trabecular bone volume has been associated with development of coronary artery calcification and improvement in bone turnover has been correlated with lower rate of progression of coronary artery calcification.¹⁴² Therefore, many studies now emphasize on the use of non-calcium-based phosphate binders as a strategy to prevent or even regress vascular calcification.

Phan and colleagues showed the effect of sevelamer on prevention of progression of both intimal and medial calcification in aortic wall of uremic apolipoprotein E-deficient mice, together with decreased nitrotyrosine expression, as a marker of oxidative damage.¹⁴³ Chertow and colleagues, in a study on 200 hemodialysis patients, could show an increase in median absolute calcium score in coronary arteries and aorta, measured by electron beam tomography in calcium treated- but not in sevelamer-treated patients.¹⁴⁴ The same group later showed decreased levels of total and LDL cholesterol, apolipoprotein B, β 2-microglobulin, and highly sensitivity CRP, and increased level of high-density lipoprotein in sevelamer-treated but not in calcium acetate-treated hemodialysis patients.¹⁴⁵ Studies by Block and colleagues and Asmus and coworkers also showed the protective effect of sevelamer on vascular calcification in dialysis patients.^{47,49}

However, in a study by Suki and colleagues on more than 1000 hemodialysis patients followed for up to 45 months, the overall mortality was not significantly reduced by sevelamer compared with calcium-based phosphate binders, except for patients older than 65 years of age, in whom sevelamer reduced the risk of death (adjusted relative risk, 0.77).¹⁴⁶ Also, a recent systematic review on clinical efficacy and safety of sevelamer in dialysis patients could not show any evidence that sevelamer reduced all-cause mortality, cardiovascular mortality, the frequency of symptomatic bone disease, or health-related quality of life.¹⁴⁷

Cinacalcet has also been studied in terms of its impact on vascular calcification. In a combined analysis of 4 similar studies, Cunningham and colleagues surveyed 1184 ESRD patients

with hyperphosphatemia and secondary hyperparathyroidism (697 patients on cinacalcet and 487 on placebo).¹⁴⁸ Cinacalcet significantly reduced cardiovascular hospitalization compared with placebo. In the ADVANCE clinical trial, Raggi and colleagues, studied the effect of cinacalcet plus low-dose vitamin D on vascular calcification of 360 prevalent hemodialysis patients and could show attenuation of vascular and cardiac valve calcification assessed by using multidetector computed tomography.¹⁴⁹ The results of the EVOLVE trial may further delineate this issue, by examining the effect of cinacalcet on all-cause and cardiovascular mortality and morbidity, peripheral vascular disease, and stroke in hyperparathyroid maintenance hemodialysis patients.¹⁵⁰

Other medications suggested for attenuation of vascular calcification in CKD patients are bisphosphonates,¹⁵¹⁻¹⁵³ BMP7 that has been investigated in murine models of vascular calcification,¹¹⁶ anti-RANK ligand therapy,¹⁵⁴ and teriparatide used for inhibition of vascular calcification in diabetic LDL-deficient mice.⁵⁷

CONCLUSIONS

With the bulk of data emphasizing the reverse association between skeletal and vascular mineralization, the paradigm of saving “bones” at the expense of hypercalcemia and adynamic bone disease, has changed to an integrated approach trying to keep the balance between healthy bones and vasculature. Minimizing the traditional risk factors of vascular calcification together with avoidance of hypercalcemia and high dose of calcium-based phosphate binders and vitamin D analogues seem to be important measures for prevention or attenuation of progression of vascular calcification. Unfortunately, there are not many therapeutic choices available to effectively reverse the process of vascular calcification, and most strategies seem to be preventive. With the evolving knowledge of the pathogenesis of vascular calcification, we can look forward to emergence of novel therapies in the future.

CONFLICT OF INTEREST

None declared.

REFERENCES

1. United States Renal Data System. Excerpts from USRDS 2009 Annual Data Report. U.S. Department of Health

- and Human Services. The National Institutes of Health, National Institute of Diabetes and Digestive and Kidney Diseases. *Am J Kidney Dis.* 2010;55:S1.
2. London GM, Guerin AP, Marchais SJ, Metivier F, Pannier B, Adda H. Arterial media calcification in end-stage renal disease: impact on all-cause and cardiovascular mortality. *Nephrol Dial Transplant.* 2003;18:1731-40.
3. Blacher J, Guerin AP, Pannier B, Marchais SJ, London GM. Arterial calcifications, arterial stiffness, and cardiovascular risk in end-stage renal disease. *Hypertension.* 2001;38:938-42.
4. Braun J, Oldendorf M, Moshage W, Heidler R, Zeitler E, Luft FC. Electron beam computed tomography in the evaluation of cardiac calcification in chronic dialysis patients. *Am J Kidney Dis.* 1996;27:394-401.
5. Parfitt AM. Soft-tissue calcification in uremia. *Arch Intern Med.* 1969;124:544.
6. Pollack VE, Schneider AF, Freund G, Kark RM. Chronic renal disease with secondary hyperparathyroidism. *Arch Intern Med.* 1959;103:200.
7. Milliner DS, Zinsmeister AR, Lieberman E, Landing B. Soft tissue calcification in pediatric patients with end-stage renal disease. *Kidney Int.* 1990;38:931-6.
8. Oh J, Wunsch R, Turzer M, et al. Advanced coronary and carotid arteriopathy in young adults with childhood-onset chronic renal failure. *Circulation.* 2002;106:100-5.
9. Merjanian R, Budoff M, Adler S, Berman N, Mehrotra R. Coronary artery, aortic wall, and valvular calcification in nondialyzed individuals with type 2 diabetes and renal disease. *Kidney Int.* 2003;64:263-71.
10. Meema HE, Oreopoulos DG. Morphology, progression, and regression of arterial and periarterial calcifications in patients with end-stage renal disease. *Radiology* 1986;158:671-7.
11. Meema HE, Oreopoulos DG, Rapoport A. Serum magnesium level and arterial calcification in end-stage renal disease. *Kidney Int.* 1987;32:388-94.
12. Levey AS, Beto JA, Coronado BE, et al. Controlling the epidemic of cardiovascular disease in chronic renal disease: what do we know? What do we need to learn? Where do we go from here? National Kidney Foundation Task Force on Cardiovascular Disease. *Am J Kidney Dis.* 1998;32:853.
13. Contiguglia SR, Alfrey AC, Miller NL, Runnells DE, Le Geros RZ. Nature of soft tissue calcification in uremia. *Kidney Int.* 1973;4:229-35.
14. Reid JD, Andersen ME. Medial calcification (whitlockite) in the aorta. *Atherosclerosis.* 1993;101:213-24.
15. Stary HC. Lipid and macrophage accumulations in arteries of children and the development of atherosclerosis. *Am J Clin Nutr.* 2000;72:1297S-1306S.
16. Shanahan CM, Cary NR, Salisbury JR, Proudfoot D, Weissberg PL, Edmonds ME. Medial localization of mineralization-regulating proteins in association with Mönckeberg's sclerosis: evidence for smooth muscle cell-mediated vascular calcification. *Circulation.* 1999;100:2168-76.
17. Proudfoot D, Davies JD, Skepper JN, Weissberg PL, Shanahan CM. Acetylated low-density lipoprotein

- stimulates human vascular smooth muscle cell calcification by promoting osteoblastic differentiation and inhibiting phagocytosis. *Circulation*. 2002;106:3044-50.
18. Lanzer P. [Mönckeberg media calcinosis]. *Z Kardiol*. 1998;87:586-93. German.
 19. Proudfoot D, Shanahan CM. Biology of calcification in vascular cells: intima versus media. *Herz*. 2001;26:245-51.
 20. Shroff RC, Shanahan CM. The vascular biology of calcification. *Semin Dial*. 2007;20:103-9.
 21. Giachelli CM. Vascular calcification mechanisms. *J Am Soc Nephrol*. 2004;15:2959-64.
 22. Ivandic BT, Qiao JH, Machleder D, Liao F, Drake TA, Lusis AJ. A locus on chromosome 7 determines myocardial cell necrosis and calcification (dystrophic cardiac calcinosis) in mice. *Proc Natl Acad Sci U S A*. 1996;93:5483-8.
 23. Ivandic BT, Utz HF, Kaczmarek PM, et al. New Dyscalc loci for myocardial cell necrosis and calcification (dystrophic cardiac calcinosis) in mice. *Physiol Genomics*. 2001;6:137-44.
 24. Colinayo VV, Qiao JH, Demant P, Krass K, Lusis AJ, Drake TA. Genetic characterization of the Dyscalc locus. *Mamm Genome*. 2002;13:283-8.
 25. Matsui Y, Rittling SR, Okamoto H, et al. Osteopontin deficiency attenuates atherosclerosis in female apolipoprotein E-deficient mice. *Arterioscler Thromb Vasc Biol*. 2003;23:1029-34.
 26. Pan JH, Sukhova GK, Yang JT, et al. Macrophage migration inhibitory factor deficiency impairs atherosclerosis in low-density lipoprotein receptor-deficient mice. *Circulation*. 2004;109:3149-53.
 27. Luo G, Ducey P, McKee MD, et al. Spontaneous calcification of arteries and cartilage in mice lacking matrix GLA protein. *Nature*. 1997;386:78-81.
 28. Speer MY, Chien YC, Quan M, et al. Smooth muscle cells deficient in osteopontin have enhanced susceptibility to calcification in vitro. *Cardiovasc Res*. 2005;66:324-33.
 29. Kuro-o M, Matsumura Y, Aizawa H, et al. Mutation of the mouse *klotho* gene leads to a syndrome resembling ageing. *Nature*. 1997;390:45-51.
 30. Spicer SS, Lewis SE, Tashian RE, Schulte BA. Mice carrying a *CAR-2* null allele lack carbonic anhydrase II immunohistochemically and show vascular calcification. *Am J Pathol*. 1989;134:947-54.
 31. Schafer C, Heiss A, Schwarz A, et al. The serum protein alpha 2-Heremans-Schmid glycoprotein/fetuin-A is a systemically acting inhibitor of ectopic calcification. *J Clin Invest*. 2003;112:357-66.
 32. Musunuru K, Post WS, Herzog W, et al. Association of single nucleotide polymorphisms on chromosome 9p21.3 with platelet reactivity: a potential mechanism for increased vascular disease. *Circ Cardiovasc Genet*. 2010;3:445-53.
 33. Burdon KP, Rudock ME, Lehtinen AB, et al. Human lipoxygenase pathway gene variation and association with markers of subclinical atherosclerosis in the diabetes heart study. *Mediators Inflamm*. 2010;170153.
 34. Schmitz F, Ewering S, Zerres K, Klomfuss S, Hoffmann R, Ortlepp JR. Parathyroid hormone gene variant and calcific aortic stenosis. *J Heart Valve Dis*. 2009;18:262-7.
 35. Freedman BI, Bowden DW, Ziegler JT, et al. Bone morphogenetic protein 7 (BMP7) gene polymorphisms are associated with inverse relationships between vascular calcification and BMD: the Diabetes Heart Study. *J Bone Miner Res*. 2009;24:1719-27.
 36. Pfohl M, Athanasiadis A, Koch M, et al. Insertion/deletion polymorphism of the angiotensin I-converting enzyme gene is associated with coronary artery plaque calcification as assessed by intravascular ultrasound. *J Am Coll Cardiol*. 1998;31:987-91.
 37. Narayan KM, Pettitt DJ, Hanson RL, et al. Familial aggregation of medial arterial calcification in Pima Indians with and without diabetes. *Diabetes Care*. 1996;19:968-71.
 38. Wagenknecht LE, Bowden DW, Carr JJ, Langefeld CD, Freedman BI, Rich SS. Familial aggregation of coronary artery calcium in families with type 2 diabetes. *Diabetes*. 2001;50:861-6.
 39. Wang Y, Zhang W, Zhang Y, et al. VKORC1 haplotypes are associated with arterial vascular diseases (stroke, coronary heart disease, and aortic dissection). *Circulation*. 2006;113:1615-21.
 40. Rufino M, Hernández D, Barrios Y, Salido E. The GLUT-1 XbaI gene polymorphism is associated with vascular calcifications in nondiabetic uremic patients. *Nephron Clin Pract*. 2008;108:c182-7.
 41. Giachelli CM. Mechanisms of vascular calcification in uremia. *Semin Nephrol*. 2004;24:401-2.
 42. El-Abbadi MM, Pai AS, Leaf EM, et al. Phosphate feeding induces arterial medial calcification in uremic mice: role of serum phosphorus, fibroblast growth factor-23, and osteopontin. *Kidney Int*. 2009;75:1297-307.
 43. Goodman WG, Goldin J, Kuizon BD, et al. Coronary-artery calcification in young adults with end-stage renal disease who are undergoing dialysis. *N Engl J Med*. 2000;342:1478-83.
 44. Chertow GM, Raggi P, Chasan-Taber S, Bommer J, Holzer H, Burke SK. Determinants of progressive vascular calcification in haemodialysis patients. *Nephrol Dial Transplant*. 2004;19:1489-96.
 45. Phan O, Ivanovski O, Nikolov IG, et al. Effect of oral calcium carbonate on aortic calcification in apolipoprotein E-deficient (apoE^{-/-}) mice with chronic renal failure. *Nephrol Dial Transplant*. 2008;23:82-90.
 46. Ossareh S, Alaei A, Saedi D. Carotid intima-media thickness in maintenance hemodialysis patients: role of cardiovascular risk factor. *Iran J Kidney Dis*. 2011;5:169-74.
 47. Block GA, Spiegel DM, Ehrlich J, et al. Effects of sevelamer and calcium on coronary artery calcification in patients new to hemodialysis. *Kidney Int*. 2005;68:1815-24.
 48. Mathew S, Lund RJ, Strebeck F, Tustison KS, Geurs T, Hruska KA. Reversal of the adynamic bone disorder and decreased vascular calcification in chronic kidney disease by sevelamer carbonate therapy. *J Am Soc Nephrol*. 2007;18:122-30.
 49. Asmus HG, Braun J, Krause R, et al. Two year comparison of sevelamer and calcium carbonate effects on cardiovascular calcification and bone density. *Nephrol*

- Dial Transplant. 2005;20:1653-61.
50. Covic A, Kanbay M, Voroneanu L, et al. Vascular calcification in chronic kidney disease. *Clin Sci (Lond)*. 2010;119:111-21.
 51. Yang H, Curinga G, Giachelli CM. Elevated extracellular calcium levels induce smooth muscle cell matrix mineralization in vitro. *Kidney Int*. 2004;66:2293-9.
 52. Shioi A, Nishizawa Y. [Roles of hyperphosphatemia in vascular calcification]. *Clin Calcium*. 2009;19:180-5. Japanese.
 53. Adragao T, Pires A, Lucas C, et al. A simple vascular calcification score predicts cardiovascular risk in haemodialysis patients. *Nephrol Dial Transplant*. 2004;19:1480-8.
 54. Oh J, Wunsch R, Turzer M, et al. Advanced coronary and carotid arteriopathy in young adults with childhood-onset chronic renal failure. *Circulation*. 2002;106:100-5.
 55. Kraśniak A, Drozd M, Pasowicz M, et al. Factors involved in vascular calcification and atherosclerosis in maintenance haemodialysis patients. *Nephrol Dial Transplant*. 2007;22:515-21.
 56. Goldsmith DJ, Covic A, Sambrook PA, Ackrill P. Vascular calcification in long-term haemodialysis patients in a single unit: a retrospective analysis. *Nephron*. 1997;77:37-43.
 57. Shao JS, Cheng SL, Charlton-Kachigian N, Loewy AP, Towler DA. Teriparatide (human parathyroid hormone (1-34)) inhibits osteogenic vascular calcification in diabetic low density lipoprotein receptor-deficient mice. *J Biol Chem*. 2003;278:50195-202.
 58. Shanahan CM. Mechanisms of vascular calcification in renal disease. *Clin Nephrol*. 2005;63:146-57.
 59. Martola L, Barany P, Stenvinkel P. Why do dialysis patients develop a heart of stone and bone of china? *Blood Purif*. 2005;23:203-10.
 60. Razzaque MS. The dualistic role of vitamin D in vascular calcifications. *Kidney Int*. 2011;79:708-14.
 61. Zehnder D, Bland R, Chana RS, et al. Synthesis of 1,25-dihydroxyvitamin D(3) by human endothelial cells is regulated by inflammatory cytokines: a novel autocrine determinant of vascular cell adhesion. *Am Soc Nephrol*. 2002;13:621-9.
 62. Watson KE, Abrolat ML, Malone LL, et al. Active serum vitamin D levels are inversely correlated with coronary calcification. *Circulation*. 1997;96:1755-60.
 63. Braam LA, Hoeks AP, Brouns F, Hamulyák K, Gerichhausen MJ, Vermeer C. Beneficial effects of vitamins D and K on the elastic properties of the vessel wall in postmenopausal women: a follow-up study. *Thromb Haemost*. 2004;91:373-80.
 64. Briese S, Wiesner S, Will JC, et al. Arterial and cardiac disease in young adults with childhood-onset end-stage renal disease-impact of calcium and vitamin D therapy. *Nephrol Dial Transplant*. 2006;21:1906-14.
 65. McCullough PA, Sandberg KR, Dumler F, Yanez JE. Determinants of coronary vascular calcification in patients with chronic kidney disease and end-stage renal disease: a systematic review. *Nephrol*. 2004 Mar-;17:205-15.
 66. Henley C, Colloton M, Cattley RC, et al. 1,25-Dihydroxyvitamin D3 but not cinacalcet HCl (Sensipar/Mimpara) treatment mediates aortic calcification in a rat model of secondary hyperparathyroidism. *Nephrol Dial Transplant*. 2005;20:1370-7.
 67. Haffner D, Hoche B, Müller D, et al. Systemic cardiovascular disease in uremic rats induced by 1,25(OH)2D3. *J Hypertens*. 2005;23:1067-75.
 68. Memon F, El-Abbadi M, Nakatani T, Taguchi T, Lanske B, Razzaque MS. Does Fgf23-klotho activity influence vascular and soft tissue calcification through regulating mineral ion metabolism? *Kidney Int*. 2008;74:566-70.
 69. Razzaque MS, Lanske B. Hypervitaminosis D and premature aging: lessons learned from Fgf23 and Klotho mutant mice. *Trends Mol Med*. 2006;12:298-305.
 70. Shroff R, Egerton M, Bridel M, et al. A bimodal association of vitamin D levels and vascular disease in children on dialysis. *J Am Soc Nephrol*. 2008;19:1239-46.
 71. Abedin M, Tintut Y, Demer LL. Vascular calcification: mechanisms and clinical ramifications. *Arterioscler Thromb Vasc Biol*. 2004;24:1161-70.
 72. Giachelli C, Bae N, Lombardi D, Majesky M, Schwartz S. Molecular cloning and characterization of 2B7, a rat mRNA which distinguishes smooth muscle cell phenotypes in vitro and is identical to osteopontin (secreted phosphoprotein I, 2aR). *Biochem Biophys Res Commun*. 1991;177:867-73.
 73. Boström K, Watson KE, Horn S, Wortham C, Herman IM, Demer LL. Bone morphogenetic protein expression in human atherosclerotic lesions. *J Clin Invest*. 1993;91:1800-9.
 74. Shanahan CM, Cary NR, Metcalfe JC, Weissberg PL. High expression of genes for calcification-regulating proteins in human atherosclerotic plaques. *J Clin Invest*. 1994;93:2393-402.
 75. Renneberg RJ, Schurgers LJ, Kroon AA, Stehouwer CD. Arterial calcifications. *J Cell Mol Med*. 2010;14:2203-10.
 76. Steitz SA, Speer MY, Curinga G, et al. Smooth muscle cell phenotypic transition associated with calcification: upregulation of Cbfa1 and downregulation of smooth muscle lineage markers. *Circ Res*. 2001;89:1147-54.
 77. Chamley-Campbell J, Campbell GR, Ross R. The smooth muscle cell in culture. *Physiol Rev*. 1979;59:1-61.
 78. Chamley-Campbell JH, Campbell GR, Ross R. Phenotype-dependent response of cultured aortic smooth muscle to serum mitogens. *J Cell Biol*. 1981;89:379-83.
 79. Weissberg PL, Clesham GJ, Bennett MR. Is vascular smooth muscle cell proliferation beneficial? *Lancet*. 1996;347(8997):305-7.
 80. Iyemere VP, Proudfoot D, Weissberg PL, Shanahan CM. Vascular smooth muscle cell phenotypic plasticity and the regulation of vascular calcification. *J Intern Med*. 2006;260:192-210.
 81. King KE, Iyemere VP, Weissberg PL, Shanahan CM. Krüppel-like factor 4 (KLF4/GKLF) is a target of bone morphogenetic proteins and transforming growth factor beta 1 in the regulation of vascular smooth muscle cell phenotype. *J Biol Chem*. 2003;278:11661-9.
 82. Anderson HC. Molecular biology of matrix vesicles. *Clin Orthop Relat Res*. 1995;:266-80.
 83. Kim KM. Calcification of matrix vesicles in human aortic

- valve and aortic media. *Fed Proc.* 1976;35:156-62.
84. Reynolds JL, Joannides AJ, Skepper JN, et al. Human vascular smooth muscle cells undergo vesicle-mediated calcification in response to changes in extracellular calcium and phosphate concentrations: a potential mechanism for accelerated vascular calcification in ESRD. *J Am Soc Nephrol.* 2004;15:2857-67.
 85. Isner JM, Kearney M, Bortman S, Passeri J. Apoptosis in human atherosclerosis and restenosis. *Circulation.* 1995;91:2703-11.
 86. Kockx MM, De Meyer GR, Muhring J, Jacob W, Bult H, Herman AG. Apoptosis and related proteins in different stages of human atherosclerotic plaques. *Circulation.* 1998;97:2307-15.
 87. Geng YJ, Libby P. Evidence for apoptosis in advanced human atheroma. Colocalization with interleukin-1 beta-converting enzyme. *Am J Pathol.* 1995;147:251-66.
 88. Proudfoot D, Skepper JN, Hegyi L, Bennett MR, Shanahan CM, Weissberg PL. Apoptosis regulates human vascular calcification in vitro: evidence for initiation of vascular calcification by apoptotic bodies. *Circ Res.* 2000;87:1055-62.
 89. Littlewood TD, Bennett MR. Apoptotic cell death in atherosclerosis. *Curr Opin Lipidol.* 2003;14:469-75.
 90. Kim HH, Kim K. Enhancement of TNF-alpha-mediated cell death in vascular smooth muscle cells through cytochrome c-independent pathway by the proteasome inhibitor. *FEBS Lett.* 2003;535:190-4.
 91. Kockx MM. Apoptosis in the atherosclerotic plaque: quantitative and qualitative aspects. *Arterioscler Thromb Vasc Biol.* 1998;18:1519-22.
 92. Price PA, Urist MR, Otawara Y. Matrix Gla protein, a new gamma-carboxyglutamic acid-containing protein which is associated with the organic matrix of bone. *Biochem Biophys Res Commun.* 1983;117:765-71.
 93. Boström K, Tsao D, Shen S, Wang Y, Demer LL. Matrix GLA protein modulates differentiation induced by bone morphogenetic protein-2 in C3H10T1/2 cells. *J Biol Chem.* 2001;276:14044-52.
 94. Luo G, Ducy P, McKee MD, et al. Spontaneous calcification of arteries and cartilage in mice lacking matrix GLA protein. *Nature.* 1997;386:78-81.
 95. Krueger T, Westenfeld R, Schurgers L, Brandenburg V. Coagulation meets calcification: the vitamin K system. *Int J Artif Organs.* 2009;32:67-74.
 96. Moe SM, Chen NX. Pathophysiology of vascular calcification in chronic kidney disease. *Circ Res.* 2004;95:560-7.
 97. Schlieper G, Westenfeld R, Krüger T, et al. Circulating nonphosphorylated carboxylated matrix gla protein predicts survival in ESRD. *J Am Soc Nephrol.* 2011;22:387-95.
 98. Giachelli CM, Schwartz SM, Liaw L. Molecular and cellular biology of osteopontin: potential role in cardiovascular disease. *Trends Cardiovasc Med.* 1995;5:88-95.
 99. Wada T, McKee MD, Steitz S, Giachelli CM. Calcification of vascular smooth muscle cell cultures: inhibition by osteopontin. *Circ Res.* 1999;84:166-78.
 100. Ohmori R, Momiyama Y, Taniguchi H, et al. Plasma osteopontin levels are associated with the presence and extent of coronary artery disease. *Atherosclerosis.* 2003;170:333-7.
 101. Asou Y, Rittling SR, Yoshitake H, et al. Osteopontin facilitates angiogenesis, accumulation of osteoclasts, and resorption in ectopic bone. *Endocrinology.* 2001;142:1325-32.
 102. Lebreton JP, Joisel F, Raoult JP, Lannuzel B, Rogez JP, Humbert G. Serum concentration of human alpha 2 HS glycoprotein during the inflammatory process: evidence that alpha 2 HS glycoprotein is a negative acute-phase reactant. *J Clin Invest.* 1979;64:1118-29.
 103. Ketteler M. Fetuin-A and extraosseous calcification in uremia. *Curr Opin Nephrol Hypertens.* 2005;14:337-42.
 104. Heiss A, DuChesne A, Denecke B, et al. Structural basis of calcification inhibition by alpha 2-HS glycoprotein/fetuin-A. Formation of colloidal calciprotein particles. *J Biol Chem.* 2003;278:13333-41.
 105. Stompór T. An overview of the pathophysiology of vascular calcification in chronic kidney disease. *Perit Dial Int.* 2007;27 Suppl 2:S215-22.
 106. Ketteler M, Bongartz P, Westenfeld R, et al. Association of low fetuin-A (AHSG) concentrations in serum with cardiovascular mortality in patients on dialysis: a cross-sectional study. *Lancet.* 2003;361:827-33.
 107. Honda H, Qureshi AR, Heimbürger O, et al. Serum albumin, C-reactive protein, interleukin 6, and fetuin a as predictors of malnutrition, cardiovascular disease, and mortality in patients with ESRD. *Am J Kidney Dis.* 2006;47:139-48.
 108. Stenvinkel P, Wang K, Qureshi AR, et al. Low fetuin-A levels are associated with cardiovascular death: Impact of variations in the gene encoding fetuin. *Kidney Int.* 2005;67:2383-92.
 109. Simonet WS, Lacey DL, Dunstan CR, et al. Osteoprotegerin: a novel secreted protein involved in the regulation of bone density. *Cell.* 1997;89:309-19.
 110. Schoppet M, Preissner KT, Hofbauer LC. RANK ligand and osteoprotegerin: paracrine regulators of bone metabolism and vascular function. *Arterioscler Thromb Vasc Biol.* 2002;22:549-53.
 111. Price PA, June HH, Buckley JR, Williamson MK. Osteoprotegerin inhibits artery calcification induced by warfarin and by vitamin D. *Arterioscler Thromb Vasc Biol.* 2001;21:1610-6.
 112. Jono S, Ikari Y, Shioi A, et al. Serum osteoprotegerin levels are associated with the presence and severity of coronary artery disease. *Circulation.* 2002;106:1192-4.
 113. Nitta K, Akiba T, Uchida K, et al. The progression of vascular calcification and serum osteoprotegerin levels in patients on long-term hemodialysis. *Am J Kidney Dis.* 2003;42:303-9.
 114. Van Campenhout A, Golledge J. Osteoprotegerin, vascular calcification and atherosclerosis. *Atherosclerosis.* 2009;204:321-9.
 115. Morena M, Terrier N, Jaussent I, et al. Plasma osteoprotegerin is associated with mortality in hemodialysis patients. *J Am Soc Nephrol.* 2006;17:262-70.

116. Davies MR, Lund RJ, Hruska KA. BMP-7 is an efficacious treatment of vascular calcification in a murine model of atherosclerosis and chronic renal failure. *J Am Soc Nephrol.* 2003;14:1559-67.
117. Galvin KM, Donovan MJ, Lynch CA, et al. A role for smad6 in development and homeostasis of the cardiovascular system. *Nat Genet.* 2000;24:171-4.
118. Lomashvili KA, Cobbs S, Hennigar RA, Hardcastle KI, O'Neill WC. Phosphate-induced vascular calcification: role of pyrophosphate and osteopontin. *J Am Soc Nephrol.* 2004;15:1392-401.
119. Lomashvili KA, Khawandi W, O'Neill WC. Reduced plasma pyrophosphate levels in hemodialysis patients. *J Am Soc Nephrol.* 2005;16:2495-500.
120. Rachow JW, Ryan LM. Inorganic pyrophosphate metabolism in arthritis. *Rheum Dis Clin North Am.* 1988;14:289-302.
121. Witteman JC, Kok FJ, van Saase JL, Valkenburg HA. Aortic calcification as a predictor of cardiovascular mortality. *Lancet.* 1986;2:1120-2.
122. Rodondi N, Taylor BC, Bauer DC, et al. Association between aortic calcification and total and cardiovascular mortality in older women. *J Intern Med.* 2007;261:238-44.
123. Rennenberg RJ, Kessels AG, Schurgers LJ, van Engelshoven JM, de Leeuw PW, Kroon AA. Vascular calcifications as a marker of increased cardiovascular risk: a meta-analysis. *Vasc Health Risk Manag.* 2009;5:185-97.
124. Blacher J, Safar ME, Pannier B, Guerin AP, Marchais SJ, London GM. Prognostic significance of arterial stiffness measurements in end-stage renal disease patients. *Curr Opin Nephrol Hypertens.* 2002;11:629-34.
125. Guérin AP, Pannier B, Marchais SJ, London GM. Cardiovascular disease in the dialysis population: prognostic significance of arterial disorders. *Curr Opin Nephrol Hypertens.* 2006;15:105-10.
126. London GM. Cardiovascular calcifications in uremic patients: clinical impact on cardiovascular function. *J Am Soc Nephrol.* 2003;14:S305-9.
127. London GM, Marchais SJ, Guerin AP. Arterial stiffness and function in end-stage renal disease. *Adv Chronic Kidney Dis.* 2004;11:202-9.
128. Safar ME, Blacher J, Pannier B, et al. Central pulse pressure and mortality in end-stage renal disease. *Hypertension.* 2002;39:735-8.
129. Guerin AP, Blacher J, Pannier B, Marchais SJ, Safar ME, London GM. Impact of aortic stiffness attenuation on survival of patients in end-stage renal failure. *Circulation.* 2001;103:987-92.
130. DeLoach SS, Joffe MM, Mai X, Goral S, Rosas SE. Aortic calcification predicts cardiovascular events and all-cause mortality in renal transplantation. *Nephrol Dial Transplant.* 2009;24:1314-9.
131. Junyent M, Martínez M, Borràs M, et al. Predicting cardiovascular disease morbidity and mortality in chronic kidney disease in Spain. The rationale and design of NEFRONA: a prospective, multicenter, observational cohort study. *BMC Nephrol.* 2010;11:14.
132. Braun J, Oldendorf M, Moshage W, Heidler R, Zeitler E, Luft FC. Electron beam computed tomography in the evaluation of cardiac calcification in chronic dialysis patients. *Am J Kidney Dis.* 1996;27:394-401.
133. Blacher J, Asmar R, Djane S, London GM, Safar ME. Aortic pulse wave velocity as a marker of cardiovascular risk in hypertensive patients. *Hypertension.* 1999;33:1111-7.
134. Persson J, Formgren J, Israelsson B, Berglund G. Ultrasound-determined intima-media thickness and atherosclerosis. Direct and indirect validation. *Arterioscler Thromb.* 1994;14:261-4.
135. Kauppila LI, Polak JF, Cupples LA, Hannan MT, Kiel DP, Wilson PW. New indices to classify location, severity and progression of calcific lesions in the abdominal aorta: a 25-year follow-up study. *Atherosclerosis.* 1997;132:245-50.
136. Bellasi A, Ferramosca E, Muntner P, et al. Correlation of simple imaging tests and coronary artery calcium measured by computed tomography in hemodialysis patients. *Kidney Int.* 2006;70:1623-8.
137. Wang AY, Wang M, Woo J, et al. Cardiac valve calcification as an important predictor for all-cause mortality and cardiovascular mortality in long-term peritoneal dialysis patients: a prospective study. *J Am Soc Nephrol.* 2003;14:159-68.
138. Kidney Disease: Improving Global Outcomes (KDIGO) CKD-MBD Work Group. KDIGO clinical practice guideline for the diagnosis, evaluation, prevention, and treatment of Chronic Kidney Disease-Mineral and Bone Disorder (CKD-MBD). *Kidney Int Suppl.* 2009;S1-130.
139. Goldsmith D. The case against routine screening for vascular calcification in chronic kidney disease. *Semin Dial.* 2010;23:280-2.
140. Uhlig K. There is no practical utility in routinely screening dialysis patients for vascular calcification. *Semin Dial.* 2010;23:277-9.
141. London GM, Marchais SJ, Guérin AP, Boutouyrie P, Métivier F, de Vernejoul MC. Association of bone activity, calcium load, aortic stiffness, and calcifications in ESRD. *J Am Soc Nephrol.* 2008;19:1827-35.
142. Barreto DV, Barreto Fde C, Carvalho AB, et al. Association of changes in bone remodeling and coronary calcification in hemodialysis patients: a prospective study. *Am J Kidney Dis.* 2008;52:1139-50.
143. Phan O, Ivanovski O, Nguyen-Khoa T, et al. Sevelamer prevents uremia-enhanced atherosclerosis progression in apolipoprotein E-deficient mice. *Circulation.* 2005;112:2875-82.
144. Chertow GM, Burke SK, Raggi P; Treat to Goal Working Group. Sevelamer attenuates the progression of coronary and aortic calcification in hemodialysis patients. *Kidney Int.* 2002;62:245-52.
145. Ferramosca E, Burke S, Chasan-Taber S, Ratti C, Chertow GM, Raggi P. Potential antiatherogenic and anti-inflammatory properties of sevelamer in maintenance hemodialysis patients. *Am Heart J.* 2005;149:820-5.
146. Suki WN; Dialysis Clinical Outcomes Revisited Investigators. Effects of sevelamer and calcium-based phosphate binders on mortality in hemodialysis patients: results of a randomized clinical trial. *J Ren Nutr.* 2008;18:91-8.

147. Tonelli M, Wiebe N, Culleton B, et al; Alberta Kidney Disease Network. Systematic review of the clinical efficacy and safety of sevelamer in dialysis patients. *Nephrol Dial Transplant*. 2007;22:2856-66.
148. Cunningham J, Danese M, Olson K, Klassen P, Chertow GM. Effects of the calcimimetic cinacalcet HCl on cardiovascular disease, fracture, and health-related quality of life in secondary hyperparathyroidism. *Kidney Int*. 2005;68:1793-800.
149. Raggi P, Chertow GM, Torres PU, et al; on behalf of the ADVANCE Study Group. The ADVANCE study: a randomized study to evaluate the effects of cinacalcet plus low-dose vitamin D on vascular calcification in patients on hemodialysis. *Nephrol Dial Transplant*. 2011;26:1327-1339.
150. Clinicaltrials.gov [homepage on the internet]. Evaluation Of Cinacalcet HCl Therapy to Lower CardioVascular Events. Available from: <http://clinicaltrials.gov/ct2/show/NCT00345839>
151. Price PA, Faus SA, Williamson MK. Bisphosphonates alendronate and ibandronate inhibit artery calcification at doses comparable to those that inhibit bone resorption. *Arterioscler Thromb Vasc Biol*. 2001;21:817-24.
152. Nitta K, Akiba T, Suzuki K, et al. Effects of cyclic intermittent etidronate therapy on coronary artery calcification in patients receiving long-term hemodialysis. *Am J Kidney Dis*. 2004;44:680-8.
153. Toussaint ND, Elder GJ, Kerr PG. Bisphosphonates in chronic kidney disease; balancing potential benefits and adverse effects on bone and soft tissue. *Clin J Am Soc Nephrol*. 2009;4:221-33.
154. Westenfeld R, Ketteler M, Brandenburg VM. Anti-RANKL therapy-implications for the bone-vascular-axis in CKD? Denosumab in post-menopausal women with low bone mineral density. *Nephrol Dial Transplant*. 2006;21:2075-7.

Correspondence:

Shahrazad Ossareh, MD
Hasheminejad Kidney Center, Vanak Sq, 19696 Tehran, Iran
Tel: +98 21 8864 4420
Fax: +98 21 8864 4441
E-mail: ossareh_s@hotmail.com

Received June 2011

Archive of SID