

Doppler Ultrasonography as a Predictive Tool for Permanent Kidney Damage Following Acute Pyelonephritis Comparison With Dimercaptosuccinic Acid Scintigraphy

Hamid Mohammadjafari,¹ Abdolrasoul Aalae,²
Ebrahim Salehifar,³ Abdolrahma Shiri,¹ Mohammad Khademloo,⁴
Soheila Shahmohammadi⁵

¹Division of Pediatric Nephrology, Department of Nephrology, Faculty of Medicine and Thalassemia Research Center, Mazandaran University of Medical Sciences, Sari, Iran

²Department of Radiology, Faculty of Medicine, Mazandaran University of Medical Sciences, Sari, Iran

³Department of Clinical Pharmacy, Faculty of Pharmacy, Mazandaran University of Medical Sciences, Sari, Iran

⁴Department of Community Medicine, Faculty of Medicine, Mazandaran University of Medical Sciences, Sari, Iran

⁵Clinical Research Development Center, Bouali Sina Hospital, Mazandaran University of Medical Sciences, Sari, Iran

Keywords. pyelonephritis, technetium Tc 99m dimercaptosuccinic acid, radionuclide imaging, Doppler ultrasonography, child

Introduction. The aim of this study was to investigate power Doppler ultrasonography for diagnosis and prediction of scarring compared with technetium Tc 99m dimercaptosuccinic acid scintigraphy in acute pyelonephritis.

Materials and Methods. Sixty-six children, aged 2 months to 6 years old, admitted with clinical and biological signs of their first febrile urinary tract infection were studied. All of the children underwent PDU and technetium Tc 99m dimercaptosuccinic acid scintigraphy within 7 days after diagnosis and repeat scintigraphy at least 6 months later, if results of the first study were abnormal. Scintigraphic and Doppler studies were interpreted and compared.

Results. Dimercaptosuccinic acid scintigraphy demonstrated scar in 7.6% of renal units, 3.1% of patients without reflux and 66.7% of those with high-grade reflux. Kidneys with permanent kidney damage had a mean resistive index (RI) of 0.71 ± 0.06 , while the RI value for nonscarred kidneys was 0.66 ± 0.06 ($P = .02$). The best cutoff point of RI value was 0.715, with a sensitivity of 70%, a specificity of 87.7%, and positive and negative predictive values of 32% and 97%, respectively. These values significantly increased when grey-scale ultrasonography findings were brought into account. Reflux was observed in 19.7% of renal units, which were associated with significantly higher RI values ($P = .05$).

Conclusions. Power Doppler ultrasonography with a cutoff value of 0.715 has a reasonable sensitivity and specificity for prediction of renal scarring in young children with febrile urinary tract infection.

IJKD 2011;5:386-91
www.ijkd.org

INTRODUCTION

Acute pyelonephritis is a common infectious disease during childhood.¹ It may result in irreversible renal scarring, which itself can lead to long-term complications (end-stage renal disease, hypertension, and gestational nephropathy). A significant proportion of children (10% to 30%) with acute pyelonephritis develop renal scarring.²

Radionuclide scintigraphy with technetium Tc 99m dimercaptosuccinic acid (^{99m}Tc-DMSA) is the popular method for detection of renal scars in these patients. In addition, inflammatory and urinary markers such as N-acetylglucosaminidase and tumor necrosis factor- α have been shown to have diagnostic value for acute pyelonephritis.^{3,4} Although DMSA scintigraphy can detect acute

inflammation during acute pyelonephritis, it is expensive and is associated with a high degree of radiation exposure to patients. Currently, it is not a standard practice for diagnosis of scarring during acute urinary tract infection (UTI).⁵⁻⁷ Assessment of renal scar is applied 6 months after the diagnosis of UTI. However, these acute changes mainly repair, and the DMSA scintigraphy would need to be repeated several months later to document permanent scarring. Consequently, several radionuclide scintigraphies result in high radiation exposure to patients.^{8,9} Therefore, an alternative strategy to minimize the use of DMSA scintigraphy would be reasonable and safe.

Color Doppler and power Doppler ultrasonography (PDU) have been used for detection of gray-scale abnormalities and focal hypovascular areas in acute pyelonephritis, and it may be useful for predicting renal scarring.¹⁰⁻¹³ There are few studies demonstrating the importance of PDU in predicting these permanent changes as compared to DMSA scan results. This study was designed to assess the diagnostic accuracy of PDU for detection of permanent kidney damage following acute pyelonephritis, by validating it against DMSA scintigraphy as the standard method.

MATERIALS AND METHODS

Sixty-six children (16 boys and 50 girls) with a mean age of 28.3 ± 25.8 months (range, 2 months to 6 years) referred to the pediatric nephrology clinic of Mazandaran University of Medical Sciences were prospectively entered in the study from September 2007 to July 2009. This study was approved by the ethic committee of vice chancellor of Mazandaran University of Medical Sciences and parents of all participants completed written consent forms. All admitted patients had the clinical symptoms and laboratory findings consistent with upper UTI (body temperature, $> 38^{\circ}\text{C}$; C-reactive protein, > 20 mg/L; and urine leukocyte count, > 5 per high-power field) and a positive urine microbial culture. Positive bacterial cultures were considered as bacterial counts greater than 100 000 colony forming units per milliliter in a midstream urine sample, more than 10 000 colony forming units per milliliter in urethral catheterized specimen, or any growth of microorganism in a suprapubic sample. Children who had kidney disease, recurrent UTI, and systemic disorders were excluded from the study.

Both ultrasonography (with PDU) and $^{99\text{m}}\text{Tc}$ -DMSA scintigraphy were performed within 7 days of the admission of each patient. Standard gray-scale ultrasonography was performed with the anterior and posterior views of each kidney in longitudinal and axial plans. A linear 5- to 10-MHz transducer and convex 5-MHz transducers were used for children younger than 3 months and over 3 months of age, respectively. Power Doppler ultrasonography was performed in the supine and prone positions of the patients. The scanner was a Siemens G-50 with a 2- to 5-MHz curved-array transducer (Siemens, Erlangen, Germany). At least 3 tracings from 2 different interlobar branches were obtained for each kidney. In spectral analysis, only resistive index (RI) was evaluated and the average RI was calculated for each kidney. Voiding cystourethrography (VCUG) was used with traditional radiography and contrast material for boys the first time. Nuclear VCUG (direct radionucleocystography) was performed for all of the patients on follow-up. Two qualified radiologists performed the ultrasonography and cystography procedures. The radiologists were blinded to the laboratory and clinical data of the patients.

Technetium Tc 99m dimercaptosuccinic acid scintigraphy was performed using a tomographic gamma camera (Siemens DH E-CAM, Siemens, Erlangen, Germany) with a low-energy high-resolution collimator. The anterior, posterior, and both posterior oblique images were acquired. The presence of renal lesions was determined and their severity was ranked according to the extent seen on 2 different views. Renal scarring was defined as segmental defects of uptake with indentation of the renal contour, or global scarring in case of reduced uptake with diminution of kidney size. If the first scintigraphy was indicative of abnormality, the study was repeated at least 6 months after the initial evaluation. Technetium Tc 99m dimercaptosuccinic acid scintigraphy is considered as a gold standard measure to identify permanent kidney damage.

Statistical analyses were carried out with the SPSS software (Statistical Package for the Social Sciences, version 12.0, SPSS Inc, Chicago, Ill, USA). Descriptive statistics for continuous variables were expressed as mean \pm standard deviation. Differences between mean values were evaluated

by Student *t* test and nonparametric tests, where appropriated. The diagnostic value (sensitivity, specificity, and predictive values) of PDU was assessed by receiver operating characteristic curve for each cutoff value. A *P* value less than .05 was considered significant.

RESULTS

A total of 66 patients (132 renal units) were enrolled in the study and underwent PDU and late DMSA imaging. The mean RI value was 0.668 ± 0.060 (range, 0.46 to 0.82). No significant difference was observed in RI values between the boys and the girls or between age groups (younger than 24 months versus 24 months and older; Table 1). Ultrasonographic findings were hydronephrosis in 12 patients (18.2%), altered echogenicity in 1 (1.5%), and increased size of the kidney in 1 (1.5%).

Renal DMSA scintigraphy exhibited scarring in 10 of 132 renal units (7.6%); 3.1% of the patients without vesicoureteral reflux (VUR) and 66.7% of those with high-grade VUR had scar on DMSA scans. Results obtained from VCUG are showed in Table 2. A total of 19.7% of the renal units had VUR.

Table 1. Resistive Indexes in Subgroups of Pediatric Patients Based on Gender, Age, and Imaging Studies

Patients Subgroups	Number (%) [*]	Resistive index	<i>P</i>
Gender			
Male	16 (24)	0.677 ± 0.060	.49
Female	50 (76)	0.665 ± 0.060	
Age			
< 24 mo	39 (59)	0.672 ± 0.063	.51
24 to 72 mo	27 (41)	0.662 ± 0.056	
Vesicoureteral reflux			
Yes	24 (20)	0.686 ± 0.080	.05
No	98 (80)	0.664 ± 0.056	
Renal scar			
Yes	10 (8)	0.710 ± 0.060	.02
No	122 (92)	0.664 ± 0.060	
All patients	132 (100)	0.668 ± 0.060	...

*Numbers are representative of patients for age and gender, and renal units for others.

Table 2. Relationship Between Vesicoureteral Reflux and Scar on Dimercaptosuccinic Acid Scintigraphy*

Vesicoureteral Reflux	Dimercaptosuccinic Acid Scintigraphy	
	Renal Units Without Scar (%)	Renal Units With Scar (%)
No	95 (96.9)	3 (3.1)
Grades 1 to 3	14 (93.3)	1 (6.7)
Grades 4 to 5	3 (33.3)	6 (66.7)

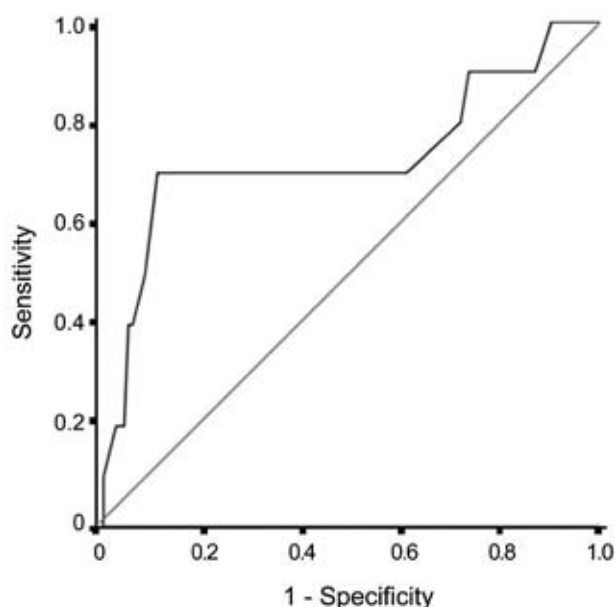
*Chi-square *P* < .001

There was a significant difference between the RI values obtained from the refluxing and nonrefluxing renal units (*P* = .05). No significant relationship was observed between the RI values and the severity of VUR. However, a positive relationship between presence of VUR and development of scarring was seen. The correlation between RI values and the presence of renal lesions on the 2nd DMSA scintigraphy is shown in Table 3. The mean RI value was 0.664 ± 0.060 in the kidneys with no lesions and 0.710 ± 0.060 in patients with renal lesions.

A total of 132 kidneys were assessed in this study. The receiver operating characteristic curve analysis in 10 units with renal involvement and 122 units without renal scarring revealed that a discriminatory RI of 0.715 was optimal for detecting renal scarring (Figure and Table 3). The sensitivity and specificity for this cutoff point were 70.0% and 87.7%, respectively. The positive predictive value (PPV) and negative predictive value (NPV) were 31.8% and 97.3%, respectively (Table 4). The cutoff

Table 3. Dimercaptosuccinic Acid Scintigraphy Results by Resistive Index Cutoff Point of 0.715

Resistive Index	Dimercaptosuccinic Acid Scintigraphy		All
	Renal Units Without Scar (%)	Renal Units With Scar (%)	
< 0.715	107 (97.3)	3 (2.7)	110
> 0.715	15 (68.2)	7 (31.8)	22



Receiver operating characteristics curve of 132 kidneys with and without renal involvement. The area under the curve was 0.724, and confidence interval was between 0.520 and 0.928.

Table 4. Relationship Between a Combination of Grey-scale and Doppler Ultrasonography Findings and Scar on Dimercaptosuccinic Acid Scintigraphy*

Gray-scale and Doppler	Dimercaptosuccinic Acid Scintigraphy		All
	Renal Units Without Scar (%)	Renal Units With Scar (%)	
Both normal	98 (99)	1 (1)	99
One abnormal	24 (80)	6 (20)	30
Both abnormal†	0	3 (100)	3

*Chi-square $P < .001$

†Sensitivity, specificity, and negative and positive predictive values were 30%, 100%, 95%, and 100%, respectively.

value with the highest sensitivity was 0.585 (a sensitivity of 100%) and the value with the highest specificity was 0.775 (a specificity of 98.4%). Based on the cutoff point of 0.715, the DMSA results and RI values are shown in Table 3. Among 10 kidney-scarred units, 7 could be predicted with considering the RI value of 0.715 (a sensitivity of 70.0%).

In order to increasing accuracy of Doppler study for prediction of permanent kidney damage, we considered gray-scale and Doppler ultrasound findings simultaneously. Among 99 patients who had both normal findings, only 1 had scar on DMSA. Permanent kidney damage was observed in all the 3 children who had both abnormal gray-scale and Doppler imaging (Table 4).

DISCUSSION

Urinary tract infection is one of the most common bacterial infections in children and occurs in as many as 5% and 0.5% of girls and boys, respectively.^{14,15} Renal ^{99m}Tc-DMSA scintigraphy has been considered the main diagnostic procedure for detecting renal scars in children, which is widely used in clinical practice.^{16,17} Interpretation of this radionuclide imaging is usually only qualitative and needs at least 6 months time to detect permanent kidney damage.^{18,19} An early and reliable diagnostic tool for prediction of kidney damage would be useful for children with UTI who require intravenous antibiotics. Recently, PDU has been used for renal vascular visualization, with promising results for diagnosis of acute pyelonephritis and predicting renal scar.^{20,21} In this study, we compared the diagnostic results of PDU and DMSA for predicting renal scarring following an episode of acute pyelonephritis. The RI value was 0.668 ± 0.060 , and a cutoff value of 0.715 led to reasonable sensitivity

(70%) and specificity (87.7%) for prediction of renal scarring. Although RI values below 0.7 can be used as an indicator of normal renal vasculature resistance in adults, this value is not applicable in children. The mean RI values of 0.65 and 0.64 were suggested by previous studies.^{22,23} Interestingly, Kuzmic and coworkers showed that healthy children aged younger than 6 years and 6 to 16 years had RI values of 0.705 ± 0.018 and 0.605 ± 0.029 , respectively.¹²

In our study, 7.6% of the renal units had scar in late DMSA scintigraphy. This rate can be compared with a rate of 13% reported by Narchi and Donovan.⁶ Hitzel and colleagues reported that scarring had developed in 51% of children diagnosed with and treated for pyelonephritis, although they mentioned that the range of scarring was overestimated because of the relatively short follow-up.²⁴

According to our study, PDU had apparently reasonable capability to predict which children with UTI would have renal involvement and could progress to permanent kidney damage. Power Doppler ultrasonography missed only 3 patients with mild (grade 1) scarring kidneys. Our findings are in agreement with the results of Basiratnia and coworkers, who obtained the sensitivity and specificity of 66% and 81%, respectively.²⁵ An NPV of 75% and a PPV of 57% were reported by Hitzel and colleagues.²⁴ Similar results were reported by Aalaei and associates.²⁶ In another study, Narchi and Donovan investigated on children under 4 years of age with a 1st febrile episode of UTI and showed that PDU had sensitivity and specificity of 33.3% and 97.7%, respectively, with a PPV of 50% and a NPV of 95.4%.⁶ Comparing the findings of our study with the four aforementioned studies reveals that the PPV was lower in our study, demonstrating higher capability of PDU to predict developing scar rather than ruling it out.

We measured RI of renal vasculature. There was a significant positive relationship between RI and presence and severity of permanent kidney damage. In our findings, an RI of 0.715 was the best value for predicting renal scarring, with sensitivity and specificity of 70% and 87.7%, respectively; however, an optimal cutoff value of 0.71 was suggested for diagnosing renal scarring.^{24,25} Akdilli and colleagues evaluated the changes of intrarenal color Doppler ultrasonography in lower UTI. The mean RI was

0.75 ± 0.07 in patients with UTI and 0.71 ± 0.1 in the healthy control group.²⁰ For methodological reasons, we did not compare RI values in infected with normal children. Interestingly, our results were very similar to a study performed in 2004 in Turkey. Ozelik and coworkers, in a prospective study, found that the discriminatory RI value of 0.715 was optimal for detecting renal scarring.²⁷

In our study, when both gray-scale and Doppler ultrasonography findings were combined, specificity and PPV were increased significantly. Narchi and Donovan believed that PDU was less specific than gray-scale ultrasonography (97.7% versus 100%) for predicting absence of scarring, and the detection rate did not improve by combining PDU with ultrasonography.⁶ This study had such limitations including small sample size and lower age of patients (< 4 years). However, Brader and associates reported that sensitivity for detecting renal involvement increased from 84.1% with PDU only and 85.7% with gray-scale ultrasonography to 92.1% in the combined approach.¹³

There was a positive relation between presence of VUR and development of scarring in our group of patients, although there was not such a relation according to severity of VUR. Hitzel and colleagues reported that the development of scarring following acute pyelonephritis is independent of the presence or absence of reflux.¹⁰

In our study, 70% of the renal units with scar had VUR. It is suggested that the RI values may be increased with VUR in children.²⁸ Radmayr and colleagues demonstrated the mean RI value of 0.77 in children with VUR grades 4 to 5 and this value was less than 0.7 in children who had VUR grades 1 to 3.²⁹ Ozelik and colleagues reported that the RI value was not influenced by the grade of VUR.²⁷ In this study, refluxing renal units had significantly higher RI value compared to nonrefluxing units, but the difference was not significant according to the severity of VUR (0.69 ± 0.06 for grades 4 to 5 and 0.68 ± 0.10 for grades 1 to 3).

We prepared the RI value with highest sensitivity and specificity. We found those children with RI value of lower than 0.585 never had renal scarring in late DMSA (sensitivity of 100%). It means that children with this low RI do not need any aggressive investigation and therapy, while most of children with RI values greater than 0.775 would have scar in their kidneys (specificity, 98.4%).

CONCLUSIONS

Data of this study indicated that there was a highly significant relationship between RI values and the severity of renal involvement. In addition, our results demonstrated that children with higher RI values were at increased risk of having reflux, scarring, or both.

CONFLICT OF INTEREST

None declared.

REFERENCES

- Mohkam M, Karimi A, Habibian S, Sharifian M. Urinary N-acetyl-beta-D-glucosaminidase as a diagnostic marker of acute pyelonephritis in children. *Iran J Kidney Dis.* 2008;2:24-8.
- Smellie JM, Barratt TM, Chantler C, et al. Medical versus surgical treatment in children with severe bilateral vesicoureteric reflux and bilateral nephropathy: a randomised trial. *Lancet.* 2001;357:1329-33.
- Mohkam M, Asgarian F, Fahimzad A, Sharifian M, Dalirani R, Abdollah Gorgi F. Diagnostic potential of urinary tumor necrosis factor-alpha in children with acute pyelonephritis. *Iran J Kidney Dis.* 2009;3:89-92.
- Mohkam M, Maham S, Rahmani A, et al. Technetium Tc 99m dimercaptosuccinic acid renal scintigraphy in children with acute pyelonephritis: correlation with other imaging tests. *Iran J Kidney Dis.* 2010;4:297-301.
- Rushton HG, Majd M, Chandra R, Yim D. Evaluation of 99mtechnetium-dimercapto-succinic acid renal scans in experimental acute pyelonephritis in piglets. *J Urol.* 1988;140:1169-74.
- Narchi H, Donovan R. Renal power Doppler ultrasound does not predict renal scarring after urinary tract infection. *Scott Med J.* 2008;53:7-10.
- Verboven M, Ingels M, Delree M, Piepsz A. 99mTc-DMSA scintigraphy in acute urinary tract infection in children. *Pediatr Radiol.* 1990;20:540-2.
- Majd M, Rushton HG. Renal cortical scintigraphy in the diagnosis of acute pyelonephritis. *Semin Nucl Med.* 1992;22:98-111.
- Jakobsson B, Svensson L. Transient pyelonephritic changes on 99mTechnetium-dimercaptosuccinic acid scan for at least five months after infection. *Acta Paediatr.* 1997;86:803-7.
- Hitzel A, Liard A, Vera P, Manrique A, Menard JF, Dacher JN. Color and power Doppler sonography versus DMSA scintigraphy in acute pyelonephritis and in prediction of renal scarring. *J Nucl Med.* 2002;43:27-32.
- Frauscher F, Radmayr C, Klauser A, et al. [Assessment of renal resistance index in children with vesico-ureteral reflux]. *Ultraschall Med.* 1999;20:93-7. German.
- Kuzmic AC, Brkljacic B, Ivankovic D, Galesic K. Doppler sonographic renal resistance index in healthy children. *Eur Radiol.* 2000;10:1644-8.
- Brader P, Riccabona M, Schwarz T, Seebacher U, Ring E. Value of comprehensive renal ultrasound in children

- with acute urinary tract infection for assessment of renal involvement: comparison with DMSA scintigraphy and final diagnosis. *Eur Radiol.* 2008;18:2981-9.
14. Dacher JN, Hitzel A, Avni FE, Vera P. Imaging strategies in pediatric urinary tract infection. *Eur Radiol.* 2005;15:1283-8.
 15. Vachvanichsanong P. Urinary tract infection: one lingering effect of childhood kidney diseases--review of the literature. *J Nephrol.* 2007;20:21-8.
 16. Stogianni A, Nikolopoulos P, Oikonomou I, et al. Childhood acute pyelonephritis: comparison of power Doppler sonography and Tc-DMSA scintigraphy. *Pediatr Radiol.* 2007;37:685-90.
 17. Benador N, Siegrist CA, Gendrel D, et al. Procalcitonin is a marker of severity of renal lesions in pyelonephritis. *Pediatrics.* 1998;102:1422-5.
 18. Shanon A, Feldman W, McDonald P, et al. Evaluation of renal scars by technetium-labeled dimercaptosuccinic acid scan, intravenous urography, and ultrasonography: a comparative study. *J Pediatr.* 1992;120:399-403.
 19. Patel K, Charron M, Hoberman A, Brown ML, Rogers KD. Intra- and interobserver variability in interpretation of DMSA scans using a set of standardized criteria. *Pediatr Radiol.* 1993;23:506-9.
 20. Akdilli A, Karaman CZ, Basak O, Aydogdu A. The diagnostic value of intrarenal colour duplex Doppler ultrasonography in children with lower urinary tract infection. *Pediatr Radiol.* 1999;29:897-900.
 21. Clautice-Engle T, Jeffrey RB, Jr. Renal hypoperfusion: value of power Doppler imaging. *AJR Am J Roentgenol.* 1997;168:1227-31.
 22. Lin GJ, Cher TW. Renal vascular resistance in normal children--a color Doppler study. *Pediatr Nephrol.* 1997;11:182-5.
 23. Bude RO, DiPietro MA, Platt JF, Rubin JM, Miesowicz S, Lundquist C. Age dependency of the renal resistive index in healthy children. *Radiology.* 1992;184:469-73.
 24. Hitzel A, Liard A, Dacher JN, et al. Quantitative analysis of 99mTc-DMSA during acute pyelonephritis for prediction of long-term renal scarring. *J Nucl Med.* 2004;45:285-9.
 25. Basiratnia M, Noohi AH, Lotfi M, Alavi MS. Power Doppler sonographic evaluation of acute childhood pyelonephritis. *Pediatr Nephrol.* 2006;21:1854-7.
 26. Alaei A, Mohammadjafari H, Khademloo M. Comparing the accuracy of Doppler resistance index of the renal artery with DMSA scintigraphy in children with febrile UTI and prediction of VUR and acute pyelonephritis. *J Mazandaran Univ Med Sci.* 2007;61:96-104.
 27. Ozcelik G, Polat TB, Aktas S, Cetinkaya F. Resistive index in febrile urinary tract infections: predictive value of renal outcome. *Pediatr Nephrol.* 2004;19:148-52.
 28. Kawauchi A, Yamao Y, Ukimura O, Kamoi K, Soh J, Miki T. Evaluation of reflux kidney using renal resistive index. *J Urol.* 2001;165:2010-2.
 29. Radmayr C, Klauser A, Maneschg C, Bartsch G, Frauscher F. Importance of the renal resistive index in children suffering from vesicoureteral reflux. *Eur Urol.* 1999;36:75-9.

Correspondence to:

Hamid Mohammadjafari, MD
 Department of Nephrology, Bouali Sina Hospital, Pasdaran Blvd, Sari, Iran
 Tel: +98 151 223 4506
 Fax: +98 151 223 4506
 E-mail: hamidmjaafari@yahoo.com

Received January 2011

Revised June 2011

Accepted June 2011

Archive of SJD