

# Recurrence of Primary Hyperoxaluria After Kidney Transplantation

Tahereh Malakoutian,<sup>1</sup> Mojgan Asgari,<sup>2</sup> Massoud Houshmand,<sup>3,4</sup> Ronak Mohammadi,<sup>1</sup> Omid Aryani,<sup>4</sup> Esmaeel Mohammadi Pargoo,<sup>4</sup> Ahad J Ghods<sup>1</sup>

<sup>1</sup>Division of Nephrology, Department of Internal Medicine, Hasheminejad Kidney Center, Iran University of Medical Sciences, Tehran, Iran

<sup>2</sup>Department of Pathology, Hasheminejad Kidney Center, Iran University of Medical Sciences, Tehran, Iran

<sup>3</sup>National Institute for Genetic Engineering and Biotechnology, Tehran, Iran

<sup>4</sup>Genetic Diagnostic Laboratory, Special Medical Center, Tehran, Iran

**Keywords.** primary hyperoxaluria, chronic kidney failure, nephrocalcinosis, kidney transplantation

Primary hyperoxaluria is a genetic disorder in glyoxylate metabolism that leads to systemic overproduction of oxalate. Functional deficiency of alanine-glyoxylate aminotransferase in this disease leads to recurrent nephrolithiasis, nephrocalcinosis, systemic oxalosis, and kidney failure. We present a young woman with end-stage renal disease who received a kidney allograft and experienced early graft failure presumed to be an acute rejection. There was no improvement in kidney function, and she was required hemodialysis. Ultimately, biopsy revealed birefringent calcium oxalate crystals, which raised suspicion of primary hyperoxaluria. Further evaluations including genetic study and metabolic assay confirmed the diagnosis of primary hyperoxaluria type 1. This suggests a screening method for ruling out primary hyperoxaluria in suspected cases, especially before planning for kidney transplantation in patients with end-stage renal disease who have nephrocalcinosis, calcium oxalate calculi, or a family history of primary hyperoxaluria.

IJKD 2011;5:429-33  
www.ijkd.org

## INTRODUCTION

Primary hyperoxaluria type 1 (PH1) is a rare metabolic disorder with autosomal recessive inheritance. Primary hyperoxaluria type 1 was first described in the literature by the French physician, Lepoutre, in 1925. However, significant research on the disease did not begin until 1950, and the molecular genetic basis was not determined until the cloning of the gene encoding alanine-glyoxylate aminotransferase (AGT) in 1990 by Danpure and colleagues.<sup>1</sup> Primary hyperoxaluria type 1 is characterized by a deficiency of hepatic enzyme AGT that leads to enhanced conversion of glyoxylate to poorly soluble oxalate, which results in nephrolithiasis and kidney failure. Combined liver-kidney transplantation is the treatment of choice. Kidney transplantation alone in PH1 has been disappointing, as renal oxalosis leads to loss

of the allograft in many patients.<sup>2-4</sup>

We present a 22-year-old woman with fever, leukopenia, and thrombocytopenia who underwent kidney transplantation. Impairment of kidney function occurred 3 months after transplantation. Kidney allograft biopsy showed tubule-interstitial nephritis in the background of oxalate crystal nephropathy. Further evaluation revealed PH1 and the genetic study confirmed that.

## CASE REPORT

The patient was a 22-year-old woman with kidney failure who underwent kidney transplantation from a living unrelated donor about 3 months before admission to our hospital. The initial kidney function was excellent and serum creatinine was 0.9 mg/dL at the 12th postoperative day without any peri-operative complications. Mycophenolate

mofetil, cyclosporine, and prednisolone were started on as immunosuppressive therapy. After 2 months of transplantation, she presented with fever, malaise, vomiting, and a high serum creatinine level, and was treated by methylprednisolone due to suspicion of acute rejection of the transplanted kidney in another center. After a few days she was referred to our hospital.

She had fever and chills combined with pulmonary distress. In her past medical history, she had been under hemodialysis 3 times per week for 2 years, until she received a kidney transplant. She had the experience of two nephrolithiasis episodes 3 years earlier. Review of her past ultrasonography images of kidneys revealed end-stage renal disease was in the setting of multiple kidney calculi. There were no history of chronic diarrhea. Blood tests revealed a hemoglobin of 9 g/dL, low leukocyte and platelet counts, blood urea nitrogen of 108 mg/dL, and serum creatinine of 6 mg/dL. Serum uric acid, calcium, phosphate, and alkaline phosphatase levels were within the normal range. Serum electrolytes levels and liver function tests were also normal. Urinalysis revealed abundant erythrocytes in urine. Her chest radiography showed patchy infiltration in the lower lobe of the right lung.

Abdominal and pelvic ultrasonography showed bilateral small-sized native kidneys with multiple kidney calculi in both of them. The transplanted kidney was reported normal. Color Doppler ultrasonography of transplanted kidney showed normal-sized kidney with a resistive index of 0.61. Abdominopelvic computed tomography (CT) showed swelling of transplanted kidney with multiple echogenic shadow in both native kidneys suggestive of calculus, which raised the suspicion of metabolic cause for recurrent nephrolithiasis.

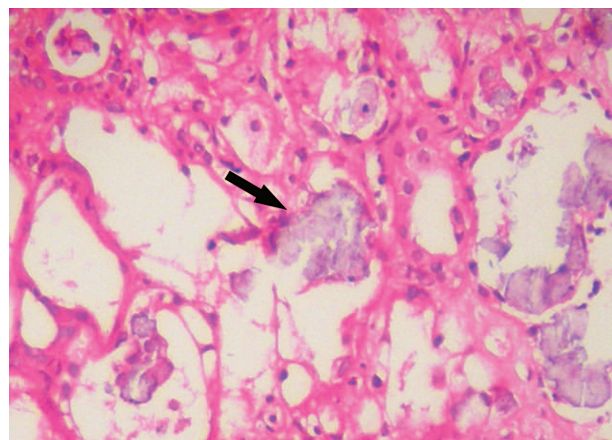
After complete sepsis workup, broad-spectrum antibiotics were started and mycophenolate mofetil and cyclosporine were discontinued. The patient developed dyspnea and nonproductive cough. The symptoms were becoming worse despite a full dose of broad-spectrum antibiotics administration. Chest spiral CT showed multiple nodules in both lungs, which were more than 1 cm in diameter. There were 2 peripheral thick-walled cavities in the left lung. Consolidation with air bronchography in the lower lobe of the right lung was present, too, suggestive of pneumonia. As cavities were peripheral, the CT-guided biopsy was planned

for her, but she developed pneumothorax during the procedure. Biopsy was terminated and chest tube was inserted.

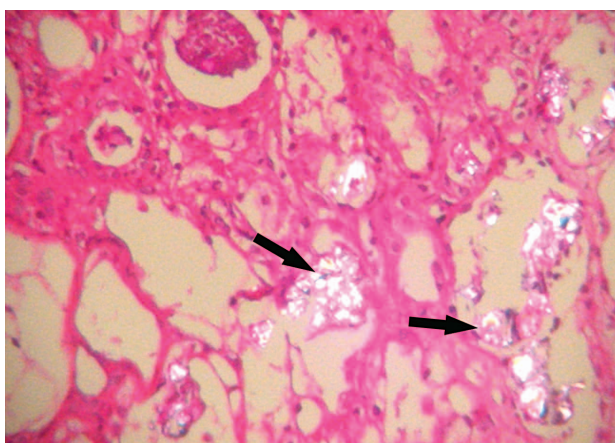
The pattern of the lesion of the lung in the setting of immunodeficiency raised the suspicion of fungal infection; thus, antifungal therapy was started on for her. When the clinical condition of the patient improved, CT-guided biopsy of the lung was performed. The culture of the lung lesion biopsy showed *Candida albicans*, and the symptom of dyspnea and cough subsided by continuing antifungal therapy for the patient. The patient then underwent hemodialysis via a jugular vein catheter due to progressive impaired kidney function and uremic symptoms despite conservative management.

Percutaneous kidney allograft biopsy was performed. There was no evidence of acute cell-mediated or antibody-mediated rejection in light microscopy. There were large refractile acellular deposits in several of the tubular lumens resembling oxalate crystals making tubular destruction and injury (Figure 1). They were double refractile under the polarized lens (Figure 2). Mild tubular atrophy and interstitial fibrosis were also seen. There was no evidence of viral cytopathic epithelial change. The final Diagnosis was oxalate crystal nephropathy.

Metabolic and genetic studies confirmed the diagnosis of primary hyperoxaluria. Urine organic compound study estimated high amounts of glycolic acid (305.01 mM/M creatinine with normal range of less than 50 mM/M), indicating hyperoxaluria type 1. Genetic study revealed mutation at exon



**Figure 1.** Renal biopsy specimen shows large refractile acellular deposits (arrow) in tubular lumens (hematoxylin-eosin,  $\times 40$ ).



**Figure 2.** There are double refractile crystals (arrows) under polarized lens (hematoxylin-eosin, × 40).

5, leading to substitution of thymidine in place of guanine at nucleotide 584 (c584T>G). The mutation has already been described as pathogenic relevant. By these studies the diagnosis of PH1 was confirmed. The patient was discharged on maintenance hemodialysis.

## DISCUSSION

Hyperoxaluria is a rare genetic metabolic disorder with hazardous outcomes.<sup>1,5-7</sup> In PH1, the missing enzyme is AGT that is normally found only in the hepatic peroxisomes. This enzyme is necessary to detoxify glyoxylate. When AGT is lacking, the peroxisomal glyoxylate is converted to oxalate. Because of the poor solubility of calcium oxalate, excess oxalate has potentially lethal consequences if crystallization occurs in sensitive organs such as the kidneys. The genetic basis of PH1 is mutations in the *AGTX* gene, which contains 11 exons spanning 10 kb on chromosome 2q37.3.

Overall, PH1 is responsible for approximately 1% of cases of end-stage renal disease in children, developing in approximately one-half of patients by the age of 15 years.<sup>2</sup> Because of the rarity of this disorder, the diagnosis is often missed or delayed by several years, especially when the disease first manifests in adulthood. The high urinary glycolate in combination with hyperoxaluria is a key biochemical marker for the disease. Diagnosis of PH should be considered in a patient with recurrent calcium calculi, nephrocalcinosis, normal urinary calcium and uric acid excretion, calcium oxalate crystals in the urine sediment, pure calcium oxalate monohydrate calculi, and marked hyperoxaluria

in the absence of gastrointestinal disease or the ingestion of megadose vitamin C.

In general, hyperoxaluria together with increased urinary excretion of glycolate or L-glyceric acid is strongly suggestive, but not absolutely diagnostic, of PH1.<sup>8</sup> In patients who have some degrees of renal insufficiency, hyperoxaluria has been reported due to oxalate retention. In these patients, serum and urine oxalate level is not helpful, and we need liver biopsy or genetic study to confirm the diagnosis. Thus, a liver biopsy may be diagnostically helpful when urinary glycolate excretion is normal, the patient is anuric, and hepatic transplantation is being considered. A liver biopsy is particularly necessary for a definite diagnosis prior to hepatic transplantation, except in patients with a known genotype or with a sibling with a definite diagnosis.

An analysis of AGT activity in liver tissue of 59 patients with PH1 showed considerable heterogeneity at the enzymatic level.<sup>9</sup> The activity of AGT was nil in more than 60% of patients, whereas other patients had AGT activities from 3% to 48%. There was no relationship between enzyme activity level and severity of PH1. The disease is clinically and genetically classified as highly heterogeneous. The presence of allelic heterogeneity of *AGTX* could be responsible to some extent for the phenotypic heterogeneity in PH1.<sup>9</sup> However, DNA analysis can be useful as a noninvasive method, especially in children or prenatal diagnosis or if a specific known genetic mutation is a strong possibility. Although over 50 disease-causing mutations have been identified, the relationship between genotype and clinical outcome remains unclear. In one study, for example, genetic analysis revealed that homozygosity for a specific mutation was associated with kidney failure, while homozygosity for other abnormalities was associated with pyridoxine responsiveness.<sup>10</sup>

There are 4 common *AGXT* mutations in PH1 patients (c33\_34insC, c508G>A, c73IT>C, and 454 T> A) that together account for greater than 50% of the reported PH mutation in the literature.<sup>1,2,11</sup> The most common mutation in PH1, a 508G>A point mutation that results in a Gly170Arg amino acid substitution, has no functional effect per se on the AGT enzyme. The mutation is only significant in the context of a specific allelic variant (polymorphism) of the *AGXT* gene (the so-called minor allele), which is present in approximately

20% of the normal population. The minor allele in the absence of other mutations has normal AGT activity.<sup>1,5</sup> Therefore, the G630A mutation in the context of the minor allele results in mistargeting of AGT to the mitochondria and leads to primary hyperoxaluria. Genetic analysis of 55 unrelated probands with PH1 from the Mayo Clinic Hyperoxaluria Center with complete sequencing across the entire *AGXT* coding region and documented hepatic AGT deficiency, suggests that a molecular diagnosis is feasible in 96% of patients. In this study, G170R (the most common *AGXT* mutation) had the highest frequency.<sup>12</sup>

Prenatal diagnosis can be performed by mutational analysis using chorionic villous (9 to 12 weeks of gestation) or amniocentesis (16 weeks of gestation).<sup>1,2</sup> For our case, diagnosis of PH1 was suspected first by metabolic urine screening test and then confirmed by molecular study of the DNA genome. The urine study showed the high amount of glycolic acid that indicates PH1. Glyceric acid was normal in the sample. Quantified target panel of the concentration of glycolic acid was 305.01 mM/M creatinine. Genomic DNA was extracted from peripheral blood of the patient by using Qiagen Extraction Kit. Polymerase chain reaction was used to amplify individual exons using primers. Studies of the *AGXT* gene showed a homozygote mutation at exon 5, leading to substitution of thymidine in place of guanine at nucleotide 584 (c584T>G). The mutation has been already described as pathogenic relevant.

To our knowledge, it seems that this is the first time that genetic assessment is performed for establishing the diagnosis of PH1 in Iran. Reviewing of this case and the similar case reports encourages us to use screening test methods for ruling out PH1 in suspected cases, especially before planning for kidney transplantation as a renal replacement therapy. Candidate patients are those who have nephrocalcinosis and /or calcium oxalate calculi or a family history of primary hyperoxaluria.

Kidney transplantation alone in PH1 has had relatively disappointing outcomes, as renal oxalosis leading to loss of the allograft occurs in many patients. Both newly produced oxalate and oxalate mobilized from tissue deposits contribute to the renal deposits.

Data from the European Dialysis and Transplant Association, for example, showed a 3-year graft

survival rate of only 23% for living related donor kidneys and 17% for cadaver kidneys in a review of 98 first transplants for oxalosis.<sup>13</sup> To date, liver-kidney transplantation is the only curative treatment for the patient with hyperoxaluria and end-stage renal disease.<sup>2,11,13,14</sup>

In conclusion, for making a correct decision for therapy we need to have a correct diagnosis. As the genetic screening strategies are currently available, it can be used as the method for screening patient with hyperoxaluria with a greater emphasis on pediatric clinic instead of invasive tests like liver biopsy.

### CONFLICT OF INTEREST

None declared.

### REFERENCES

1. Cramer SD, Tatsuya T. Primary hyperoxaluria. In: Lifton RP, Somlo S, Giebisch GH, Seldin DW, editors. Genetic Diseases of the kidney. Amsterdam: Elsevier; 2009. p. 571-87.
2. Shang MH, Jun H, Fan Y, et al. Recurrence of primary hyperoxaluria after kidney transplantation: the report of two cases. *Chin Med J (Engl)*. 2009;122:2794-7.
3. Harambat J, Fargue S, Acquaviva C, et al. Genotype-phenotype correlation in primary hyperoxaluria type 1: the p.Gly170Arg *AGXT* mutation is associated with a better outcome. *Kidney Int*. 2010;77:443-9.
4. Madiwale C, Murlidharan P, Hase NK. Recurrence of primary hyperoxaluria: an avoidable catastrophe following kidney transplant. *J Postgrad Med*. 2008;54:206-8.
5. Danpure CJ, Jennings PR. Peroxisomal alanine:glyoxylate aminotransferase deficiency in primary hyperoxaluria type I. *FEBS Lett*. 1986;201:20-4.
6. Milliner DS, Wilson DM, Smith LH. Phenotypic expression of primary hyperoxaluria: comparative features of types I and II. *Kidney Int*. 2001;59:31-6.
7. Danpure CJ, Jennings PR, Fryer P, Purdue PE, Allsop J. Primary hyperoxaluria type 1: genotypic and phenotypic heterogeneity. *J Inher Metab Dis*. 1994;17:487-99.
8. Cochat P, Basmaison O. Current approaches to the management of primary hyperoxaluria. *Arch Dis Child*. 2000;82:470-3.
9. Danpure CJ. Molecular and clinical heterogeneity in primary hyperoxaluria type 1. *Am J Kidney Dis*. 1991;17:366-9.
10. van Woerden CS, Groothoff JW, Wijburg FA, Annink C, Wanders RJ, Waterham HR. Clinical implications of mutation analysis in primary hyperoxaluria type 1. *Kidney Int*. 2004;66:746-52.
11. Millan MT, Berquist WE, So SK, et al. One hundred percent patient and kidney allograft survival with simultaneous liver and kidney transplantation in infants with primary hyperoxaluria: a single-center experience. *Transplantation*. 2003;76:1458-63.

12. Monico CG, Rossetti S, Schwanz HA, et al. Comprehensive mutation screening in 55 probands with type 1 primary hyperoxaluria shows feasibility of a gene-based diagnosis. *J Am Soc Nephrol.* 2007;18:1905-14.
13. Jamieson NV. A 20-year experience of combined liver/kidney transplantation for primary hyperoxaluria (PH1): the European PH1 transplant registry experience 1984-2004. *Am J Nephrol.* 2005;25:282-9.
14. Gruessner RW. Preemptive liver transplantation from a living related donor for primary hyperoxaluria type I. *N Engl J Med.* 1998;338:1924.

Correspondence to:  
Tahereh Malakoutian, MD  
Hasheminejad Kidney Center, Vanak Sq, Tehran 1969714713,  
Iran  
Fax: +98 21 8864 4441  
Tel: +98 21 8864 4407  
E-mail: malakoutian@ams.ac.ir

Received November 2010  
Revised April 2011  
Accepted May 2011

Archive of SID