

Inhibitory Effect of Olive Leaf Extract on Gentamicin-induced Nephrotoxicity in Rats

Majid Tavafi,¹ Hasan Ahmadvand,² Pooran Toolabi³

¹Razi Herbal Medicines Research Center, Lorestan University of Medical Sciences, Khoram Abad, Iran

²Department of Biochemistry, Faculty of Medicine, Lorestan University of Medical Sciences, Khoram Abad, Iran

³Department of Biology, Payam Noor University of Tehran, Tehran, Iran

Keywords. antioxidants, gentamicins, kidney diseases, olea, plant extracts, phytotherapy

Introduction. Gentamicin sulphate nephrotoxicity seems to be attributed to the generation of reactive oxygen species. Olive leaf extract (OLE) has been demonstrated to have antioxidant and anti-inflammatory effects. The aim of this study was to evaluate the inhibitory effect of OLE on gentamicin-induced nephrotoxicity in rats.

Materials and Methods. Thirty-five Sprague-dawley rats were divided into 5 groups to receive saline; gentamicin, 100 mg/kg/d; and gentamicin plus OLE in 3 different doses (25 mg/kg/d, 50 mg/kg/d, and 100 mg/kg/d, once daily for 12 days. Serum and renal malondialdehyde were assessed, and tubular necrosis was studied semiquantitatively. Glomerular volume and volume density of the proximal convoluted tubules were estimated stereologically from paraffin sections. Serum creatinine and renal antioxidant enzymes activity were measured.

Results. Gentamicin significantly increased serum creatinine, malondialdehyde, and tubular necrosis, and decreased creatinine clearance, volume density of the proximal convoluted tubules, renal glutathione, glutathione peroxidase, catalase, and superoxide dismutase compared with the control group. Cotreatment of gentamicin and OLE significantly decreased serum creatinine, malondialdehyde, tubular necrosis, and renal malondialdehyde, and increased renal glutathione, catalase, superoxide dismutase, volume density of proximal convoluted tubules, and creatinine clearance in comparison with gentamicin-only treated group. Serum malondialdehyde, serum creatinine, tubular necrosis, and volume density of proximal convoluted tubules were maintained at the same level as that of the control group by cotreatment of gentamicin and OLE.

Conclusions. Olive leaf extract ameliorates gentamicin nephrotoxicity via antioxidant activity, increase of renal glutathione content, and increase of renal antioxidant enzymes activity, except for glutathione peroxidase.

IJKD 2012;6:25-32
www.ijkd.org

INTRODUCTION

Amino nucleoside antibiotic gentamicin sulphate is commonly used for the treatment of Gram-negative bacterial infection. In many cases, it has

been the only effective therapeutic drug against bacterial strains resistant to other antibiotics, but nephrotoxicity side effects limit its use.¹ Gentamicin has been used clinically due to its wide spectrum of

activities against Gram-negative bacterial infections caused by *Pseudomonas*, *Proteus*, and *Serratia*.² On the other hand, gentamicin-induced nephrotoxicity is an animal model for study of acute kidney failure in experimental research.

The mechanisms of gentamicin-induced nephrotoxicity are not completely known. However, proposed pathological mechanisms include induction of oxidative stress, apoptosis, necrosis, elevation of endothelin I, and increase of monocyte/macrophages infiltration.³⁻⁶ Gentamicin-induced nephrotoxicity is characterized functionally by increased serum creatinine, increased blood urea nitrogen, and decreased glomerular filtration rate,^{7,8} and morphologically characterized by proximal tubule epithelial desquamation, tubular necrosis, epithelial edema, and glomerular hypertrophy.^{5,9,10} Gentamicin increases generation of reactive oxygen species (ROS) such as super oxide anions,¹¹⁻¹⁴ hydroxyl radicals, hydrogen peroxide, and reactive nitrogen species in the kidney.^{2,15} gentamicin-induced kidney damage is linked with lipid peroxidation^{16,17} and protein oxidation in the renal cortex.¹⁸ Gentamicin reduces activity of renal antioxidant enzymes like superoxide dismutase (SOD), catalase, glutathione peroxidase (GP), and glutathione.^{6,12,14,19,20}

Most research studies against gentamicin-induced nephrotoxicity are focused on the use of various anti-oxidants.²¹ Olive leaves are rich in biophenols such as oleuropein, verbascoside, ligstroside, tyrosol, and hydroxytyrosol. These compounds have shown biological activities such as anti-oxidation.²²⁻²⁵ In this study, we aimed to evaluate olive leaf extract (OLE) as an inhibitory agent against gentamicin-induced nephrotoxicity because of its antioxidant property. No detailed study has been carried out on the efficacy of OLE in the modulation of oxidative stress associated with gentamicin-induced nephrotoxicity in experimental animals.

MATERIALS AND METHODS

Preparation of Ethanolic Olive Leaf Extract

The olive leaves (*Olea europaea*, variety of *Sevillano*) were collected from Khoram Abad, in Lorestan Province, Iran, in August 2009. A sample was deposited at the herbarium of Lorestan Agricultural and Natural Resources Research Center with the reference number 11505. Two hundred grams of the air-dried leaves was grinded into fine

powder. The powder was extracted twice, on each occasion with 1 L of 80% ethanol. The collective ethanol extract was filtered, and the filtrate was concentrated to dryness under reduced pressure in a rotary evaporator, and the resulting ethanol extract was freeze-dried. High-performance liquid chromatography of the extract by our colleagues showed that oleuropein (356 mg/g), tyrosol (3.73), hydroxytyrosol (4.89), and caffeic acid (49.41) were the main components of the OLE.²⁶

Experimental Design

Thirty-five male Sprague-dawley rats (180 g to 200 g) were prepared from Pasteur Institute of Tehran, and they were allowed to adapt themselves with the new location for 1 week. They were kept at a room temperature of 22°C and a humidity of 50 ± 10% with 12-hour light/dark cycles. This study was approved by the Animal Ethics Committee of Lorestan University of Medical Sciences and was in accordance with the National Health and Medical Research Council guidelines.

The animals were divided into 5 equal groups randomly including 7 rats each as follows: group 1 (control group), intraperitoneal saline injection, 0.5 mL/d; group 2, gentamicin injection; group 3, gentamicin and OLE, 25 mg/kg/d; group 4, gentamicin and OLE, 50 mg/kg/d; and group 5, gentamicin and OLE, 100 mg/kg/d. Gentamicin, 100 mg/kg/d, was injected intraperitoneally²⁷ for 12 days and OLE was administrated orally by gavage every day, 1 hour before gentamicin injection. After the last injection of gentamicin, all the animals were immediately kept in individual metabolic cages in order to collect 24-hour urine.

Blood samples were obtained from animals' hearts under anesthesia (nesdonal, 50 mg/kg, intraperitoneal), were allowed to clot for 20 minutes in laboratory temperature, and were centrifuged at 10000 rpm for 10 minutes for serum separation. Then, the kidneys were excised, the left kidney was fixed in formal saline solution, and the right kidney was used for homogenization. The fixed kidney was cut to slices approximately 1-mm thick, and after tissue processing, paraffin sections (5-μm thickness) were prepared and stained by periodic acid Schiff method. The right kidney was homogenized in Tris-HCl buffer (0.05 mol/L Tris-HCl and 1.15% KCl, pH 7.4), using a homogenizer. The homogenate was centrifuged at 18 000 g (4°C)

for 30 minutes. The supernatant was utilized for renal tissue biochemical analysis.¹¹

Biochemical Analysis

Serum and urine parameters. Serum malondialdehyde as a marker of lipid peroxidation was assessed by thiobarbitoric acid test.²⁸ Serum creatinine and blood urea nitrogen were determined by special kits (Ziest Chemie Diagnostics, Tehran, Iran) according to its procedures. All biochemical measures were done in duplicate. Creatinine clearance was calculated and reported as mL/min/100 g body weight as follows: urine creatinine/serum creatinine \times urine volume/time.

Renal biochemical parameters. Parameters including malondialdehyde, glutathione, GP, SOD, and catalase in kidney homogenate were assessed by special kits (Pars Azmon, Tehran, Iran) according to their procedures.

Body Weight

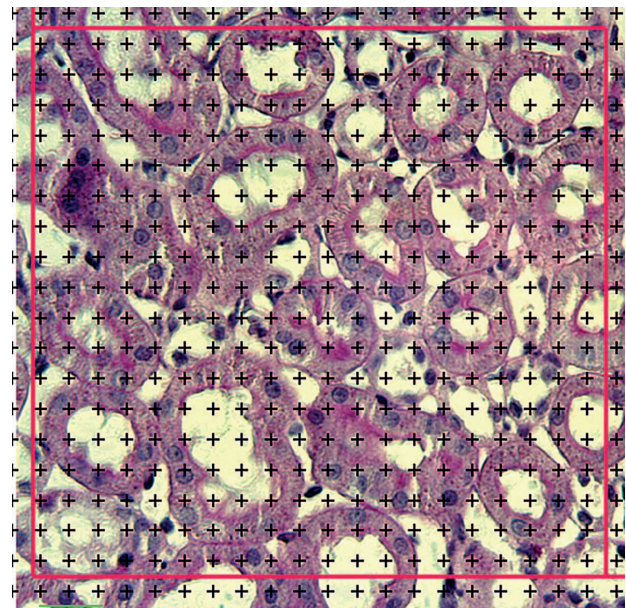
The weight of the animals was measured before and after treatment (day 0 and day 12).

Histopathological Assessments

Kidney sections were used for assessment of proximal tubule necrosis as a blinded manner by an expert histologist. Tubular necrosis was assessed on a score described as follows: zero, no cell necrosis; 1, mild usually single-cell necrosis in sparse tubules; 2, moderate, more than one cell involved in sparse tubules; 3, marked tubules exhibiting total necrosis in almost every power field; 4, massive total necrosis.²⁹

Stereological Study

The volume density of proximal convoluted tubule per cortex was estimated by the point counting rule. Sections of kidney slices (one section from each slice) were used. Microscopical image from each section was projected on a point probe (frame 13 \times 14-cm square with 360+ in it that traced on paper) by video projector via a microscope equipped with Leica DFC camera attached to the computer. At total magnification of \times 300, points that hit epithelium of proximal tubules (positive periodic acid Schiff brush border) were counted. The tubular profiles that fell inside the probe and did not cross the lower and left lines of the probe were selected for point counting (Figure).



The point grid (plus grid) superimposed on renal cortex image. Points that hit with normal proximal convoluted tubule appearance (visible brush border) were counted as described in the text (periodic acid-Schiff, \times 400).

From each kidney, at least 60 microscopical fields were assessed. The volume density of proximal convoluted tubule per cortex was estimated by below equation³⁰:

$$\Sigma Pp / \Sigma Pt$$

where ΣPp is the sum of points hitting proximal convoluted tubule epithelium and ΣPt is points falling on reference space (probe). If 10 fields are assessed then ΣPt is 10×360 .

The glomerular volume per kidney was estimated by stereological rule that completely explained in our recent research.³¹

Statistical Analyses

All values are expressed as mean \pm standard error of mean. The data (except for weight) were compared between groups by the Mann-Whitney U test. Differences of weight of animals before and after treatment in each group were analyzed by the paired *t* test. Comparison of weight and percentage of body weight change between experimental groups was analyzed through 1-way analysis of variance followed by the Tukey test. Statistical analyses were performed using the SPSS software (Statistical Package for the Social Sciences, version 13.0, SPSS Inc, Chicago, Ill, USA). A *P* value less than .05 was considered significant.

RESULTS

Olive Leaf Extract and Serum Malondialdehyde

Malondialdehyde was significantly increased in sera of rats with gentamicin-induced nephrotoxicity in comparison with the control group ($P = .01$). Treatment with OLE, regardless of its dose, significantly inhibited the increased level of malondialdehyde compared with gentamicin-only treated rats (Table 1).

Olive Leaf Extract and Kidney Function

In the gentamicin group, the level of serum creatinine significantly increased compared with the control group ($P = .008$; Table 1). Upon supplementation with OLE in groups 3 to 5, a significant decline ($P = .02$) in the levels of serum creatinine was observed in comparison with the control group. There was no significant difference in serum creatinine of the rats in groups 3 to 5 that were supplemented by OLE, 25 mg/kg/d, 50 mg/kg/d, and 100 mg/kg/d, respectively. Olive extract leaves consumption (at the above doses) maintained the level of serum creatinine in gentamicin-and-OLE-treated animals at the same level as that of the control group ($P = .69$).

Blood urea nitrogen concentration in the experimental groups is presented in Table 1. Significant increase in blood urea nitrogen was found in the gentamicin-only group compared with

the control group ($P = .004$). Upon simultaneous supplementation of gentamicin with OLE (50 mg/kg/d) in group 4, this increase was significantly inhibited ($P = .04$) in comparison with the gentamicin-only group. However, OLE consumption could not maintain the level of blood urea nitrogen at the same level in the control group ($P = .008$).

Creatinine clearance significantly decreased in the gentamicin-alone group of animals when compared with the control animals ($P = .008$; Table 1). Treatment with OLE (25 mg/kg/d and 50 mg/kg/d) in groups 3 and 4 showed significant increase of creatinine clearance in comparison with the gentamicin-only group ($P = .03$).

Olive Leaf Extract and Proximal Convolved Tubule

Induction with gentamicin in the animals showed a significant decrease of proximal convoluted tubule volume density in comparison with the control group ($P = .004$). Simultaneous treatment of gentamicin-induced nephrotoxicity rats with OLE exerted the significant increase of proximal convoluted tubule volume density when compared with gentamicin-only group ($P = .01$). Only the high dose of OLE maintained the proximal convoluted tubule volume density at the same level as that of the control group (Table 2).

Tubular necrosis significantly increased after induction with gentamicin ($P = .05$). Cotreatment

Table 1. Serum Malondialdehyde and Kidney Function Indicators in Rats Treated With and without Olive Leaf Extract (OLE)

Experimental Groups	Serum Malondialdehyde, nmol/mL	Serum Creatinine, mg/dL	Blood Urea Nitrogen, mg/dL	Creatinine Clearance, mg/min/100 g
Control	0.08 ± 0.002	0.44 ± 0.03	13.76 ± 2.74	0.54 ± 0.06
Gentamicin	0.11 ± 0.003*	3.38 ± 0.53*	63.82 ± 12.26*	0.18 ± 0.04*
Gentamicin + OLE (25 mg/kg/d)	0.05 ± 0.01††	0.70 ± 0.47†	49.99 ± 5.96*	0.73 ± 0.15†
Gentamicin + OLE (50 mg/kg/d)	0.04 ± 0.005*†	0.79 ± 0.24†	37.84 ± 5.54*†	0.48 ± 0.06†
Gentamicin + OLE (100 mg/kg/d)	0.03 ± 0.002*†	0.46 ± 0.11†	66.46 ± 5.70 *	0.20 ± 0.06*

* $P < .05$ as compared with control group.

† $P < .05$ as compared with gentamicin group.

Table 2. Effect of Olive Leaf Extract (OLE) on Histology and Biochemical Markers of Rat Kidneys Affected by Gentamicin Nephrotoxicity

Experimental Groups	Tubular Necrosis (Score 0 to 4)	Volume Density of Proximal Convolved Tubules	Glomerular volume/kidney, mm ³	Renal Malondialdehyde, nmol/g protein
Control	0.10 ± 0.04	0.22 ± 0.005	22.04 ± 1.15	0.25 ± 0.0#
Gentamicin	1.79 ± 0.18*	0.09 ± 0.01*	25.82 ± 1.90	1.11 ± 0.44*
Gentamicin + OLE (25 mg/kg/d)	0.63 ± 0.06*†	0.17 ± 0.01*†	21.39 ± 2.01	0.80 ± 0.13*
Gentamicin + OLE (50 mg/kg/d)	0.48 ± 0.14*†	0.14 ± 0.01†	23.99 ± 1.75	0.23 ± 0.02†
Gentamicin + OLE (100 mg/kg/d)	0.76 ± 0.17*†	0.20 ± 0.009†	20.49 ± 2.18	1.08 ± 0.51*

* $P < .05$ as compared with control group.

† $P < .05$ as compared with gentamicin group.

rats with gentamicin and OLE in groups 3 to 5 significantly decreased the level of proximal convoluted tubule necrosis when compared with gentamicin-only rats ($P = .05$). These treatments could not save tubular necrosis at the same level in the control group ($P = .19$; Table 2).

Olive Leaf Extract and Glomerular Hypertrophy

There were no significant differences in glomerular volume between the control and gentamicin group (Table 2). Stereologically, glomerular volume did not show significant differences between all the experimental groups.

Olive Leaf Extract and Biochemical Parameters

The level of malondialdehyde in the kidneys of gentamicin-only treated animals was significantly higher than that of the control animals ($P = .004$). Treatment of the animals in group 4 (gentamicin and OLE, 50 mg/kg/d) could significantly inhibit the increase of renal malondialdehyde in comparison with the gentamicin group ($P = .004$; Table 2). Renal glutathione level in the gentamicin group was significantly lower than that of the control group ($P = .01$). However, in groups 4 and 5 (OLE, 25 mg/kg and 50 mg/kg) renal glutathione increased significantly ($P = .04$) when compared with the gentamicin group. The level of renal glutathione in groups 3 and 4 was significantly high, similar

to the level found in the control group (Table 3). The activities of renal GP, catalase, and SOD in the gentamicin group decreased significantly ($P = .03$, $P = .19$, and $P = .04$, respectively) compared with the control group (Table 3). Treatment with OLE could not ameliorate renal GP significantly when compared with rats that received gentamicin only. Olive leaf extract consumption in group 4 (gentamicin and OLE, 50 mg/kg) significantly increased renal catalase compared with gentamicin group ($P = .38$) and maintained it at similar levels in the control group. Renal SOD significantly increased in groups 4 and 5 (gentamicin and OLE, 50 mg/kg and 100 mg/kg) compared with gentamicin group ($P = .02$) and saved as the same level as that of the control group.

Olive Leaf Extract and Body Weight of Rats

Animals that received gentamicin for 12 days showed a significant decrease in body weight when compared to their weight before treatment ($P < .001$). Gentamicin-treated animals showed a significant decrease in body weight when compared with the control group ($P = .02$). Gentamicin decreased the percentage of change in body weight when compared with the controls ($P < .001$). Treatment with OLE (100 mg/kg) inhibited weight loss when compared to the gentamicin-treated group ($P = .04$), but could not maintain at the same level as that of the control group (Table 4).

Table 3. Effect of Olive Leaf Extract (OLE) on Biochemical Markers of Rat Kidneys Affected by Gentamicin Nephrotoxicity

Experimental Groups	Renal Glutathione, nmol/mg protein	Renal Glutathione Peroxidase, U/g protein	Renal Catalase, k/mg protein	Renal Superoxide Dismutase, U/mg protein
Control	0.64 ± 0.04	94.80 ± 8.46	1281.9 ± 217.8	1044.8 ± 97.5
Gentamicin	0.43 ± 0.03*	65.02 ± 6.36*	409.6 ± 89.2*	690.05 ± 97.1*
Gentamicin + OLE (25 mg/kg/d)	0.65 ± 0.08†	80.00 ± 5.05	855.3 ± 127.2*	908.5 ± 105.4
Gentamicin + OLE (50 mg/kg/d)	0.69 ± 0.03†	58.38 ± 12.25*	1500.34 ± 501.02†	1028.6 ± 40.4†
Gentamicin + OLE (100 mg/kg/d)	0.38 ± 0.05*	23.39 ± 4.80*†	613.75 ± 164.64*	1306.5 ± 132.9†

* $P < .05$ as compared with control group.

† $P < .05$ as compared with gentamicin group.

Table 4. Effect of Olive Leaf Extract (OLE) on Animal Body Weight and Body Weight Changes in Rats Affected by Gentamicin Nephrotoxicity

Experimental Groups	Average Body Weight, g		% Body Weight Change
	Before Treatment (day 0)	After Treatment (day 12)	
Control	182.80 ± 3.05	189.20 ± 2.55	4.86 ± 0.54
Gentamicin	186.80 ± 2.12	176.30 ± 2.06*	-8.40 ± 0.47*
Gentamicin + OLE (25 mg/kg/d)	187.30 ± 2.68	177.60 ± 2.84*	-7.10 ± 0.79*
Gentamicin + OLE (50 mg/kg/d)	185.00 ± 1.69	176.00 ± 1.31*	-7.23 ± 0.80*
Gentamicin + OLE (100 mg/kg/d)	185.50 ± 1.01	178.30 ± 2.12*	-5.58 ± 0.68*†

* $P < .05$ as compared with control group.

† $P < .05$ as compared with gentamicin group.

DISCUSSION

In spite of undesirable gentamicin-induced nephrotoxicity, this antibiotic still constitute the only effective therapeutic alternative against microorganisms insensitive to other antibiotics. Moreover, gentamicin-induced nephrotoxicity has been widely used as an animal model to study acute kidney failure in experimental research.²⁹ In the pathogenesis of gentamicin-induced nephrotoxicity, oxidative stress has been proposed to contribute to nephrotoxicity, and it has been suggested that ROS is the central key in the mechanisms that lead to tubular necrosis and decrease of glomerular filtration rate. Reactive oxygen species activates nuclear factor kappa B that plays a key role in the inception of inflammatory process.³² It may be said that the central role of gentamicin-induced nephrotoxicity is oxidative stress and inflammation; a loop of damage amplification and a connection between mechanisms of tubular and glomerular changes.³²

Marked elevations of serum creatinine and urea concentration were suggested as a significant functional impairment of kidney in gentamicin-induced nephrotoxicity.¹² Serum creatinine concentration is a more potent indicator than the urea in the first phases of kidney disease. Further more, urea concentrations begin to increase only after parenchymal injury.³³ In our study, administration of gentamicin (100 mg/kg/d, intraperitoneally) led to significant increase of serum creatinine, blood urea nitrogen, and malondialdehyde as it was previously reported by others.^{14-21,29} The elevated level of malondialdehyde indicates increased free radicals generation in gentamicin-induced nephrotoxicity. Increase of serum creatinine, urea, and malondialdehyde were inhibited significantly in rats simultaneous treated with OLE and gentamicin in comparison with gentamicin-only treated animals. Similar results were also reported using different antioxidants by other researchers.^{14,19,20,27,29} It seems that these results are related to the antioxidant property of OLE. Our results also showed amelioration of creatinine clearance in groups that simultaneously received gentamicin and OLE (25 mg/kg and 50 mg/kg), similar to what reported by other researchers who used antioxidant agents.^{29,34} The inhibition of serum creatinine and increase of creatinine clearance in this study shows the amelioration of glomerular

function by OLE consumption.

Gentamicin alters glomerular filtration rate because of mesangial cell contraction, loss of glomerular filtration barrier selectively due to the neutralization of its negative charges, mesangial cell proliferation, and apoptosis.³² It can be speculated that amelioration of creatinine clearance by OLE is due to the recovery of tubular and glomerular function in gentamicin nephrotoxicity. In the present study, the gentamicin-treated rats showed severe proximal tubule necrosis. Tubular necrosis was inhibited in the animals treated with gentamicin and OLE in comparison with gentamicin-only treated animals. Such results were reported by other researchers by using antioxidant compounds previously.^{13,19,27,29,35} Gentamicin makes proximal tubular cell death via oxidative stress, apoptosis, inflammation, phospholipidosis, and increase of intracellular sodium ions.³²

Our results showed that the volume density of proximal tubules in the gentamicin-only treated rats decreased significantly by 59% in comparison with the control group. Decrease of proximal convoluted tubules volume density was inhibited in the gentamicin and OLE groups and saved it as the same level as that of the control group at the dose of 100 mg/kg/d. Although our stereological results did not show significant glomerular hypertrophy by gentamicin administration, some researchers reported glomerular hypertrophy after gentamicin treatment by morphological rules and increase of glomerular area by using gentamicin.^{5,9,10,36}

This study reveals that gentamicin consumption led to significant increase of renal malondialdehyde compared with the control group. Increased renal malondialdehyde was inhibited in the group that received gentamicin and OLE, 50 mg/kg, in comparison with the gentamicin-only treated animals. The same results were reported by other researchers with antioxidant agents.^{13,19,27} According to our results in the gentamicin-only treated group, renal tissue glutathione content and renal tissue antioxidant enzymes activity GP, catalase, and SOD declined significantly when compared with the control group, similar to what reported by other researchers.^{12,14,19,20} However, Karahan and colleagues reported that gentamicin cannot increase renal glutathione significantly compared with the control group and Farombi and Ekor reported that renal SOD levels could not be changed by

gentamicin.^{27,29} The increased production of ROS in gentamicin-induced nephrotoxicity may cause inactivation of antioxidant enzymes such as SOD and GP.²⁰ Our results showed that in the gentamicin and OLE groups, glutathione, catalase, and SOD were increased significantly in comparison with those in the gentamicin-only treated animals. These results were reported by others who treated animals with different antioxidant agents.^{12,14,19} Nonetheless, OLE consumption could not ameliorate GP activity in the gentamicin and OLE groups in comparison with the gentamicin-only treated rats.

It is well known that oleuropein, hydroxytyrosol, tyrosol, and caffeic acid are the main constituents of olive leaves, which are thought to be responsible for their pharmacological effects. Furthermore, olive leaves contain p-coumaric acid, vanillic acid, vanillin, luteolin, diosmetin, rutin, luteolin-7-glucoside, apigenin-7-glucoside, and diosmetin-7-glucoside.^{37,38} It has been reported that pure hydroxytyrosol had an important antioxidant effect, which confirms the high activity of the hydrolysate extract.²⁵ Hydroxytyrosol is the principal oleuropein derivative; it is used to prevent diseases because it is endowed with an important antioxidant property.²⁴ Olive phenolic compounds have strong free-radical scavenging capacity and show a synergistic behavior when combined, as occurs naturally in the olive leaf and hence OLE. In addition, the antioxidant effect produced by OLE is higher due to the synergy of flavonoids and phenols and the high oleuropein content.²³

The significant and progressive weight losses in gentamicin-treated rats are remarkable. In our research, supplementation of OLE (100 mg/kg/d) inhibited weight loss induced by gentamicin, even though it could not save animal weight at the same level as the control group. Such results also reported by using *Cassia auriculata* root extract and aqueous leaf and seed extract of *Phyllanthus amarus* for prevention of weight loss induced by gentamicin.^{39,40} It is reasonable to conclude that the use of antioxidant effect of OLE was responsible for the inhibited weight loss recorded in this study.

CONCLUSIONS

Olive leaf extract protects gentamicin-induced nephrotoxicity possibly by inhibition of lipid peroxidation, enhancing renal glutathione content, and antioxidant enzymes activity. The findings thus

suggest the potential therapeutic use of OLE as a new nephroprotective agent against acute kidney failure induced by nephrotoxins like gentamicin. Further studies with larger sample sizes and a longer duration of follow-up are required to confirm these results.

ACKNOWLEDGEMENTS

The authors thank the head and personals of Razi Herbal Drugs Research Center of Lorestan Medical University.

CONFLICT OF INTEREST

None declared.

REFERENCES

1. Salgado CM, Hernandez FL, Novoa JM. Glomerular nephrotoxicity of amino nucleosides. *Toxicol Applied Pharmacol.* 2007;223:86-98.
2. Balakumar P, Chakkarwar VA, Kumar V, Jain A, Reddy J, Singh M. Experimental models for nephropathy. *J Renin Angiotensin Aldosterone Syst.* 2008;9:189-95.
3. Geleilate TJ, Melo GC, Costa RS, Volpini RA, Soares TJ, Coimbra TM. Role of myofibroblasts, macrophages, transforming growth factor-beta endothelin, angiotensin-II, and fibronectin in the progression of tubulointerstitial nephritis induced by gentamicin. *J Nephrol.* 2002;15: 633-42.
4. Ali BH. Gentamicin nephrotoxicity in humans and animals: some recent research. *Gen Pharmacol.* 1995;26:1477-87.
5. Bledsoe G, Crickman S, Mao J, et al. Kallikrein/kinin protects against gentamicin-induced nephrotoxicity by inhibition of inflammation and apoptosis. *Nephrol Dial Transplant.* 2006;21:624-33.
6. Balakumar P, Rohilla A, Thangathirupathi A. Gentamicin-induced nephrotoxicity: Do we have a promising therapeutic approach to blunt it? *Pharmacol Res.* 2010;62:179-86.
7. Romero F, Perez M, Chavez M, Parra G, Durante P. Effect of uric acid on gentamicin-induced nephrotoxicity in rats - role of matrix metalloproteinases 2 and 9. *Basic Clin Pharmacol Toxicol.* 2009;105:416-24.
8. Mysior M, Stefanczyk L. Doppler ultrasound criteria of physiological flow in asymmetrical vertebral arteries. *Med Sci Monit.* 2007;13 Suppl 1:73-7.
9. Abdel-Naim AB, Abdel-Wahab MH, Attia FF. Protective effects of vitamin e and probucol against gentamicin-induced nephrotoxicity in rats. *Pharmacol Res.* 1999;40:183-7.
10. Lakshmi BV, Neelima N, Kasthuri N, Umarani V, Sudhakar M. Protective Effect of Bauhinia purpurea on Gentamicin-induced Nephrotoxicity in Rats. *Indian J Pharm Sci.* 2009;71:551-4.
11. Li J, Li QX, Xie XF, Ao Y, Tie CR, Song RJ. Differential roles of dihydropyridine calcium antagonist nifedipine, nitrendipine and amlodipine on gentamicin-induced renal

- tubular toxicity in rats. *Eur J Pharmacol.* 2009;620:97-104.
12. Kalayarasan S, Prabhu PN, Sriram N, Manikandan R, Arumugam M, Sudhandiran G. Diallyl sulfide enhances antioxidants and inhibits inflammation through the activation of Nrf2 against gentamicin-induced nephrotoxicity in Wistar rats. *Eur J Pharmacol.* 2009;606:162-71.
 13. Yaman I, Balıkcı E. Protective effects of nigella sativa against gentamicin-induced nephrotoxicity in rats. *Exp Toxicol Pathol.* 2010;62:183-90.
 14. Nitha B, Janardhanan KK. Aqueous-ethanolic extract of morel mushroom mycelium *Morchella esculenta*, protects cisplatin and gentamicin induced nephrotoxicity in mice. *Food Chem Toxicol.* 2008;46:3193-9.
 15. Walker PD, Barri Y, Shah SV. Oxidant mechanisms in gentamicin nephrotoxicity. *Ren Fail.* 1999;21:433-42.
 16. Parlakpınar H, Tasdemir S, Polat A, et al. Protective role of caffeic acid phenethyl ester (CAPE) on gentamicin-induced acute renal toxicity in rats. *Toxicology.* 2005;207:169-77.
 17. Ali BH. The effect of treatment with the medicinal plant *Rhazya stricta* Decne on gentamicin nephrotoxicity in rats. *Phytomedicine.* 2002;9:385-9.
 18. Sener G, Sehirli AO, Altunbas HZ, et al. Melatonin protects against gentamicin-induced nephrotoxicity in rats. *J Pineal Res.* 2002;32:231-6.
 19. Polat A, Parlakpınar H, Tasdemir S, et al. Protective role of aminoguanidine on gentamicin-induced acute renal failure in rats. *Acta Histochem.* 2006;108:365-71.
 20. Karadeniz A, Yildirim A, Simsek N, Kalkan Y, Celebi F. *Spirulina platensis* protects against gentamicin-induced nephrotoxicity in rats. *Phytother Res.* 2008;22:1506-10.
 21. Khan SA, Priyamvada S, Farooq N, Khan S, Khan MW, Yusufi AN. Protective effect of green tea extract on gentamicin-induced nephrotoxicity and oxidative damage in rat kidney. *Pharmacol Res.* 2009;59:254-62.
 22. Visioli F, Bellomo G, Galli C. Free radical-scavenging properties of olive oil polyphenols. *Biochem Biophys Res Commun.* 1998;247:60-4.
 23. Benavente-García O, Castillo J, Lorente J, Ortuno A, Del Rio JA. Antioxidant activity of phenolics extracted from *Olea europaea* L. leaves. *Food Chem.* 2000;68:457-62.
 24. Capasso R, Evidente A, Avolio S, Solla F. A highly convenient synthesis of hydroxytyrosol and its recovery from agricultural waste waters. *J Agric Food Chem.* 1999;47:1745-8.
 25. Jemai H, Fki I, Bouaziz M, et al. Lipid-lowering and antioxidant effects of hydroxytyrosol and its triacetylated derivative recovered from olive tree leaves in cholesterol-fed rats. *J Agric Food Chem.* 2008;56:2630-6.
 26. Mohagheghi F, Bigdeli MR, Rasoulzadeh B, Hashemi P, Pour MR. The neuroprotective effect of olive leaf extract is related to improved blood-brain barrier permeability and brain edema in rat with experimental focal cerebral ischemia. *Phytomedicine.* 2011;18:170-5.
 27. Karahan I, Atessahin A, Yilmaz S, Ceribasi AO, Sakin F. Protective effect of lycopene on gentamicin-induced oxidative stress and nephrotoxicity in rats. *Toxicology.* 2005;215:198-204.
 28. Satho K. Serum lipid peroxidation in cerebrovascular disorders determined by a new colorimetric method. *Clin Chem Acta.* 1978;90:37-43.
 29. Farombi EO, Ekor M. Curcumin attenuates gentamicin-induced renal oxidative damage in rats. *Food Chem Toxicol.* 2006;44:1443-8.
 30. Carlos A. Stereological tools in biomedical research. *Acad Bras Ciênc.* 2003;75:413.
 31. Tavafi M, Ahmadvand H, Tamjidipoor A, Delfan B, Khalatbari AR. Satureja khuzestanica essential oil ameliorates progression of diabetic nephropathy in uninephrectomized diabetic rats. *Tissue Cell.* 2011;43:45-51.
 32. Lopez-Novoa JM, Quiros Y, Vicente L, Morales AI, Lopez-Hernandez FJ. New insights into the mechanism of aminoglycoside nephrotoxicity: an integrative point of view. *Kidney Int.* 2011;79:33-45.
 33. Gilbert DN, Wood CA, Kohlhepp SJ, et al. Polyaspartic acid prevents experimental aminoglycoside nephrotoxicity. *J Infect Dis.* 1989;159:945-53.
 34. Priyamvada S, Priyadarshini M, Arivarasu NA, et al. Studies on the protective effect of dietary fish oil on gentamicin-induced nephrotoxicity and oxidative damage in rat kidney. *Prostaglandins Leukot Essent Fatty Acids.* 2008;78:369-81.
 35. Sayed-Ahmed MM, Nagi MN. Thymoquinone supplementation prevents the development of gentamicin-induced acute renal toxicity in rats. *Clin Exp Pharmacol Physiol.* 2007;34:399-405.
 36. Stojiljkovic N, Mihailovic D, Veljkovic S, Stojiljkovic M, Jovanovic I. Glomerular basement membrane alterations induced by gentamicin administration in rats. *Exp Toxicol Pathol.* 2008;60:69-75.
 37. Bianco A, Uccella N. Biophenolic components of olives. *Food Res Int.* 2000;33:475-85.
 38. Ryan D, Antolovich M, Prenzler P, Robards K, Lavee S. Biotransformations of phenolic compounds in *Olea europaea* L. *Scientia Horticulturae.* 2002;92:147-76.
 39. Annie S, Rajagopal PL, Malini S. Effect of *Cassia auriculata* Linn. root extract on cisplatin and gentamicin-induced renal injury. *Phytomedicine.* 2005;12:555-60.
 40. Adeneye AA, Benebo AS. Protective effect of the aqueous leaf and seed extract of *Phyllanthus amarus* on gentamicin and acetaminophen-induced nephrotoxic rats. *J Ethnopharmacol.* 2008;118:318-23.

Correspondence to:

Majid Tavafi, PhD

Razi Herbal Medicines Research Center, Lorestan University of Medical Sciences, Khoram Abad, Iran

E-mail: mtavafi@yahoo.com

Received May 2011

Revised August 2011

Accepted August 2011