

# Acute Page Kidney Complicating Kidney Transplant Artery Stenting

## Presentation of a Case and Novel Management

Alireza Hamidian Jahromi,<sup>1,2</sup> Jiri Fronek,<sup>1,3</sup> Nicos Kessararis,<sup>1</sup> Gareth Bydawell,<sup>4</sup> Uday Patel,<sup>4</sup> Iain AM MacPhee<sup>1</sup>

<sup>1</sup>Department of Renal Medicine and Transplantation, St George's Hospital, Blackshaw Road, London, United Kingdom

<sup>2</sup>Department of Surgery, Louisiana State University Health Sciences Center-Shreveport, Los Angeles, United States

<sup>3</sup>Institute for Clinical and Experimental Medicine and 2nd Medical Faculty, Charles University, Prague, Czech Republic

<sup>4</sup>Department of Radiology, St George's Healthcare NHS Trust, London, United Kingdom

We present a rare complication of transplant renal artery stenting in a patient who developed subcapsular hematoma and presented as acute page kidney. We discuss possible mechanisms and successful novel management using radiological-assisted decompression. We propose considering this alternative option before proceeding with surgical exploration and renal capsulotomy.

IJKD 2013;7:352-5  
www.ijkd.org

**Keywords.** kidney transplantation, postoperative complications, stents, renal artery obstruction, hematoma

### INTRODUCTION

Transplant renal artery stenosis (TRAS) is a common vascular complication after kidney transplantation (reported incidence, 1% to 23%), which can cause resistant hypertension, allograft dysfunction, and even graft loss.<sup>1,2</sup> Endovascular management, percutaneous transluminal angioplasty or stenting is the main management although repeat treatment may be necessary.<sup>1,3</sup> The overall safety of this approach is established.<sup>1,4-6</sup> We present a rare complication of stent insertion, with a discussion of possible mechanism and management.

### CASE REPORT AND MANAGEMENT

A 19-year-old man with end-stage renal failure (immunoglobulin A nephropathy) underwent living-related kidney transplantation. The graft was a left kidney with 1 artery, 1 vein, and 1 ureter,

which were anastomosed to the right external iliac artery, right external iliac vein, and the bladder, respectively. Immediately postoperation, Doppler ultrasonography showed good perfusion throughout the graft. His serum creatinine fell from 861  $\mu\text{mol/L}$  on pre-operation measurement to 212  $\mu\text{mol/L}$  4 days after operation.

Nine days postoperation, serum creatinine concentration was 234  $\mu\text{mol/L}$  and Doppler ultrasonography showed dampened flow in the transplant renal artery (TRA), with resistance indexes measuring only 0.33 to 0.48. Measurement of flow indexes in TRA showed a decreased acceleration flow of 65  $\text{cm/sec}^2$  (reference range, > 300  $\text{cm/sec}^2$ ) and elevated peak systolic velocity (PSV) of 455  $\text{cm/sec}$  to 535  $\text{cm/sec}$  (reference range, < 250  $\text{cm/sec}$ ). There was a focal narrowing at the site of anastomosis of the TRA to the external iliac artery, and the findings were consistent with

TRAS. It was planned to have serial follow-up Doppler ultrasonography as his serum creatinine concentration was stable, and it was too soon after surgery to undergo any intervention.

Three weeks posttransplantation and following a rise in his serum creatinine from 208  $\mu\text{mol/L}$  to 226  $\mu\text{mol/L}$ , his medical status was reviewed in the hospital. As the histopathology on-call service was not available over the weekend, he was given a single dose of methyl prednisolone (Aventis Pharma Ltd, London, UK) before undergoing transplant kidney biopsy the next day, which showed areas of chronic inflammatory cell infiltrate accompanied by moderate tubulitis, representing borderline features suspicious of acute T-cell-mediated rejection. Following antirejection treatment, his serum creatinine came down from 226  $\mu\text{mol/L}$  to 170  $\mu\text{mol/L}$ .

One month posttransplantation, Doppler ultrasonography demonstrated persistently elevated blood flow velocity within TRA, with a PSV measurement of 520 cm/sec compared with a PSV of 150 cm/sec in the external iliac artery. Incidental note was made of a 1-cm arteriovenous fistula at the biopsy site arising from an upper pole segmental vessel. At this stage the patient was referred for angiography and endovascular therapy.

Arteriography confirmed a significant stenosis of TRA just distal to its anastomosis with the right external iliac artery. There was a pressure gradient of 60 mm Hg to 80 mmHg across the stenosis. Angioplasty was performed using a 6-mm diameter balloon. There was a residual systolic arterial pressure gradient (25 mm Hg to 30 mm Hg) across the stenotic area after the procedure. However, no further intervention was performed in view of the improved angiographic appearance and the short-time interval since surgery.

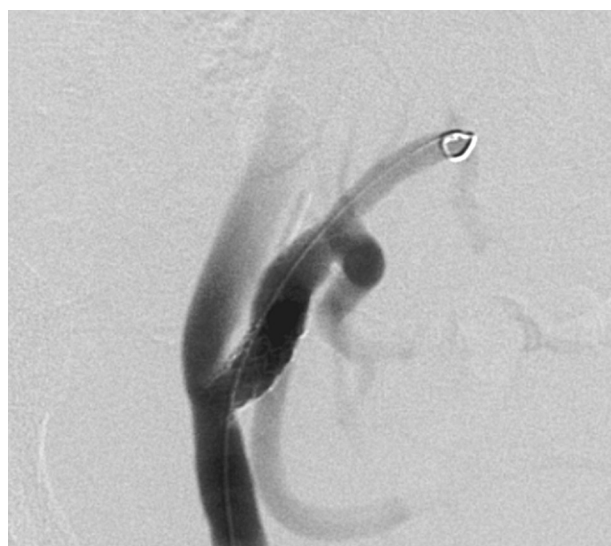Doppler ultrasonography 1 week later showed that flow velocities were still elevated. Furthermore, there had been no improvement in serum creatinine concentration; therefore, repeat angiography was performed. This confirmed residual stenosis at the site of the recent angioplasty (pressure gradient of 40 mm Hg), so we proceeded with endovascular stenting. Stent positioning was difficult due to angulation at the arterial anastomosis. Therefore, 3 separate (6 mm; 1.5 cm long) balloon-expandable stents (Palmaz, Genesis, Cordis Europa, The

Netherlands) were required for a satisfactory result (Figure 1). At the end of the procedure, the pressure gradient was lowered to 10 mm Hg. Postprocedural angiography showed satisfactory stent position with no evidence of any complications and an entirely normal intrarenal arterial tree. Finally, a vascular closure device (Angio-Seal, St Jude Medical Europe Inc, Belgium) was used without complications.

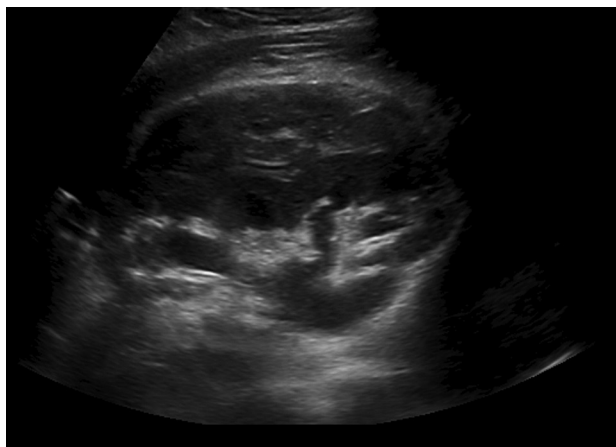However, 6 hours postprocedure, urine output decreased significantly. Doppler ultrasonography showed a large subcapsular hematoma (10  $\times$  3.1  $\times$  6 cm), which was surrounding the anterior aspect of the transplant kidney, opposite to the renal hilum (Figure 2). Good blood flow was seen throughout the transplant kidney, but resistive index values were increased to around 0.69 to 0.73.

The hematoma was seen to significantly compress the kidney. The diagnosis of acute page kidney (APK) was made, and this was felt to account for the decreased urine output. His serum creatinine was raised to 512  $\mu\text{mol/L}$ . He underwent ultrasonography-guided drainage of the subcapsular hematoma. Following aspiration, a 10-F (3.3 mm) drainage pigtail catheter (Flexitime, regular APDL, Boston Scientific Co, USA) was inserted into this collection.

Examination with Doppler ultrasonography showed improved blood flow within the transplant kidney. The drain was kept in for 4 days. Serial follow-up Doppler ultrasonography showed



**Figure 1.** Digital subtraction angiogram showed successful stent deployment at the surgical anastomosis of the renal transplant artery with the external iliac artery.

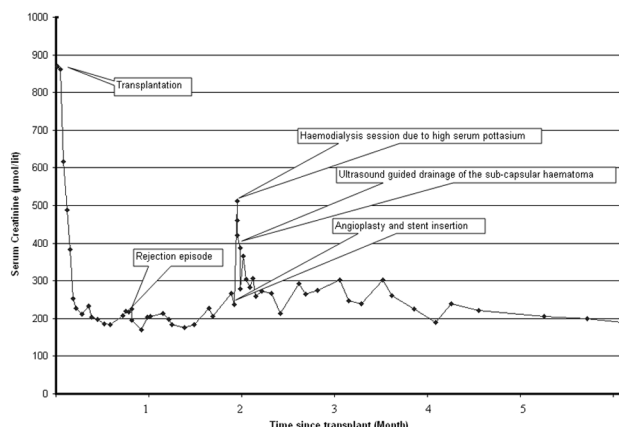


**Figure 2.** Longitudinal ultrasonography image of the transplant kidney showed a large 10 × 3.1-cm subcapsular hematoma situated anterior to the kidney. Note is also made of the prominent collecting system, which is secondary to the distended bladder (seen inferior to the kidney).

reducing pressure effect of hematoma on the kidney and good vascular perfusion with resistive index values of 0.57 to 0.64. The PSV at the transplant artery anastomosis site was measured between 340 cm/sec to 440 cm/sec, with a PSV in the external iliac artery of 380 cm/sec. His serum creatinine concentration started to decrease, following the successful stent insertion. Six months after stenting, his serum creatinine decreased to 189 μmol/L. Figure 3 shows the change in his serum creatinine concentration since the time of transplant. The most recent serum creatinine level, 2 years after transplantation as 164 μmol/L, and the glomerular filtration rate was estimated to be 45 mL/min.

## DISCUSSION

Transplant renal artery stenosis is a common



**Figure 3.** Changes in the serum creatinine concentration in the patient since the time of transplant.

vascular complication after kidney transplantation, which can present months to years postoperatively.<sup>7</sup> It can be caused by trauma to donor or recipient's artery, poor suturing technique, kinking or damage to the iliac or renal artery during transplantation, and atherosclerotic plaque. The first report of successfully using expandable metal stents for management of resistant TRAS comes from St Mary's Hospital in London, UK.<sup>8</sup> In the last 2 years in our center, we have seen 2 other cases of TRAS in 131 living donor kidney transplants (incidence rate of 2.3%). Both cases were stented successfully, without complications. In a retrospective study on 32 interventions in 30 allografts, the stenting technical success rate was 100% with a single major complication, *puncture site pseudo-aneurysm*.<sup>1</sup>

Major complications are rare but are associated with severe morbidity. The most feared complication after percutaneous intervention for TRAS is immediate arterial rupture, requiring either immediate surgical repair or the insertion of a covered stent. Delayed hemorrhage, as seen in our case, is much less common. Even then, one would expect it to be related to bleeding from the puncture site. To our knowledge, there has been only 1 previous report of major hemorrhage after stenting (not related to the main arterial rupture).<sup>9</sup> This was thought to be due to transcortical position of the guide wire. Attempted renal artery embolization failed to control the hemorrhage.<sup>9</sup>

External compression of the kidney causing subsequent ischemia and hypertension has been described as APK.<sup>10</sup> It can happen in native and allograft kidneys. Trauma, spontaneous bleeding in patients with predisposing factors (anticoagulation), bleeding after interventions (operation, biopsy, and lithotripsy) have been proposed as the etiological factors.<sup>11</sup> In our case, there are a few possible mechanisms for APK. Spontaneous bleeding, transcortical position of the guide wire during procedure, arterial rupture, bleeding from the low resistance paranchymal tract from the previous biopsy sites, sudden increase in blood flow and pressure after relieving the stenotic area of the TRA post procedure and subsequent rupture of the previous arteriovenous are the possible mechanisms.

In this case, the patient was not anti-coagulated, angiographic review did not show any acute arterial bleeding and there was no evidence of guide-wire perforation. The exact cause of the sub-capsular

hematoma is not known. Whether the previous arteriovenous or the biopsy tract was a factor, can only be a matter of speculation.

In a report on 518 ultrasonography-guided kidney allograft biopsies, 4 recipients developed APK.<sup>10</sup> Surgical exploration (allograft capsulotomy) was successfully performed in all cases as the first measure to rescue the graft.<sup>10</sup> In our center, between January 1996 and November 2008, there have been 774 kidney transplant operations (212 living donors and 562 deceased donors) and we have done 969 ultrasonography guided kidney allograft biopsies (including protocol biopsies more recently). None of these resulted in APK.

Spontaneous native-kidney APK in a young lady taking warfarin for dilated cardiomyopathy has been previously reported from our center.<sup>12</sup> After reversing her anticoagulation, she was treated successfully with percutaneous drainage. The current case is the first kidney allograft APK we have seen.

In the past, the management of allograft APK has always been surgical.<sup>10,13</sup> Although there have been recent reports using laparoscopic and radiological methods for the treating native-kidney APK,<sup>12,14</sup> percutaneous drainage of the APK in a kidney allograft using Doppler ultrasonography has not been reported before. We have shown that such an approach is safe and effective. We therefore propose considering this alternative option before proceeding with surgical exploration and renal capsulotomy in such cases.

## CONCLUSIONS

Acute page kidney is a rare but serious complication of TRA stenting. Early diagnosis is invaluable as immediate decompression can rescue the allograft. As radiological assisted decompression can be successful, we propose considering this alternative option before proceeding with surgical exploration.

## CONFLICT OF INTEREST

None declared.

## REFERENCES

1. Valpreda S, Messina M, Rabbia C. Stenting of transplant renal artery stenosis: outcome in a single center study. *J*

*Cardiovasc Surg (Torino)*. 2008;49:565-70.

2. Polak WG, Jezior D, Garcarek J, et al. Incidence and outcome of transplant renal artery stenosis: single center experience. *Transplant Proc*. 2006;38:131-2.
3. da Silva RG, Lima VC, Amorim JE, Machado PG, Pacheco-Silva A, Medina-Pestana JO. Angioplasty with stent is the preferred therapy for posttransplant renal artery stenosis. *Transplant Proc*. 2002;34:514-5.
4. Pappas P, Zavos G, Kaza S, et al. Angioplasty and stenting of arterial stenosis affecting renal transplant function. *Transplant Proc*. 2008;40:1391-6.
5. Bertoni E, Zanazzi M, Rosati A, et al. Efficacy and safety of Palmaz stent insertion in the treatment of renal artery stenosis in kidney transplantation. *Transpl Int*. 2000;13 Suppl 1:S425-30.
6. Salvadori M, Di Maria L, Rosati A, et al. Efficacy and safety of Palmaz stent implantation in the treatment of renal artery stenosis in renal transplantation. *Transplant Proc*. 2005;37:1047-8.
7. Fervenza FC, Lafayette RA, Alfrey EJ, Petersen J. Renal artery stenosis in kidney transplants. *Am J Kidney Dis*. 1998;31:142-8.
8. Newman-Sanders AP, Gedroyc WG, al-Kutoubi MA, Koo C, Taube D. The use of expandable metal stents in transplant renal artery stenosis. *Clin Radiol*. 1995;50:245-50.
9. Axelrod DJ, Freeman H, Pukin L, Guller J, Mitty HA. Guide wire perforation leading to fatal perirenal hemorrhage from transcortical collaterals after renal artery stent placement. *J Vasc Interv Radiol*. 2004;15:985-7.
10. Chung J, Caumartin Y, Warren J, Luke PP. Acute Page kidney following renal allograft biopsy: a complication requiring early recognition and treatment. *Am J Transplant*. 2008;8:1323-8.
11. Haydar A, Bakri RS, Prime M, Goldsmith DJ. Page kidney—a review of the literature. *J Nephrol*. 2003;16:329-33.
12. Suckling R, Uddin F, Pilcher J, MacPhee IA, Eastwood JB, Banerjee D. Page kidney: successful radiological management of acute renal failure. *Nephrol Dial Transplant*. 2006;21:1740.
13. Moriarty KP, Lipkowitz GS, Germain MJ. Capsulectomy: a cure for the page kidney. *J Pediatr Surg*. 1997;32:831-3.
14. Castle EP, Herrell SD. Laparoscopic management of page kidney. *J Urol*. 2002;168:673-4.

Correspondence to:

Iain MacPhee, DPhil, FRCP

Department of Renal Medicine and Transplantation, St George's Hospital, Blackshaw Rd, London, SW17 0QT, United Kingdom

E-mail: imacphee@sgul.ac.uk

Received February 2013

Revised April 2013