

Preventive Effects of Nicorandil and Atorvastatin in Contrast-induced Nephropathy in Patients with Renal Dysfunction Undergoing Coronary Artery Angiography: A Double Blind, Randomized, Controlled Clinical Trial

Sousan Mohammadi Kebar,¹ Elham Atighi,¹ Saeed Hosseninia,¹ Behzad Babapour²

¹Department of Internal Medicine, Faculty of Medicine, Ardabil University of Medical Sciences, Ardabil, Iran

²Department of Cardiology, Faculty of Medicine, Ardabil University of Medical Sciences, Ardabil, Iran

Keywords. nicorandil, atorvastatin, contrast media, acute kidney injury, coronary artery disease

Introductions. Contrast-induced nephropathy (CIN) is an important issue in patients with cardiovascular disorders undergoing angiography, especially in patients with kidney failure. The purpose of the present study was to compare the preventive effects of nicorandil and atorvastatin on the incidence of CIN in patients with chronic kidney disease (CKD).

Methods. In this clinical trial study, 270 patients with renal insufficiency nominated for angiographic procedures were randomly divided into three groups (each group, n = 90): hydration group (1000 mL saline), hydration + atorvastatin group (80 mg/d for 3 days), and hydration + nicorandil group (10 mg 3 times/d for 3 days). Serum creatinine (Cr) and blood urea nitrogen (BUN) levels as well as glomerular filtration rate (GFR) were evaluated before and 72 hours after the intervention.

Results. At the end of the study, serum Cr and BUN levels in all three groups showed a significant increase compared to the pre-intervention levels, which were significantly higher in the control group than the other two groups. The amount of GFR also significantly decreased following the intervention in all three groups, with the decline being significantly more pronounced in the control group than in other two groups. No significant differences were found in serum concentrations of Cr and BUN as well as GFR levels between nicorandil and atorvastatin groups at the end of the study.

Conclusion. Nicorandil and atorvastatin administration showed preventive effects on CIN in CKD patients undergoing angiography, but there was no significant difference between the two drugs.

IJKD 2023;17:205-14
www.ijkd.org

DOI: 10.52547/ijkd.7348

INTRODUCTION

Contrast-induced nephropathy (CIN) is one of the most common and preventable cause of acute kidney injury (AKI), occurring in about 11% of hospitalized patients. Hypotension, surgery and

CIN are the most common causes of AKI.² This kidney disorder worsens the patient outcome and increases the mortality rate.³ Contrast-induced nephropathy is a significant consequence that increases concerns in patients with cardiovascular

disease who are angiography candidates, especially patients suffering from renal insufficiency.⁴ An increase in serum creatinine (Cr) concentration of 25% (or at least 0.5 mg/dL) from the reference concentration is defined as CIN after using contrast media.⁵ Due to the increased incidence of cardiovascular diseases (CVD) around the world and the increased need for diagnostic interventions such as angiography, a 10 to 20% increase in CIN has been reported in CVD patients.⁶ In patients with cardiovascular disease, CIN increases length of hospitalization, hemodialysis, and mortality.⁷

It seems that kidney disorders caused by the contrast agents are due to changes in renal circulation, decreased blood supply to the medulla, and direct poisoning of the epithelial cells of the renal tubules.⁸ Although the pathophysiology of CIN is not fully known, the role of several mediators, such as angiotensin, adenosine, endothelin, platelet-activating factor (PAF), nitric oxide, insulin-like growth factor (IGF), atrial natriuretic peptide, and prostaglandins has been described.⁹ Maintaining adequate intravascular volume with the administration of crystalloid isotonic solutions (1 to 1.5 mL/kg of body weight per hour) for 3 to 12 hours before the procedure and continuing for 6 to 24 hours thereafter can significantly reduce the risk of contrast-induced nephropathy.¹⁰ Contrast agents are one of the major causes of renal tubular damage and acute tubular necrosis.¹¹ Various therapeutic measures, such as the administration of nicorandil, atorvastatin, and bicarbonate, as well as adequate hydration before the use of contrast agents, have been studied to prevent CIN.¹²⁻¹⁴ The findings of these studies are mostly controversial. Despite the conflicting evidence regarding the preventive effects of nicorandil and atorvastatin on the incidence of CIN in some clinical trials, there is no consensus on their therapeutic use in patients nominated for angiography.

Therefore, the primary aim of this study was to evaluate the preventive effects of nicorandil and atorvastatin on CIN in CKD candidates for angiography. In addition, the secondary goal was to compare the effectiveness of the two drugs in preventing CIN.

MATERIALS AND METHODS

Design

This randomized, double-blind, placebo-

controlled clinical trial was conducted from January 1, 2019, to March 30, 2020, at Imam Khomeini Hospital, Ardabil, Iran.

Participants

Two hundred and seventy female and male patients with chronic kidney disease, who were candidates for coronary angiography and met the following criteria were included in the study: 1- glomerular filtration rate (GFR) below 60 mL/min/1.73m², 2- age between 18 and 75 years, and 3- cardiac ejection fractional (EF) more than 40%. Exclusion criteria were: 1- patients with symptoms of hypotension (systolic pressure < 90 mmHg or diastolic pressure < 50 mmHg), 2- patients with a history of allergic reactions to contrast agents, and 3- patients requiring emergency angiography.

Randomization

Using practical sampling method, the study participants were randomly divided into three groups (each group containing 90 patients): hydration group (Hyd), hydration + atorvastatin group (Hyd + Ator), and hydration + nicorandil group (Hyd + Nico). Randomization of patients was done in Excel using RANDBETWEEN function. The trial was designed to be double-blind, so the researchers were given identical white bags for all three intervention groups, numbered them in a random order, and delivered them to the physician. All the study participants (researchers and patients) were blinded with random codes (Figure 1).

Intervention

The enrolled study participants were divided into three groups. The Hyd group, as a control group, was hydrated with a infusion of 1000 mL of normal saline for 6 hours prior to and after the procedure. Patients in the Hyd + Nico group received nicorandil tablets (10 mg/d for three days),¹⁵ and the Hyd + Ator group received atorvastatin tablets (80 mg/d for three days),¹⁶ one day before the procedure and two days after it. The latter two groups were given the same quantity of normal saline as the Hyd group. All patients included in the study had a history of taking 20 mg of atorvastatin daily. After one-week wash-out period to avoid any carryover effect, patients were prescribed 80 mg of atorvastatin for 3 days.

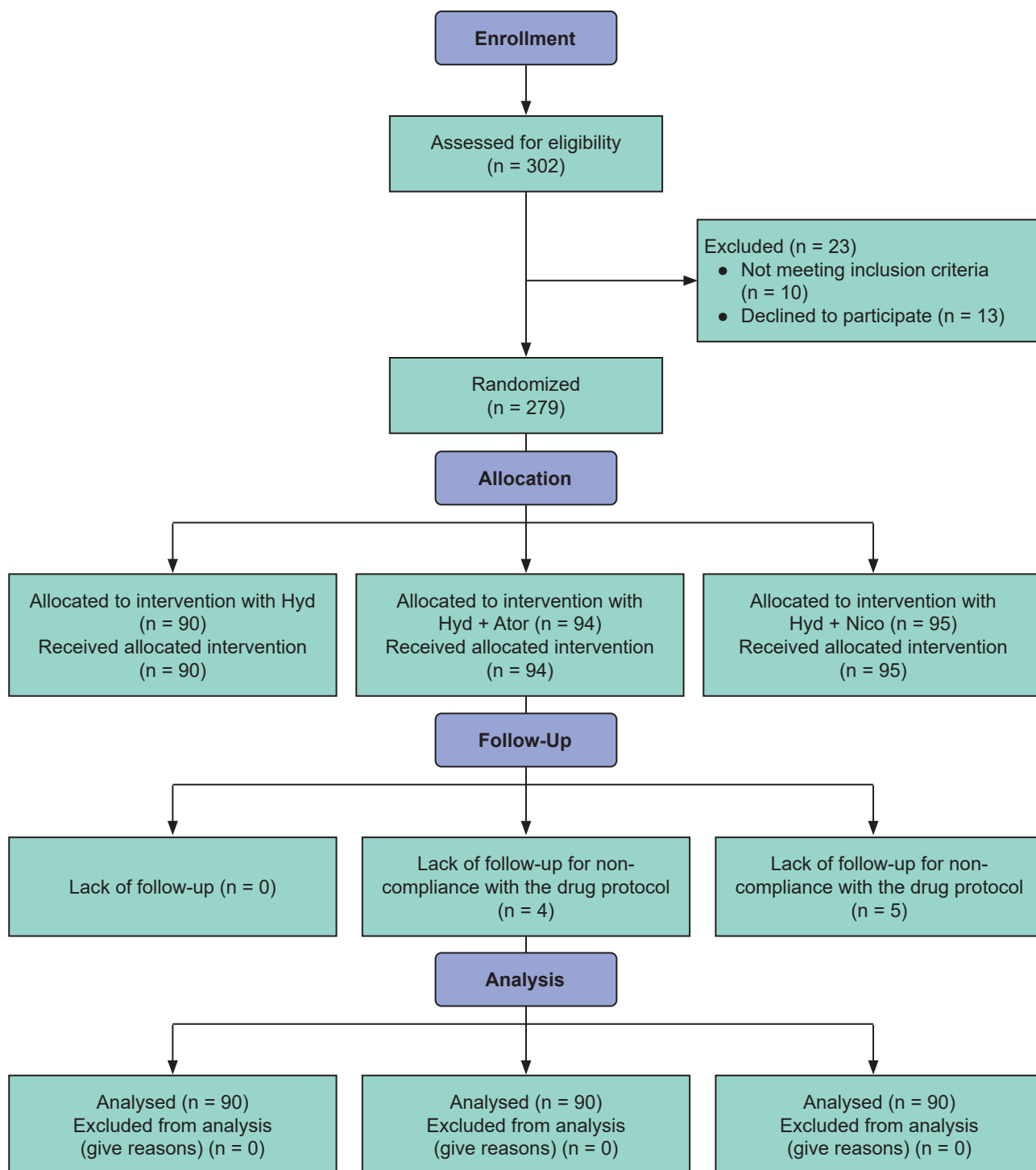


Figure 1. Flow Diagram of the Trial (Abbreviations: Hyd, hydration; Ator, atorvastatin; Nico, nicorandil)

Outcomes and Relevant Measures

Primary outcome was determination of serum creatinine and blood urea nitrogen (BUN) levels, and the secondary outcome was GFR calculation in the study groups.

Demographic and Clinical Assessments Questionnaire

Demographic information such as age and sex, as well as history of hypertension and diabetes mellitus were collected from all patients at the

beginning of the study. For the calculation of GFR the Cocroft-Galt formula was used.¹⁷

Biochemical Examinations

Before the intervention and 72 hours after the intervention 3 to 5 cc of blood samples were taken from all patients, and their serum was stored at 70 C for BUN and Cr analysis. Any increase in serum creatinine of ≥ 0.3 mg/dL within 72 hours after the procedure was defined as acute kidney injury (AKI) based upon the AKIN criteria or KDIGO guideline. Among patients who develop AKI after angiography, contrast-induced AKI (CI-AKI) was differentiated from athroembolism, ischemic ATN, interstitial nephritis, and prerenal azotemia by physical examination and taking history.

Sample Size Estimation

Using the sample volume calculation formula (two domains) for the clinical trial study, on the basis of previous studies,^{18,19} 90 participants were selected for each study group. The sample size was computed for each group of 90 participants based on the ratio of nephropathy in those who received atorvastatin and in the control group, which were 4.5% and 17.8%, respectively.

Statistical Analysis

The normal distribution of the data was determined from the Kolmogorov-Smirnov test. Parametric data were reported by using the mean \pm standard deviation (SD) and non-parametric data were reported by using the 25th to 75th percentiles. Paired t-test (parametric) and Wilcoxon (non-parametric) tests were used to analyze the data in each group pre- and post-intervention. Independent t-test and Mann-Whitney tests were used for comparing data between control and intervention groups. $P < .05$ was defined as

statistically significant. SPSS version 21 and Graph Pad Prism 7 software were used for the statistical analysis.

RESULTS

Characteristics of the Study Participants

The study parameters are summarized in Table. At the beginning of the study, there were no significant differences in age, sex, serum levels of BUN and Cr, GFR, history of hypertension and diabetes mellitus among the three groups.

Effects of Intervention on Serum Levels of BUN

At the end of the study, it was found that BUN levels in all three groups increased significantly compared to the beginning of the study ($P < .001$ for all, Figure 2A). Analysis of BUN levels at the end of the study showed that the increase in BUN in Hyd group was significantly higher compared with Hyd + Ator and Hyd + Nico groups ($P < .05$ and $P < .01$, respectively) (Figure 2B and 2C).

In fact, a significant difference was observed at the end of the study, but the average changes at the beginning and end of the study were not significantly different among the three groups.

Effects of Intervention on Serum Levels of Cr

At the end of the study, serum Cr levels in all three groups significantly increased compared with the beginning of the study ($P < .001$ for all, Figure 3A). In addition, after the intervention, the increase in serum Cr levels in the Hyd group was significantly higher than Hyd + Ator and Hyd + Nico groups ($P < .01$ for both, Figure 3B). In addition, the mean changes in serum Cr level in Hyd + Ator and Hyd + Nico groups were significantly lower than Hyd group ($P < .001$ for both, Figure 3C).

On the other hand, the results of our study

Table 1. Baseline Parameters in Study Groups

Variables	Hyd (n = 90)	Hyd + Ator (n = 90)	Hyd + Nico (n = 90)	P
Age, y	58.52 \pm 7.59	58.82 \pm 8.12	57.36 \pm 8.74	> .05
Sex, male, n (%)	54 (60)	54 (60)	57 (63.3)	> .05
Diabetic History, n (%)	38 (42.2)	41 (45.6)	46 (51.1)	> .05
Hypertension History, n (%)	63 (70)	52 (57.8)	52 (57.8)	> .05
BUN, mg/dL	33.89 \pm 11.44	32.40 \pm 14.50	31.19 \pm 12.85	> .05
Cr, mg/dL	2.09 \pm 1.03	2.02 \pm 1.13	2.08 \pm 1.18	> .05
GFR, mL/min/ 1.73m ²	44.28 \pm 13.43	45.13 \pm 13.83	44.79 \pm 13.30	> .05

Abbreviations: Cr, creatinine; BUN, blood urea nitrogen; GFR, glomerular filtration rate; Hyd, hydration; Ator, atorvastatin; Nico, nicorandil.

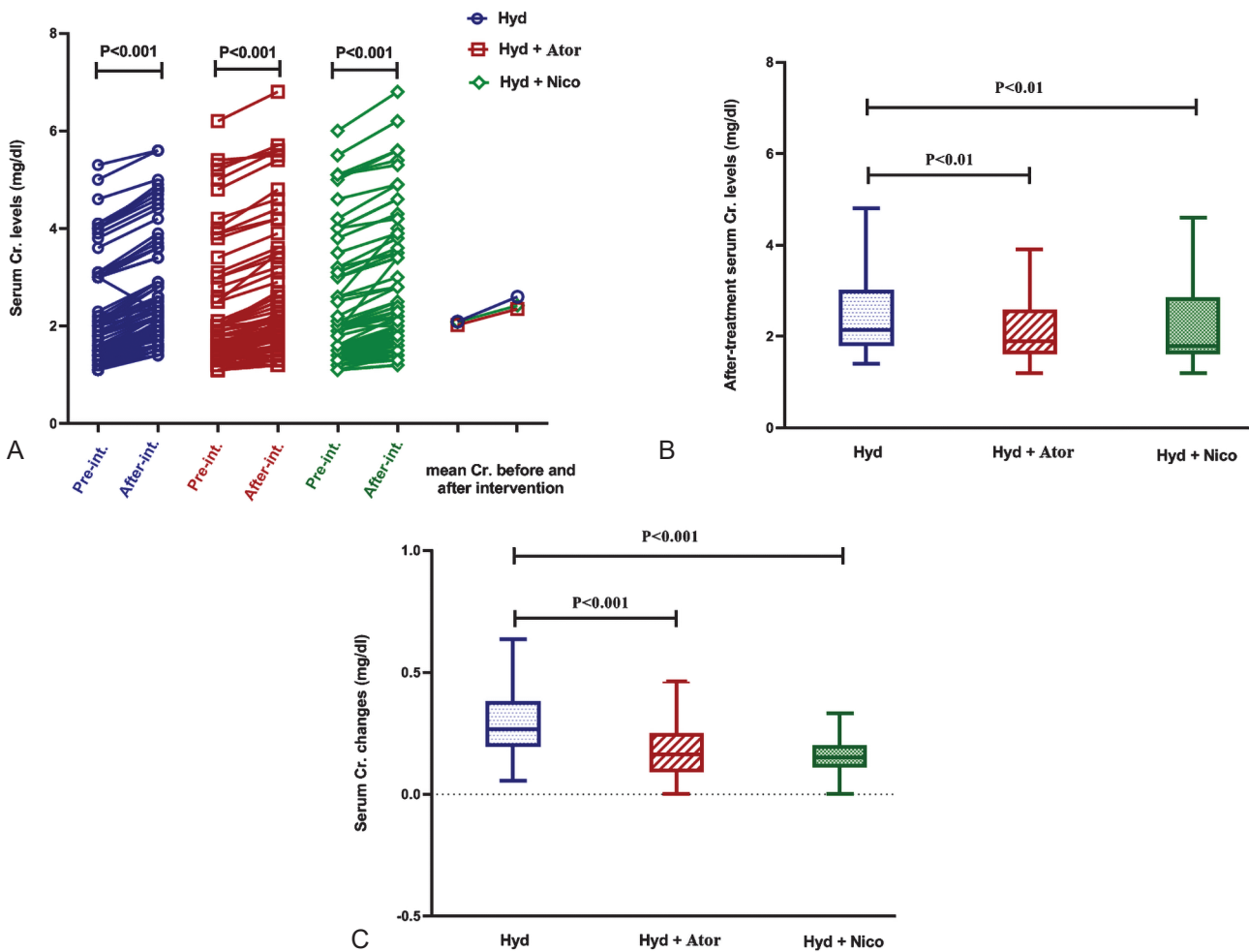


Figure 2. Individual values and mean of (A): serum Cr level, (B): serum Cr level differences between group at end of study, and (C): serum Cr level changes in Hyd. group (blue color), Hyd. + Ator group (red color), Hyd. + Nico (green color) group's pre-intervention and after 48 hours angiography-intervention (Abbreviations: Cr, creatinine; Hyd, hydration; Ator, atorvastatin; Nico, nicorandil; pre-int., pre-intervention; After-int., after-intervention)

revealed that the percentage of Cr changes in the Hyd + Ator (18.14 ± 13.15) and Hyd + Nico (17.34 ± 12.06) groups were significantly lower than the Hyd group (33.19 ± 24.42 , for both $P < .001$), but no significant difference was seen between the Hyd + Nico and Hyd + Ator groups ($P > .05$).

Effects of Intervention on GFR Levels

The GFR significantly decreased in all three groups by the end of the study as compared with the beginning ($P < .001$ for all, Figure 4A). Interestingly, the decreased GFR level was more prominent in the Hyd group than in the Hyd + Ator and Hyd + Nico groups ($P < .01$ and $P < .001$, respectively) (Figure 4B). Changes in GFR at the beginning and at the end of the study were considered. Also, there was a significant decrease in the mean GFR

changes in the Hyd group compared to Hyd + Ator and Hyd + Nico groups ($P < .001$ for both, Figure 4C).

DISCUSSION

According to the results of our study, there was a significantly lower incidence of CIN among CKD patients who were required to have angiography, and who were given atorvastatin and nicorandil in addition to hydration than among those who only received hydration. In addition, atorvastatin was more effective than nicorandil in preventing severe CIN, but no statistically significant difference was noticed.

Contrast-induced acute kidney injury is a serious issue in patients with cardiovascular disorders, and it is even more perilous in those with concomitant

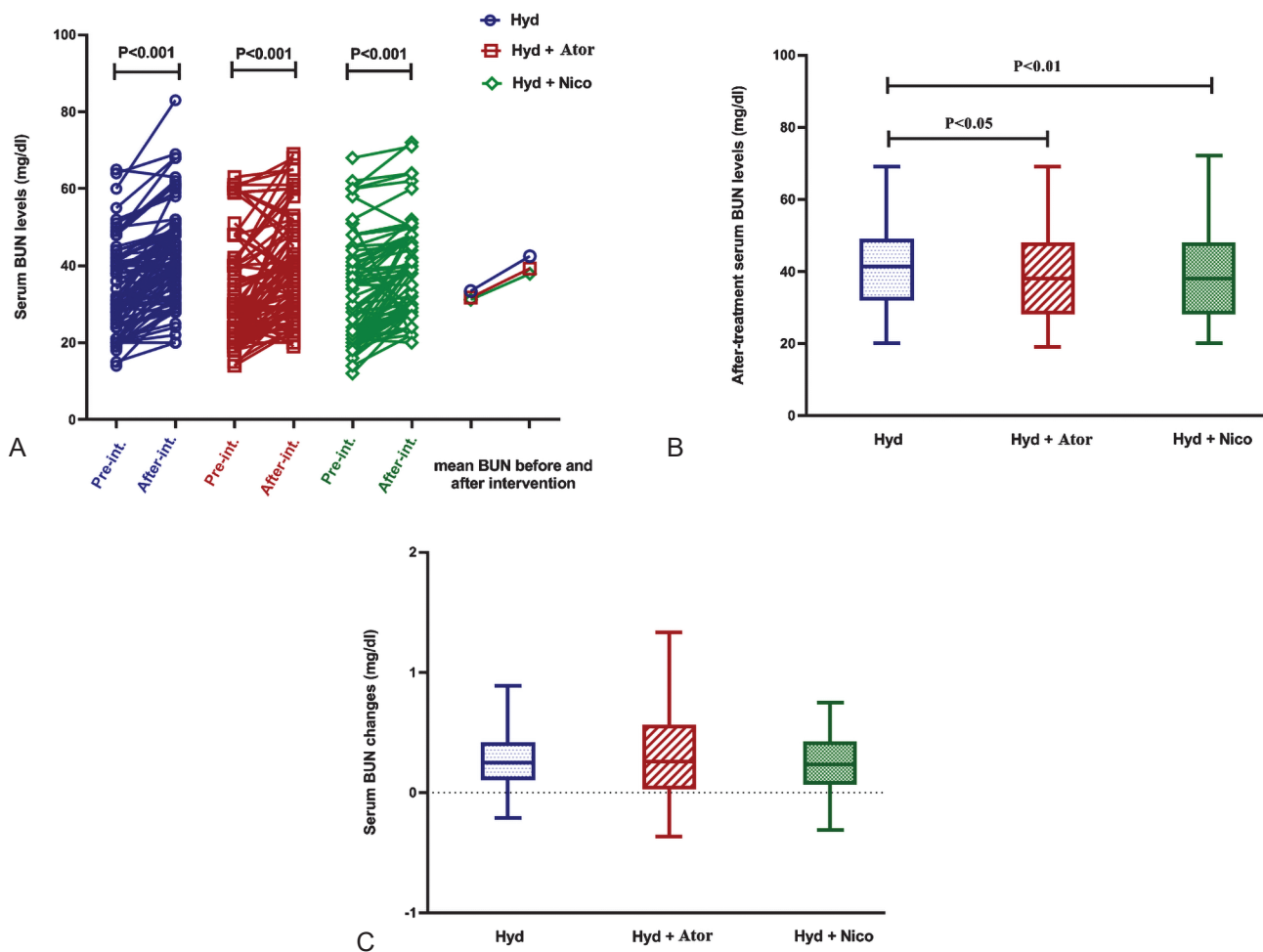


Figure 3. Individual values and mean of (A): BUN level, (B): BUN level differences between group at end of study, and (C): BUN level changes in Hyd. group (blue color), Hyd. + Ator group (red color), Hyd. + Nico (green color) group pre-intervention and after 48 hours angiography-intervention (Abbreviations: BUN, blood urea nitrogen; Hyd, hydration; Ator, atorvastatin; Nico, nicorandil; pre-int., pre-intervention; After-int., after-intervention)

CKD.²⁰ Although the cause of CIN is uncertain, it is believed that destruction of epithelial cells of the renal tubules as well as inadequate blood supply to the deeper parts of the outer medulla, may contribute to its emergence.^{12,21} According to research renal ischemia is significantly affected by both vasoconstricting agents (such as endothelin and adenosine) and vasodilating agents (such as nitric oxide and prostaglandin E2). It has been shown that the infusion of contrast agents can contribute to kidney ischemia, due to adenosine and a decreased NO synthase activity.²¹⁻²³ The secretion of endothelin and prostaglandins by endothelial cells could be the cause of limited blood flow and oxygen deprivation in the kidney, apart from infusion of contrast media only.²³ Other variables that could be associated with CIN are the

secretion of proinflammatory cytokines, imbalance between oxidant and antioxidant markers, and necrosis, obstruction of the renal tubules by protein.²⁴ Inspecting various pathophysiologic mechanisms of CIN, experiments utilizing hydration, statins, N-acetylcysteine, sodium bicarbonate, acetylcysteine, iloprost, trimetazidine, and nicorandil have been conducted to prevent it; however, they have yielded inconsistent results.^{13,25}

Nicorandil is a medication used to treat heart failure and angina due to its Nitric Oxide donor and ATP-sensitive potassium (K_{ATP}) channel-activating properties.²⁶ Nicorandil is administered as a preventative measure in patients with slow or absent coronary blood flow because of its ability to modify cardiac sympathetic nerve activity as well as microvascular circulation.²⁷ K_{ATP} channels

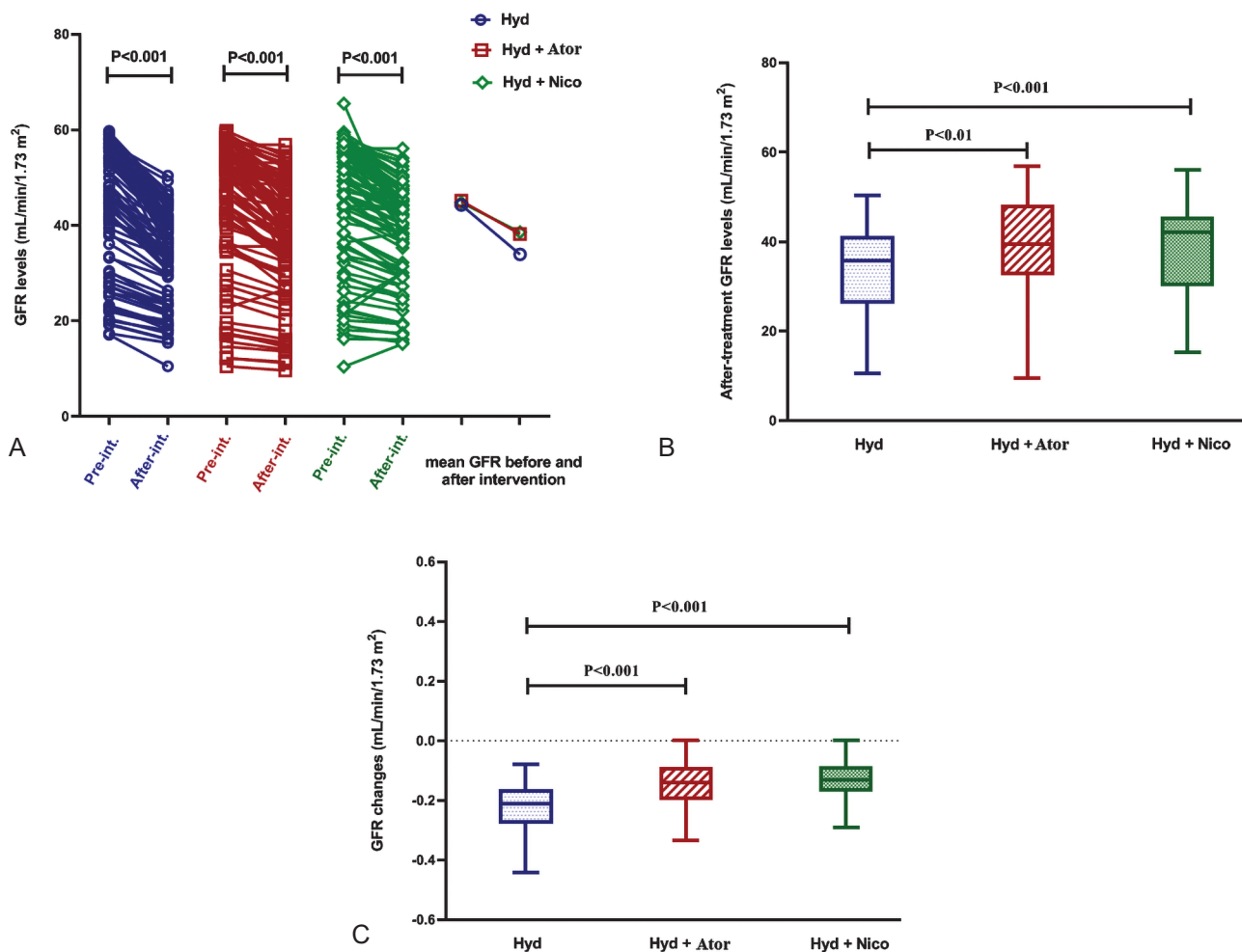


Figure 4. Individual values and mean of (A): GFR level, (B): GFR differences between group at end of study, and (C): GFR changes in Hyd. group (blue color), Hyd. + Ator group (red color), Hyd. + Nico (green color) group's pre-intervention and after 48 hours angiography-intervention (GFR: glomerular filtration rate (Abbreviations: Hyd, hydration; Ator, atorvastatin; Nico, nicorandil; pre-int., pre-intervention; After-int., after-intervention))

are widely distributed in a variety of tissues, including the kidneys that serve as sensors for the availability of oxygen and glucose in the metabolic changes in cells. Opening of K_{ATP} channels in the kidney amplifies renal blood flow and decreases the injury induced by hypoxia.²⁸ Shimizu *et al.* found that nicorandil may protect the kidney from ischemia-reperfusion trauma through diminishing the expression of K-ATP subunit KIR 6.2 in an animal study.²⁷ Studies have indicated that Nicorandil can reduce urinary protein production, resulting in a reduction of kidney injury²⁹ Numerous studies have been conducted to determine the role of nicorandil in preventing CIN, but more research is still needed to determine its advantageous impact. Some studies have reported beneficial effects of nicorandil on CIN, while others have not observed

any effect.^{15,30,31} This research demonstrated that a three-day administration of nicorandil along with hydration was effective in preventing CIN in individuals with kidney dysfunction, as compared to the control group who received hydration only. Nicorandil administration notably prevented the rise in serum Cr and BUN concentrations as well as diminishing GFR values, after a two-day angiographic intervention.

It has been reported that the generation of reactive oxygen species (ROS) is a concern in the pathogenesis of CIN, as it activates the p38 and Jun N-terminal kinase (JNK) ½ pathways.^{32,33} Several investigations have confirmed that using antioxidants can decrease CIN damage by neutralizing ROS.¹⁸ Other studies have demonstrated that statins, which inhibit 3-hydroxy-

3-methyl-glutaryl-CoA reductase, are effective in suppressing the proliferation of smooth muscle cells, inhibiting platelet aggregation, improving endothelial function, reducing inflammation, and modulating the oxidants/antioxidant balance.³⁴ Numerous studies have researched the prophylactic effects of atorvastatin against CIN, but the findings demand more reliability and are not conclusive; they need more certainty due to the conflicting results.³⁵⁻³⁷ Although some research indicated that atorvastatin had no effect on CIN prevention, other studies have demonstrated positive outcomes.^{36,37} The results of the current study demonstrated that taking atorvastatin and proper hydration for three days before receiving contrast media markedly prevented CIN. Indeed, atorvastatin effectively prevented a substantial increase in serum Cr and BUN levels and a decrease in GFR levels. This finding is consistent with the results of previous studies.¹⁸

In this study the preventive effects of nicorandil and atorvastatin on the development of CIN in CKD patients following angiography were investigated for the first time. Although both nicorandil and atorvastatin significantly prevented CIN, no significant difference was observed between the two groups. Although the benefits of atorvastatin compared to nicorandil were somewhat evident, no significant difference was observed between the two drugs. The efficacy of atorvastatin has been reported to be time dependent. In vitro studies in contrast media (CM) treatment of kidney cells have shown that incubation for more than 12 hours with atorvastatin increased survival and decreased death signals.¹⁸

LIMITATIONS OF THE STUDY

Firstly, the results of this study may only be applicable to patients who met the inclusion and exclusion criteria, and patients with moderate to severe kidney dysfunction. Because this study included atorvastatin and nicorandil in addition to hydration, the findings could be attributed not just to the effects of these two medications, but also to the impact of hydration, which can be addressed in conjunction with these drugs. Finally, some studies have shown that the beneficial effects of statins in combination with other drugs such as N-acetylcysteine are very evident, which requires further studies.

CONCLUSION

Contrast-induced nephropathy is a major problem in patients undergoing angiography, especially patients with kidney dysfunction. This study showed that nicorandil, and atorvastatin, could prevent CIN. Both agents prevented the increase in Cr and BUN levels, and the decrease in GFR levels. There was no significant difference between the two medications in terms of beneficial protective effects on CIN. Using statins for a longer period looks more advantageous; however, further research is required to confirm their beneficial effects.

DECLARATIONS

Ethics Approval and Informed Consent

This study was performed in accordance with the Declaration of Helsinki and was approved by the ethics committee of Ardabil University of Medical Sciences (IR.ARUMS.REC.1399.013). It was registered in the Iranian Registration of Clinical Trials (IRCT20150808023559N22). Written informed consent was secured from all the study participants.

Consent for Publication

Not applicable.

Availability of Data and Materials

The data set generated and/or analyzed during the current study are not available to the public due to non-disclosure policy of the university, but are available at the reasonable request from the corresponding author.

Competing Interests

The authors have declared that there is no conflict of interest.

FUNDING

Ardabil University of Medical sciences

AUTHORS' CONTRIBUTION

BB and SM: Literature search, Proposal writing, Data collection, Data Analysis, Data Interpretation, Manuscript preparation, Manuscript Review

EA and SH: Proposal writing, Data Analysis, Draft preparation, Manuscript Review

ACKNOWLEDGMENT

The authors would like to thank the staff of the

CAT Lab of Ardabil Imam Khomeini Hospital and all the study participants.

REFERENCES

- Rudnick MR, Leonberg-Yoo AK, Litt HI, et al. The Controversy of Contrast-Induced Nephropathy With Intravenous Contrast: What Is the Risk? *Am J Kidney Dis.* 2020; 75(1):105-113.
- Hossain MA, Costanzo E, Cosentino J, et al. Contrast-induced nephropathy: Pathophysiology, risk factors, and prevention. *Saudi J Kidney Dis Transpl.* 2018; 29(1):1-9.
- Sun G, Chen P, Wang K, et al. Contrast-Induced Nephropathy and Long-Term Mortality After Percutaneous Coronary Intervention in Patients With Acute Myocardial Infarction. *Angiology.* 2019; 70(7):621-626.
- Caspi O, Habib M, Cohen Y, et al. Acute Kidney Injury After Primary Angioplasty: Is Contrast-Induced Nephropathy the Culprit? *J Am Heart Assoc.* 2017; 6(6).
- Yang JS, Peng YR, Tsai SC, et al. The molecular mechanism of contrast-induced nephropathy (CIN) and its link to in vitro studies on iodinated contrast media (CM). *Biomedicine (Taipei).* 2018; 8(1):1.
- Do C. Intravenous Contrast: Friend or Foe? A Review on Contrast-Induced Nephropathy. *Adv Chronic Kidney Dis.* 2017; 24(3):147-149.
- Lin J, Chen J, Wu D, et al. Biomarkers for the early prediction of contrast-induced nephropathy after percutaneous coronary intervention in adults: A systematic review and meta-analysis. *Angiology.* 2022; 73(3):207-217.
- Brinjikji W, Demchuk AM, Murad MH, et al. Neurons Over Nephrons: Systematic Review and Meta-Analysis of Contrast-Induced Nephropathy in Patients With Acute Stroke. *Stroke.* 2017; 48(7):1862-1868.
- Grossman PM, Ali SS, Aronow HD, et al. Contrast-induced nephropathy in patients undergoing endovascular peripheral vascular intervention: Incidence, risk factors, and outcomes as observed in the Blue Cross Blue Shield of Michigan Cardiovascular Consortium. *J Interv Cardiol.* 2017; 30(3):274-280.
- Windpessl M, Kronbichler A. Pro: Contrast-induced nephropathy-should we try to avoid contrast media in patients with chronic kidney disease? *Nephrol Dial Transplant.* 2018; 33(8):1317-1319.
- Zhang F, Lu Z, Wang F. Advances in the pathogenesis and prevention of contrast-induced nephropathy. *Life Sci.* 2020; 259:118379.
- Persson PB, Hansell P, Liss P. Pathophysiology of contrast medium-induced nephropathy. *Kidney Int.* 2005; 68(1):14-22.
- Azzalini L, Spagnoli V, Ly HQ. Contrast-Induced Nephropathy: From Pathophysiology to Preventive Strategies. *Can J Cardiol.* 2016; 32(2):247-255.
- Xu R, Tao A, Bai Y, et al. Effectiveness of N-Acetylcysteine for the Prevention of Contrast-Induced Nephropathy: A Systematic Review and Meta-Analysis of Randomized Controlled Trials. *J Am Heart Assoc.* 2016; 5(9).
- Zhang P, Li WY, Yang SC, et al. Preventive Effects of Nicorandil Against Contrast-Induced Nephropathy in Patients With Moderate Renal Insufficiency Undergoing Percutaneous Coronary Intervention. *Angiology.* 2020; 71(2):183-188.
- Syed MH, Khandelwal PN, Thawani VR, et al. Efficacy of Atorvastatin in Prevention of Contrast-induced Nephropathy in High-risk Patients Undergoing Angiography: A Double-blind Randomized Controlled Trial. *J Pharmacol Pharmacother.* 2017; 8(2):50-53.
- Gault MH, Longerich LL, Harnett JD, et al. Predicting glomerular function from adjusted serum creatinine. *Nephron.* 1992; 62(3):249-256.
- Quintavalle C, Fiore D, De Micco F, et al. Impact of a high loading dose of atorvastatin on contrast-induced acute kidney injury. *Circulation.* 2012; 126(25):3008-3016.
- Iranirad L, Sadeghi MS, Bagheri A, et al. Allopurinol prophylactic therapy and the prevention of contrast-induced nephropathy in high-risk patients undergoing coronary angiography: A prospective randomized controlled trial. *ARYA Atheroscler.* 2017; 13(5):230-235.
- Mehran R, Aymong ED, Nikolsky E, et al. A simple risk score for prediction of contrast-induced nephropathy after percutaneous coronary intervention: development and initial validation. *J Am Coll Cardiol.* 2004; 44(7):1393-1399.
- Tumlin J, Stacul F, Adam A, et al. Pathophysiology of contrast-induced nephropathy. *Am J Cardiol.* 2006; 98(6a):14k-20k.
- Brezis M, Heyman SN, Dinour D, et al. Role of nitric oxide in renal medullary oxygenation. Studies in isolated and intact rat kidneys. *J Clin Invest.* 1991; 88(2):390-395.
- Myers SI, Wang L, Liu F, et al. Iodinated contrast induced renal vasoconstriction is due in part to the downregulation of renal cortical and medullary nitric oxide synthesis. *J Vasc Surg.* 2006; 44(2):383-391.
- Ozkok S, Ozkok A. Contrast-induced acute kidney injury: A review of practical points. *World journal of nephrology.* 2017; 6(3):86.
- Ellis JH, Cohan RH. Reducing the risk of contrast-induced nephropathy: a perspective on the controversies. *AJR Am J Roentgenol.* 2009; 192(6):1544-1549.
- Taira N. Nicorandil as a hybrid between nitrates and potassium channel activators. *Am J Cardiol.* 1989; 63(21):18j-24j.
- Shimizu S, Saito M, Kinoshita Y, et al. Nicorandil ameliorates ischaemia-reperfusion injury in the rat kidney. *Br J Pharmacol.* 2011; 163(2):272-282.
- Sun Z, Zhang X, Ito K, et al. Amelioration of oxidative mitochondrial DNA damage and deletion after renal ischemic injury by the KATP channel opener diazoxide. *Am J Physiol Renal Physiol.* 2008; 294(3):F491-498.
- Tamura Y, Tanabe K, Kitagawa W, et al. Nicorandil, a K(atp) channel opener, alleviates chronic renal injury by targeting podocytes and macrophages. *Am J Physiol Renal Physiol.* 2012; 303(3):F339-349.
- Fan Y, Wei Q, Cai J, et al. Preventive effect of oral nicorandil on contrast-induced nephropathy in patients with renal insufficiency undergoing elective cardiac catheterization. *Heart Vessels.* 2016; 31(11):1776-1782.

31. Ko YG, Lee BK, Kang WC, et al. Preventive effect of pretreatment with intravenous nicorandil on contrast-induced nephropathy in patients with renal dysfunction undergoing coronary angiography (PRINCIPLE Study). *Yonsei Med J.* 2013; 54(4):957-964.
32. Lee HC, Sheu SH, Yen HW, et al. JNK/ATF2 pathway is involved in iodinated contrast media-induced apoptosis. *Am J Nephrol.* 2010; 31(2):125-133.
33. Quintavalle C, Brenca M, De Micco F, et al. In vivo and in vitro assessment of pathways involved in contrast media-induced renal cells apoptosis. *Cell Death Dis.* 2011; 2(5):e155.
34. Davignon J. Beneficial cardiovascular pleiotropic effects of statins. *Circulation.* 2004; 109(23_suppl_1):III-39-III-43.
35. Zhang T, Shen LH, Hu LH, et al. Statins for the prevention of contrast-induced nephropathy: a systematic review and meta-analysis. *Am J Nephrol.* 2011; 33(4):344-351.
36. Khanal S, Attallah N, Smith DE, et al. Statin therapy reduces contrast-induced nephropathy: an analysis of contemporary percutaneous interventions. *Am J Med.* 2005; 118(8):843-849.
37. Jo SH, Koo BK, Park JS, et al. Prevention of radiocontrast medium-induced nephropathy using short-term high-dose simvastatin in patients with renal insufficiency undergoing coronary angiography (PROMISS) trial—a randomized controlled study. *Am Heart J.* 2008; 155(3):499.e491-498.

Correspondence to:
Behzad Babapour, MD
Department of Cardiology, Faculty of Medicine, Ardabil
University of Medical Sciences, Ardabil, Iran
Tel: 0098 453 325 1401
Fax: 0098 453 325 1401
E-mail: b.babapoursaatlou@arums.ac.ir

Received March 2023
Revised May 2023
Accepted May 2023