

# Comparison of Two Methods for Upper Lid Fascia Lata Sling in Congenital Blepharoptosis: a Randomized Clinical Trial

Abbas Bagheri MD, Maryam Aletaha MD, Hossein Saloor MD, Shahin Yazdani MD.

Shaheed Beheshti Medical University, Tehran, Iran

**Purpose:** To compare the results of two different methods of upper lid sling with autogenous fascia lata in the treatment of congenital ptosis.

**Methods:** In a randomized clinical trial, patients with congenital upper lid ptosis and poor levator function ( $<4\text{mm}$ ) were randomly assigned to two different methods of upper lid sling: group A, bitriangular fascia sling (modified Crawford method) and group B, monotriangular fascia sling (modified Fox method).

**Results:** This study included 30 upper eyelids (15 eyelids in each surgical group) of 19 patients (8 unilateral and 11 bilateral cases) with congenital ptosis. Mean increase in eyelid fissure height was  $2.7\pm 2.3$  mm in group A and  $3.4\pm 2.2$  mm in group B, respectively. Change in eyelid fissure in both groups was significant ( $P<0.001$ , paired t-test) but intergroup difference was not ( $P=0.4$ , independent sample t-test). Early complications such as corneal epithelial defects and entropion, and late complications such as undercorrection were comparable in the two groups. No patient experienced recurrent ptosis requiring reoperation in either group.

**Conclusion:** The monotriangular method of upper lid fascia sling can be used instead of the more popular bitriangular method. Advantages include less need for fascial tissue, less periocular scar formation and a shorter period of anesthesia.

*Iranian J Ophthalmic Res* 2006; 1 (2): 85-91.

**Correspondence to:** Abbas Bagheri, MD. Associate Professor of Ophthalmology; Ophthalmic Research Center, Labbafinejad Medical Center, Boostan 9 St., Pasdaran Ave., Tehran 16666, Iran; Tel: +98 21 22584733, Fax: +98 21 22562138, e-mail: abbasbagheri@yahoo.com

## INTRODUCTION

Blepharoptosis surgery is one of the most common oculoplastic procedures; the aim of which is to clear the visual axis, reducing amblyopia in young patients and improving superior visual fields in adult patients. The secondary goal is to improve appearance by producing symmetric lid crease and contour in the upper lids. The choice of surgical procedure depends on the function of levator muscles; with weak

levator function, the classic approach is to sling the upper lid(s) to the frontalis muscle by an exogenous or autogenous material.<sup>1-6</sup> However, supermaximum levator resection or Whitnall's ligament sling has been used by some surgeons<sup>7,8</sup> and reverse use of protractor muscles (frontalis and orbicularis oculi) as retractors is recommended by others.<sup>9,10</sup>

Different materials have been used for eyelid sling, the most popular exogenous ones are silicone rod,<sup>11,12</sup> mersilene mesh,<sup>13-18</sup> supramid<sup>19</sup>

and Gore-Tex;<sup>20</sup> the most commonly used endogenous materials are preserved<sup>21-23</sup> or fresh<sup>24</sup> fascia lata and fascia temporalis,<sup>25</sup> even though autogenous palmaris longus tendon<sup>26</sup> and umbilical vein<sup>27</sup> have also been used. Autogenous fascia lata is the preferred material because of its low rate of complications<sup>28,29</sup> and long term viability and compatibility.<sup>30</sup> There is no general agreement on the method of sling; single, double rhomboid, pentagon or triangular methods can be used.<sup>1-5</sup> Some believe that the monotriangular method is best for peaked brows and the pentagon or rhomboid type is preferred for diffuse elevated brows.<sup>5</sup> Others recommend monotriangular (modified Fox method) for children and bitriangular (modified Crawford method) for adults.<sup>1</sup>

This study was designed as a prospective randomized clinical trial to compare two different methods of upper lid sling with autogenous fascia lata in the treatment of congenital upper lid ptosis with poor levator function.

## METHODS

Patients with unilateral or bilateral congenital upper lid ptosis who were referred to the ophthalmic service from July 2003 to December 2004 and fulfilled the criteria for sling surgery with autogenous fascia lata were randomly allocated to one of two surgical groups. Inclusion criteria included weak levator function (<4 mm) and age over 4 years for adequate harvestable autogenous fascia lata. Exclusion criteria included weak Bell's phenomenon (less than 50% of normal), positive phenylephrine test, jaw winking phenomenon, blepharophimosis syndrome, systemic or myopathic disorders with secondary ptosis such as myotonic dystrophy, myasthenia gravis, chronic progressive external ophthalmoplegia, and Graves disease, history of intra or extra ocular and eyelid surgery, sharp or blunt trauma to the eyelids, eyelid tumors and scars.

A complete examination including cyclorefraction, best corrected visual acuity, biomicroscopic evaluation of the lacrimal meniscus, extraocular movements, pupillary reactions and

corneal sensation was performed. Ptosis examination included: lid fissure height, eyelid crease height, upper lid margin-reflex distance (MRD<sub>1</sub>), lower lid margin-reflex distance (MRD<sub>2</sub>), scleral show, levator function, lagophthalmos, jaw winking and Bell's phenomenon (4+ implies complete disappearance of the cornea and zero corresponds to absence of Bell's phenomenon).

The ethics committee of the ophthalmic research center approved this study and informed consent was obtained from all patients or their guardians. All patients were operated under general anesthesia by a single surgeon (AB). Margin-reflex distance (MRD<sub>1</sub>) and eyelid fissure height were documented 1, 6, 12 and 24 weeks after the procedures. Face photographs were taken before the operation and at the same postoperative intervals. Any complication including epithelial defect, overcorrection, undercorrection, granuloma formation, fascia exposure and suture abscess were documented. Thigh scar and any abnormalities in gait were also evaluated.

## Surgical Technique

With the knee and hip in flexion on one side, the thigh was fixed with leukoplast adhesive to both sides of the surgical table and an 8 cm incision was produced in the skin and subcutaneous tissues on the lateral thigh starting about 6 cm above the lateral femoral condyle and extending toward the anterior superior iliac spine. Subcutaneous fat was undermined above and below the incision and strips of fascia lata, 12 cm in length and 3-12 mm in width were harvested according to surgical technique and the number of lids to be operated. Fascial strips were cleaned from unwanted tissues and cut to 3 mm strips.

## Group A

Two 3 mm incisions were made above the brow parallel to the medial and lateral canthus and deepened to reach the frontal periosteum. Three 3 mm incisions were also made on the


upper lid 2 mm above the eyelashes; the first one in the central upper lid and the other two 10 mm on either side. Fascia lata stringing was performed as in figure 1A and the two ends of the fascia were tied at the two sites above the brow. After adjustment of eyelid height at the limbus, the fascia knots were sutured with 5-0 Prolene and buried in the frontalis muscle and finally the skin was repaired with 6-0 Prolene.

**Group B**

A single 3 mm incision similar to group A was produced in the center of the brow. Two 3 mm incisions also were produced on the upper lid 2 mm above the eyelashes 10 mm apart (5 mm

from the center of upper lid on either side). Fascia lata stringing was performed with Wright needle as in figure 1B and the two free ends of fascia were tied and sutured as described above. Skin repair was also similar to group A.

After completion of the procedure in both groups, a 4-0 silk frost suture was inserted in the center of the lower lid to prevent corneal exposure and eye was patched with gentamicin ointment for 6 hours. The patients received oral cephalixin for 5 days. The frost sutures were removed after 24 hours if the corneal epithelium was intact; in case of an epithelial defect simple eye ointment was prescribed every 6-8 hours and the frost suture was removed after complete epithelial healing.



**Figure 1** Schematic presentation of fascia sling: (A) Bitriangular (modified Crawford) method, (B) Monotriangular (modified Fox) method.

**RESULTS**

From July 2003 to December 2004, 8 patients with unilateral and 11 patients with bilateral ptosis were enrolled in this study. Fifteen eyelids of 10 patients and 15 eyelids of 9 patients were randomized to groups A and B, respectively (Tables 1&2). Mean age was 14.2±8.4 (range 4-26) years and 17.8±13.3 (range 4-48) years in groups A and B, respectively. Age and sex distributions in both groups were comparable. Mean follow up was 15.1±6.8 (range 9-29) months and 15.7±5.4 (range 10-26) months in

groups A and B, respectively. Mean operative time for each eyelid (not including the time needed for harvesting fascia lata) was 29.9±2.3 and 16.5±1.7 minutes in groups A and B, respectively (t-test, P=0.0001).

Mean preoperative lid fissure height in group A was 6.5±1.6 mm which increased to 9.3±1.3 mm after the operation. Corresponding figures for group B were 7.2±2.3 mm and 10.6±1.4 mm, respectively. Lid fissure height increased by 2.7±2.3 mm in group A and 3.4±2.2 mm in group B. Changes in lid fissure in both groups were statistically significant (paired t-

test,  $P < 0.001$ ) but the inter-group difference was not (t-test,  $P = 0.4$ ).  $MRD_1$  increase was  $2.7 \pm 1.3$  mm in group A and  $3 \pm 1.1$  mm in group B (t-test,  $P = 0.6$ ) (Figures 2&3).

Short term complications in group A included corneal epithelial defects in 7 eyes (46.7%), entropion in 2 eyelids (13.3%); long-term complications included mild ( $\leq 1$  mm) undercorrection in 2 eyelids (13.3%). Short term complications in group B included corneal epithelial defects in 3 eyes (20%), entropion in 2 eyelids (13.3%) and wound dehiscence in one case (6.7%). Long term complications included mild ( $\leq 1$  mm) undercorrection in 2 eyelids (13.3%). No statistically significant difference in complications was observed between the groups.

The eyelid margins were symmetric in all patients and remained so at all follow up visits.

Ten lids in group A (66.7%) and 12 in group B (80%) required trimming of the upper lid skin (upper lid blepharoplasty) for crease formation 6 months after surgery. No patient needed re-operation for recurrent ptosis. One week after operation no patient had any complaint in gait and the thigh wound healed after 2 weeks.

**DISCUSSION**

Blepharoptosis surgery is a challenging area in oculoplastic surgery. This procedure can prevent amblyopia by opening the visual axis in congenital or early onset ptosis. Improvement of the superior visual field and reduction of astigmatism are other goals. The subsidiary goal of this procedure is to obtain natural appearing and symmetric eyelids.

**Table 1** Characteristics of patients in group A (double triangular).

No.	Sex	Age	Laterality	Eye	Lid fissure (mm) before /after	$MRD_1$ (mm) before /after	Short term complications	Long term complications	Complementary operation	F/U (month)
1	M	15	OU	R L	5/9 5/8	1/3 1/2	PEE	D D-Under	B B	29
2	M	22	OU	R L	4/10 5/10	3/2 -1/2	CED	D D	B B	26
3	M	26	OD	R L	5/9 10/10	1/3 4/4	Entropion-CED	D-Under	B	16
4	F	16	OU	R L	8/10 8/10	0/3 0/3	PEE	D D	B B	13
5	F	6	OS	R L	10/10 5/10	3/3 -1/3	PEE	.	.	12
6	M	25	OU	R L	6/10 8/10	1/3 1/3	PEE	D D	B B	12
7	M	4	OU	R L	8/9 8/9	1/2 1/2	-	.	.	12
8	M	16	OS	R L	10/10 7/10	2/2 0/2	Entropion-PEE	D	B	11
9	F	8	OD	R L	7/10 10/10	0/3 3/3	PEE	.	.	11
10	F	4	OD	R L	5/9 10/10	2/3 3/3	PEE	.	.	9

MRD: marginal reflex distance, F/U: follow up, M: male, F: female, OU: binocular, OD: right eye, OS: left eye, R: right, L: left, D: dermatochalasis, B: blepharoplasty, PEE: punctate epithelial erosion, Under: undercorrection, CED: corneal epithelial defect

**Table 2** Characteristics of patients in group B (monotriangular).!

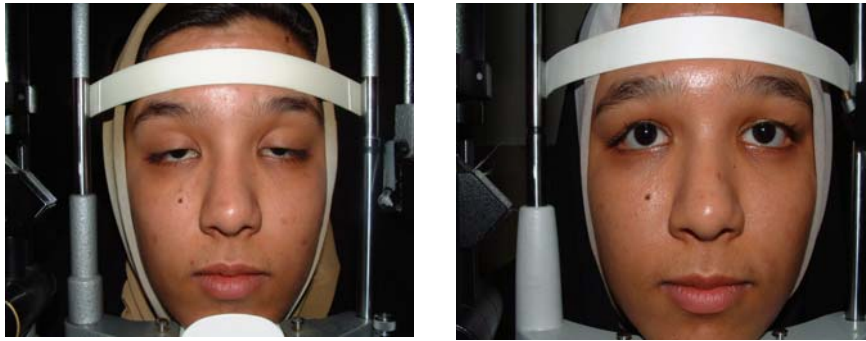
No.	Sex	Age	Laterality	Eye	Lid fissure (mm) before /after	MRD <sub>1</sub> (mm) before /after	Short term complications	Long term complications	Complementary operation	F/U (month)
1	M	48	OU	R L	9/12 9/12	2/6 2/6	!! .	D D	B B	26
2	F	23	OU	R L	6/9 7/9	0/4 1/4	!! !!	D D	B B	24
3	F	15	OU	R L	10/11 10/11	0/4 0/4	!! !!	D D	B B	16
4	M	12	OD	R L	8/12 12/12	0/2 2/2	Entropion- PEE !! !!	D -	B -	14
5	M	18	OU	R L	7/9 7/9	1/2 1/2	Wound dehiscence .	D D	Wound repair-B B	14
6	F	25	OU	R L	7/10 7/11	0/3 0/4	Entropion .	D-Under D	B B	13
7	M	6	OS	R L	9/9 3/8	3/3 -2/2	!! CED	!! D-Under	!! B	13
8	M	4	OD	R L	2/12 12/12	0/2 2/2	PEE -	!! !!	!! !!	12
9	M	10	OU	R L	7/12 9/12	1/3 0/3	- -	!! .	!! .	10

MRD: marginal reflex distance, F/U: follow up, M: male, F: female, OU: binocular, OD: right eye, OS: left eye, R: right, L: left, D: dermatochalasis, B: blepharoplasty, PEE: punctate epithelial erosion, Under: under-correction, CED: corneal epithelial defect

Different methods exist for correction of ptosis. Frontalis suspension is used when levator function is weak, especially in myogenic and neurogenic ptosis. In this method, frontalis power is transferred to the tarsus of the ptotic eye by a natural or synthetic material.<sup>1</sup> There are different methods and materials used for frontalis suspension but most authors agree that autogenous fascia lata is the best material and banked fascia is the next usable material.<sup>1-5</sup>

Common methods of sling include single rhomboid, double rhomboid and double triangular.<sup>1-5</sup> Smaili et al<sup>23</sup> have reported the results of sling with preserved fascia lata in a double triangular fashion on 132 eyelids of 72 patients. In all patients other than 3 cases, eyelid width was acceptable 6-15 years after surgery; in 20 cases (28%) reoperations were performed because of recurrent ptosis. Short term results were com-

parable to our patients. Broughton et al<sup>21</sup> performed double rhomboid sling with fascia lata on 50 eyelids and observed recurrent ptosis in 5 cases (10%) after 2 years. Other studies using fascia lata for upper lid sling have reported comparable results.<sup>23-24</sup> In our study two methods of upper lid sling using autogenous fascia lata were compared in a randomized clinical trial. Results and complications of the monotriangular and bitriangular methods were similar. In the monotriangular method, the operation was shorter and easier, less sling material (fascia lata) was needed and less eyelid skin wounds were produced. Theoretically, the chance of intraoperative complications like eyelid hematoma and damage to ocular soft tissues is less. The weakness of this study was the relatively small number of cases and limited follow up.



**Figure 2** A patient in group A (bitriangular) before (left) and after (right) the procedure (case number 4 in table 1)



**Figure 3** A patient in group B (monotriangular) before (left) and after (right) the procedure (case number 2 in table 2)

#### REFERENCES

- 1- Tyers AG, Collin J RO. Color atlas of ophthalmic plastic surgery. 2nd ed. Boston: Butterworth Heinemann; 2001: 133- 172.
- 2- Landa M, Bedrossian EH. Blepharoptosis. In: Della Rocca RC, Bedrossian Jr EH, Arthurs BP, eds. Ophthalmic plastic surgery decision making and techniques. New York: McGraw- Hill; 2002: 77-89.
- 3- Brindley GO. Congenital blepharoptosis. In: Stephenson CM, ed. Ophthalmic plastic reconstructive and orbital surgery. Boston: Butterworth – Heinemann; 1997: 117-135.
- 4- Chen WPD, Khan JA, McCord Jr CD. A color atlas of cosmetic oculofacial surgery. Philadelphia: Butterworth – Heinemann; 2004: 187-204.
- 5- Dresner S. Ptosis management: A practical approach. In: Chen WP, ed. Oculoplastic surgery the essentials. New York: Thieme; 2001: 75-88.
- 6- Custer PL. Ptosis: Levator muscle surgery and frontalis suspension. In: Chen WPD, ed. Oculoplastic surgery the essentials. New York: Thieme; 2001: 89-101.
- 7- Epstein G, Putterman A. Super-maximal levator resection for severe unilateral congenital blepharoptosis. *Ophthalmic Surg* 1984;15:971.
- 8- Leibsohn JM. Withnall's ligament eyelid suspension for severe blepharoptosis. *Ophthalmic Surg* 1987;18: 286-287.
- 9- Tsai CC, Lin TM, Lai CS, Lin SD. Use of orbicularis oculi muscle flap for under corrected blepharoptosis with previous frontalis suspension. *Br J Plast Surg* 2000;53:475-476.
- 10- Goldy SH, Baylis HI, Goldberg RA, Shorr N. Frontalis muscle flap advancement for correction of blepharoptosis. *Ophthalm Plast Reconstr Surg* 2000; 16:83-93.
- 11- Older JJ, Dunne PB. Silicone Slings for the correction of ptosis associated with progressive external ophthalmoplegia. *Ophthalmic Surg* 1984;15:379-381.
- 12- Carter SR, Meecham WJ, Seiff SR. Silicon frontalis slings for the correction of blepharoptosis. *Ophthalmology* 1996;103:623-630.
- 13- Hintschich CR, Zurcher M, Collin JRO. Mersilene mesh brow suspension: efficiency and

- complications. *Br J Ophthalmol* 1995;79:358-361.
- 14- Kemp EG, Mac Andie K. Mersilene mesh as an alternative to autogenous fascia lata in brow suspension. *Ophthalmic Plast Reconstr Surg* 2001;17:419-422.
  - 15- Gabrieli CB, Recuperero SM, Contostabile MT, Pacella E, Abdolrahimzadeh S. Fox's modified technique using the mersilene mesh sling in the management of blepharoptosis. *Ophthalmic Surg Laser* 1996; 27:924-8.
  - 16- EL-Toukhy E, Salaem M, EL-Shewy T, Abou-Steit M, Levine M. Mersilene mesh sling as an alternative to autogenous fascia lata in the management of ptosis. *Eye* 2001;15:178-182.
  - 17- Sternberg I, Seelenfreund MH, Sternberg N. A new sling material for ptosis patients. *Ophthalmic Surgery* 1988;19:64-66.
  - 18- Lam DS, Gandhi SR, Ng JS, Chen IN, Kwok PS, Chan GH. Early correction of severe unilateral infant ptosis with the mersilene mesh sling. *Eye* 1997;11:806-809.
  - 19- Katowitz JA. Frontalis suspension in congenital ptosis using a polyfilament, cable-type suture. *Arch Ophthalmol* 1979;97:1659-1663.
  - 20- Steinkogler FJ. A new material for frontal sling operation in congenital ptosis. *Klin Monatsbl Augenheilkd* 1987;191:361-363. [Abstract]
  - 21- Broughton WL, Matthews II JG, Harris Jr DJ. Congenital ptosis results of treatment using lyophilized fascia lata for frontalis suspension. *Ophthalmology* 1982;89:1261-1266.
  - 22- O'Reilly J, Lanigan B, Bowell R, O'Keefe M. Congenital ptosis: long-term results using stored fascia lata. *Acta Ophthalmol Scand* 1998;76:346-348.
  - 23- Esmaeli B, Chung H, Poshby R. Long-term results of frontalis suspension using irradiated banked fascia lata. *Ophthalm Plast Reconstr Surg* 1998;14:159-163.
  - 24- Reny A, George JL. Treatment of severe ptosis by suspension of the upper eyelid using the autogenic frontal muscle and fascia lata. Analysis of 34 interventions. *J Fr Ophthalmol* 1983;6:797-807. [Abstract]
  - 25- Kokot W, Poljanowski P. Suspending of blepharoptosis on temporalis fascia slings: our own experience. *Klin Oczna* 1998;100:393-395. [Abstract]
  - 26- Lam DSC, NG JSK, Cheng GPM, Li RTH. Autogenous palmaris longus tendon as frontalis suspension material for ptosis correction in children. *Am J Ophthalmol* 1998;126:109-115.
  - 27- Sternberg I, Seelenfreund MH, Sternberg N. A new sling material for ptosis patients. *Ophthalmic Surg* 1988;19:64-66.
  - 28- Wheatcroft SM, Vardy SJ, Tyers AG. Complications of fascia lata harvesting for ptosis. *Br J Ophthalmol* 1997;81:581-583.
  - 29- Naugle Jr TC, Fry CL, Sabatier RE, Elliott LF. High leg incision fascia lata harvesting. *Ophthalmology* 104:1480-1488.
  - 30- Orlando F, Weiss JS, Beyer- Machule CK, Albert DM, Shapiro A. Histopathologic condition of fascia lata implant 42 years after ptosis repair. *Arch Ophthalmol* 1985;103:1518-1519.