

Posterior Ischemic Optic Neuropathy following Herpes Zoster Ophthalmicus

Mohammad Pakravan, MD; Hamid Ahmadi, MD; Amir-Reza Kaharkaboudi, MD

Labbafinejad Medical Center, Shahid Beheshti University, MC, Tehran, Iran

Purpose: To report a case of posterior ischemic optic neuropathy (PION) following herpes zoster ophthalmicus (HZO).

Case Report: A 58-year-old woman with history of recent HZO in her right eye presented with acute painless loss of vision in the same eye to no light perception. Examination revealed a positive relative afferent pupillary defect and a normal appearing optic disc. Inflammatory and infiltrative lesions of the optic nerve were ruled out by laboratory and imaging studies. The patient received systemic acyclovir and prednisolone. Three months later, visual acuity improved to counting fingers, but the optic disc became pale and atrophic leading to a presumptive diagnosis of PION. Considering the positive PCR test for varicella zoster virus and the short time interval between the two presentations, HZO was considered as the most probable cause of the optic neuropathy.

Conclusion: Herpes zoster ophthalmicus can be associated with PION.

Key words: Optic Neuropathy, Ischemic; Herpes Zoster Ophthalmicus

J Ophthalmic Vis Res 2009; 4 (1): 59-62.

Correspondence to: Mohammad Pakravan, MD. Associate Professor of Ophthalmology; Ophthalmic Research Center, No. 5, Boostan 9 St., Amir Ebrahimi Ave., Pasdaran, Tehran 16666, Iran; Tel: +98 21 22585952, Fax: +98 21 22590607; e-mail: mopakravan@yahoo.com

Received: September 27, 2008

Accepted: November 15, 2008

INTRODUCTION

Posterior ischemic optic neuropathy (PION) is thought to occur following the occlusion of blood vessels supplying the optic nerve and occurs in three classic settings: arteritic, non-arteritic and postoperative.^{1,2} Arteritic PION occurs in the course of systemic inflammatory vascular diseases. The postoperative type follows certain procedures particularly those associated with significant systemic hypotension such as cardiovascular surgery or prolonged operations such as spinal cord surgery and even rarely following operations such as percutaneous nephrolithotomy. Non-arteritic PION is the most common type but the underlying causes remain elusive.¹⁻³

This case report describes a patient who developed PION following herpes zoster ophthalmicus (HZO). To our knowledge only one similar case has been reported in the literature.⁴

CASE REPORT

A 58-year-old female patient presented with sudden and painless loss of vision in her right eye. Past history was negative for systemic vasculopathic conditions such as diabetes mellitus, hyperlipidemia and systemic hypertension as well as smoking. The patient had been hospitalized due to HZO presenting with typical eyelid/skin rashes and keratouveitis in the same eye from 3 weeks before the onset of visual loss and received oral acyclovir, systemic and topi-

cal steroids and topical cycloplegics leading to improvement of the condition. On examination, the right eye had no light perception and +4 relative afferent pupillary defect (RAPD). Slit-lamp biomicroscopy disclosed mild punctate epithelial erosions, keratic precipitates, clear anterior chamber, sectoral iris atrophy, a dilated pupil and moderate lens opacity. A mild cellular reaction was present in the vitreous cavity, intraocular pressure was 22 mmHg and funduscopy revealed a normal appearing cup-less disc with normal vasculature, normal macula and normal peripheral retina (Fig. 1). The left eye had visual acuity of 20/25 and except for a mild cataract was otherwise unremarkable.

A presumptive diagnosis of PION was made but the patient was also evaluated for retrobulbar optic neuritis and infiltrative or mass lesions. After obtaining urgent imaging studies and checking for erythrocyte sedimentation rate (ESR), oral prednisolone (1 mg/kg/day), oral acyclovir (800 mg 4 times daily), and topical homatropine, sulfacetamide and prednisolone, each 4 times daily were initiated. Laboratory studies including blood urea nitrogen, serum creatinine, uric acid, lipid profile, thyroid stimulating hormone, thyroxine, triiodothyronine, aspartate aminotransferase, lactate dehydrogenase and creatine phosphokinase, were within normal limits. White blood cell count was 6,000 with 65% neutrophils, 27% lymphocytes, 7% monocytes and 1% eosinophils and ESR was 24 mm/hour. Serum polymerase chain reaction was negative for herpes simplex virus (types 1 and 2) DNA, but positive for herpes zoster virus (HZV) DNA. Fluorescein angiography was unremarkable. Color doppler echographic studies of the extracranial carotid arteries revealed lesions occluding 45% to 50% of the lumen bilaterally which were considered normal regarding the age of patient. Magnetic resonance imaging with and without contrast were obtained from the brain and orbit, which failed to show space occupying or infiltrative lesions. Visually evoked potentials disclosed decreased amplitude and delay in the P₁₀₀ wave in the right eye but was normal in the left eye.

Visual acuity in the involved eye demonstrated some improvement one month after

treatment and reached counting fingers, two months after the attack but remained unchanged up to 4 months thereafter. RAPD decreased slightly but remained +2 to +3. Six weeks after treatment funduscopy revealed a pale optic disc (Fig. 2). Four months after onset of visual loss the visual field was restricted to the central 10 degrees in the right eye (Fig. 3) but the left eye was normal. During follow-up, the involved eye developed mydriasis in a tonic pupil-like pattern which improved with time.

DISCUSSION

Ischemic optic neuropathy (ION) results from insufficient optic nerve perfusion leading to axonal necrosis and is classified as posterior (PION) or anterior (AION) based on the site of the lesion(s). The pathophysiologic mechanisms for these two types of ION differ from each other due to the different patterns of blood supply to the anterior and posterior parts of the optic nerve.^{5,6} The patient presented herein developed PION within a short time interval (3 weeks) following HZO. Patient age, positive serology for HZV, normal appearing optic disc at presentation and optic atrophy 6 weeks after visual loss, and lack of significant visual improvement are highly suggestive of PION.

PION consists of 3 subgroups including postoperative, arteritic and non-arteritic; the prognosis of the non-arteritic type is better than the other two variants.^{1,2,7,8} Our patient fulfilled all diagnostic criteria for PION including sudden and painless loss of vision associated with visual field defects, positive RAPD, lack of optic disc signs such as swelling or hemorrhage, development of optic atrophy 6-8 weeks after onset of disease and absence of compressive, infiltrative, toxic or inflammatory lesions in the optic nerve.^{1,2}

In one study, PION was associated with systemic hypertension (28%), diabetes mellitus (43%), smoking (36%), coronary heart disease (14%) and stroke (21%).⁷ Patients with PION should be evaluated for systemic vascular diseases, and occlusive or inflammatory vascular conditions such as giant cell arthritis. The patient presented herein was evaluated for such conditions and was found to be normal.

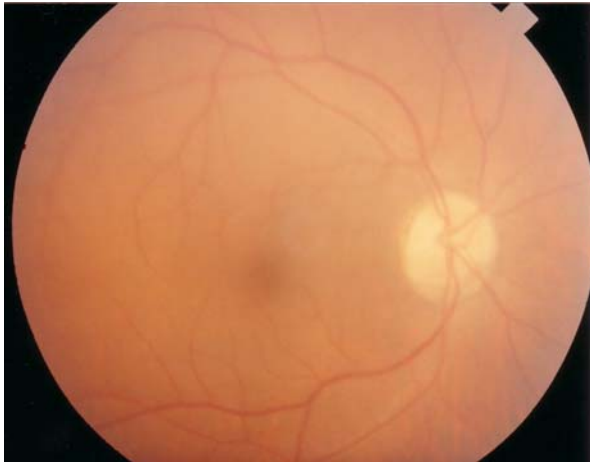

Figure 1 Fundus photograph of the right eye at presentation.

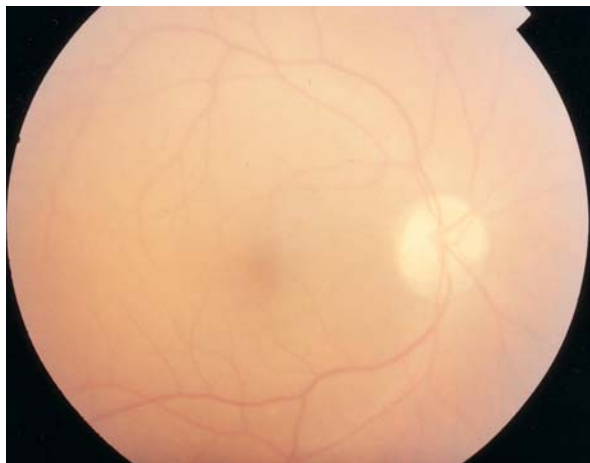


Figure 2 Fundus photograph of the same eye 6 weeks after onset of visual loss reveals optic atrophy.

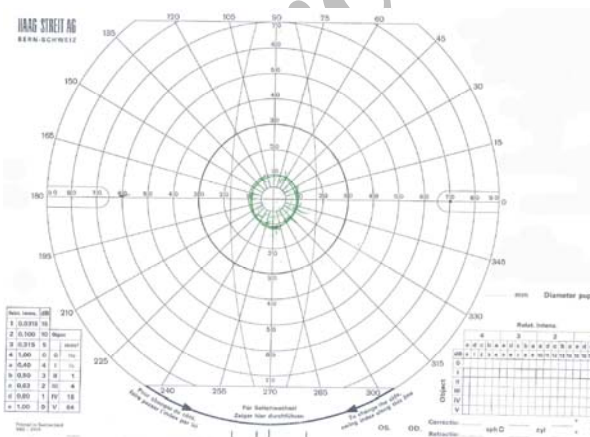


Figure 3 Visual field of the right eye 4 months after onset of visual loss; vision is restricted to the central 10 degrees.

Primary HZV infection causes varicella but reactivation of the virus results in zoster. Up to 90% of individuals aged 60 have serologic evidence of primary HZV infection but only 20% develop zoster.⁹ Immunosuppression, aging or concomitant illnesses increase the risk for reactivation of HZV. Although very rare, zoster may relapse in immunodeficient subjects.¹⁰ HZO results from reactivation of HZV in the first division of the trigeminal nerve and may involve the eye and periocular tissues with manifestations including vesicular eruptions on the forehead or upper lids, follicular or necrotizing conjunctivitis, extraocular muscle palsy and optic neuritis.¹¹ The mechanism of tissue damage is vasculitic inflammation and ischemia.¹²

Although one cannot definitely exclude optic neuritis in the presented case, considering our patient's age, lack of pain at onset and optic atrophy 6 weeks after onset, PION is most likely. Considering the fact that symptoms occurred a few days after HZO and that PCR was positive for HZV, we strongly suggest HZV as the cause of PION. To our knowledge this is the second report of PION following HZO.⁴

REFERENCES

1. Sadda SR, Nee M, Miller NR, Biousse V, Newman NJ, Konzis A. Clinical spectrum of posterior ischemic optic neuropathy. *Am J Ophthalmol* 2001;132:743-750.
2. Kelman SE. Ischemic optic neuropathies. In: Walsh & Hoy's. *Clinical Neuro-ophthalmology*. 5th ed. Philadelphia: Williams & Wilkins; 2005: 370-374.
3. Pakravan M, Kiavash V, Moradian S. One case of posterior ischemic optic neuropathy following transcatheter nephrolithotomy. *Bina J Ophthalmol* 2007; 11: 556-563.[Farsi]
4. Kothe AC, Flanagan J, Trevino RC. True posterior ischemic optic neuropathy associated with herpes zoster ophthalmicus. *Optom Vis Sci* 1990;67:845-849.
5. Hayreh SS. Posterior ischemic optic neuropathy. *Ophthalmologica* 1981;182:29-41.
6. Hayreh SS. The optic nerve head circulation in health and disease. *Exp eye Res* 1995;61:259-272.
7. Hayreh SS. Posterior ischemic optic neuropathy: clinical features, pathogenesis and management. *Eye* 2004;18:188-206.
8. Buono LM, Foroozan R. Perioperative posterior ischemic optic neuropathy review of the literature.

- Surv Ophthalmol* 2005;50:15-26.
9. Karbassi M, Raizman MB, Schuman JS. Herpes zoster ophthalmicus. *Surv Ophthalmol* 1992;36:395-410.
 10. Liesegang TJ. Corneal complication from herpes zoster ophthalmicus. *Ophthalmology* 1985;92:316-324.
 11. Gershon AA, Steinberg SP. Antibody responses to varicella zoster virus and the role of antibody in host defense. *Am J Med Sci* 1981;282:12-17.
 12. Liesegang TJ. Diagnosis and therapy of herpes zoster ophthalmicus. *Ophthalmology* 1991;98:1216-1229.

Archive of SID