

## Photo Essay

# Ultra-wide Field Fluorescein Angiography in Retinitis Pigmentosa with Intermediate Uveitis

Koushik Tripathy, MD; Rohan Chawla, FRCS; Pradeep Venkatesh, MD; Rajpal Vohra, MD  
Yog Raj Sharma, MS; Varun Gogia, MD; Shreyans Jain, MBBS; Alkananda Behera, MBBS

Department of Ophthalmology, Dr. Rajendra Prasad Centre for Ophthalmic Sciences, All India Institute of Medical Sciences, New Delhi, India

*J Ophthalmic Vis Res* 2016; 11 (2): 237-239.

### PRESENTATION

An 18-year-old man presented with a history of night blindness and decreased vision in both eyes. There was no family history of retinitis pigmentosa (RP). Best corrected visual acuity was 6/18 in his right eye and 6/24 in the left eye. On slit lamp examination, few pigmented keratic precipitates were seen in both eyes, with occasional anterior chamber cells. There were no cataracts, but retrolental cells were seen in both eyes. Intraocular pressure in both eyes was 16 mmHg. Both eyes showed mild disc pallor, pigment spicules around the equator, and inferior preretinal exudates [Figure 1].

Disc leakage and petaloid leakage in the macula were noted on ultra-widefield fluorescein angiograms (UWFA, Figure 2). Central macular thickness (CMT) based on optical coherence tomography (Cirrus HD-OCT, Carl Zeiss Meditec, Dublin, CA) was 500 microns in the right eye and 433 microns in the left eye [Figure 3] with intraretinal cystoid changes. Scotopic electroretinogram was extinguished, and the patient had a small visual field of 10° in both eyes. Chest

X-ray, hemogram, and angiotensin converting enzyme levels were normal, and VDRL and Mantoux tests were negative. A diagnosis of non-syndromic RP with intermediate uveitis and cystoid macular edema (CME) in both eyes was made.

The patient was started on oral prednisolone 1 mg/kg daily. Two weeks after therapy, the visual acuity improved to 6/9 in both eyes with resolution of CME. CMT was reduced to 282 microns in the right eye and 273 microns in the left eye, with marked decrease in cystic spaces.

### DISCUSSION

Ultra-widefield imaging and fluorescein angiography (UWFI and UWFA) have improved imaging of peripheral retinal disorders and uveitis cases.<sup>[1,2]</sup> The conventional fundus camera has a limited field of view, capturing 30° and 50° of the fundus in one frame. Using various montaging techniques, one can portray up to a maximum of 140°. UWFI (Optos Inc., Marlborough, MA, USA) employs dual wavelength scanning laser ophthalmoscopy and can give a single image covering up to 82% or 200 degrees of the retina. This system takes advantage of the optics of an ellipsoid mirror which contains two focal points. The laser beam of the UWFI camera is directed through one of the focal points, while the patient's eye is positioned such that the second focal

This is an open access article distributed under the terms of the Creative Commons Attribution-NonCommercial-ShareAlike 3.0 License, which allows others to remix, tweak, and build upon the work non-commercially, as long as the author is credited and the new creations are licensed under the identical terms.

For reprints contact: [reprints@medknow.com](mailto:reprints@medknow.com)

**How to cite this article:** Tripathy K, Chawla R, Venkatesh P, Vohra R, Sharma YR, Gogia V, et al. Ultra-wide field fluorescein angiography in retinitis pigmentosa with intermediate uveitis. *J Ophthalmic Vis Res* 2016;11:237-9.

#### Correspondence to:

Koushik Tripathy, MD. Dr. Rajendra Prasad Centre for Ophthalmic Sciences, All India Institute of Medical Sciences, New Delhi - 110 029, India.  
E-mail: [koushiktripathy@gmail.com](mailto:koushiktripathy@gmail.com)

Received: 21-10-2014

Accepted: 29-11-2014

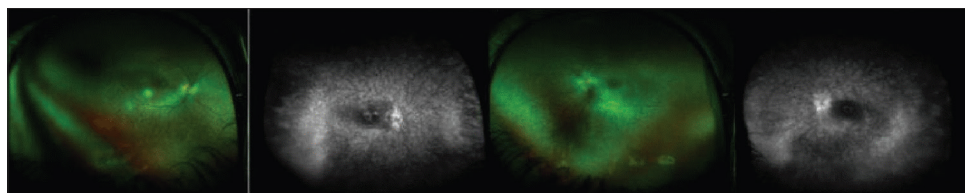
#### Access this article online

##### Quick Response Code:

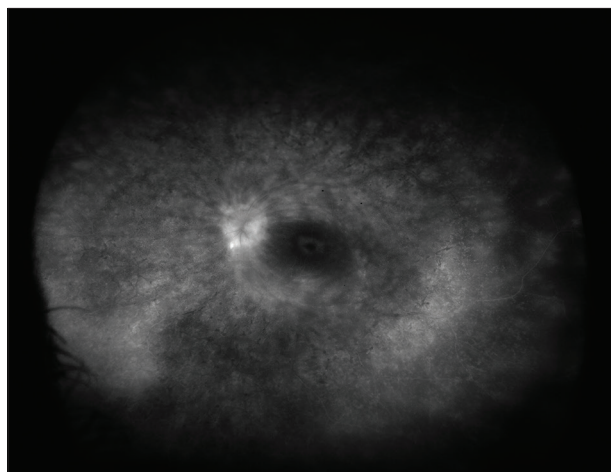


Website:  
[www.jovr.org](http://www.jovr.org)

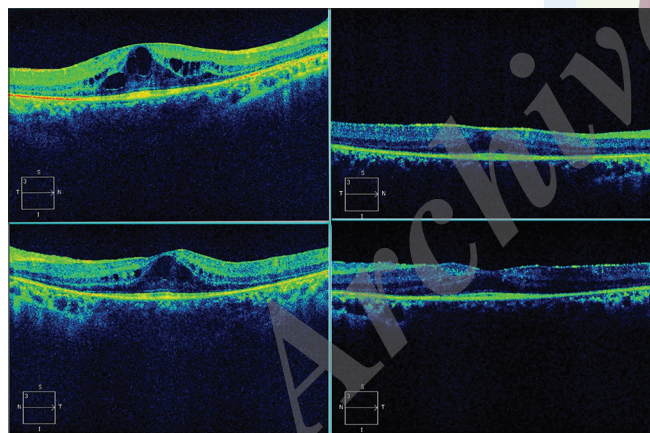
DOI:  
10.4103/2008-322X.183929



**Figure 1.** Fundus photographs and fluorescein angiograms of the both eyes shows typical bony spicule pigmentation, and preretinal exudates inferiorly suggestive of retinitis pigmentosa with intermediate uveitis.



**Figure 2.** Ultra-wide field fundus fluorescein angiogram of the left eye shows disc leak and petaloid leakage at the macula.



**Figure 3.** Pre- and post-treatment fundus imaging of the right (up) and left eyes (down). At presentation, central macular thickness (CMT) was 433 microns in the left eye with cystic spaces visible on optical coherence tomography.

point is located inside the patient's eye creating a 200 degree image.

CME has been reported in 11-70% of patients with RP.<sup>[3]</sup> However, reports on intermediate uveitis coexisting with RP are rare.<sup>[4]</sup> The presence of peripheral vasculitis, vascular leakage, and CME could masquerade as uveitis in RP. The exact cause of CME in RP is unclear but is presumed to be due to breakdown of the blood retinal barrier and decreased pumping efficiency of the

retinal pigment epithelium. Intermediate uveitis which is characterized by disc leakage, CME on fluorescein angiogram and preretinal exudates have rarely been reported in RP.<sup>[4]</sup> There is limited data in the literature regarding the role of UWFA in RP. Kaufman et al showed that UWFA revealed peripheral vascular leakage indicative of vasculitis in 15 of 25 patients (60%) in RP.<sup>[5]</sup> Miller and colleagues showed that 31% of RP patients showed peripheral vascular leakage, and 63% patients showed CME without clinical signs of Coats'-like response.<sup>[6]</sup>

In the patient described herein, UWFI and UWFA were able to simultaneously pick up peripheral pre-retinal exudates, clinical features of RP, central CME and disc leakage. Thus, a single investigation helped us identify and document both pathologies. The OCT showed significant resolution of CME after 2 weeks of therapy and visual acuity of the patient was also improved. This is the evidence supporting that CME in our patient was inflammatory in nature. Thus, although rare, one should also rule out the presence of intermediate uveitis patients with RP with CME. UWFI/UWFA may prove to be a promising tool for simultaneous imaging of central and peripheral retinal pathologies.

### Acknowledgments

We sincerely acknowledge invaluable support and suggestion by Trina Sengupta Tripathy, without which the manuscript would have been incomplete.

### Financial Support and Sponsorship

Nil.

### Conflicts of Interest

There are no conflicts of interest.

### REFERENCES

1. Tripathy K, Sharma YR, Gogia V, Venkatesh P, Singh SK, Vohra R. Serial ultra wide field imaging for following up acute retinal necrosis cases. *Oman J Ophthalmol* 2015;8:71-72.
2. Tripathy K, Chawla R, Venkatesh P, Sharma YR, Vohra R. Ultra wide field imaging in uveitic non-dilating pupil. *J Ophthalmic Vis Res* [In press].
3. Gregory-Evans K, Pennesi ME, Weleber RG. Retinitis pigmentosa

- and allied disorders. In: Retina. 5<sup>th</sup> ed., Ch. 40. London: Saunders/ Elsevier; 2013.
- Herrero-Latorre R, Fernandez-Perez S, Garcia-Martin E, Satue M, Idoipe M, De La Mata G, et al. Bilateral intermediate uveitis associated with retinosis pigmentosa. *Acta Ophthalmol* 2012;90.
  - Kaufman M, Medina-Mendez C, Friberg T, Eller A. Evaluation of peripheral retinal vasculitis in retinitis pigmentosa using wide-field fluorescein angiography. *Invest Ophthalmol Vis Sci* 2013;54:4018.
  - Miller KV, Eller AW, Friberg TR. Peripheral retinal vascular leakage in retinitis pigmentosa evaluated with optos widefield fluorescein angiography. *Invest Ophthalmol Vis Sci* 2010;51:4044.

Archive of SID