

Case Report

Possible Role of Descemet–Stroma Interface for Descemet’s Membrane Detachment after Penetrating Keratoplasty

Vivian WM Ho¹, FRCOphth, MBChB, BSc (Hons); Vito Romano¹, MD; Bernhard Steger¹, MD
Stephen B. Kaye^{1,2}, FRCS, FRCOphth, MD

¹Department of Corneal and External Eye Diseases, St. Paul’s Eye Unit, Royal Liverpool University Hospital, Liverpool, United Kingdom

²Department of Eye and Vision Science, University of Liverpool, Liverpool, United Kingdom

Abstract

Purpose: To report two cases of spontaneous Descemet’s membrane detachment (DMD) and dehiscence following penetrating keratoplasty (PK).

Case Reports: Spontaneous DMD or Descemet’s membrane (DM) dehiscence following PK is a rare occurrence. Here, we describe two cases of such an occurrence following PK arising from the graft–host interface. A possible causative relation between DMD/dehiscence and DM–stromal interface attachment is suggested.

Conclusion: DMD and dehiscence after PK can be explained by the peripheral thinning of DM and possible changes to the recently characterized anchoring zone of interwoven collagen fibers and proteoglycans at the Descemet–stroma interface.

Keywords: Descemet’s Membrane Detachment; Anchoring Zone; Penetrating Keratoplasty; Air Tamponade

J Ophthalmic Vis Res 2018; 13 (1): 72-74

INTRODUCTION

Descemet’s membrane detachment (DMD) usually occurs following surgical procedures such as cataract surgery or deep anterior lamellar keratoplasty.^[1,2] It may also occur spontaneously following trauma or in patients with corneal ectasia, as in keratoconus.^[1] Spontaneous DMD or DM dehiscence following penetrating keratoplasty (PK), however,

is rare. Here, we describe two cases of such an occurrence following PK arising from the graft–host interface.

CASE REPORT

Case 1

A 64-year-old woman was referred with aggressive acanthamoeba associated keratitis and scleritis that were unresponsive to medical treatment. She developed a corneal abscess and a central descemetocele requiring a 9.5-mm therapeutic PK with removal of the necrotic iris and cataract surgery.

This is an open access article distributed under the terms of the Creative Commons Attribution-NonCommercial-ShareAlike 3.0 License, which allows others to remix, tweak, and build upon the work non-commercially, as long as the author is credited and the new creations are licensed under the identical terms.

For reprints contact: reprints@medknow.com

How to cite this article: Ho VW, Romano V, Steger B, Kaye SB, Possible role of Descemet–stroma interface for Descemet’s membrane detachment after penetrating keratoplasty. *J Ophthalmic Vis Res* 2018;13:72-4.

Correspondence to:

Vivian WM Ho, FRCOphth, MBChB, BSc (Hons).
St. Paul’s Eye Unit, Royal Liverpool University
Hospital, 8Z Link, Prescott St., Liverpool, UK, L7 8XP.
E-mail: wing.ho@nhs.net

Received: 09-03-2016

Accepted: 15-07-2016

Access this article online

Quick Response Code:



Website:
www.jovr.org

DOI:
10.4103/jovr.jovr_40_16

Archive of SID

Fourteen months following the surgery, the patient underwent a repeat PK as a result of graft failure secondary to endothelial decompensation. A 9.5-mm donor was sutured into a 9-mm recipient bed with 16 interrupted 10-0 monofilament nylon sutures. The donor was a woman aged 71 years; the enucleation time was 17 hours after death and the cornea was stored in organ culture 31 hours after death. Endothelial assessment showed good endothelial cell count at 2800 cells/mm² with a moderate degree of folds and <2% cell death along the folds, with peripheral opacity/arcus.

After four months, the graft remained clear with the patient having a visual acuity of 0.8 logMAR and intraocular pressure within normal limits. After five months, a large inferonasal DM detachment developed with a circumferential flap folded in the anterior chamber [Figure 1a], which was evident on anterior segment optical coherence tomography (AS-OCT) [Figure 1b]. Descemetopexy with air was performed followed by face-up posturing for 24 hours. The DMD resolved completely after three months with the patient having a best-corrected visual acuity (BCVA) of 0.76 logMAR.

Case 2

A 17-year-old woman presented with advanced keratoconus in her right eye with a BCVA of 1.0 OD and 0.0 OS logMAR. She underwent an uneventful PK

in her right eye. An 8.0-mm donor graft was sutured into a 7.75-mm recipient bed with 12 continuous 10-0 monofilament mersilene sutures. The donor was a boy aged 16 years and 9 months; the eye was enucleated 24 hours after death and the cornea was stored in organ culture 40 hours after death. Endothelial assessment showed excellent endothelial cell count at 3250 cells/mm² with a heavy degree of folding and <2% of dead cells along the folds with no opacity.

Her BCVA was 0.6 logMAR after one month and corneal edema was evident inferotemporally with subepithelial haze [Figure 2a]. AS-OCT showed a DM dehiscence extending centrally from the graft-host interface [Figure 2b]. After nine months, the corneal edema persisted, but the dehiscence did not progress. Her BCVA improved to 0.0 logMAR after 14 months.

DISCUSSION

DMD has been reported in post-mortem cases and in a recent case wherein it occurred more than 20 years after PK for keratoconus.^[3,4] In the two patients described here, a peripheral DMD and DM dehiscence developed five months and one month following PK, respectively.

Several causative mechanisms of DMD have been proposed, such as instrumentation, pre-existing

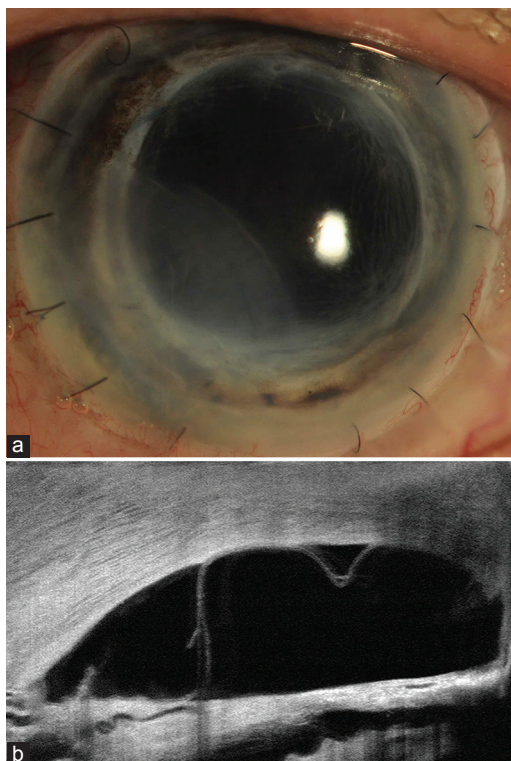


Figure 1. (a) Inferonasal view of Descemet's membrane detachment (DMD) 5 months after penetrating keratoplasty in patient 1. (b) tomography.

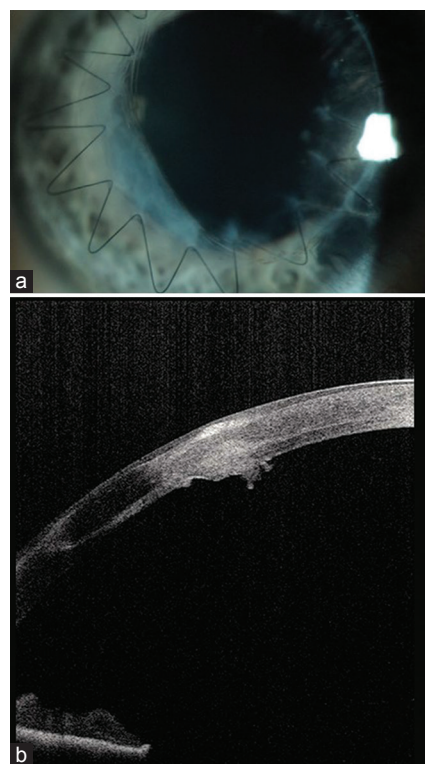


Figure 2. (a) Inferotemporal view of Descemet's membrane (DM) dehiscence at the graft-host interface 1 month following penetrating keratoplasty in patient 2. (b) DM dehiscence in the same patient demonstrated by anterior segment optical coherence tomography.

Archive of SID

anatomical abnormalities, or long-term use of amiodarone.^[1,5] We could not, however, find any evidence of injury to the DM either intra- or post-operatively in either case. Both grafts exhibited good endothelial cell counts and the donors were not known to have been exposed to amiodarone.

In case 1, it is possible that during the preparation of the 9.5-mm corneal graft, there was a slight decentration of the donor trephine including a very peripheral segment of DM. This may be of importance, as DM tapers progressively from 7–10 μm to 0.5 μm at its periphery,^[6] at which point, DM may be more susceptible to tears, such as during suturing or as part of the wound healing process. In case 2, the thinning of peripheral DM together with corneal ectasia may explain the spontaneous DM dehiscence at the graft–host interface. A similar suggestion was hypothesized by Gorski et al in their study including patients with keratoconus, where they suggested progressive keratoconus in the peripheral host tissue led to DMD after PK.^[4]

The absence of a uniform acellular pre-DM layer has been demonstrated by Schlötzer-Schrehardt et al.^[7] They characterized an anchoring zone of interwoven collagen fibers at the Descemet–stroma interface, measuring 0.5–1 μm in thickness. This interfibrillar attachment, analogous to Bowman’s layer, although present in both the central and the peripheral cornea, may be less defined in the very peripheral part of DM. We speculate that possible changes to this interfibrillar zone at the very periphery of the DM–stromal interface, together with the thinning of the peripheral DM, may have predisposed a weakening that may have resulted in the development of DMD and dehiscence. It would also be supported by the relative ease of peeling DM away peripherally from adjacent stroma in preparation for DM endothelial keratoplasty.^[7]

In summary, peripheral DMD and dehiscence can occur following PK, and this is possibly explained by the relatively new observations of the structure of DM and its stromal attachment.

Declaration of patient consent

The authors certify that they have obtained all appropriate patients consent forms. In the form the patients have given their consent for their images and other clinical information to be reported in the journal. Patients understand that their names and initials will not be published and due efforts will be made to conceal their identity, but anonymity cannot be guaranteed.

Acknowledgement

Special thanks to Mr. M Batterbury FRCS, FRCOphth for providing the management details for patient in case 2.

Financial Support and Sponsorship

Nil.

Conflicts of Interest

There are no conflicts of interest.

REFERENCES

1. Chow VW, Agarwal T, Vajpayee RB, Jhanji V. Update on diagnosis and management of Descemet’s membrane detachment. *Curr Opin Ophthalmol* 2013;24:356-361.
2. Romano V, Steger B, Kaye S. Spontaneous Descemet membrane tear after uneventful Big Bubble DALK. *Cornea* 2015;34:479-481.
3. Lang GK, Green WR, Maumenee AE. Clinicopathologic studies of keratoplasty eyes obtained post mortem. *Am J Ophthalmol* 1986;101:28-40.
4. Gorski M, Shih C, Savoie B, Udell I. Spontaneous Descemet Membrane Detachment 20 Years After Penetrating Keratoplasty for Keratoconus. *Cornea* 2016;35:1023-1025.
5. Ciancaglini M, Carpineto P, Zuppardi E, Nubile M, Doronzo E, Mastropasqua L. *In vivo* confocal microscopy of patients with amiodarone-induced keratopathy. *Cornea* 2001;20:368-373.
6. Binder PS, Rock ME, Schmidt KC, Anderson JA. High-Voltage Electron Microscopy of Normal Human Cornea. *Invest Ophthalmol Vis Sci* 1991;32:2234-2243.
7. Schlötzer-Schrehardt U, Bachmann BO, Tourtas T, Torricelli AA, Singh A, González S, et al. Ultrastructure of the Posterior Corneal Stroma. *Ophthalmology* 2015;122:693-699.