

Case Report

Previously Diagnosed Leber's Hereditary Optic Neuropathy with Clinical Signs of Idiopathic Intracranial Hypertension Responsive to Acetazolamide Therapy

Hamid Sajjadi^{1,2}, MD, FACS; Hossein Poorsalman³, MD

¹San Jose Eye and Laser Medical Center, Cupertino, California, USA

²Department of Ophthalmology, Acacia Medical Center, Dubai, UAE

³Department of Ophthalmology, Red Crescent Hospital, Dubai, UAE

Abstract

Purpose: To present a case of suspected Leber's hereditary optic neuropathy (LHON) with MRI and OCT findings compatible with pseudotumor cerebri responsive to acetazolamide therapy.

Case Report: A five-year-old boy referred to our clinic with optic atrophy and low vision was originally diagnosed with LHON. Laboratory tests were negative for LHON, while OCT and MRI were consistent with pseudotumor cerebri. Acetazolamide therapy resulted in dramatic improvement of visual acuity.

Conclusion: Some cases of previously labeled hereditary optic neuropathies with clinical signs of idiopathic intracranial hypertension could respond to intracranial pressure lowering treatment.

Keywords: Cerebro-spinal Fluid; Leber's Hereditary Optic Neuropathy; Optical Coherence Tomography; Pseudotumor Cerebri

J Ophthalmic Vis Res 2019; 14 (1): 109-113

INTRODUCTION

Leber's hereditary optic neuropathy (LHON) is an inherited form of vision loss. Although symptoms of this condition usually present during adolescence or into the twenties, rare cases may appear in early childhood or later in adulthood. For unknown reasons, males are affected more often than females. Blurring and clouding of vision are usually the first symptoms of LHON.^[1] These vision problems can occur unilaterally or simultaneously in both eyes; if vision loss starts in one eye, the other eye is usually

affected within several weeks or months. Vision loss is typically the only symptom of LHON; however, some families with additional symptoms have been reported. In these individuals, the condition is described as "LHON plus". Along with vision loss and optic atrophy, the features of LHON plus may include movement disorders, tremors, and cardiac conduction defects.^[2]

Idiopathic intracranial hypertension (IIH), previously known as pseudotumor cerebri (PTC) and benign intracranial hypertension (BIH), is a syndrome characterized by increased intracranial pressure (IICP) secondary to cerebrospinal fluid, often without an understood cause. A recent paper showed that events like brain trauma can lead to PTC, and changed the stereotype of the presenting PTC

Correspondence to:

Hamid Sajjadi, MD, FACS. Alwasl Road, Acacia Medical Center, UAE.

E-mail: hsajjadi@yahoo.com

Received: 08-04-2018

Accepted: 20-08-2018

Access this article online

Quick Response Code:



Website:
www.jovr.org

DOI:
10.4103/jovr.jovr_85_18

This is an open access journal, and articles are distributed under the terms of the Creative Commons Attribution-NonCommercial-ShareAlike 4.0 License, which allows others to remix, tweak, and build upon the work non-commercially, as long as appropriate credit is given and the new creations are licensed under the identical terms.

For reprints contact: reprints@medknow.com

How to cite this article: Sajjadi H, Poorsalman H. Previously diagnosed Leber's hereditary optic neuropathy with clinical signs of idiopathic intracranial hypertension responsive to acetazolamide therapy. *J Ophthalmic Vis Res* 2019;14:109-13.

Idiopathic Intracranial Hypertension Misdiagnosed as Leber's Hereditary Optic Neuropathy; Sajjadi and Poorsalman

patient.^[3] The ophthalmic morbidity of PTC is related to vision loss from optic nerve damage. If untreated, longstanding pressure from inside the brain onto the optic nerves commonly results in irreversible optic neuropathy with visual field loss, color desaturation or even total loss of color vision.^[4] Although rare, central visual acuity loss can also occur, especially in younger patients.^[3,5]

Herein we describe a case referred to our clinic with diagnosis of LHON. The boy presented with severe visual acuity loss secondary to severe optic atrophy. Full workup included genetic tests ruled out LHON and MRI which supported a new diagnosis of pseudotumor cerebri. Despite loss of central field vision, the patient had great recovery with acetazolamide treatment.

CASE REPORT

A five-year-old Caucasian male was referred to us with a two-year history of blurry vision and headaches; he had previously been evaluated by two ophthalmologists who diagnosed LHON. Our initial exam was on 24 October 2016. On exam, BCVA with Cycloplegic

refraction were OD = $-0.75-0.25 \times 120 = 20/100$, and OS = $-0.50-0.50 \times 70 = 20/100$. Stereopsis was 400 seconds of arc. No relative afferent pupillary defect was noted. Intraocular pressure was 16 mmHg in both eyes. Pachymetry were 520/520 in both eyes.

On fundus exam, he had 3-4+ optic disc pallor with 0.75 cupping. Macular OCT showed extensive macular thinning with normal structure [Figure 1a]. Ganglion cell layer (GCL) OCT revealed nearly complete GCL loss including central loss OU [Figures 1b and c]. This GCL loss was responsible for macular thinning. Three-dimensional OCT of the optic disc showed optic atrophy and our Pattern 4 IHH, 75% specific for IICP [Figure 1d].^[3] In Pattern 4 IHH, there remains a hint of temporal wings, secondary to cerebrospinal fluid in the temporal retina. The average nerve fiber layer (ANFL) were 66 microns OD and 54 microns OS. Using a technique we have previously described^[3], we measured 400 microns of papilledema in the right eye and 560 microns in the left eye on OCT. Our routine optic neuropathy workup for adults was performed.^[3] Vitamin D level was low and treated while Vitamin B12 levels were normal (678). Tests for collagen vascular disease,

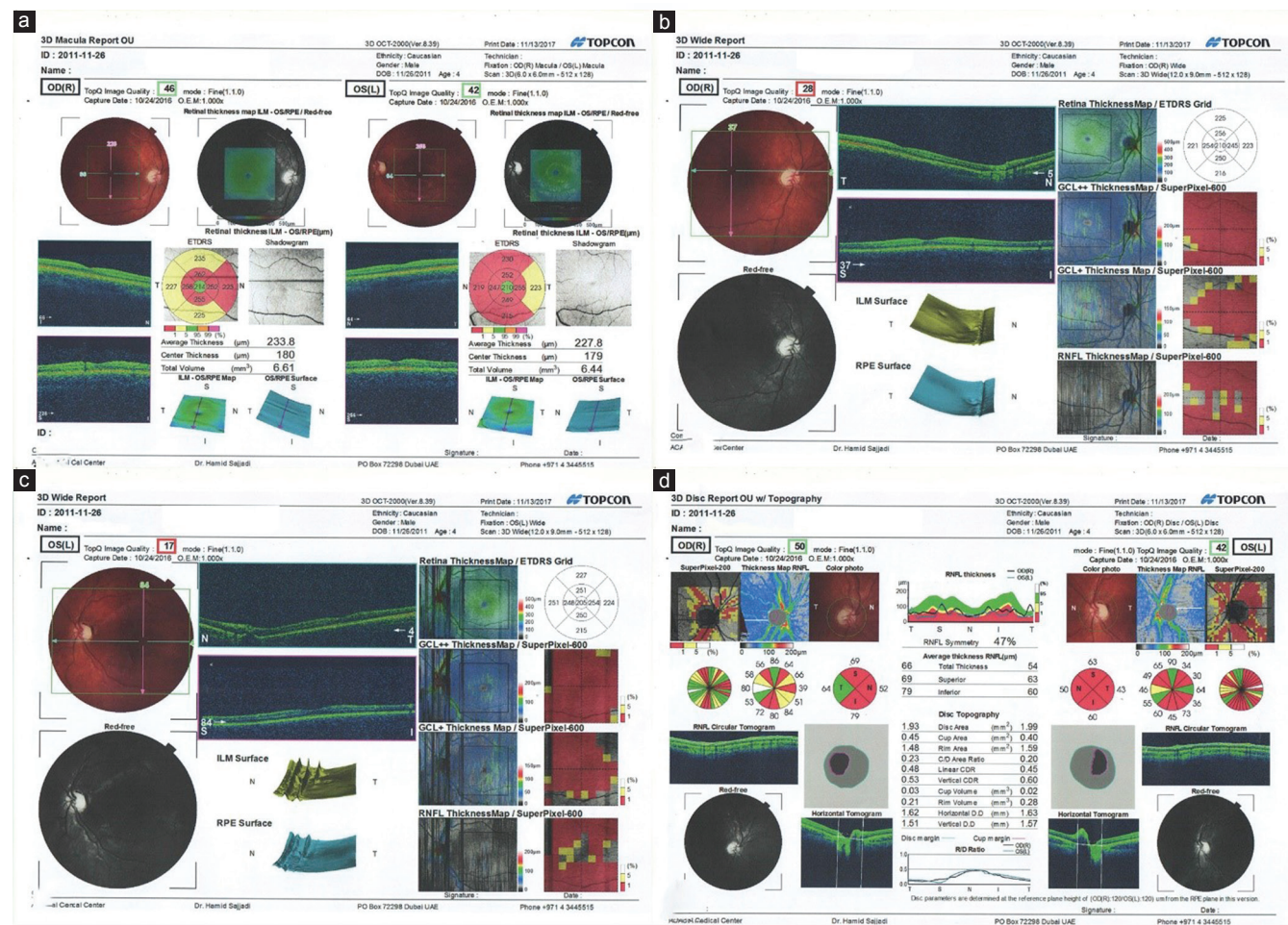


Figure 1. (a) Macular OCT showing extensive macular thinning with normal structure, (b and c) Ganglion cell layer OCT showing near total macular GCL loss with central loss. (d) Optic nerve OCT showing severe optic atrophy.

Idiopathic Intracranial Hypertension Misdiagnosed as Leber's Hereditary Optic Neuropathy; Sajjadi and Poorsalman

parathyroid hormone and Lyme disease were negative. Genetic tests for mutations in the DNA of mitochondria that are associated with LHON, including MT-ND1,

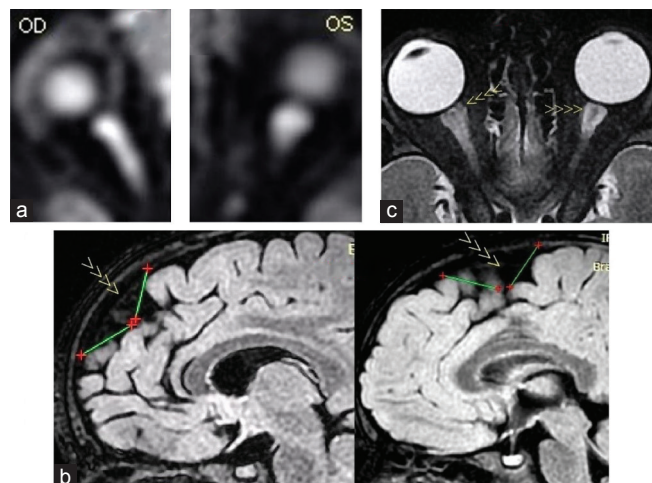


Figure 2. Brain MRI (a) Diffusion weighted showing extensive fluid around optic nerves. (b) Hygroma, unusual in a child. (c) Greater than 2-mm of CSF in optic nerve near globe.

MT-ND4, MT-ND4L, and MT-ND6 genes, were sent to another laboratory. Interestingly, 85% of females and 50% of males with these mutated genes never show signs of LHON.

Brain MRI was considered normal by radiologist. However, in one axial cut, we interpreted more than 2 mm of CSF in the optic nerve near the globe [Figures 2a and c] and a small hygroma, which is very unusual at a young age and may be a sign of increased ICP [Figure 2b]. With a tentative diagnosis of PTC, the patient was referred to a neurologist for a spinal tap. The opening intracranial pressure in lateral decubitus position was 180 mm-H₂O (normal range in children is up to 210 mm-H₂O).^[6]

Although this pressure was not considered high in recent reference intervals, other clinical signs were compatible with IIH, and there was no risk in initiating treatment with acetazolamide (125 mg PO QID). Two months later, the boy's headaches were completely absent and his BCVA had improved to 20/30 in each eye. At a four-month follow up, BCVA was stable at 20/30 per eye and stereopsis had improved to 80 seconds of arc. Repeat OCT of the macula showed

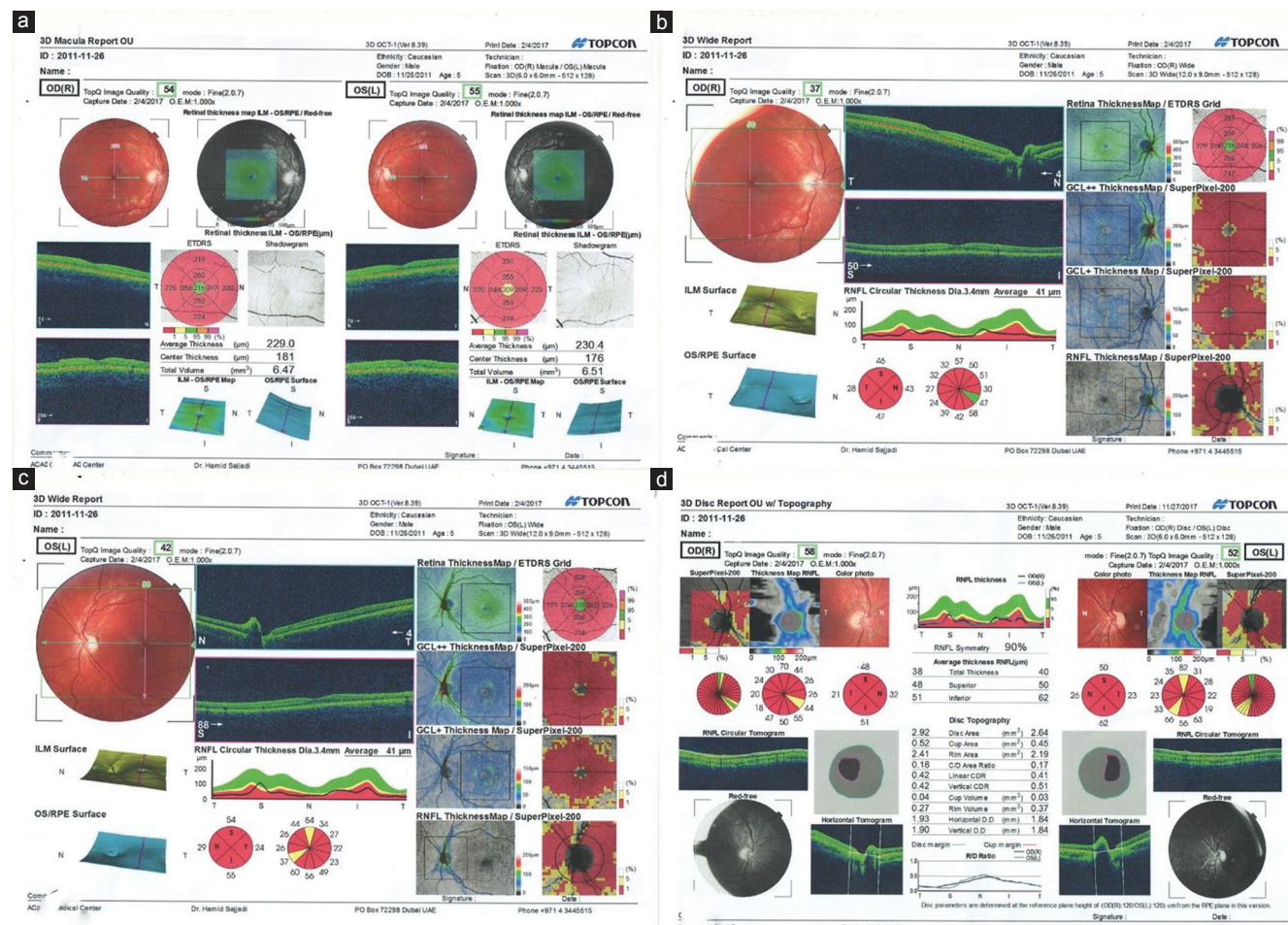


Figure 3. (a) OCT macula at presentation. (b and c) OCT of GCL showing improvement in ganglion cell layers with a central opening explaining the improved visual acuity. (d) The decrease in ANFL due to decrease in ICP and decreased papilledema.

Idiopathic Intracranial Hypertension Misdiagnosed as Leber's Hereditary Optic Neuropathy; Sajjadi and Poorsalman

consistent thinning as before [Figure 3a]. OCT of GCL showed improvement in GCL with a central opening, explaining the improved visual acuity in both eyes [Figures 3b and c]. On optic nerve OCT, ANFL decreased to 40 microns OD and 44 microns OS [Figure 3d].

Exactly one year later, VA and OCTs [Figure 4] were stable, despite some increase in ANFL from the original improvement seen after four months of treatment, and some non-significant thickening of macula and thus increased GCL. Stereopsis improved to 50 seconds of arc. The patient remained on 125 mg Diamox (acetazolamide) PO QID.

Conflict of Interest Statement: The authors have no conflict of interest in this article.

DISCUSSION

This case demonstrates successful acetazolamide treatment of a child, suspected to have congenital optic neuropathy, but with clinical signs of IIH. Although intracranial pressure was within normal limits, the

patient's VA and visual function improved dramatically after treatment. There are some cases of known IIH in literature with normal CSF opening pressure.^[7] Therefore, clinicians must be more inquisitive, especially in children and young adults, regarding cases of decreased vision whether with or without papilledema or headaches. Any abnormality of optic nerve, even pseudo-papilledema, deserves an OCT of the optic nerve and a GCL analysis.^[3] We have shown recently that obese females with headaches and papilledema, are no longer stereotypic for PTC. In our study of 164 cases of PTC diagnosed with OCT only, 56% of patients did not experience headaches, 62% were not visibly obese, 46% were males and, although some had optic atrophy or large cupping, none had overt papilledema (0%). Only 35% had absence of spontaneous venous pulsations (SVPs).^[3]

In conclusion, even optic neuropathies nearing end stage deserve a workup for PTC since treatment could prevent further vision loss. Neither papilledema nor the absence of SVPs is required to diagnose pseudotumor cerebri. Children may actually have optic atrophy without papilledema. We suggest cases of decreased vision,

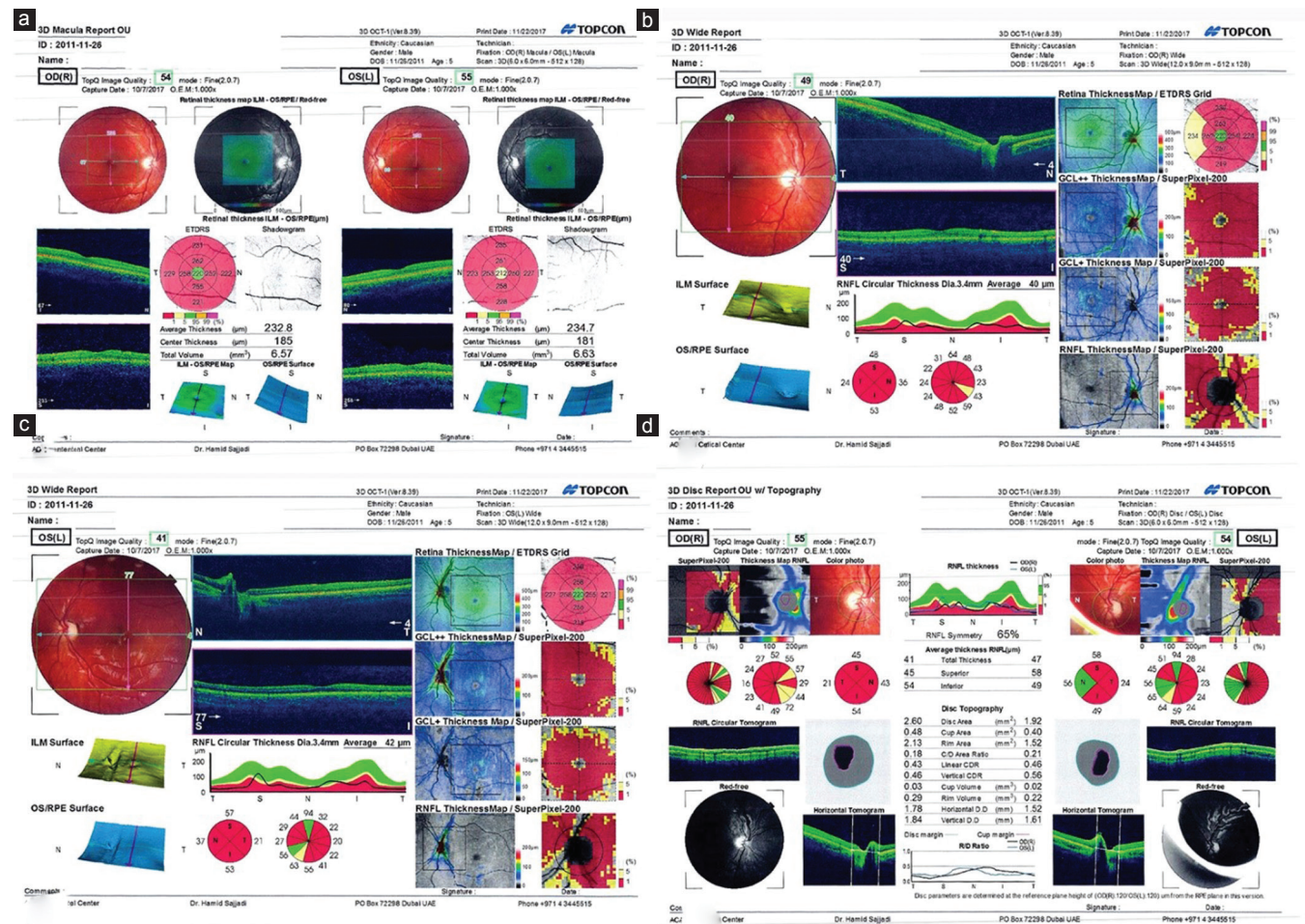


Figure 4. (a) OCT macula. (b and c) GCL OCT. (d) OCT optic nerve. Stable condition from four months to one year of treatment, some recovery of ANFL from the initial drop after four months.

previously labeled as hereditary optic neuropathies but showing clinical signs of IIH, be further evaluated as they could respond favorably to ICP lowering treatments such as carbonic anhydrase inhibitors.

Declaration of Patient Consent

The authors certify that they have obtained all appropriate patient consent forms. In the form the patient(s) has/have given his/her/their consent for his/her/their images and other clinical information to be reported in the journal. The patients understand that their names and initials will not be published and due efforts will be made to conceal their identity, but anonymity cannot be guaranteed.

Financial Support and Sponsorship

Nil.

Conflicts of Interest

There are no conflicts of interest.

REFERENCES

1. Newman NJ. Hereditary optic neuropathies: From the mitochondria to the optic nerve. *Am J Ophthalmol* 2005;140:517-523.
2. Yu-Wai-Man P, Griffiths PG, Hudson G, Chinnery PF. Inherited mitochondrial optic neuropathies. *J Med Genet* 2009;46:145-158.
3. Sajjadi F, Khoshnevisan MH, Doane JF, Sajjadi H. New predictive value of optical coherence tomography analysis in the diagnosis of idiopathic intracranial hypertension. *J Contemp Med Sci* 2017;3:197-207.
4. Digre KB, Nakamoto BK, Warner JE, Langeberg WJ, Baggaley SK, Katz BJ. A comparison of idiopathic intracranial hypertension with and without papilledema. *Headache* 2009;49:185-193.
5. Corbett JJ, Savino PJ, Thompson HS, Kansu T, Schatz NJ, Orr LS, et al. Visual loss in pseudotumor cerebri. Follow-up of 57 patients from five to 41 year and a profile of 14 patients with permanent severe visual loss. *Arch Neurol* 1982;39:461-474.
6. Avery RA. Reference range of cerebrospinal fluid opening pressure in children: Historical overview and current data. *Neuropediatrics* 2014;45:206-211.
7. Suh SY, Kim SJ. IIH with normal CSF pressures? *Indian J Ophthalmol* 2013;61:681-682.

