

# Modified long Mire Technique for Biliary Decompression in Hilar Cholangiocarcinoma (Klatskin Tumor) Over 10 Years Experience of a Single Center

Afsharfard A<sup>1,2</sup>, Mozaffar M<sup>2</sup>, Sobhiyeh MR<sup>2</sup>, Tadayon N<sup>2</sup>, Atghiyayie KH<sup>2</sup>

## Abstract

**Background:** Patients with malignant obstruction of the biliary tract suffer from progressive jaundice and pruritis, and if the obstruction is not relieved they will die from cholangitis, septicemia or liver failure. The correct choice between many operative and non-operative procedures available to relieve jaundice is not yet determined.

Unresectable disease (perihilar cholangiocarcinoma) found at the time of open exploration can be treated with a palliative surgical biliary bypass such as modified Longmire technique.

**Methods:** Eighteen (18) cases with unresectable hilar cholangiocarcinoma found at the operation underwent modified Longmire technique for biliary decompression.

**Results:** The mean preoperative bilirubin level was 22 mg/dl. The post operative mean total bilirubin level was below 5mg/dL about 1 month after surgery. During the follow-up period, averaging 22 months (max 6 years), jaundice recurred only near the death of these patients. There was 1 in-hospital death, and the median survival was 18 months (maximum 6 years). The operation completely relieved the jaundice, and excellent palliation was achieved for more than 85% of the survival time.

**Conclusion:** We found this technique very effective to palliate patients mentioned above.

**Please cite this article as:** Afsharfard A, Mozaffar M, Sobhiyeh MR, Tadayon N, Atghiyayie KH. Modified long Mire Technique for Biliary Decompression in Hilar Cholangiocarcinoma (Klatskin Tumor) Over 10 Years Experience of a Single Center. *Iran J Cancer Prev*, 2010 ; Vol3, No 2, p. 75-78.

**Key Words:** Cholestatic Jaundice, Biliary decompression, Modified long mire technique, Hilar Cholangiocarcinoma, klatskin tumor

## Introduction

Patients with malignant obstruction of the biliary tract suffer from progressive jaundice with its attending pruritis.

Death from cholangitis, septicemia or liver failure ensues if the obstruction is not relieved. A bewildering array of operative and non-operative procedures are available for the treatment of these patients.

**Treatment Options:** A wide range of treatment options is available. Non-operative decompressions are indicated in patients with poor surgical risks and in patients with short life expectancy due to extensive tumors or multiple metastasis. Percutaneously placed catheters or endoscopically placed endoprosthesis can be used. Percutaneous placement of expandable metal stents or drainage catheters is usually the appropriate approach for

proximal tumors [1, -4]. There is a significant risk of cholangitis with internal and external drainage, and stent occlusion is not uncommon [3].

Curative resection offers the only hope of cure and long term survival [1, 4-6].

Patients should undergo surgical exploration if they have no signs of metastasis or locally unresectable disease on preoperative investigations [1].

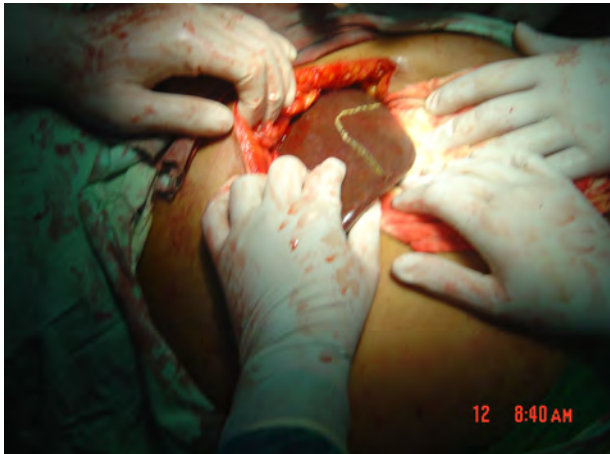Although surgical bypass offers improved patency and fewer episodes of cholangitis, an operative intervention is not warranted in patients with metastatic disease [1, 4].

However, despite improvements in ultrasonography, CT scanning, and MRI, more than one half of patients who are explored are found to have peritoneal implants, nodal or hepatic metastasis, or locally advanced disease that precludes resection [7, 11].

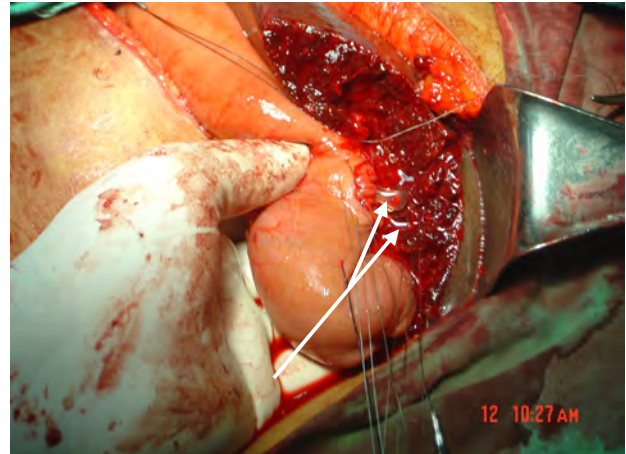
1. Cancer Research Center, Shahid Beheshti University of Medical Sciences, Tehran, Iran  
2. Department of General and Vascular Surgery, Shohada Tajrish Medical Center, Shahid Beheshti University of Medical Sciences, Tehran, Iran

Corresponding Author:  
Niki Tadayon MD  
Resident of Surgery  
Tel: (+98) 21-22 72 11 44  
Email: niki\_td@yahoo.com

Received: 3 Jan. 2010  
Accepted: 20 Mar. 2010  
*IJCP* 2010; 2: 75-78



**Figure1.** The modified Longmire operation. A portion of the left lateral liver segment has been resected and a reux loop of jejunum is brought up and connected to the dilated intrahepatic duct.



**Figure2.** The modified Longmire operation. A portion of the left lateral liver segment has been resected a nelaton catheter has been inserted in the ducts as a stent

The available retrospective evidence suggests that surgical biliary bypass offers more durable palliation in these patients. The palliative options for patients with unresectable perihilar cholangiocarcinoma include [1] tumor debulking with Roux- $\infty$  Y hepaticojejunostomy and intraoperative placement of Silastic transhepatic catheters, and [5] Roux- $\infty$  Y hepaticojejunostomy using the segment 3 or 4 duct. These unilateral bypasses should be avoided in the presence of ipsilateral liver lobe atrophy, a finding that indicates limited functional hepatic parenchyma.

The original technique was invented by Dr. Longmire in 1948 which was a partial hepatectomy and one-layer anastomosis approximating dilated bile duct mucosa to jejunal mucosa with simple interrupted sutures and placement of a stent and through the anastomosis. Finally, end-to-side jejunojejunostomy was performed about 60 cm from the choledochojejunostomy.

In 1971, Dr. Longmire indicated that the following modifications must be applied for the procedure to be performed successfully [12]: after partial hepatectomy and finding 2 or 3 dilated ducts and further dilating them by Bake's dilatator 6-8mm, a one-layer anastomosis between the anti mesenteric boarder of a roux limb of jejunum and the duct is constructed by approximating mucosa to mucosa with simple interrupted 6-0 absorbable sutures. Just before the anterior layer of the anastomosis is completed, a -16- gauge Nelaton Suction Catheter with side holes threaded through the opening to avoid any tension on the anastomosis, the jejunum is

secured to the adjacent liver capsule. Finally, a hand-sewn end-to-side jejunojejunostomy is performed about 60 cm from the choledochojejunostomy with 3-0 Gambee silk sutures. Two panrose drains are placed in the right upper quadrant.

Although this was an effective technique, small number of cases managed with this technique has been recorded in the literature since Longmire and Sanford introduced this procedure in 1948. We wish to report successful use of this operation for biliary drainage in primary adenocarcinoma of the intrahepatic bile ducts.

## Materials and Methods

The clinical records of 18 cases with unresectable hilar cholangiocarcinoma found at the operation and post operative follow up were reviewed retrospectively. After confirming the diagnosis of unresectable Klatskine tumor, the modified Longmire technique was performed as follows: after wedge resection of left lobe and finding 2 or 3 dilated ducts a one-layer anastomosis between the anti mesenteric boarder of a roux limb of jejunum and the duct is constructed by approximating mucosa to mucosa with simple interrupted 6-0 absorbable sutures. The jejunum is secured to the adjacent liver capsule. Finally, a hand-sewn end-to-side jejunojejunostomy is performed about 60 cm from the cholangiojejunostomy with 3-0 Gambee silk sutures. Two panrose drains are placed in the right upper quadrant (Fig1-2). The mean bilirubin level, jaundice

and prurient and the period during which the patient was icterus free were recorded.

**Results**

The procedure was performed on 18 patients (mean age 57) with cholestasis (mean alkaline phosphatase 780 U/l, mean bilirubin level mean 22 mg/dl). The post operative mean total bilirubin level was below 5mg/dL about 1 month after surgery. During the follow-up period, averaging 22 months (max 6 years), jaundice recurred only near the death of these patients. There was 1 in-hospital death, and the median survival was 18 months.(maximum 6 years) The operation completely relieved the jaundice, and excellent palliation was achieved for more than 85% of the survival time (Table 1).

**Discussion**

Malignant obstruction of the biliary tract results in progressive jaundice, purities, cholangitis, septicaemia and liver failure. Bewildering arrays of operative and non-operative procedures are available to relive jaundice in these patients.

Curative resection offers the only hope of cure and long term survival [1, 4-6].

Patients should undergo surgical exploration if they have no signs of metastasis or locally unresectable disease on preoperative

investigations[1].

However, despite improvements in ultrasonography, CT scanning, and MRI, more than one half of patients who are explored are found to have peritoneal implants, nodal or hepatic metastasis, or locally advanced disease that precludes resection [7-11].

For these patients, available retrospective evidence suggests that a palliative surgical biliary bypass offers more durable palliation than percutaneous or endoscopic stenting as catheters and endoprosthesis have their intrinsic problems. Longmire and Sanford introduced a procedure in 1948 using a partial hepatectomy and one-layer simple interrupted sutures anastomosis approximating dilated bile duct mucosa to jejunal mucosa over a stent. Then, securing the jejunum to the adjacent liver capsule to avoid any tension on the anastomosis and finally, end-to-side jejunojejunostomy about 60 cm from the choledochojejunostomy.

In 1971, Dr. Longmire indicated that the following must be present for the procedure to be performed successfully:

- "1) The intrahepatic ducts must be dilated. Drainage of contracted sclerotic ducts will not relieve the jaundice regardless of the patency or the size of the anastomosis.
- 2) The radiopaque solution must pass freely

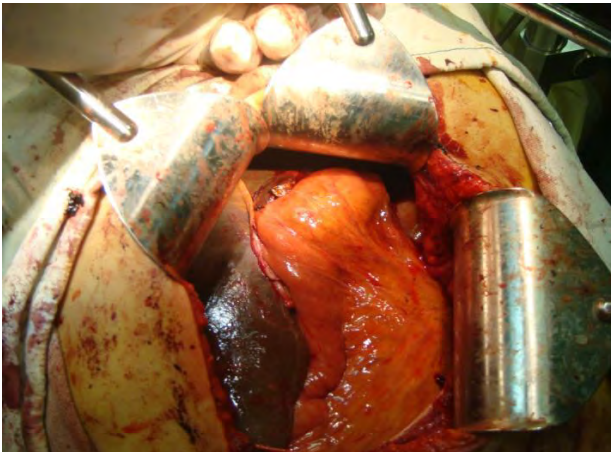
**Table 1.** Demographic data and results

Number	Sex	Age(m)	Survival	Bil.1	Bil.2
1	M	56	18	19	6.4
2	F	46	71.5	31.5	3.5
3	F	55	20	24	3.9
4	M	60	19	25	4.9
5	M	62	13	38	5.1
6	F	58	18	17	6.5
7	M	54	18	23.5	3.8
8	F	53	16	20.5	6.6
9	M	59	12	24.5	6.1
10	F	69	17	21.5	4.7
11	M	62	0.5	19.5	5
12	F	55	21	19	5.5
13	M	57	17	18.5	4.6
14	M	50	18	17.5	5.2
15	F	58	19	20	3.5
16	F	60	18	19	6.3
17	M	55	20	21	4.5
18	M	57	20	18	3.5

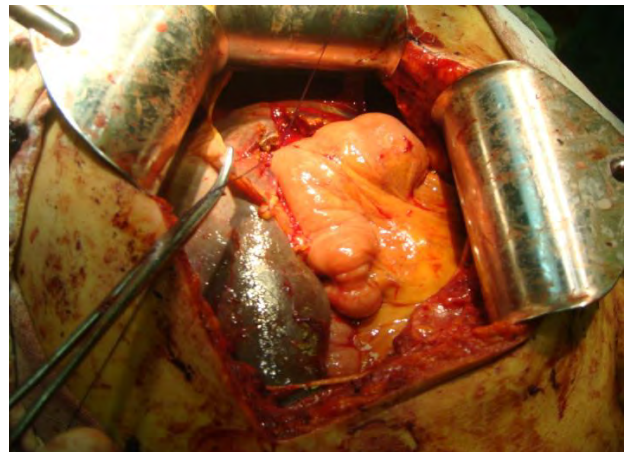
Survival in months

Bil1:Preoperation total bilirubin (mg/dl)

Bil2:One week postoperation total bilirubin (mg/dl)



**Figure3.** The modified Longmire operation. A reux loop of jejunum is brought up and anastomosed to the dilated intrahepatic ducts



**Figure4.** The modified Longmire operation. The final reconstruction

between the left and right intrahepatic ducts. Drainage of the left duct alone may offer significant improvement if the obstructive right duct is not infected and if there is good hepatic parenchymal reserve.

3) The ducts must be clear of stones, gravel, or sludge that might interfere with proper drainage of the intrahepatic ducts in a retrograde fashion through the left hepatic system [12].

We managed 18 cases of cholangiocarcinoma found at the operation to be unresectable with this technique and found this technique to be a quiet effective procedure in revealing jaundice (Fig 3, 4). Because this procedure requires general anesthesia and abdominal operation doesn't need, comparing these two techniques is not right. But when a patient undergoes a surgery with hope of cure, a modified longmire operation can provide excellent palliation.

## Conclusions

Modified long mire technique is safe and highly effective in achieving internal biliary drainage and seems to be a promising surgical technique in palliative treatment of kelatsin tumor.

## Acknowledgments

We would like to thank Cancer Research Center for its cooperation with us.

## Conflict of Interest

The authors declare that they have no conflict of interest in this article.

## Authors' Contribution

AAF and MM designed the study; NT wrote the paper, while MRS and KHA contributed to the data entry and analyzed the data.

## References

1. Yeo. Shackelford's Surgery of the Alimentary Tract. 6th edition. 2007,vol II chap 104.
2. Aljiffry M, Walsh MJ, Molinari M. Advances in diagnosis, treatment and palliation of cholangiocarcinoma: 1990-2009. World J Gastroenterol. 2009 Sep;15(34): 4240-62.
3. Witzigmann H, Lang H, Lauer H. Guidelines for palliative surgery of cholangiocarcinoma. HPB (Oxford). 2008; 10(3):154 -60.
4. Forsmo HM, Horn A, Viste A, Hoem D, Ovrebo K. Survival and an overview of decision-making in patients with cholangiocarcinoma. Hepatobiliary Pancreat Dis Int. 2008Aug;7(4):412 -7.
5. Jonas S, Benckert C, Thelen A, Lopez-Hänninen E, Rösch T, Neuhaus P. Radical surgery for hilar cholangiocarcinoma. Eur J Surg Oncol. 2008 Mar;34(3): 263-71.
6. Ramos Rubio E. Radical surgery for hilar cholangiocarcinoma (Klatskin tumor. Cir Esp. 2007 Jul; 82(1):11 -15.
7. Yasuji Seyama, Masatoshi Makuuchi. Current surgical treatment for bile duct cancer. World J Gastroenterol. 2007 March 14; 13(10): 1505-15.
8. Cameron JL, Pitt HA, Zinner MJ, Steven L.Kaufman, Joann Coleman. Management of proximal cholangiocarcinomas by surgical resection and radiotherapy. Am J Surg 1990; 159:91 -7.
9. Hadjis NS, Blenkarn JI, Alexander N, Benjamin IS, Blumjart LH. Outcome of radical surgery in hilar cholangiocarcinoma. Surgery 1990; 107:597 -604.
10. Bismuth H, Nakache R, Diamond T. Management strategies in resection for hilar cholangiocarcinoma. Ann Surg.1992 ; 215:31 -8.
11. Henry A. Pitt Charles J. Yeo, William Dooley. Malignancies of the biliary tree Current Problems in Surgery.1995 Jan; 32(1):1- 90.
12. L.William Traverso. The Longmire I, II, and III operations. American Journal of Surgery. 2003 May, Volume 185, Issue 5.