

An Intracystic Papillary Carcinoma of the Breast

Donya Farrokh¹, Mahboobeh Abedi¹, Yalda Fallah Rastegar²

Abstract

Intracystic carcinoma of the breast is a rare form of breast carcinoma. Among all malignant breast tumors, this lesion has an incidence of 0.2-0.5%. These neoplasms have certain characteristic imaging findings which help to differentiate these lesions from other focal breast abnormalities.

This report is on the case of a 48-year-old woman with a palpable, painless lump in her right breast. Mammography demonstrated an oval well-circumscribed mass without calcification. Breast ultrasonography showed a cystic lesion with an intracystic solid component projecting from its posterior wall. Cyst aspiration revealed a hemorrhagic fluid and a suspicious cytology. Excisional biopsy revealed papillary carcinoma suggesting of intracystic papillary carcinoma.

Keywords: Breast cancer; Mammography; Ultrasonography; Magnetic resonance imaging

Please cite this article as: Farrokh D, Abedi M, Fallah Rastegar Y. An Intracystic Papillary Carcinoma of the Breast. *Iran J Cancer Prev*. 2013; 6(2):118-21.

1. Dept. of Radiology, Imam Reza Hospital, Mashad University of Medical Sciences, Mashad, Iran
2. Dept. of Surgery, Shariaty Hospital, Mashad University of Medical Sciences, Mashad, Iran

Corresponding Author: Mahboobeh Abedi, MD
Tel: (+98) 51 18 02 25 36
Email: abedi.mahboobeh@yahoo.com

Received: 10 Mar. 2011

Accepted: 20 Jul. 2011

Iran J Cancer Prev 2013;2:118-21

Introduction

Intraductal papillary neoplasms of the breast form a wide spectrum of pathological changes, with benign intraductal papilloma on one end of the spectrum and papillary carcinoma at the other end [1]. Papillary carcinoma of the breast is a rare form of breast carcinoma. Intracystic Papillary Carcinoma (IPC) is a variant of papillary carcinoma and accounts for 0.5-1% of breast cancers [2-4]. Physical examination and imaging findings are not usually sufficient to distinguish between benign tumors and this malignant intracystic lesion.

The imaging technique which provides the greatest information about these tumors is ultrasonography [1, 2, 5]. Fine Needle Aspiration Biopsy (FNAB) can show a malignant lesion, but it is often inaccurate and excisional biopsy is usually necessary for definitive diagnosis [2, 4, 6]. IPC was originally reported as a localized non-invasive carcinoma, but is occasionally associated with Ductal Carcinoma In Situ (DCIS) or invasive carcinoma around the main tumor [2, 3, 7, 8].

Complete excision of the cyst which should include the intracystic tumor is the treatment of choice [1, 2]. Here, a case of IPC in a 48-year-old woman is described with a review of the literature.

Case Report

A 50-year-old woman presented to the Breast Diagnostic Clinic with 10 months history of an

enlarging right breast mass. The mass was painless, when the patient was presented for physical examination. On clinical examination, she had a firm, well-circumscribed mass in the central part of the right breast at 2 o'clock, 2.0×3.0 cm. The mass was mobile and there was no evidence of nipple retraction, abnormal nipple discharge or skin thickening. The left breast and both axillary area were normal. The patient was asymptomatic in other ways. She had a positive familial history of breast cancer in her maternal grandmother.

Her last mammogram was four years before, which was normal. Bilateral mammography using a dedicated free-standing unit showed an oval-shaped mass with smooth circumscribed margins in the central part of the right breast, measuring 2.0 × 3.0 cm, without calcification. There were no associated findings of skin thickening, microcalcification or parenchymal distortion (Figure 1).

Ultrasonography using a dedicated breast ultrasound unit showed a well-circumscribed regular-shaped cystic mass with an internal hypoechoic solid component projecting into the cyst from its wall measuring 22 × 18 × 28 mm (Figure 2).

Fine needle aspiration biopsy cytology of the cyst revealed a bloodstained fluid that was suspicious, papanicolaou grade III cytology. An excisional biopsy was performed. Macroscopic examination of the specimen showed a cyst 2×3 cm with an intracystic papillary projection (Figure 3).

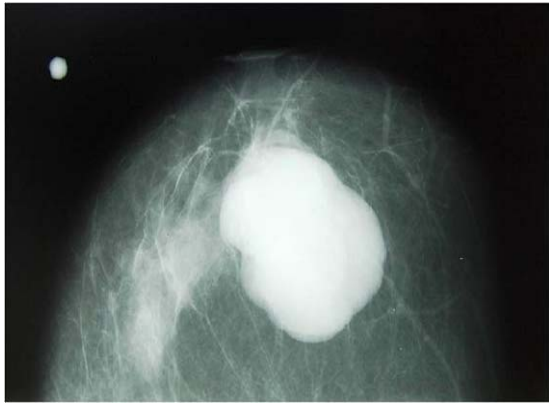

Figure 1. Right craniocaudal mammogram shows a dense mass with a lobulated well-defined margin.

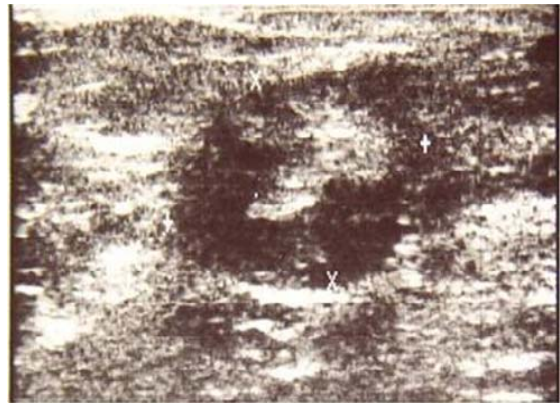

Figure 2. Sonogram shows a cystic mass with an intracystic solid component and echogenic internal septa.

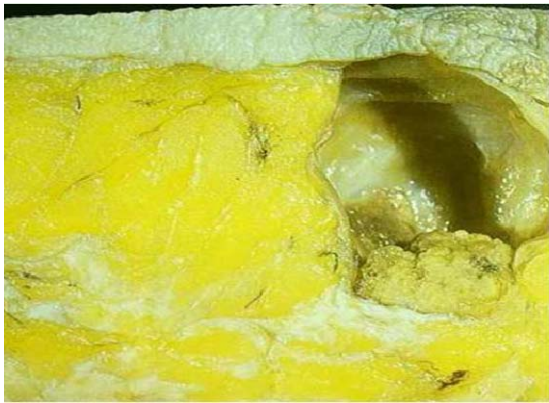

Figure 3. Photograph of a gross specimen shows a lobulated mass with branching and irregular surface within a cystic space.

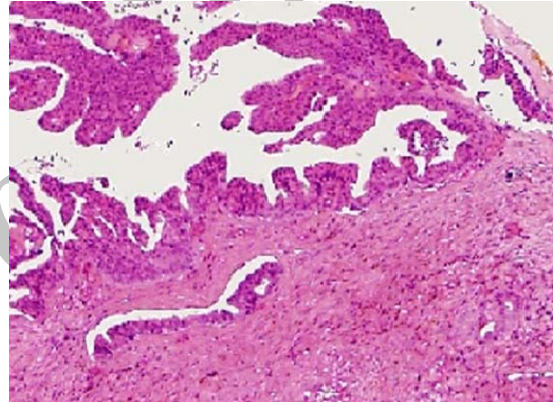


Figure 4. Photomicrograph of a histopathological specimen shows multiple papillae of single epithelial cell type and poorly formed cytoplasmic cores. (H & E, $\times 100$)

Histopathological examination revealed a cyst with a fibrotic wall and a papillary frond with a fibrovascular core and pleomorphic epithelial cells (Figure 4).

As regards the histologic findings, the breast cystic lesion corresponded to an intracystic papillary carcinoma.

The breast tissue around the margins of the cystic lesion showed no evidence of malignancy. P53, cyclin P1, and C-erb- BR expression was negative in our patient. Both estrogen and progesterone receptors were positive.

Routine laboratory examination, chest x-Ray and abdominal ultrasonography showed no abnormality. No suspicious lesions were demonstrated on examination for malignancy in other organs. A partial mastectomy was performed for the patient and there was no evidence of DCIS or invasive

carcinoma on histological examination at the surgical margin.

Discussion

Cystic carcinoma of the breast includes a heterogeneous spectrum of tumors. These include IPC with or without invasion, ductal carcinoma with cystic degeneration, and cystic hypersecretory ductal adenocarcinoma [3, 9]. IPC is a rare neoplasm of the breast, so far classified as a histologic variant of DCIS. However, this is no debated since the overall clinical and radiological presentation of IPC is different from DCIS and metastatic cases have been reported [10]. According to Haris et al., Leal et al., and Lofkceowits et al., nearly 4% to 70% of patients with IPC show DCIS or invasive carcinoma around the main tumor [11].

IPC can be present as a pure form or associated with ductal carcinoma in situ or ductal carcinoma invasive around the tumor. The frequency of lymph node involvement, local recurrence and distant recurrence is 0% to 11%, 3% to 70% and 0% to 4%, respectively [6, 7, 11].

IPCs are reported in patients from 25 to 80 years of age, with a peak incidence in patients aged 40 to 75 years old [2, 4]. These tumors may have a wide spectrum of presentations varying from a focally invasive lesion to a large mass located within a cystically dilated duct. The tumor may be small and detected only on mammography or may be large and palpable in clinical examination [2, 6, 12]. IPCs are reported in different sizes, ranging from 1 to 10 cm. It may be seen anywhere in the breast, and not only in the retroareolar region. Recently, imaging diagnostic methods and less invasive histopathological examinations have made it possible to diagnose IPC before excisional biopsy and radical surgery.

The mammographic finding of IPC is usually a well-circumscribed, high-density mass. Occasionally, satellite lesions or microcalcifications or both are present. IPC usually presents as a smooth sharply circumscribed mass without an irregular or nodular contour, except when the tumor breaks through the wall of the cyst to invade the adjacent parenchyma [2, 12, 13].

Ultrasonography is the preferred imaging method to distinguish cystic from solid masses of the breast and to differentiate simple cyst from cysts with intracystic tumoral lesions [12-15]. Ultrasonography usually shows complex cystic and solid masses that have mild to moderate posterior acoustic shadowing or posterior acoustic enhancement [5, 13, 16]. In rare cases, a cystic carcinoma might have no solid component [17].

Intracystic breast carcinoma without solid component may simulate as a simple cyst on ultrasound. Color Doppler Ultrasound is a useful diagnostic method to distinguish between the solid portion of the cystic lesion and echogenic internal debris [18]. Magnetic Resonance (MR) imaging of the IPC shows mural nodules and internal septa. MR imaging of the large IPC might show a multicystic appearance [13, 14, 18, 19].

It is well documented that MR imaging is more sensitive in detecting DCIS around the IPC than other imaging methods. In younger patients, however, the presence of high background signals sometimes make it difficult to demonstrate the DCIS with MR because of the high contrast of MR [19, 20].

It is feasible to perform a preoperative ultrasound-guided Fine Needle Aspiration Biopsy Cytology (FNABC) or core biopsy of the cystic and solid component for cytological and histological studies [21]. The aspirated fluid is often bloody, although the bloody aspirate is not pathognomonic for IPC. Although ultrasound and aspiration biopsy are usually the first steps in the diagnosis of IPC, cytological examination also has high false-negative results due to necrotic materials, degenerative changes in the diagnostic cells and abundant obscuring blood in the cystic lesion [14-16]. Core needle biopsy is a useful tool for diagnosis of IPC, although it is important to keep in mind that core needle biopsy of the central solid portion of the mass cannot distinguish between in-situ and invasive lesions at the periphery of IPC [4, 5, 12, 22].

On pathologic examination, most tumors have a soft or friable consistency, and have a spherical circumscribed contour. IPC usually appears as a mass with cystic component, which might have a papillary, nodular or shaggy internal surface.

There is usually fibrotic tissue in the wall of the cyst, which limits invasion into the surrounding parenchyma. Most IPCs are characterized by well-circumscribed nodules surrounded by a fibrous capsule and large vessels might be seen within the papillary nodules or the internal septa of intracystic lesion. Hemorrhagic areas within the solid components of the tumor and blood within the cystic spaces are often recognized [23]. Hemorrhage in IPC is usually due to torsion and infarction of the intracystic nodules. Pathologically, intracystic papillary carcinoma can show four cellular patterns: cribriform, compact columnar epithelial, stratified spindle cell, or a transitional cell form resembling urothelium, or a combination of two or more of these patterns may be seen [9]. IPC may be associated with foci of DCIS or invasive cancer, and necrosis is often a prominent feature when an associated invasive component is present [2, 7, 8].

The treatment of IPC is similar to other forms of breast cancer in which lumpectomy, segmentectomy and mastectomy are reliable actions. Sentinel node biopsies or axillary dissections are often performed for evaluation of axillary lymph nodes. Radiation therapy may also be administered in some patients [16, 23].

It is important for the surgeon to know that approximately half of all patients with IPC are associated with DCIS or invasive carcinoma to design an appropriate surgical treatment [2, 7]. Partial mastectomy without axillary lymph node dissection is the standard treatment for patients with non-invasive

IPC, while patients with invasive IPC usually undergo mastectomy with lymph node dissection.

IPC is characterized by a more benign behavior and a subsequent higher survival rate. The prognosis for IPC is usually very good with disease-specific survival rates approximately 100%. In cases with a large amount of nuclear atypia, the prognosis may be less optimistic [9, 22].

Acknowledgment

None.

Conflict of Interest

The authors have no conflict of interest in this article.

Authors' Contribution

Donya Farrokh designed the study and wrote the paper. Mahboobeh Abedi contributed in literature review and writing-up process. Yalda Fallah Rastegar contributed in literature review. All authors read and approved the final version.

References

- Ganesan S, Karthik G, Joshi M, Damodaran V. Ultrasound spectrum in intraductal papillary neoplasm of breast. *Br J Radiol.* 2006; 79 (946): 843-9.
- Amemiya T, Oda K, Satake H, Ichihara S, Sawaki A, Shimoyama Y, et al. A case of intracystic papillary carcinoma accompanying widespread ductal carcinoma in situ. *Breast cancer.* 2007; 14 (3): 312-6.
- Fisher ER, Palkar AS, Redmond C, Barton B, Fisher B. Pathologic findings from the National Surgical Adjuvant Breast Project (protocol No.4). VI. Invasive Papillary Cancer. *Am J Clin Pathol.* 1980; 73: 313-22.
- Carter D. Intraductal papillary tumors of the breast: a study of 78 cases. *Cancer.* 1977; 39(4): 1689-92.
- Ohlinger R, Frese H, Schwesinger G, Schimming A, Kohler G. Papillary intracystic carcinoma of the female breast; role of ultrasonography. *Ultraschall Med.* 2005; 26 (4): 325-8.
- Lefkowitz M, Lefkowitz W, Wargotz ES. Intraductal papillary carcinoma of the breast and its variants: a clinicopathological study of 77 cases. *Hum pathol.* 1994; 25(8):802-9.
- Leal C, Costa I, Fonseca D, Lopes P, Bento MJ, Lopes C. Intracystic (encysted) papillary carcinoma of the breast: a clinical, pathological, and immunohistochemical study. *Hum pathol.* 1998; 29(10): 1097-104.
- Wanger AE, Middleton LP, Whitman GJ. Intracystic papillary carcinoma of the breast with invasion. *AJR Am J Roentgenol.* 2004; 183 (5): 1516.
- Solorzano CC, Middleton LP, Hunt KK, Mirza N, Meric F, Kuerer HM, et al. Treatment and outcome of Patients with intracystic papillary carcinoma of the breast. *Am J Surg.* 2002; 184 (4): 364-8.
- Okita R, Ohsumi S, Takashima S, Saeki T, Aogi K, Nishimura R. Synchronous liver metastases of intracystic papillary carcinoma with invasion of the breast. *Breast cancer.* 2005; 12(4):327-30.
- Harris KP, Faliakou EC, Exon DJ, Nasiri N, Sacks NP, Gui GP. Treatment and outcome of intracystic papillary carcinoma of the breast. *Br J surg.* 1999; 86(10): 1274.
- Knelson MH, el Youssef SJ, Goldberg RE, Ballance W. Intracystic papillary carcinoma of the breast: mammographic, sonographic and MR appearance with pathologic correlation. *J Comput Assist Tomogr.* 1987; 11(6): 1074-6.
- Lam WW, Tang AP, Tse G, Chu WC. Radiology-Pathology conference: papillary carcinoma of the breast. *Clin imaging.* 2005; 29 (6): 396-400.
- Yang WT, Suen M, Metrewell C. Sonographic features of benign papillary neoplasm of the breast: review of 22 patients. *J Ultrasound Med.* 1997; 16(3): 161-8.
- Boonjunwetwat D, Prathombutr A. Imaging of benign papillary neoplasm of the breast: mammographic, galactographic and sonographic findings. *J med Assoc Thai.* 2000; 83(8): 832-8.
- Ohlingr R, Frese H, Schwesinger G, Schimming A, Kohler G. Papillary intracystic carcinoma of the female breast: Role of ultrasonography. *Ultraschall Med.* 2005; 26 (4): 325-8.
- Dragoumis DM, Assimaki AS, Tsiftoglou AP. Solid variant of a pure intracystic papillary carcinoma of the breast: case report. *Eur J Gynaecol Oncol.* 2008; 29 (5):545-7.
- Soo MS, Williford ME, Walsh R, Bentley RC, Kornguth PJ. Papillary carcinoma of the breast: imaging findings. *AJR.* 1995; 164(2): 321-6.
- Schimauchi A, Yamada T, Sato A, Takase K, Usami S, Ischida T, et al. Comparison of MDCT and MRI for evaluating the intraductal components of breast cancer. *Am J Roentgenol.* 2006; 187(2): 322-9.
- Linda A, Londero V, Mazzarella F, Zuiani C, Bazzocchi M. Rare breast neoplasms: is there any peculiar feature on magnetic resonance mammography. *Radiol Med.* 2007; 112 (6): 850-62.
- Shin HJ, Kim HH, Kim SM, Yang HR, Sohn JH, Kwon GY, et al. Papillary lesions of the breast diagnosed at percutaneous sonographically guided biopsy: comparison of sonographic features and biopsy methods. *AJR Am J Roentgenol.* 2008; 190 (3): 930-6.
- Calderaro J, Espie M, Duclos J, Giachethi S, Wehrer D, Sandid W, et al. Breast intracystic papillary carcinoma: an update. *Breast J.* 2009; 15 (6): 639-44.