

Paratesticular Liposarcoma; a Case Report

Shapour Omidvari¹, Seyyed Hasan Hamedei¹, Leila Moaddab-Shoar¹, Hamid Nasrollahi¹, Yahya Daneshbod², Mohammad Amin Mosleh-Shirazi¹, Mansour Ansraei¹, Mohammad Mohammadianpanah³, Niloofar Ahmadloo¹, Ahmad Mosalaei⁴

Abstract

Paratesticular sarcomas have happened rarely. Due to the infrequency of this malignant disease and its diverse histopathologic subtypes, no standard treatment would be available. Multiple treatments have reported in literature with different results. We have reported a 55 years old man with a 30 years history of paratesticular mass. After multiple operations, radical orchiectomy has revealed liposarcoma. The patient has been receiving 50 Gy radiation to the scrotum and inguinal area. After 18 months follow up, the patient was well and disease free. He has shown good response to surgery and radiotherapy, so we have reported the disease and its clinical course.

Keywords: liposarcoma; scrotum; survival

Please cite this article as: Omidvari Sh, Hamedei SH, Moaddab-Shoar L, Nasrollahi H, Daneshbod Y, Mosleh-Shirazi MA, et al. Paratesticular Liposarcoma; a Case Report. *Iran J Cancer Prev.* 2014;7(4):239-43.

Introduction

Soft tissue sarcomas have not been very common among the human cancers, but their incidences have been increasing slowly. Radiation, immunodeficiency, some of the drugs, some hereditary indexes and some viruses might have roles in their pathogenesis [1]. Sarcoma in the paratesticular region would be extremely rare [2, 3] and its treatment could not be clear [4]. We have presented the case of a man with more than 1.5 years history of benign scrotal mass and multiple operations. The lesion has finally found as liposarcoma.

Case Report

A 55-year old man has left side inguinal hernia for 30 years but has received no treatment for it. He was a victim of chemical warfare in 1988, and had a Coronary Artery Bypass Graft (CABG) operation in 2005. In January 2010, a mass has appeared in his left scrotum. He had no pain or other symptoms such as fever or dysuria. Serum markers (LDH, AFP, β hCG) were normal. The patient has undergone mass excision in May 2010, and pathology has revealed lipoma. A mass has reappeared 1 year later. Based on the ultrasonography, the right testis was normal and a multi lobulated mass measuring 45×25×25 mm has seen in the left scrotum. The

mass has excised again in July 2011 and pathology has shown a benign spindle cell tumor. None of operations were radical orchiectomy and adjuvant treatment has not administered. Three months later, the lesion has recurred for a second time. After reviewing pathology samples (from the 2nd operation), diagnosis of low grade malignant fibrous histiocytoma has made. In a pelvic CT scan, a hypo-attenuated mass has seen in the left scrotum (Figure 1). The patient has undergone left radical orchiectomy and high ligation of spermatic cord in November 2011. The tumor was a 7 cm creamy yellow, lobulated soft tissue attached to left testis without necrosis or hemorrhage (Figure 2). The surrounding testis has shown no pathology. In the IHC study, tumor cells were positive for CD68 and S100 (Figure 3). Well differentiated liposarcoma has diagnosed (Figure 4). According to the American Joint Committee on Cancer (AJCC) staging system for soft tissue sarcoma (7th ed, 2010), he had a T2aN0 or stage Ib lesion.

Then patient has referred to our hospital for adjuvant therapy. Abdomen and pelvic CT scan, chest X- ray, blood chemistry profile and serum markers (LDH, AFP and β hCG) were normal. The patient has received 50 Gy to the left scrotum and inguinal area, and then after 18 months follow up, has looks like well and disease free.

1. Dept. of Radiation Oncology, Namazi Hospital, Shiraz University of Medical Sciences, Shiraz, Iran

2. Daneshbod Pathology Lab, Shiraz, Iran

3. Colorectal Research Center, Shiraz University of Medical Sciences, Shiraz, Iran

4. Shiraz Institute for Cancer Research, Shiraz University of Medical Sciences, Shiraz, Iran

Corresponding Author:

Hamid Nasrollahi;

Radiation Oncologist

Tel: (+98) 7116474320

Email: Nasrolahiamid@yahoo.com

Received: 4 Apr. 2014

Accepted: 29 May 2014

Iran J Cancer Prev. 2014; 4:239-43

Table 1. Studies that have reported paratesticular sarcoma.

| Author | Age (year) | Presentation | Operation | Adjuvant Treatment | Recurrence | Histopathology |
|---------------|---------------------------------|-------------------------|--------------------------|--------------------|------------------|---------------------------------|
| Dündar [18] | 64 (spermatic cord) | 4 Y mass | Radical Orchectomy | No | No (3 mo) | Liposarcoma |
| Ushida [19] | 75 (spermatic cord) | 3-4 Y mass and swelling | Orchiectomy | No | No (8 mo) | Liposarcoma |
| Novosel [8] | 71 (spermatic cord) | 6 mo mass | Simple Orchectomy | No | No (6 mo) | Liposarcoma |
| Sano [20] | 67 (scrotal wall) | Swelling | Tumor Resection | No Data | No Data | Malignant Mesenchymoma |
| Yol [14] | 63 (scrotal and abdominal mass) | 2 Y mass | Tumor Removal | RT | No Data | Liposarcoma |
| Hagiwara [16] | 78 (spermatic cord) | No Data | High Inguinal Orchectomy | No | After 6 Y, local | Pleomorphic Liposarcoma |
| Kostka [6] | 62 (spermatic cord) | 6 mo (mass) | Radical Orchectomy | No | No (1 year) | Well-Differentiated Liposarcoma |
| May [15] | 39 | 4 years (mass) | Radical Orchectomy | No | No (12 mo) | No Data |
| Iida [21] | 27 | 10 years mass | | No | No (41mo) | Well Diff Leiomyosarcoma |

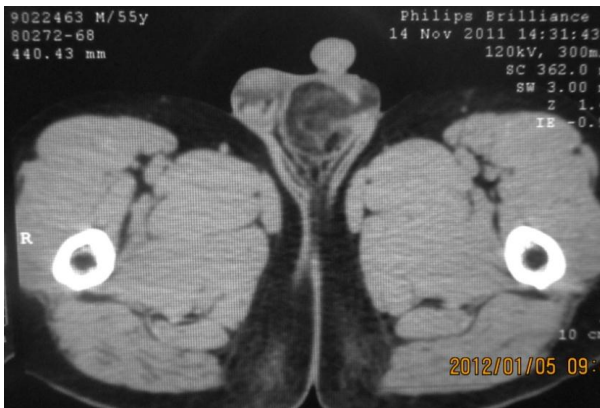

Figure 1. CT Scan has shown a tumor in the scrotum.

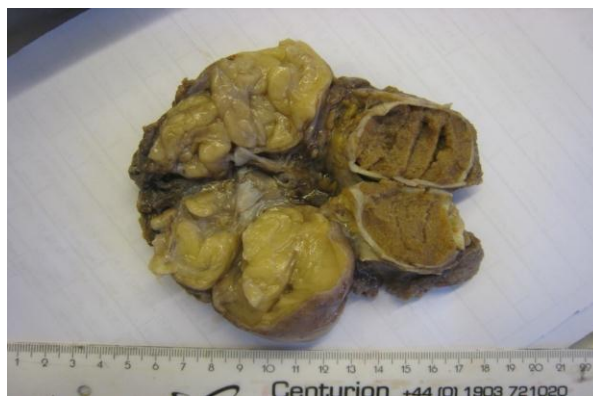

Figure 2. The tumor was creamy yellow, lobulated soft tissue that attached to the left testis without necrosis or hemorrhage.

Discussion

Soft tissue sarcomas have not been common among the humans and have constituted only 1% of adult malignancies. This disease has affected the males more than the females. Most of sarcomas have not associated with risk factors, but some

environmental and genetic predispositions have proposed in a minority of patients [1].

Sarcoma in tunica albuginea and vaginalis, spermatic cord and epididimis (collectively, paratesticular region), scrotal skin and testicles have been very rare [2, 3]. Patients usually have not diagnosed as sarcoma preoperatively, and have often

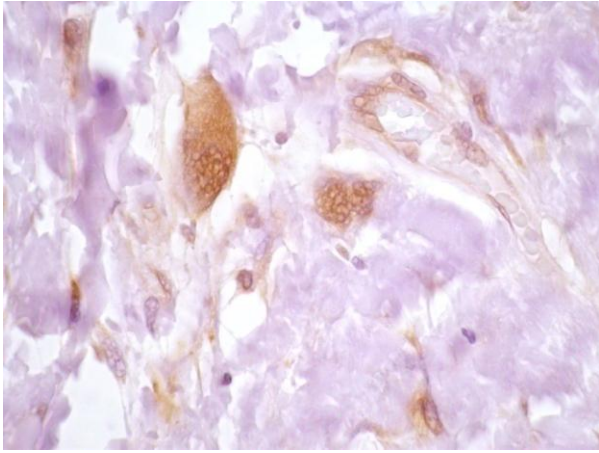


Figure 3. Immuno-histochemical study has shown positivity for S100.

misdiagnosed as benign lesions [2, 5, 6]. Our patient has operated first as a lipoma. Lipoma would be the most common benign lesion in scrotum [7]. Novosel has believed that these malignant lesions have usually found during hernia operations [8]. Soler, in a review of the literature, has believed that most paratesticular liposarcomas have presented as mass [5]. In most reviewed reports, there were long histories of scrotal mass or treatments as benign lesion (Table 1). Paratesticular sarcomas might also have other presentations. Guo et al. has reported a 63 year old man who has presented with Fournier gangrene. After 10 months and multiple operations, pathologic evaluation has shown malignancy. The patient had malignant fibrous histiocytoma of scrotum with lung metastasis and only 1 month survival [9]. In some reports, paratesticular sarcomas have presented as primary testicular tumors [10].

After suspicion of sarcoma, the next step was surgical tumor removal. Extent of surgery for paratesticular sarcoma has not been clear. In most reports, radical orchiectomy has carried out. Kochman has reported local recurrence 3 months after local excision alone for well-differentiated liposarcoma of scrotal wall. After funiculorchidectomy, the patient was disease free for 2 years [11]. But Crespo Atín has suggested that only mass excision was enough [12]. Lymph node dissection has not usually been necessary [6]. Sarcomas have been a diverse group of diseases with different behaviors. Catton et al has reviewed 21 cases during 1958 to 1987 with paratesticular sarcoma and has suggested retroperitoneal lymph node dissection for those patients with rhabdomyosarcoma, intermediate or high grade

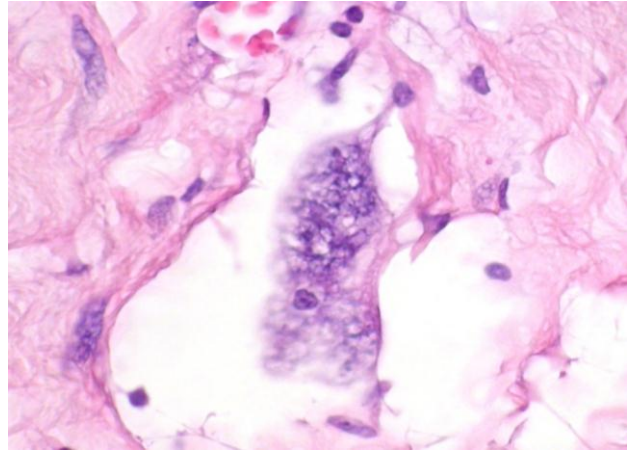


Figure 4. The Pathological image of the well differentiated liposarcoma (HE, original magnification $\times 100$).

malignant fibrous histiocytoma, or fibrosarcoma [13]. Our patient has undergone a second operation due to local recurrence. In both operations, mass excision has performed but has not followed by any adjuvant therapy. In the end, radical orchiectomy has performed for him.

The definite patterns of spread of paratesticular sarcomas are not well defined. Most sites for recurrence are local [4, 5, 7]. Some authors propose hematogenic routes as important for spread in paratesticular sarcomas [2, 7]. Yol et al. reported a 63 years old man with a 2 year scrotal mass and no treatment. Their patient developed abdominal mass; biopsy and the subsequent operation showed a 42 kg retroperitoneal myxoid liposarcoma [14].

Paratesticular liposarcomas have usually well differentiated with good prognosis [15]. Schwartz has reported 6 cases with spermatic cord liposarcoma, one of whom was disease free for 23 years [16]. Liposarcoma was a radiosensitive tumor but its role in paratesticular liposarcoma was not clear. No adjuvant treatment has been considered standard for paratesticular sarcomas [4, 6, 7]. Some believe radiotherapy would be beneficial in recurrent or high grade liposarcoma [5, 15]. Some authors have reported paratesticular sarcomas with a relatively prolonged disease free survival without adjuvant therapy. Hagiwara has reported a 78 years old man with spermatic cord liposarcoma. The patient has not received adjuvant treatment, and was disease free for 6 years before developing local recurrence [16].

The role of chemotherapy in paratesticular sarcoma has not well studied. Fujita has reported a

50-year-old man who had malignant mesenchymoma (consisting of osteosarcoma, leiomyosarcoma, and liposarcoma) of spermatic cord. Their patient has presented with painless swelling in the inguinal area. After orchiectomy, the patient has received 2 courses of the CYVADIC regimen. No recurrence has observed after 12 months when they have reported this patient again [17].

Conclusion

Herein, we have reported a case of paratesticular liposarcoma who has shown good response to surgery and radiotherapy.

Paratesticular liposarcoma would be so rare to have a well-studied clinical presentation, clinical course, treatment and survival. It has seemed presenting good prognosis, but further studies have not needed to draw a conclusion.

Acknowledgment

We would like to thank Miss Vale Mesbah for helping us to prepare this manuscript.

Conflict of Interest

There was not any kind conflict of interest regarding this study.

Authors' Contribution

Shapour Omidvari: Concept and design, acquisition of data, drafting the article, interpretation of data, critical revision of article.

All co-authors: Concept and design, interpretation of data, critical revision of article.

References

- Zahm SH, Fraumeni JF Jr. The epidemiology of soft tissue sarcoma. *Semin Oncol.* 1997;24(5):504-14.
- John T, Portenier D, Auster B, Mehregan D, Drelichman A, Telmos A. Leiomyosarcoma of scrotum--case report and review of literature. *Urology.* 2006;67(2): 424.e13-424.e15.
- Bajaj P, Agarwal K, Niveditha SR, Pathania OP. Leiomyosarcoma arising from tunica vaginalis testis: a case report. *Indian J Pathol Microbiol.* 2001;44(2):145-6.
- Gago Juan A, Luján Galán M, Bustamante Alarma S, Fernández Lobato R, Zárate Rodríguez E, Martín Osés E, Berenguer Sánchez A. A paratesticular myxoid liposarcoma as a simulator of a hernial process. A case report. *Arch Esp Urol.* 1997;50(8):921-3.
- Soler Soler JL, Zuluaga Gómez A, Hidalgo Domínguez MR, Bados Nieto MP, Martínez Torres JL, de la Fuente Serrano A, Nogueras Ocaña M. Liposarcoma of the spermatic cord: a report of a new case and a review of the literature. *Actas Urol Esp.* 1999;23(5):447-54.
- Kostka R, Baitler T, Zachoval R, Sosna B, Palascak P. Liposarcoma of the spermatic cord. *Prog Urol.* 2006;16(2):215-7.
- Yoshino T, Yoneda K, Shirane T. First Report of Liposarcoma of the Spermatic Cord after Radical Prostatectomy for Prostate Cancer. *Anticancer Res.* 2009;29(2):677-80.
- Novosel I, Spajić B, Kraus O, Kruslin B. Liposarcoma of the spermatic cord: case report and review of the literature. *Lijec Vjesn.* 2002;124(5):137-9.
- Guo J, Zhou S, Rao NP, Pez GH. Pleomorphic malignant fibrous histiocytoma/undifferentiated high-grade pleomorphic sarcoma of the scrotum in a patient presenting as fournier gangrene: a case report. *Appl Immunohistochem Mol Morphol.* 2010;18(5):473-8.
- Singla K, Preet Malhotra K, Rathore R, Arora D, Sharma S. Scrotal leiomyosarcoma associated with bilateral epididymo-orchitis. *Urology.* 2011;78(5):1069-70.
- Kochman A, Jabłeczki J, Rabczyński J. Recurrent primary well-differentiated intrascrotal liposarcoma: case report and review of the literature. *Tumori.* 1999;85(2):135-6.
- Crespo Atín V, Padilla Nieva J, Martín Bazaco J, Llarena Ibarguren R, Pertusa Peña C. Scrotal liposarcoma. *Arch Esp Urol.* 2001;54(7):729-32.
- Catton CN, Cummings BJ, Fornasier V, O'Sullivan B, Quirt I, Warr D. Adult paratesticular sarcomas: a review of 21 cases. *J Urol.* 1991;146(2):342-5.
- Yol S, Tavli S, Tavli L, Belviranlı M, Yosunkaya A. Retroperitoneal and scrotal giant liposarcoma: report of a case. *Surg Today.* 1998;28(3):339-42.
- May M, Seehafer M, Helke C, Gunia S, Hoschke B. Liposarcoma of the spermatic cord--report of one new case and review of the literature. *Aktuelle Urol.* 2004;35(2):130-3.
- Schwartz SL, Swierzewski SJ 3rd, Sondak VK, Grossman HB. Liposarcoma of the spermatic cord: report of 6 cases and review of the literature. *J Urol.* 1995;153(1):154-7.
- Fujita T, Akino H, Suzuki Y, Isomatsu Y, Okada K. Malignant mesenchymoma of the spermatic cord: a case report. *Hinyokika Kyo.* 1994;40(2):165-8.
- Dündar M, Erol H, Koçak I, Kaçar F. Liposarcoma of the spermatic cord. *Urol Int.* 2001;67(1):102-3.

19. Ushida H, Johnin K, Koizumi S, Okada Y. Liposarcoma of the spermatic cord in the left scrotum and inguinal region: a case report. *Hinyokika Kyo*. 2000;46(5):349-51.

20. Sano M, Takagi Y, Kimura M, Akagashi K, Hisasue S, Adachi H, et al. Malignant mesenchymoma

in the scrotum. A case report. *Nihon Hinyokika Gakkai Zasshi*. 1998;89(11):903-6.

21. Iida K, Endo M, Tsutsumi M, Ishikawa S. Leiomyosarcoma of the scrotum: a case report. *Hinyokika Kyo*. 2000;46(12):919-21.

Archive of SID