

[Research]

Histopathological changes in liver and gill of *Acipenser persicus* fry in short term exposure to *Nodularia spumigena*

Z. Ramzanpour^{1*}, M. Sattari², J. Imanpour Namin², F. Chobian¹, A. Halajian¹

1- International Sturgeon Research Institute, P.O Box: 41635-3464, Rasht, Iran

2- Fisheries Department, Faculty of Natural Resources, University of Guilan, Sowmeh Sara, Guilan, Iran

* Corresponding author's E-mail: zohreh66@gmail.com

(Received: May.20.2014, Accepted: Oct.09.2014)

ABSTRACT

Persian sturgeon, *Acipenser persicus* is a native, commercially important and highly esteemed fish species in the Caspian Sea. In this study, effects of Nodularin (NODLN), a cyclic pentapeptide hepatotoxin, on liver and gill tissues of *A. persicus* were studied. Nodularin was produced in high amounts by *Nodularia spumigena*, a cyanobacterium species during the algal bloom in the Caspian Sea and was accumulated in biota of the Sea. Persian sturgeon were exposed directly to NODLN as prolonged immersion containing *N. spumigena* in two different doses (1×10^4 and 1×10^8 cells.ml⁻¹) for 24, 48 and 96 hours to examine its histopathological effects on fish liver and gill. Histopathological examinations revealed loss of liver architecture, degeneration of hepatocytes, nuclear pyknosis, karyolysis and finally necrosis of the cells over the time. Observation of gill tissues following immersion in algal cells treatments showed hypertrophy, fusion of secondary lamellae due to proliferation (hyperplasia) of branchial epithelium in low dose and vacuolization of epithelial and pillar cells, telangiectasis, fusion of secondary and primary lamellae, complete necrosis and sloughing of secondary lamellar epithelium in high dose.

Keywords: Bioaccumulation, Nodularin, hepatotoxicity, Caspian Sea, *Acipenser persicus*

INTRODUCTION

Proliferation of cyanobacteria, under favorable conditions is commonly known as algal blooms. In summer, due to anthropogenic (man - made) pollutants, blooms of cyanobacteria occur under calm conditions. Blooms are not always visible, but if there are over 10000 cyanobacterial cells/ml of water, then the water clarity is probably impaired. Algal toxins have been the cause of poisoning and mortality in animals and illness or death in human (Carmichael *et al.*, 1989). Numerous cyanobacterial blooms are well known for their toxin production of toxins. Over 5,000 species of phytoplankton are known, of those, some 300 species form harmful algal blooms (HABs) deleterious to aquatic ecosystems.

Cyanobacteria are known to produce secondary metabolites, commonly known as cyanotoxins. The lysis of the cyanobacterial cells, results in toxic cellular components which is released into the

water. Cyanobacteria contain chlorophyll as a major pigment to absorb light required for photosynthesis. *N. spumigena* is a blue-green algae (also known as cyanobacteria). It produces chains of cells to form mostly straight filaments and is heterocystous and gas-vacuolate planktonic species to form scums. Nodularin (NODLN) is produced in high amounts by the cyanobacterium *N. spumigena* in the Sea. NODLN is composed of 5 amino acids in a peptide ring, consisting of a chemical structure of cyclo (D-MeAsp-L-arginine-Adda-D-glutamate-Mdhh) (Sivonen *et al.*, 1989). Nodularin may accumulate into aquatic organisms and be transferred to higher trophic levels, and eventually affect vector animals and consumers.

The cyanobacterial water blooms are common in the Baltic Sea (Codd & Beattie, 1991), in brackish waters of Australia, New Zealand (Woodward & Shulmeister, 2005). Adverse effects of cyanobacterial exposure mainly characterized by metabolism

disorder in liver. The ability of hepatotoxins to induce liver damage after exposure or injection is so important (Falconer *et al.*, 1994). Reported symptoms of human nodularin toxicity include gastrointestinal upsets, skin and respiratory irritations, headaches, eczema and inflammation of the eyes (Carmichael, 1997).

The Caspian Sea suffers from frequent occurrence of N₂-fixing cyanobacterial water blooms including *N. spumigena*. In September 2005, anomalous algal bloom occurred in the south Caspian Sea. *N. spumigena* once again caused a bloom for a short period of time in coastal water of the southwest Caspian Sea in 2009 and 2010.

Histological analysis appears to be a very sensitive laboratory examination for determination of toxic effects on fish. The liver is a detoxification organ and essential for excretion of toxic substances from the body.

MATERIALS AND METHODS

N. spumigena was collected and isolated during the September 2005 algal bloom in the South Caspian Sea.

Culture medium

The toxic *N. Spumigena* was cultured in modified (without nitrogen resources) liquid Zehnder medium (Kotai, 1972; Staub, 1961; Schlosser, 1994). sodium nitrate (NaNO₃) was eliminated in Modified Zehnder. Medium was prepared from the filtered Caspian Sea water (salinity: 13‰). Cultures were prepared in constant conditions at 23 ± 2°C under fluorescent light (60 μmol photons m⁻² s⁻¹) on a 12 h light: 12 h dark photoperiods.

Cultures were diluted with fresh medium every 48 hours. Filaments added to the fish tanks, was collected in exponential phase. Culture system mixing was achieved manually by stirring on a daily basis or jetpumps (Lavens & Sorgeloos, 1996).

Table 1. Composition and preparation of Zehnder medium (modified)

Stock	Nutrients	Quantities	Stock volume Final	Concentration (ml/l sea water)
1	NaNO ₃	46.7 g	In 300 ml distilled water	3
	Ca(NO ₃) ₂ 4 H ₂ O	5.9 g		
	MgSO ₄ 7H ₂ O	2.5 g		
2	KH ₂ PO ₄	9.3 g	In 300 ml distilled water	1
	Na ₂ CO ₃	6.3g		
	FeCl ₃ + 6H ₂ O	1.3515 g +150 ml distilled water		
A				
3	1.5 ml HCl	2.1915 g + 150 ml distilled Water	H ₂ O (A) 5 ml + (B) 5 ml +490 ml	10
	B			
4	Na ₂ SiO ₃ + 9H ₂ O	25 mg	In 500 ml distilled water	0.08 ml
	H ₃ BO ₃	1550 mg		
	MnCl ₂ + 4H ₂ O	1115 mg		
	(NH ₄) ₆	44mg		
	MO ₇ O ₂₄ +4H ₂ O			
	KBr	59.5 mg		
	KI	41.5mg		
	ZnSO ₄	43.5mg		
Ca(NO ₃) ₂ + 6H ₂ O	73mg			
CaSO ₄ + 5H ₂ O	62.5mg			
Al ₂ (SO ₄) ₃ + 18H ₂ O	237mg			
LiCl+ H ₂ O	25mg			

***N. spumigena* preparation**

N. spumigena cell counts were performed in triplicates and the mean algal cell densities (cells.ml⁻¹) were determined. Counting of cells in filamentous cyanobacteria (*N. spumigena*) was based on filament-by-filament enumeration. The average number of cells per filament was used to translate number of filaments into number of cells (Kankaanpaa et al., 2002)

Fish, Treatment and Sample Preparation or Experimental design

Fish were kept in aquaria for a week to acclimatize and fed only once a day. The water parameters in this period were: temperature 22.3 - 24.5°C; salinity 10‰ and pH 8.01. Before any fish handling, they were anaesthetized using clove powder 150mg.l⁻¹ and randomly divided into three groups and placed into nine aquaria (three replicates in each group). The aquaria were filled with sea water and fish were randomly distributed into aquaria. Sea water volume was kept constant (68 liter in each aquarium). Fish were collected at 12, 24, 48, and 96h after exposure in triplicate

and were immediately used for analysis. Fish were killed and body cavity was dissected, Liver samples were taken for histological analyses and were fixed in buffered 4% formaldehyde (Bucke, 1972).

Exposure to *N. Spumigena* cells

Fish were immersed in aquaria containing *N. spumigena* for exposure in three experimental treatments. Toxic treatments contained *N. spumigena* at two cell densities (1×10⁴ cells.ml⁻¹: low dose group and 1×10⁸ cells.ml⁻¹: high dose group) and the third group as control (non-toxic control). All treatments were in triplicate.

Experiment tanks were constantly aerated and the overall behavior of the fish was monitored daily.

RESULTS

No effects of NODLN on fish behavior were observed. There were no fish mortalities throughout the experiment. During the samplings, all fish appeared to be normal, and there were no obvious pathological symptoms apparent at autopsy.

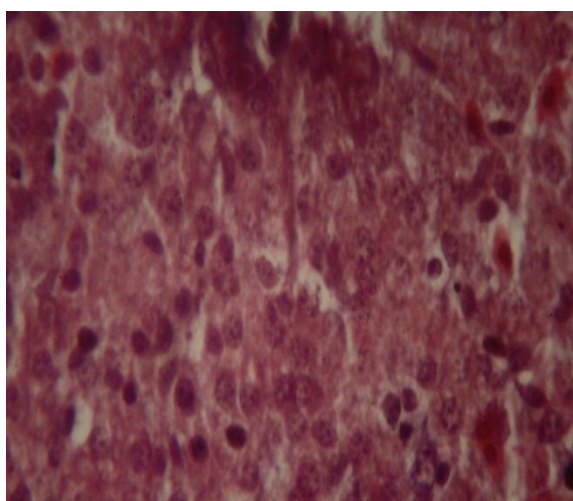


Fig. 1

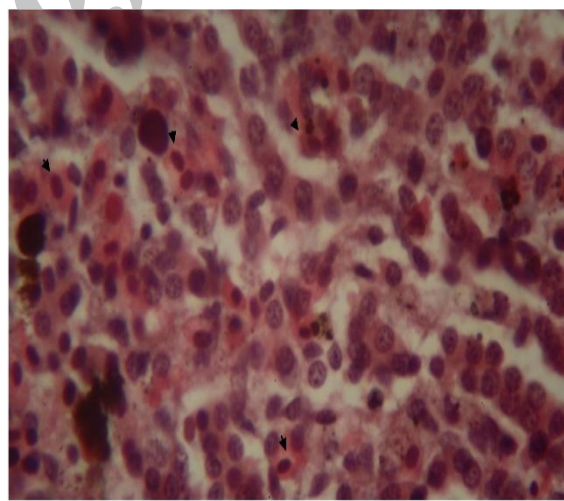


Fig. 2

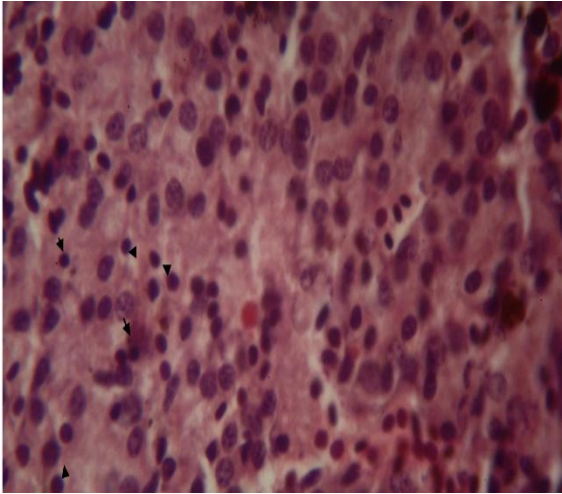


Fig. 3

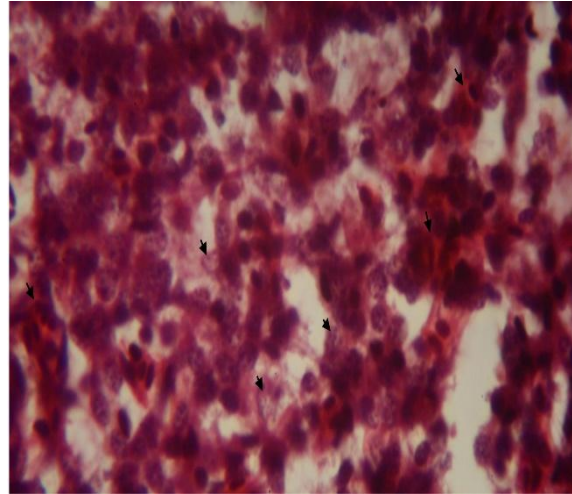


Fig. 4

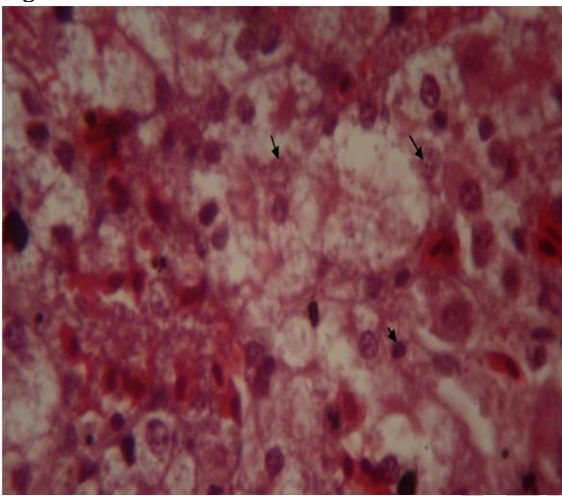


Fig. 5

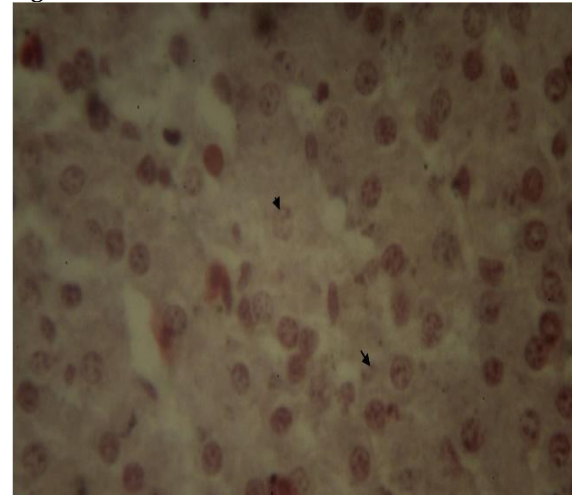


Fig. 6

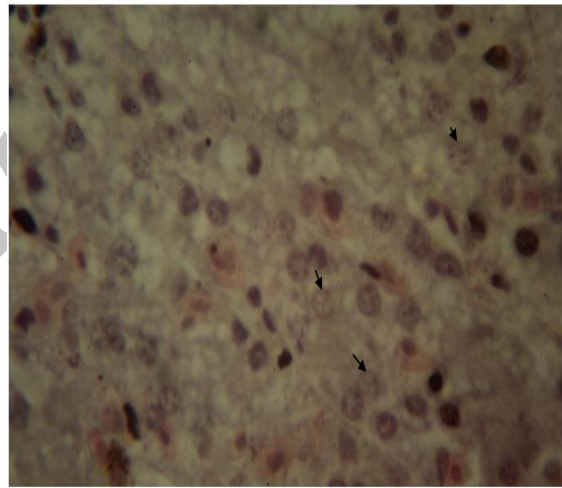


Fig. 7

Figs. 1-7: H & E stained liver tissue section of Persian sturgeon, *A. persicus*, exposed to water with immersed *N. Spumigena* (400X). **Fig. 1:** control; **Fig. 2:** 24 h after immersion in a 10^4 cells.ml⁻¹ *N. spumigena* treatment showing hemorrhages (red blood cells, arrows) and vacuolation of hepatocytes; **Fig. 3:** 48 h after immersing in a 10^4 cells.ml⁻¹ showing pyknosis, clamping and condensed chromatin; **Fig. 4:** 96 h after immersion in a 10^4 cells.ml⁻¹ showing hemorrhage and also karyorhexis of hepatocytes (arrows); **Fig. 5:** 24h after immersing in a 10^8 cells.ml⁻¹ showing hemorrhages, vacuolation and pyknosis, karyorhexis, karyolysis and necrosis of hapatocytes; **Fig. 6:** 48 h after immersion in a 10^8 cells.ml⁻¹ showing karyolysis (arrows), extensive necrosis and loss of hepatocytes; **Fig. 7:** 96 h after immersing in a 10^8 cells.ml⁻¹ showing overt necrosis of hepatocytes and also different phases of necrosis including karyorexis and karyolysis.

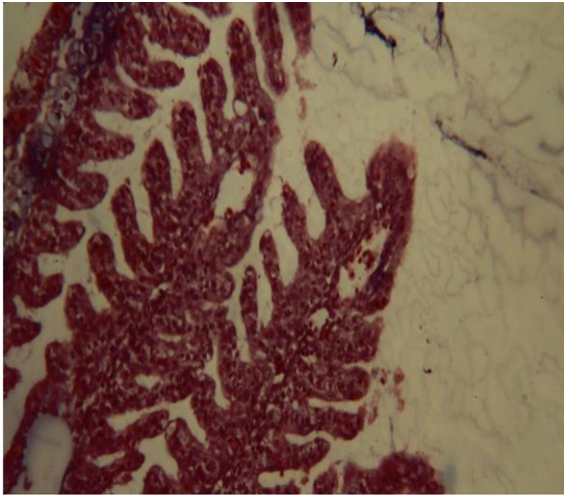


Fig. 8

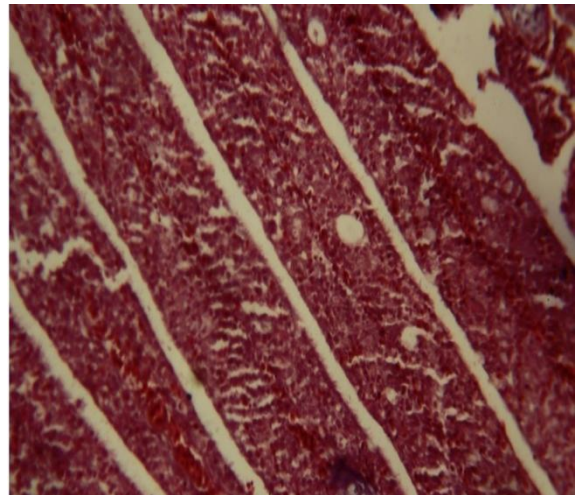


Fig. 9

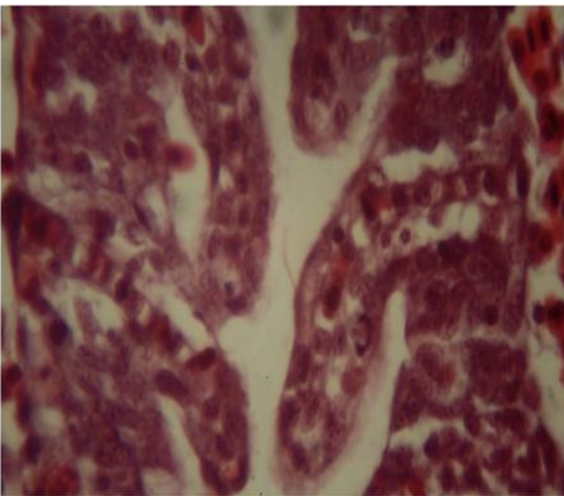


Fig. 10

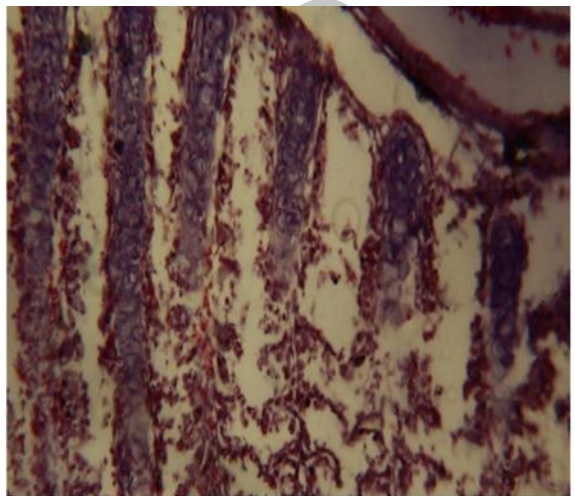


Fig. 11

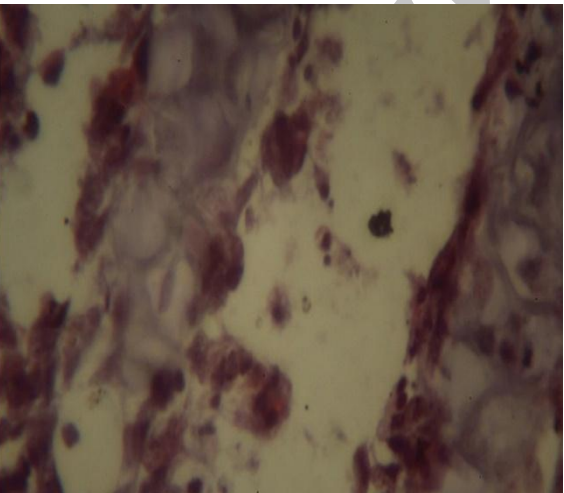


Fig. 12

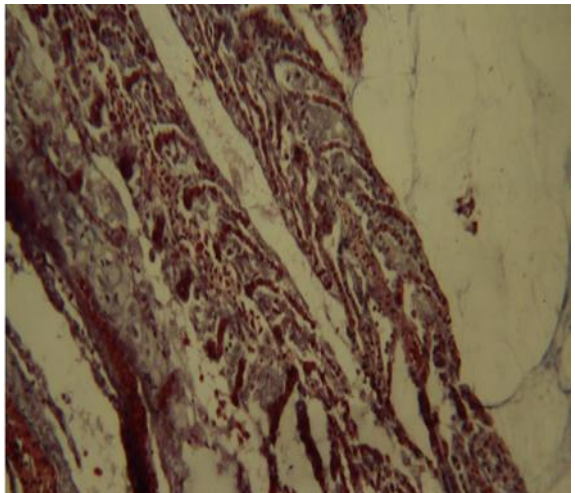


Fig. 13

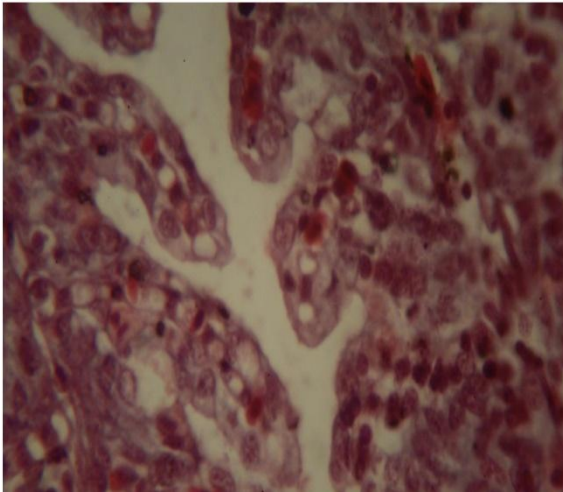


Fig. 14



Fig. 15

Figs. 8-15: H & E stained gill tissue section of Persian sturgeon, *A. persicus*, exposed to water with immersed *N. spumigena*. **Fig. 8:** Control, 100X; **Fig. 9:** Gill 24 h after immersion in a 10^4 cells.ml⁻¹ treatment showing fusion of secondary lamellae due to proliferation (hyperplasia) of branchial epithelium (100X); **Fig. 10:** 48 h after immersing in a 10^4 cells.ml⁻¹ treatment (400X) showing hypertrophy of epithelial cells; **Fig. 11:** 96 h after immersion in a 10^4 cells.ml⁻¹ showing necrosis and sloughing of secondary lamellar epithelium (40X); **Fig. 12:** 96 h after immersion in 10^4 cells.ml⁻¹ showing complete necrosis and sloughing of lamellar epithelium (400X); **Fig. 13:** 24 h after immersion in a 10^8 cells.ml⁻¹ showing fusion of secondary lamellae and tellangiectasis (40X); **Fig. 14:** 48 h after immersion in 10^8 cells.ml⁻¹ showing extensive lamellar hypertrophy and also vacuolization of epithelial and pilar cells (400X); **Fig. 15:** 96 h after immersion in a 10^8 cells.ml⁻¹ showing fusion of secondary and primary lamellae (100X).

Histopathological Observation

The hepatocyte degeneration and necrosis were observed in a time dependent manner. After 24 h exposure to low dose of *N. spumigena*, hemorrhages (red blood cells, arrows) and vacuolation of hepatocytes were observed. Pyknosis, clumping and condensed chromatin were observed after 48 hours exposure to low dose. After 96h, hemorrhage and also karyorhexis of hepatocytes were apparent. Following 24 h exposure to high dose of *N.spumigena*, hemorrhages, vacuolation and pyknosis, karyorhexis, karyolysis and necrosis of hapatocytes were evident. Karyolysis, extensive necrosis and loss of hepatocytes were apparent 48 h post - exposure to high dose. After 96 h some focal necrosis of hepatocytes (necrotic cells) associated with pyknotic nuclei were observed.

Observation of gill tissues following 24 h after immersion in a 10^4 .ml⁻¹ algal cells (*N. spumigena*) treatment showed fusion of secondary lamellae due to proliferation (hyperplasia) of branchial epithelium; After 48 h immersion in a 10^4 cells.ml⁻¹ treatment, hypertrophy of epithelial cells was visible and 96 h after immersion in a

10^4 cells.ml⁻¹, complete necrosis and sloughing of secondary lamellar epithelium was found; After 24 h immersion in a 10^8 cells.ml⁻¹, fusion of secondary lamellae and tellangiectasis was observed; 48 h after immersion in a 10^8 cells.ml⁻¹, showed extensive lamellar hypertrophy and vacuolization of epithelial and pilar cells and finally by the end of 96 h immersion in a 10^8 cells.ml⁻¹, fusion of secondary and also primary lamellae was apparent.

DISCUSSION

Although the Caspian Sea has experienced frequent occurrence of N₂-fixing cyanobacterial water blooms by *N. spumigena*, but few reports have been released about the effects of these blooms on fish species inhabiting the Sea basin.

Persian sturgeon is a commercially important and highly steemed fish species in the Caspian Sea which is caught by industrial fishermen. The species is native to the Caspian Sea and may be affected by cyanobacterial blooms.

The present study indicated that exposure of Persian sturgeon in immersion of *N.*

spumigena induces changes in liver and damages hepatocytes. The histopathological changes of liver in the present study were to some extent similar to the changes described in various papers in other fish species. There are several reports about different exposure routes of algae to fish. Pekka *et al.* (2009) used single and repeated oral exposure of *N. spumigena* on flounder, *Platichthys flesus* and observed that the architecture of the liver focally a little incoherent, but not totally destroyed. In the livers the cell shape was not strict and easily seen. Apparently round lipid vacuoles were also noticed. Focal areas with numerous degenerative liver cells, shrinkage of the cytoplasm, loss of nucleolus and pyknotic nuclei were also detected.

Kankaanpaa *et al.* (2002), exposed Baltic sea trout, *Salmo trutta m. fario* L., orally to a single dose of food containing NODLN (125 mg/kg w.w.) from *N. spumigena* and concluded that NODLN rapidly induces severe but reversible liver damage.

Li & Xie (2009) used intraperitoneal administration of microcystins (MCs) to silver carp. They reported that the liver of MC - treated fish had alterations in its structure, the severity of which increased with the time of exposure to MCs. One and three hours after injection of MCs, changes occurred mainly in the pericentral region of liver and were characterized by the appearance of hepatocytes with condensed cytoplasm. Twelve hours after injection of MCs, the typical chord structure disappeared, condensation and vacuolation in the cytoplasm of hepatocytes became more conspicuous and extended to a larger area of the liver. In addition, slight hemorrhage from ruptured vessels were also visible. 24 and 48 hours after injection of MCs, hemorrhage and tissue damage involved the whole liver. Most of the liver cells were swollen and lost their granular appearance with chromatin clumping and condensation, which were most likely necrotic.

Rodger *et al.* (1994) described the histopathological changes of brown trout, *Salmo trutta*, associated with the death of water bloom of *Anabaena flos-aquae*. The changes in liver were characterized by confluent necrosis showing cellular degeneration and loss of obvious cell

boundaries. Pyknosis and karyorrhexis of hepatocytes was obvious. Similar changes in liver have been described in different fish species by other authors (Garcia, 1989; Rabergh *et al.*, 1991; Tencalla *et al.*, 1994).

Fischer *et al.* (2000) indicated that hepatocyte necrosis represents primary events in microcystin - induced hepatotoxicity in the rainbow trout and apoptotic cell death seems to be of only secondary nature. Fischer and Deitrich (2000) suggested that in comparison to the pathological events in salmonids exposed to microcystin, in which a slower development of pathology and primarily necrotic cell death prevails, the pathology in the carp develops rapidly and at lower toxin concentrations. According to these authors, this is most likely due to a more efficient uptake of toxins, while the mechanism of cell death is primarily apoptosis.

Khalili *et al.*, (2013) exposed Caspian Kutum, *Rutilus kutum* directly to NODLN by prolonged immersion in a bath containing *N. spumigena* in two different doses for 12, 24, 48, 96 h and observed loss of liver architecture, degeneration of hepatocytes, pyknosis, karyolysis and finally necrosis of these cells over the time. In the present study, the damage of liver in fish occurred in long term exposure. The degree of damage depended on the concentration of the extract.

REFERENCES

- Bucke, D. (1972) Some histological techniques applicable to fish tissues, In: L.E. Mawdesley-Thomas, Editor, *Diseases of Fish*, Academic Press, London pp. 153-189.
- Carmichael, W.W. (1992) Cyanobacteria secondary metabolites – the cyanotoxins. *Journal of Applied Bacteriology*, **72**: 445-459.
- Carmichael, W.W. (1997) The cyanotoxins, *Advanced Botanical Research*, **27**: 211-256.
- Codd, G.A., & Beattie, K.A. (1991) Cyanobacteria (blue-green algae) and their toxins: awareness and action in the United Kingdom. *PHLS Microbiology Diagnosis*, **8**: 82-86.
- Falconer, I.R., Burch, M.D., Steffensen, D.A., Choice, M., & Coverdale, O.R. (1994) Toxicity of the blue green alga

- (cyanobacterium) *Microcystis aeruginosa* in drinking water to growing pigs, as an animal model for human injury and risk assessment. *Environmental Toxicology and Water Quality*, 9: 131-139.
- Kankaanpaa, H., Vuorinen, P.J., Sipia, V., & Keinanen, M. (2002) Acute effects and bioaccumulation of nodularin in sea trout (*Salmo trutta m. trutta* L.) exposed orally to *Nodularia spumigena* under laboratory conditions. *Aquatic Toxicology*, 3: 155-68.
- Khalili, S. (2014) Histopathological changes in liver and gill of *Rutilus kutum* fry in short term exposure to *Nodularia spumigena*. MSc dissertation, University of Guilan, Sowmeh Sara, Iran, pp. 85
- Kotai, J. (1972) Instruction for preparation of modified nutrient solution Z8 for algae. *Publication B-Norwegian institute for water research*, Blindern, Oslo. 5: 11-69.
- Lavens, P. & Sorgeloos, P. (1996) Manual on the production and use of live food for aquaculture. *FAO fisheries Technical Paper*, No. 361. 295pp. ISBN: 92-5-103934-8130.
- Li, L. & Xie, P. (2009) Hepatic histopathological characteristics and antioxidant response of phytoplanktivorous silver carp intraperitoneally injected with extracted microcystins. *Biomedical and Environmental Sciences*, 22:297-302
- Qiu, T., Xie, P., Guo, L. & Zhang, D. (2009) Plasma biochemical responses of the planktivorous filter-feeding silver carp (*Hypophthalmichthys molitrix*) and bighead carp (*Aristichthys nobilis*) to prolonged toxic cyanobacterial blooms in natural waters. *Environmental Toxicology and Pharmacology*, 27: 350-356.
- Raberg, C.M.I., Bylund, G., & Eriksson, J.E. (1991) Histopathological effects of Microcystin -LR, a cyclic peptide toxin from the cyanobacterium (blue-green algae) *Microcystis aeruginosa*, on common carp (*Cyprinus carpio* L.), *Aquatic Toxicology*, 20:131-146.
- Schlosser, U.G. (1994) Sag-Sammlung-Von-Algenkulturen at the University of Göttingen-catalog of strains. *Acta Botanica*, 107: 114-186.
- Sivonen, K., Kononen, K., Carmichael, W. W., Dahlem, A.M., Rinehart, K.L., Kiviranta, J., & Neimela, S.I. (1989) Occurrence of the hepatotoxic cyanobacterium *Nodularia spumigena* in the Baltic Sea and structure of the toxin. *Applied Environmental Microbiology*, 55: 1990-1995.
- Staub, R. (1961) Ernährungs physiologisch-autökologische Untersuchungen an der planktonischen Blaualge *Oscillatoria rubescens* DC. - Schweiz. *Z. Hydrology* 23: 82-198.
- Tencalla, G.F., Dietrich, R. D., & Schlatter, C.H. (1994) Toxicity of *Microcystis aeruginosa* peptide toxin to yearling rainbow trout (*Oncorhynchus mykiss*). *Aquatic Toxicology*, 30: 215-224
- Woodward, C.A. & Shulmeister, J. (2005): A Holocene record of human induced and natural environmental change from lake Forsyth (TeWairewa), New Zealand. *Journal of Paleolimnology* 34: 481-501.

تغییرات هیستوپاتولوژیک بافت کبد و آبشش بچه تاسماهی ایرانی *Acipenser persicus* در مواجهه کوتاه مدت با *Nodularia spumigena*

ز. رمضانپور^{1*}، م. ستاری²، ج. ایمانپور نمین²، ف. چوبیان¹، ع. حلاجیان¹

1- انستیتو تحقیقات بین المللی ماهیان خاویاری دکتر دادمان، رشت، ایران

2- گروه شیلات دانشکده منابع طبیعی دانشگاه گیلان، صومعه سرا، ایران

(تاریخ دریافت: 93/2/31 - تاریخ پذیرش: 93/7/20)

چکیده

تاس ماهی ایرانی (*Acipenser persicus*) گونه بومی و تجاری مهم دریای خزر می باشد. در این مطالعه اثرات نودولارین (NODLN) یک سم کبدی پنتا پتید حلقوی بر روی بافت کبد و آبشش بچه تاسماهی ایرانی بررسی شد. نودولارین در مقادیر بالا توسط جلبک سیانوباکتری *Nodularia spumigena* در هنگام شکوفایی در دریای خزر تولید شده و در بافت بدن موجودات دریای خزر تجمع می یابد. تاسماهی ایرانی مستقیماً در معرض سم نودولارین به صورت غوطه وری طولانی در دو دوز مختلف (1×10^4 و 1×10^8 سلول سیانوباکتری در میلی لیتر) به مدت 24، 48 و 96 ساعت قرار گرفت تا اثرات هیستوپاتولوژیک آن روی بافت کبد و آبشش ارزیابی شود. مطالعات هیستوپاتولوژیک تخریب ساختار کبد، استحاله سلول های کبدی، پیکنوز هسته، کاربولیز و در نهایت نکروز سلول ها را به مرور زمان نشان داد. مشاهده بافت آبشش پس از غوطه وری در تیمارهای جلبکی، هیپرتروفی، جوش خوردن تیغه های ثانویه در اثر تزاید (هیپرپلازی) بافت پوششی آبشش در دوز پایین و واکوئول دار شدن سلول های پوششی و ستونی، تلانژیکتازی، جوش خوردن تیغه های ثانویه و اولیه، نکروز کامل و پوسته پوسته شدن بافت پوششی تیغه های ثانویه در دوز بالا را نشان داد.

* مولف مسئول