

## Ganglioneuroma of Retroperitoneum: a Case Report

Mehrdad Payandeh,<sup>1</sup> Mehrnosh Acinfar,<sup>1</sup> Mohammad Erfan Zare,<sup>1,2</sup> Mohammad Ali Hessami,<sup>3</sup> Abolghasem Mirbahary<sup>4</sup>

<sup>1</sup>Medical Biology Research Center, Kermanshah University of Medical Science, Kermanshah, Iran

<sup>2</sup>Student Research Committee, Kermanshah University of Medical Science, Kermanshah, Iran

<sup>3</sup>Department of Surgical Oncology, Kermanshah University of Medical Science, Kermanshah, Iran

<sup>4</sup>Department of Pathology, Kermanshah University of Medical Science, Kermanshah, Iran.

**Corresponding author:** Mehrdad Payandeh, MD, Hematologist- Oncologist

Medical Biology Research Center, Sorkheh Lizheh, Kermanshah University of Medical Sciences (KUMS), Kermanshah, Iran.

P.O.Box: 1568,

Tel.: +98 831 4276473; Fax: +98 831 4276471

Email: md.payandeh@yahoo.com

### Abstract

Ganglioneuromas presented as a retroperitoneal tumor around the vital organs is a rare entity. A case with unusual presentation is reported. Young woman of 44 years old presented without any complaint, that known during incidental abdominopelvic ultrasonography. It was treated with partial resection for debulking surgery. Debulking surgery with preservation of organ functions is feasible in these slow growing tumors for better quality of life.

**Keywords:** Ganglioneuroma, Retroperitoneal, Surgery

### Introduction

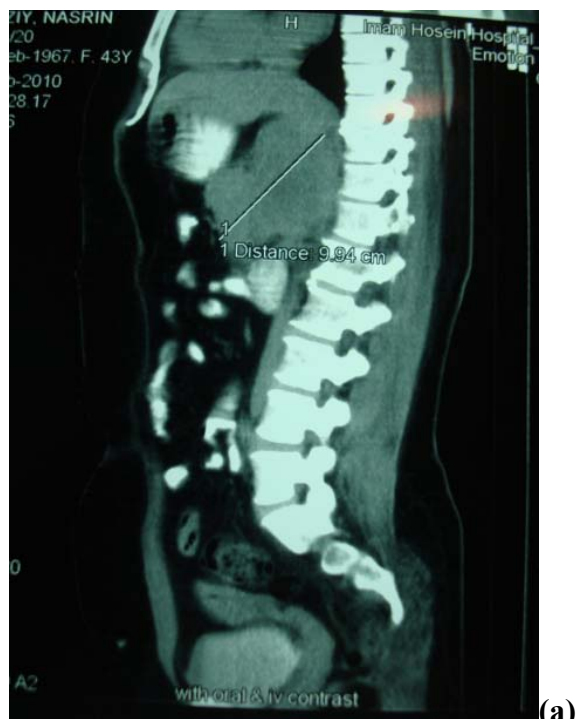Ganglioneuromas and ganglioneuroblastomas are tumors of the sympathetic nervous system that originate from neural crest sympathogonia, which are completely undifferentiated cells of the sympathetic nervous system. Along with neuroblastomas, ganglioneuromas and ganglioneuroblastomas are collectively known as neuroblastic or neurogenic tumors. These tumors are commonly seen in young population.(1) They are highly differentiated benign tumors and are compatible with long-term disease free survival even though surgical treatments are unsatisfactory.(2)

### Case Report

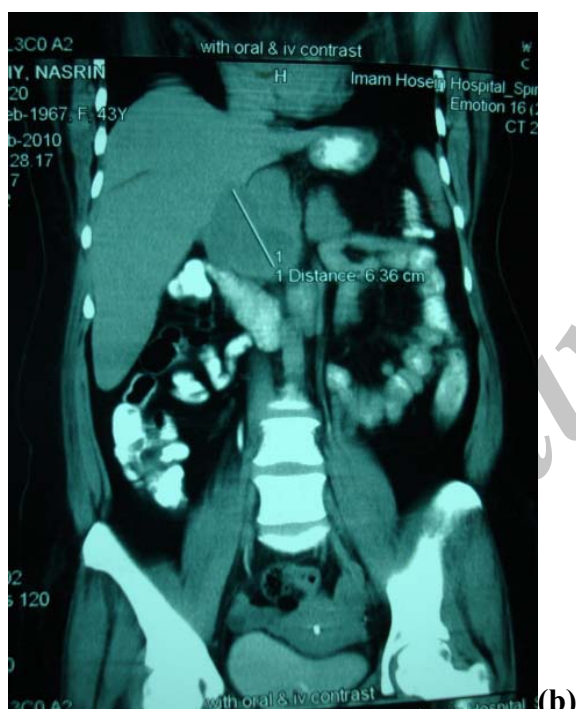The young woman was 44 years old female coming to us with complains of painless central abdominal mass that known during incidental abdominopelvic ultrasonography. She had history of occasional unspecific abdominal pain for last 3 months of visit. She was well oriented.

On physical examination his vital signs were normal. He looked pallor. Chest was clinically clear. abdominal examination was normal. No

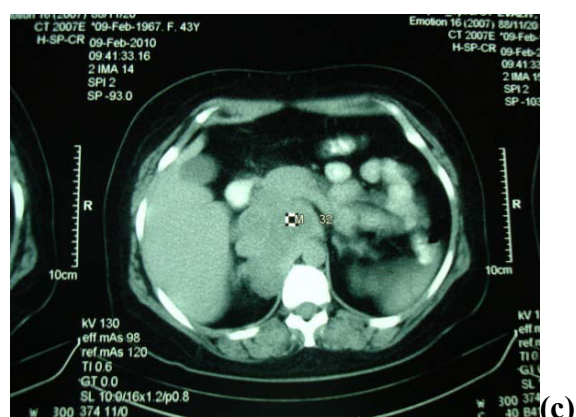hepatosplenomegaly was there. No shifting dullness was there. Bowel sounds were existing and normal. On Investigations hemoglobin was 10.5 g/dl, other blood parameters were within normal limit. Chest x-ray revealed nothing, Liver Function Tests and Renal Function Tests were normal. 5-HIAA and VMA of 24 urine collection be in normal range. Computed Tomography (CT) scan of the abdomen and pelvis was taken that showed a mass of homogenous density was arising from the central retroperitoneum encircling the aorta covering liver form lateral wall coming towards dome and anteriorly. It was spreading into the pelvic and bilateral iliac vessels (Figure- 1). Other abdominal viscera looked normal. Occult blood was negative. As all were inconclusive for management, laparotomy was done for exploration and biopsy. It revealed a 15 ×10cm<sup>2</sup> soft to medium consistency mass was arising from the retroperitoneum anterior to the pancreas. That revealed it to be a Neural tumor possibly Ganglioneuroma. We decided to debulk the tumor, but due to tense vascular involment it is impossible, and only small debulking was doing. On cross section the tumor was white in color with multiple nodules of varying



(a)

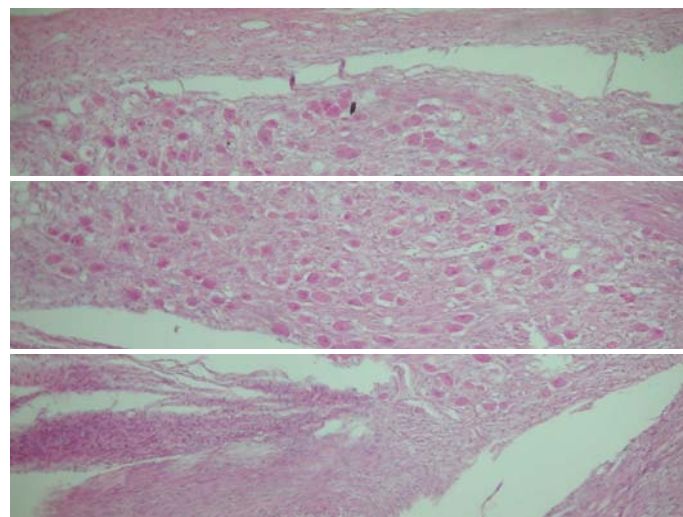


(b)



(c)

**Figure- 1.** CT scan of abdomen showing Retroperitoneal widening of soft tissues (a, b, c).



**Figure- 2.** Microphotograph of the histopathology slide on H&E Staining showing ganglion cells on X 10 magnification.

sizes in it. Ascites was nil. No peritoneal seedling of tumor was there. Post-operative period was uneventful; patient was discharged on 3<sup>th</sup> postoperative day. Final permanent section conformed the diagnosis of Ganglioneuroma (See Figure- 2).

### Pathology report

It is composed of proliferated spindle cells having elongated somewhat wavy nuclei arranged in interlacing pattern with formation various size nerve bundles the neoplasm entrapped sympathetic ganglia and contains mature ganglion cell, some with intact surrounding sustentacular cells. The neoplasm is circumscribed showing a fibrotic capsule in the periphery of the fragments. there is no immature neuroblastic elements throughout sections. An occasional focal lymphoid aggregate is present throughout lesion.

### Discussion

Most frequently occurring in the abdomen, these tumors can grow wherever sympathetic nervous tissue is found. Common locations for ganglioneuromas and ganglioneuroblastomas include the adrenal gland, paraspinal retroperitoneum (sympathetic ganglia), posterior mediastinum, head, and neck; it is uncommon to find them in the urinary bladder, bowel wall, abdominal wall, and gallbladder. Among these, ganglioneuromas are the most common neoplasm of the sympathetic nervous system in adults.(3) Ganglioneuromas are thought to be the fully differentiated counterpart of neuroblastomas. They may occur spontaneously or during the therapy for

neuroblastomas with either chemotherapy or radiation therapy.(2)

### Pathophysiology

Ganglioneuromas, ganglioneuroblastomas, and neuroblastomas are histologically differentiated by their stage of neuroblast maturation.(3) Ganglioneuromas are composed of mature ganglion cells and are considered benign tumors. Ganglioneuroblastomas and neuroblastomas are less mature and are considered more aggressive and dangerous. These tumors have a higher neuroblast content and tend to occur in young children (median age: 2 years).

Composite neuroblastic tumors have been described as well; these tumors may have malignant nerve-sheath or pheochromocytoma tumors growing within them. In rare cases, von Recklinghausen disease, Beckwith-Wiedemann syndrome, Hirschsprung disease, central failure of ventilation, and DiGeorge syndrome have been associated with ganglioneuroma and ganglioneuroblastoma.(4)

In general, neuroblastic or neurogenic tumors appear radiologically as well-circumscribed, smooth or lobulated masses that may contain calcifications. The benign (ganglioneuromas) and malignant (ganglioneuroblastomas) forms of these tumors are virtually identical radiologically. The only differentiating factor is the possibility of distant metastases with malignant ganglioneuroblastomas.

Ganglioneuromas common in 10 to 30 years old age group with more predominance in pediatric age group. The reported incidence of this disease is one per million population. They are mostly sporadic but there are a few reports of ganglioneuromas associated with neurofibromatosis type II and multiple endocrinologic neoplasia type II.(4) Ganglioneuromas can be found in the central nervous system or peripherally in the sympathetic system.(5) The most common localization is the posterior mediastinum followed by the retroperitoneal space.(1) Among the primary retroperitoneal tumors, they constitute only a small percentage of 0.72 to 1.6.(2) Pelvic retroperitoneal localization like in our's is even rarer. There are a few reports of ganglioneuroma involving the lesser pelvis and pelvic floor.(6-8)

Retroperitoneal ganglioneuromas are usually non-functioning and asymptomatic until they reach large sizes in which case they cause symptoms due to local expansion and pressure on adjacent structures.(2) Although symptoms of autonomic dysfunctions are usually seen in patients with

hormone secreting ganglioneuromas, such symptoms may also be seen in patients with paravertebral ganglioneuromas compressing the autonomic fibers of the lumbosacral plexus.(9) Also, there are functional ganglioneuromas that were found to release peptides such as vasoactive intestinal peptides (VIP), somatostatins and Neuropeptide Y (NPY) in the literature.(1, 10) These tumors may cause some symptoms like diarrhea, sweating and hypertension related to those peptides. Diarrhea in this patient can be caused by this kind of intestinal peptides. Since ganglioneuromas may release catecholaminergic peptides, surgeons should be aware of the possibility of hypertensive crisis during the surgery.(1, 10, 11)

Preoperative diagnosis of retroperitoneal ganglioneuroma is often difficult and the diagnosis is usually based on histopathological findings after surgical excision of the tumor. Although in some cases aspiration cytology with fine needle has been reported to be useful in the preoperative diagnosis of adrenal ganglioneuroma, since the tumoral tissue can contain fractions of less well differentiated areas, surgical exploration is required to achieve a definitive diagnosis and risk assessment.(4, 10)

Radiological examination also has no diagnostic value in most cases. In a study of thirteen retroperitoneal ganglioneuromas, it was concluded that unless typical CT or MRI findings are present, diagnosis of ganglioneuromas is difficult radiologically.(2) A well-circumscribed mass with a tendency to partially or completely surround blood vessels without compressing the lumen was the mainstay of these findings.(5) Visualization of this close relation perhaps may be the most important gain of imaging techniques before attempting a large excision for the surgeons. For the pure ganglioneuromas, heterogeneous high signal intensity on T2 weighted MR images may be helpful in the differential diagnosis of other retroperitoneal masses but more studies are needed especially for the mixed pathologies such as the ganglioneuroma-pheochromocytoma combination.(5, 12) Because of the rarity of retroperitoneal ganglioneuromas and absence of any characteristic radiologic features, imaging of these tumors is not reliable and diagnostic.(1)

In some studies, certain tests for elevated serum or urinary hormonal levels were studied as a screening test in patients with retroperitoneal tumors but larger series are needed to postulate any universal marker for the specific and differential diagnosis of ganglioneuromas and neuroblastomas.(1, 2, 3, 13)



Grossly, they are large, encapsulated masses of firm consistency with an homogenous, solid, grayish white cut surface. Areas with different color or consistency should be sampled for microscopic examination with the suspicion of less differentiated foci. They can be multiple and or associated with other independent types of neurogenous neoplasms such as neuroblastoma and pheocromocytoma.(3) Microscopically, it consists of a spindle cell tumor resembling a neurofibroma but shows numerous ganglion cells. Microscopically ganglioneuromas have two subtypes. The mature subtype consists of a spindle cell tumor resembling a neuroblastoma but have fascicles composed of neuritic processes, Schwann cells and perineural cells and show numerous ganglion cells. The maturing subtype has a similar stroma but with ganglion cells of differing maturation, from fully mature ones to neuroblasts. Immunohistochemically they are characterized by reactivity with S100 and neuronal markers such as NSE and synaptophysin.(14)

Ganglioneuromas are typically slowly growing, benign tumors and have a tendency to remain clinically silent for a considerable time. They can occur as a result of the necrosis of immature neuroblasts from the malignant neuroblastomas in the primary or any metastatic site. The probability of reoccurrence of neuroblastoma from the ganglioneuroma is not known but at least one case has been reported 15 years after conversion to ganglioneuroma. Most patients have prolonged survival without any evidence of progression.(2)

## Conclusion

According to many authors, surgical excision is sufficient for the treatment.(15) Preoperative or postoperative chemotherapy or radiotherapy have no value in the treatment except it was associated with ganglioneuroblastoma changes when there might be some role of chemotherapy.(2) Even with the residual disease; cessation of all other treatments and a close follow-up may be adequate. If any progression of the tumor is seen during follow-up, re-biopsy or laparotomy may be indicated.

With the knowledge of the tumors biology, surgeons may attend to less radical operations in the aim of total resection of the tumor. Due to the close relations to large vessels, some potentially life-threatening complications may be seen during the surgical resection. In this particular case, if we go for total surgical removal, it definitely needed a total pelvic exenteration. It definitely raises a Quality of life (QOL) issue for he has no bowel or

urinary symptoms so far. According to our knowledge, this is the first diagnosed case of ganglioneuroma of abdominal cavity in our hospital. Although retroperitoneal ganglioneuromas are very rare lesions, it should be kept in mind for the differential diagnosis of pelvic masses. As it is a slow growing tumor, gross total surgical removal with preservation of organ functions is a feasible surgical option. At this time patient is stable without any symptom and not suffering of sweating, diarrhea or hypertension. And do not need any surgical procedure and according most decision for this disease is only in close follow up.

## References

1. De Bernardi B, Gambini C, Haupt R, Granata C, Rizzo A, Conte M, et al. Retrospective study of childhood ganglioneuroma. *J Clin Oncol*. Apr 1 2008; 26 (10): 1710- 6. [Medline].
2. Shimada H, Ambros IM, Dehner LP, et al. Terminology and morphologic criteria of neuroblastic tumors: recommendations by the International Neuroblastoma Pathology Committee. *Cancer*. Jul 15 1999; 86 (2): 349- 63. [Medline].
3. Lonergan GJ, Schwab CM, Suarez ES, Carlson CL. Neuroblastoma, ganglioneuroblastoma, and ganglioneuroma: radiologic- pathologic correlation. *Radiographics*. Jul- Aug 2002; 22 (4): 911- 34. [Medline].
4. Shin JH, Lee HK, Khang SK, et al. Neuronal tumors of the central nervous system: radiologic findings and pathologic correlation. *Radiographics*. Sep- Oct 2002; 22 (5): 1177- 89. [Medline].
5. Mawaja S, Materne R, Detrembleur N, de Leval L, Defechereux T, Meurisse M. Adrenal ganglioneuroma. *Am J Surg*. Nov 2007; 194 (5): 683- 4. [Medline].
6. Geoerger B, Hero B, Harms D, et al. Metabolic activity and clinical features of primary ganglioneuromas. *Cancer*. May 15 2001; 91 (10): 1905- 13. [Medline].
7. Brouwers FM, Eisenhofer G, Lenders JW, Pacak K. Emergencies caused by pheochromocytoma, neuroblastoma, or ganglioneuroma. *Endocrinol Metab Clin North Am*. Dec 2006; 35 (4): 699- 724, viii. [Medline].
8. Patterson AR, Barker CS, Loukota RA, Spencer J. Ganglioneuroma of the mandible resulting from metastasis of neuroblastoma. *Int J Oral Maxillofac Surg*. Nov 17 2008; [Medline].
9. Gasparetto EL, Rosemberg S, Matushita H, da Costa Leite C. Ganglioneuroblastoma of the cerebellum: neuroimaging and pathological features

of a case. *Arq Neuropsiquiatr.* Jun 2007; 65 (2A): 338- 40. [Medline].

10. Dozois EJ, Wall JC, Spinner RJ, Jacofsky DJ, Yaszemski MJ, Sim FH, et al. Neurogenic tumors of the pelvis: clinicopathologic features and surgical outcomes using a multidisciplinary team. *Ann Surg Oncol.* Apr 2009; 16 (4): 1010- 6. [Medline].

11. Coldman AJ, Fryer CJ, Elwood JM, Sonley MJ. Neuroblastoma: influence of age at diagnosis, stage, tumor site, and sex on prognosis. *Cancer.* Oct 15 1980; 46 (8): 1896- 1901. [Medline].

12. Schultz KR, Pullen DJ, Sather HN, Shuster JJ, Devidas M, Borowitz MJ. Risk- and response-based classification of childhood B-precursor acute lymphoblastic leukemia: a combined analysis of prognostic markers from the Pediatric Oncology Group (POG) and Children's Cancer Group (CCG). *Blood.* Feb 1 2007; 109 (3): 926- 35. [Medline].

13. Joshi VV. Peripheral neuroblastic tumors: pathologic classification based on recommendations of international neuroblastoma pathology committee (Modification of shimada classification). *Pediatr Dev Pathol.* Mar-Apr 2000; 3 (2): 184- 99. [Medline].

14. Catalina-Fernández I, Sáenz-Santamaria J, López-Presa D. Fine needle aspiration cytology of ganglioneuroma. *Acta Cytol.* May-Jun 2008; 52 (3): 380- 1. [Medline].

15. Brossard J, Bernstein ML, Lemieux B. Neuroblastoma: an enigmatic disease. *British Medical Bulletin.* 1996; 52: 787- 801.

Archive of SID