

Tuberculous brain abscess in a child with cystic fibrosis; a case report

Mojtaba Rostami¹, Monirsadat Emadoleslami², Iraj Karimi¹

¹Research Center for Infectious Diseases and Tropical Medicine, Isfahan University of Medical Sciences, Iran

²Department of Pediatric Infectious Diseases, Isfahan University of Medical Sciences, Iran

ABSTRACT

Background: Tuberculous brain abscess is an extremely rare manifestation of tuberculous involvement of the central nervous system. In countries such as India where tuberculosis is fairly common, few cases of tuberculous brain abscess have been reported.

Patient: The patient was an 8-year old boy presented with the diagnosis of cystic fibrosis and a history of tonic and clonic convulsions since 2 years ago with normal brain CT scan. Two months ago he became febrile and complained of severe headache that often awakened him up. Diagnosis of intracranial abscess was made clinically and the patient received ceftriaxon, amikacin and clindamycine; however, 2 weeks of treatment failed to show improvement. During craniotomy multiple cystic lesions and a mass of 9×3×8cm in frontoparietal area was found. After operation the patient developed severe hepatitis with elevated enzymes and bilirubin level due to anesthesia and anti-tuberculous treatment. Drugs were discontinued but fever persisted and he started a downhill course. While hepatitis was going to resolve, restarting antituberculous drugs flared up hepatitis and 3 days later he expired because of hepatic failure.

Conclusion: Meningitis is an entity of tuberculous infection in subjects living in countries of high burden tuberculosis, thus, it should be kept in mind for suspicious subjects.

Keywords: Tuberculosis, Brain abscess, Cystic fibrosis.

(Iranian Journal of Clinical Infectious Diseases 2006;1(4):201-203).

INTRODUCTION

Tuberculous brain abscess is an extremely rare manifestation of tuberculous involvement of the central nervous system (CNS) (1). Even among patients infected with HIV, it is considered rare with only 9 documented cases worldwide (2). However, in countries such as India where tuberculosis is fairly common, few cases of tuberculous brain abscess have been reported (3-5).

We present a case of tuberculous abscess in a child with cystic fibrosis and apparently normal immune system.

PATIENT

The patient was an 8-year old boy residing in central part of Iran (Golpaigan). He was the second child of healthy parents who were not relatives. When he was 3 years old, he experienced intermittent fever and recurrent bouts of pneumonia for the first time. A year and a half later the

Received: 17 May 2006 Accepted: 26 September 2006

Reprint or Correspondence: Mojtaba Rostami, MD.
Research Center for Infectious Diseases and Tropical
Medicine, Isfahan University of Medical Sciences. P.O. Box:
81758-39634. E-mail: morostami@gmail.com

202 Tuberculous brain abscess; a case report

diagnosis of cystic fibrosis was made by positive sweat test. He had a history of tonic and clonic convulsions since 2 years ago with normal brain CT scan. Two months ago he became febrile (often 40°C) and complained of severe headache that often awakened him up.

Physical exam revealed a boy with retarded growth relative to age. He had ataxia and deviation to the left side on walking. CT scan and MRI revealed shift of the falx to the right side and a large irregular lesion in left frontoparietal lobe as low signal intensity on T1-weighted images that contain multiple ring enhancement cystic lesions after contrast injection, with pressure effect and invasion into left lateral ventricle. Posterior fossa, orbit and brain stem were normal. (figures 1 and 2).

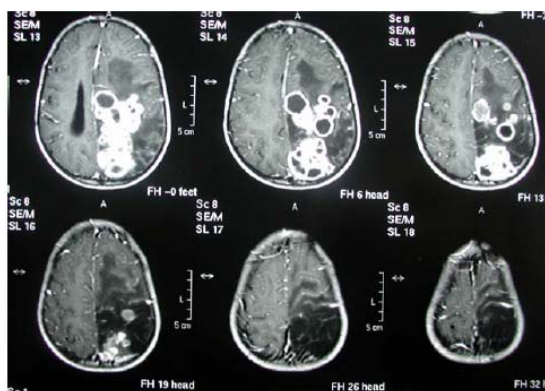


Figure 1. Brain MRI (coronal view) of tuberculous brain abscess of a child with cystic fibrosis

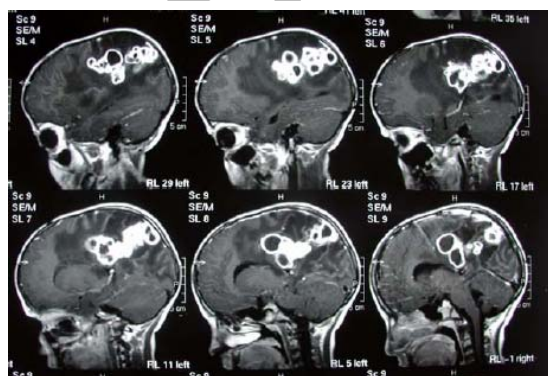


Figure 2. Brain MRI (sagittal view) of tuberculous brain abscess of a child with cystic fibrosis

He weighted 19 kg at admission with 119cm height and head circumference of 55cm. The patient had been given BCG (Bacillus Calmette Guerine) vaccine at birth according to the country vaccination program. The results of urine analysis, and the levels of urea nitrogen, creatinine, calcium, phosphorus, magnesium, electrolytes, alpha1-antitrypsin, C₃, C₄, CH50, IgG, IgM, IgA and IgE were within normal range. Nitroblue-tetrazolium test (NBT) was normal, and a complete blood count showed 25000WBC/mm³. Total complement was 32mg/dl (normal: 63–150mg/dl) while the level of lactate dehydrogenase was elevated (275 U/l). Three blood cultures in biphasic environment were sterile, and tests for antibodies to the human immunodeficiency virus (HIV), types 1 and 2, were negative. Tests for anti tissue transglutaminase and gliadine IgG were normal and test for antineutrophil cytoplasmic autoantibodies were negative. IgG and IgM antibodies to *Toxoplasma gondii* were negative. Tests of brucellosis performed several times by ELISA method were insignificant. Tuberculin skin test with 5 TU solution was negative. Chest radiographs disclosed a left axillary calcified lymph node and diffuse millet opacification throughout the lungs that had worsened since a study performed six months earlier. EEG showed abnormal generalized slowing. Diagnosis of intracranial abscess was made clinically and the patient received ceftriaxon, amikacin and clindamycine; however, 2 weeks of treatment failed to show improvement. Craniotomy with purpose of draining and removal of abscess was achieved. Findings were multiple cystic lesions and a mass of 9×3×8cm in frontoparietal area. Direct smear and culture were taken. Pathology findings were sections of multiple granulomas containing epithelioid, giant cells and extensive caseous necrosis. No acid fast bacilli were found on Zeil-Nelson staining. Staining and results of culture 14 days later for fungi were negative. After operation the patient developed severe hepatitis with elevated enzymes and

bilirubin level due to anesthesia and anti-tuberculous treatment. Drugs were discontinued but fever persisted and he started a downhill course. While hepatitis was going to resolve, restarting antituberculous drugs flared up hepatitis and 3 days later he expired because of hepatic failure. Two months later culture confirmed diagnosis of tuberculosis.

DISCUSSION

Meningitis is an entity of tuberculous infection in subjects living in countries of high burden tuberculosis. Although the most presenting form of TB is pulmonary one, central nerves system infection is also common. The most common form of CNS infection with *M. tuberculosis* is meningitis and tuberculoma (1); however, tuberculous brain abscess is very rare in immunocompromised individuals (6). It is impossible to differentiate diagnosis from pyogenic abscess only on the basis of clinical findings. Although concomitant infection in the other sites of the body is a usual finding in pyogenic abscess but in 10 to 60 percent of patients with a brain abscess, no underlying source of infection is found (7-9).

In the present case Ghon complex is seen as a scar of an old TB (Figure 3). Lumbar puncture is a clue in diagnosis of central nervous system infections but it is associated with a 12% danger of unfavorable outcome such as cereberal herniation when a mass lesion is present (10).

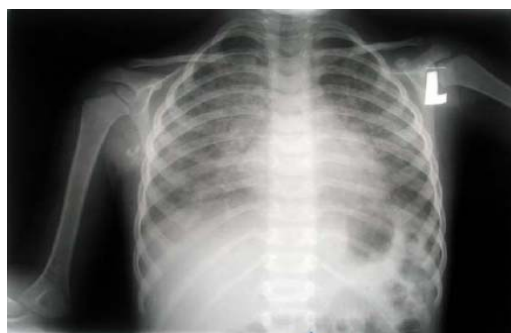

Figure 3. Plain chest film of tuberculous brain abscess of a child with cystic fibrosis

Imaging tools such as CT scan and MRI also have limitation in differentiating TB from abscess due to other bacteria. Schoeman J et al. reported occurrence of parenchymal signal abnormalities in the brainstem and adjacent temporal lobes on MRI in TB meningitis and tuberculoma but it is impossible to make a definite diagnosis (10). Such situation may be a dilemma because blind treatment for bacterial abscess does not improve the outcome and may be a time wasting trial. On the other hand, searching for responsible microorganism may be unsuccessful in closed area of brain. Although tuberculous abscess is always a possibility in cases like this, but definite microbiologic or histopathology is needed for proper management.

REFERENCES

1. Garcia-Monco JC. Central nervous system tuberculosis. *Neurol Clin* 1999;17:737-9.
2. Vidal JE, Cimerman S, Marques da Silva PR, et al. Tuberculous brain abscess in a patient with AIDS: case report and literature review. *Rev Inst Med Trop Sao Paulo* 2003;45:111-14.
3. Inbasekaran V, Natarajan M. Tuberculous brain abscess. *J India Med Assoc* 1991;89:207-9.
4. Kumar S, Malhotra V, Prakash B, et al. Tuberculous brain abscess with computed tomography appearance - a case report. *Neurol India* 1987;35:103-6.
5. Unnikrishnan M, Chandy MJ, Abraham J. Posterior fossa abscess. *J Assoc Physicians India* 1989;37:376-78.
6. Whitener DR. Tuberculous brain abscess. Report of a case and review of the literature. *Arch Neurol* 1978;35:148-55.
7. Calfee DP, Wispelwey B. Brain abscess. *Semin Neurol* 2000;20:353-360.
8. Roos K, Tyler KL. Bacterial meningitis and other suppurative infections. In: Braunwald E, Fauci AS, Kasper DL, et al. editors. *Harrison's principles of internal medicine*. 16th edition. New York: McGraw-Hill, 2001;p:2485-7.
9. Mathisen GE, Johnson JP. Brain abscess. *Clin Infect Dis* 1997;25:763-781.
10. Schoeman J, Hewlett R, Donald P. MRI of childhood tuberculous meningitis. *Neuroradiology* 1988;30(6):473-7.