



Progressive Paraparesis after CABG Surgery

Kamran Shadvar*, Yashar Eslampoor

Cardiovascular Research Center, Tabriz University of Medical Sciences, Tabriz, Iran

ARTICLE INFO

Article Type:

Case Report

Article History:

Received: 7 Oct 2012

Accepted: 12 March 2013

Keywords:

Paraparesis

CABG

ABSTRACT

CABG is one of the most common cardiac surgeries all over the world. Similar to other surgeries, it may be associated with some undesirable complications including neurologic complications which might cause morbidity and mortality after surgery. We will describe a case of Progressive Paraparesis after CABG Surgery and review its etiology, diagnosis and management.

Case history

A 73-year-old man with a history of chest pain 1.5 months was admitted to Shahid Madani heart hospital. He had hypertension and herniorrhaphy in his past medical history with no history of sensory or motor impairments. All lab data were within normal limits except for ESR (521st, 1132nd) & CRP (2+). Echocardiographic findings were LVEF of 55% and mild left ventricular hypertrophy. Coronary artery CT-angiography was performed and stenosis of three coronary arteries was established. The patient was scheduled for coronary artery bypass surgery (CABG). The induction of anesthesia was performed with Fentanyl 500 micrograms, midazolam 10 mg & cisatracurium 20 mg; later, anesthesia was maintained and maintained with infusion of fentanyl 4 μ /kg/hr, midazolam 1 μ /kg/min & cisatracurium 1 μ /kg/min. After positioning the patient with inserting a pillow in the back of his thoracic space (for better exposure of surgical field), the CABG surgery was performed with off pump coronary artery bypass (OPCAB) technique. The vital signs were stable during surgery and the ABGs during surgery were within normal limits. At the end of surgery the patient was transmitted to the ICU while being intubated and unconscious with BP=110/60 mmHg, HR=77/min and NSR, CVP=8 cmH₂O and SPO₂=100%.

After admission to the ICU, the primary vital signs were normal except for BP. Nitroglycerine infusion was started because of high BP and tapered following the management of high BP. The patient was successfully weaned and extubated the day of surgery. The post-surgery drug orders were: Enoxaparin 40 mg q 12h/Sc, Osvix tab daily, captopril 25 mg q12h, metoral 25 mg q12h, atorvastatine 40mg daily and ASA 80 mg daily.

The first day post-surgery, LAB findings in ICU were:

Hb=10, Hct=30.5, Plt=242000, WBC=9100, PT=15.3, PTT=32, INR=1.47, Na=139, K=4.9, BUN=17, Cr=0.94, CPK=847, CK-MB=58. All of the following lab findings during ICU admission were within normal limits.

In the first day of admission, the patient was stable, awake and oriented. No signs of hemodynamic instability or cardiac dysrhythmias were seen. The patient just complained of dizziness and instability in walking. Neurologic consultation was performed stating that the cranial nerves were intact, cerebellar tests and sensory examinations were normal, muscle forces of lower limbs were 4/5 and symmetric and plantar reflexes were double flexor.

In the second day of admission, the overall condition of patient was good but the difficulty in complete movement of lower limbs was presented and he could not walk without aid. After that the progressive paraparesis appeared and the muscle forces and DTRs began to decrease gradually. For determination of cause of paraparesis with the probability of CVA or lacunar infarct in the internal capsule region diffusion-weighted MR Imaging of the Brain was obtained, but no abnormality was found (Figure 1). In the third day of admission, the paraparesis progressed and muscle forces decreased from 4/5 to 3/5 and then to 2/5. Neurology consultation was performed again recommending to rule out the vascular causes (due to slight coldness of the lower limbs, especially in the right lower limb). Color Doppler of lower limbs was performed and there was no stenosis or thrombosis in arteries or veins of the lower limbs (just a 9×36 mm baker cyst was seen at right popliteal region). In the fourth day of admission, severe weakness of lower limbs, absence of DTRs, no plantar reflexes, and muscle forces= 1/5 at left and 0/5 at right were observed but the sensation of

*Corresponding author: Kamran Shadvar, E-mail: k_shadvar@yahoo.com

Copyright © 2013 by Tabriz University of Medical Sciences

the lower limbs was intact with ability to localization. Suspecting neuropathies, EMG-NCV was performed reporting peripheral sensory-motor polyneuropathy mainly demyelinating types with differential diagnosis of acute inflammatory demyelinating polyneuropathy (AIDP) and critical illness polyneuropathy (CIP). Neurology consultation was performed and after review of EMG-NCV reports they consider Guillain-Barre Polyneuropathy; however, they found a sensory level at T9-T10. It should be emphasized that due to this sensory level and after consulting with neurologist, thoracolumbosacral MRI was considered because spinal cord ischemia was at top of the list of differential diagnoses. Thoracolumbosacral MRI showed the pathologic fracture of the third thoracic vertebra with a compression in spinal cord (Figures 2 & 3). After diagnosis was made, an urgent consultation was performed with the neurosurgery service and the emergency spinal surgery was performed. The pathology of vertebral fracture was an extradural mass; the definite site was unknown and metastatic adenocarcinoma was probable. In the follow-up period after spinal surgery, there was no change in patient weakness and after that because our patient had been discharged from the hospital we could not follow up the patient completely to discover if the weakness had been better or not.



Figure 2. spinal cord MRI

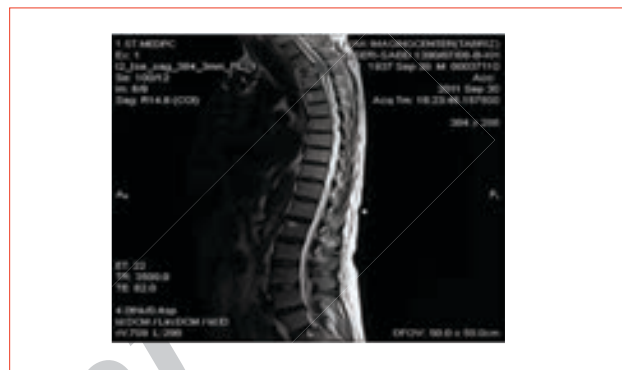

Figure 3. spinal cord MRI

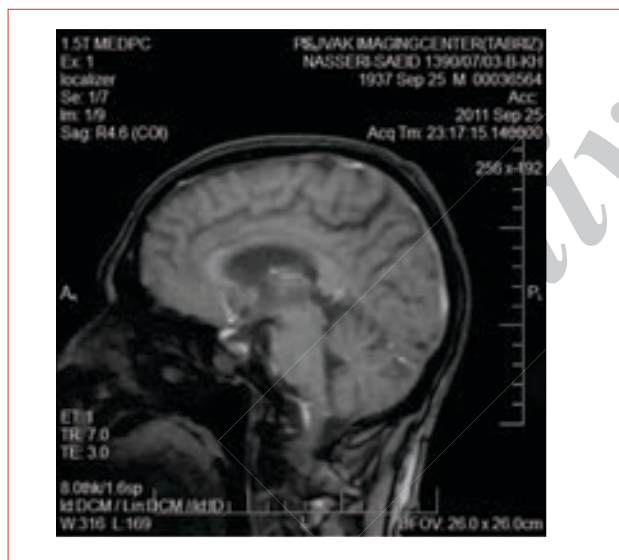


Figure 1. Brain MRI

Discussion

Neurologic complications after cardiac surgery can occur in the post operative period. The causes of these complications are hypoxia, metabolic abnormalities, emboli, or hemorrhage. These complications can be divided into two types: type 1 (3%) includes major focal deficit and stupor or coma; type 2 (3%) includes intellectual dysfunction. These complications are associated with increased mortality, prolonged ICU stay and decreased

long-term survival.¹⁻⁷

Risk factors for neurologic complications in cardiac surgery are hemodynamic instability, diabetes mellitus, advanced age, complex procedures, prolonged CPB (>2hr), previous stroke, hypertension, hyperglycemia, hyperthermia, hypoxemia, aortic atheromatosis and peripheral vascular disease.^{1,2,5}

Mechanisms and factors for neurologic lesions are embolization, hypoperfusion, influencing factors, aortic atheroma plaque, cerebrovascular disease, altered cerebral autoregulation, hypotension, intracardiac debris air, venous obstruction on bypass, CPB circuit surface, cerebral hyperthermia and hypoxia.

In this case, Our differential diagnoses were CVA or lacunar infarct (internal capsular region) - embolic or hemorrhagic, spinal cord ischemia and infarct (due to embolic insult or hypoperfusion), acute inflammatory demyelinating polyradiculoneuropathy (AIDP) or critically ill polyneuropathy (CIP), peripheral nervous injury, peripheral vascular disease and spinal cord ischemia.

In the Spinal cord ischemic stroke, neurologic deficits may occur without pain; however, most of them (>80%) are painful and this is an interesting difference from cerebral infarction which is usually not painful. Depending on the level of the cord lesion, symptoms may vary from mild to moderate and even from reversible leg weakness to quadriplegia. Fever is a warning (red flag)

to consider infectious origins particularly acute bacterial meningitis. It can occur because of surgical procedures in which hypotension and prolonged positioning (e.g. seated neurosurgical approaches and hyperlordosis) may be prominent factors.¹⁰⁻¹³ Involvement of intrinsic cord vessels has been reported with arteritis such as SLE. Anterior spinal artery occlusion has been reported with arteritis including that associated with syphilis and diabetes mellitus; after trauma; and as a complication of spinal angiography, spinal adhesive arachnoiditis, administration of intrathecal phenol, and spinal anesthesia. Aortic diseases are blamed to produce spinal infarction in a variety of situations including dissecting aneurysm; aortic surgery, especially with aortic cross-clamping above the renal artery aortography; atherosclerotic embolization; and aortic thrombosis.

Uncommon causes include complications of abdominal surgery, particularly sympathectomy; circulatory failure as a result of cardiac arrest or prolonged hypotension; and vascular steal in the presence of an arteriovenous malformation, or vascular compression by tumors in the spinal canal, vertebral fracture, or a herniated intervertebral disk (Figure 2 & 3).^{12,13}

This complication is a rare condition which is never discussed in the literature. We considered that this complication was due to a vertebral degenerative process in this patient and after placing role under the shoulder and positioning for thoracotomy, the T3 vertebral body was fractured. Despite occurrence of this complication, placing role to position for CABG surgery is inevitable and pathologies in vertebrae before surgery cannot be considered in all patient especially when the patient him/herself does not have any associated complaint. Hence, in this patient diagnosed was made accidentally.

Competing interests: The authors declare that they have no competing interests.

References

1. Roach GW, Kanchuger M, Mangano CM, Newman M, Nussmeier N, Wolman R, et al. Adverse cerebral Outcomes after coronary bypass Surgery. Multicenter Study of Perioperative ischemia Research Group and the ischemia Research and Education Foundation investigators. **N Engl J Med** 1996; 525:1857.
2. Bucerius J, Gummert JF, Borger MA, Walther T, Doll N, Onnasch JF, et al. Stroke after Cardiac surgery: A risk factor analysis Of 16,184 consecutive adult patients. **Ann Thorac Surg** 2003; 75:472
3. Hogue CW Jr, Barzilai B, Pieper KS, Coombs LP, DeLong ER, Kouchoukos NT, et al. Sex differences in neurological Outcomes and mortality after cardiac Surgery: A Society Of Thoracic Surgery National Database report. **Circulation** 2001;103: 2133-7.
4. Nussmeier NA. A review Of risk factors for adverse neurologic Outcome after cardiac Surgery. **J Extracorp Technol** 2002;34:4.
5. Ridderstolpe L, Ahlgren E, Gill H, Rutberg H. Risk factor analysis Of early and delayed cerebral complications after cardiac Surgery. **Cardiothorac Vasc Anesth** 2002; 16:278-85.
6. Wolman RL, Nussmeier NA, Aggarwal A, Kanchuger MS, Roach

GW, Newman MF, et al: Cerebral injury after Cardiac Surgery: identification Of a group at extraordinary risk. Multicenter Study Of Perioperative Ischemia Research Group (MCSPI) and the Ischemia Research Education Foundation (IREF) Investigators. **Stroke** 1999; 30:514-22.

7. Ahonen J, Salmenpera M. Brain injury after adult cardiac Surgery. **Acta Anaesthesiol Scand** 2004; 48:4-19.

8. Hughes RA, Swan AV, Raphael JC, Annane D, van Koningsveld R, van Doorn PA. Immunotherapy for Guillain-Barre syndrome: a systematic review. **Brain** 2007;130:2245-5.

9. Chawla J, Gruener G. Management of critical illness polyneuropathy and myopathy. **Neural Clin** 2010;28:961-77

10. Cheshire WP, Santos CC, Massey EW, Howard JF Jr. Spinal cord infarction: etiology and outcome. **Neurology** 1996;47:321-30.

11. Weber P, Vogel T, Bitterling H, Utzschneider S, von Schulze Pellingahr C, Birkenmajer C. Spinal cord infarction after operative stabilisation of the thoracic spine in a patient with tuberculous spondylodiscitis and sickle cell trait. **Spine** 2009;34:E294-7.

12. Hogan EL, Romanul FC. Spinal cord infarction occurring during insertion of aortic graft. **Neurology** 1966; 16:67-74.

13. Ross RT. Spinal cord infarction in disease and surgery of the aorta. **Can J Neurol Sci** 1985;12:289-95.