



## Original Article

## Combination effect of voluntary exercise and garlic (*Allium sativum*) on oxidative stress, cholesterol level and histopathology of heart tissue in type 1 diabetic rats

Rafiqe Ghyasi<sup>1</sup>, Gisou Mohaddes<sup>2</sup>, Roya Naderi<sup>3,4\*</sup>

<sup>1</sup>Drug Applied Research Center of Tabriz University of Medical Sciences, Tabriz, Iran

<sup>2</sup>Neuroscience Research Centre of Tabriz University of Medical Sciences, Tabriz, Iran

<sup>3</sup>Nephrology and Kidney Transplant Research Center, Urmia University of Medical Sciences, Urmia, Iran

<sup>4</sup>Department of Physiology, Faculty of Medicine, Urmia University of Medical Sciences, Urmia, Iran

### Article info

#### Article History:

Received: 6 December 2018

Accepted: 1 March 2019

published: 6 March 2019

#### Keywords:

Voluntary Exercise  
Garlic  
MDA  
TAC  
Cholesterol  
Oxidative Stress

### Abstract

**Introduction:** This study aimed to evaluate the combination effect of voluntary exercise and garlic on oxidative markers, cholesterol level and histological alterations in streptozotocin (STZ)-induced diabetes in rat heart.

**Methods:** Thirty-five male Wistar rats were randomly assigned into five experimental groups (n=7): Control, Diabetes, Diabetes+Garlic, Diabetes+Exercise, Diabetes+Garlic+Exercise groups. Diabetes was induced by STZ (ip, 50 mg/kg) in animals. Animals received garlic homogenate (250 mg/kg) by oral gavage or subjected to voluntary exercise alone or together for 6 weeks. At the end of intervention blood and heart tissue samples were obtained and used for measurement of glycosylated haemoglobin (HbA1c), cholesterol, total antioxidant capacity (TAC), malondialdehyde (MDA) levels and histological analysis.

**Results:** Improved blood glucose, cholesterol, total antioxidant capacity, and MDA levels were established in both Diabetes+Garlic and Diabetes+Exercise groups. Additionally, staining with Hematoxylin and Eosin (H&E) revealed that voluntary exercise and garlic alone and together reduced interstitial edema, leukocyte infiltration, and myonecrosis. Furthermore, simultaneous treatment of diabetic rats with garlic and exercise training had an additive effect on these parameters.

**Conclusion:** The findings indicated that combination therapy with garlic and voluntary exercise may present more beneficial effects in heart histological remodeling in diabetic rats than the use of garlic or voluntary exercise alone and that these beneficial effects might be associated with enhancement in cholesterol, total antioxidant capacity, and MDA levels.

**Please cite this article as:** Ghyasi R, Mohaddes G, Naderi R. Combination effect of voluntary exercise and garlic (*Allium sativum*) on oxidative stress, cholesterol level and histopathology of heart tissue in type 1 diabetic rats. *J Cardiovasc Thorac Res* 2019;11(1):61-67. doi: 10.15171/jcvtr.2019.10.

### Introduction

Diabetes mellitus (DM) is associated with an increased risk of cardiovascular disease.<sup>1</sup> The prevalence of vascular disease in diabetic patients is risen more than 3-fold and is the crucial cause of mortality and morbidity in diabetic patients.<sup>2</sup> It has been reported that prolonged hyperglycemia leads to generation of free radicals, oxidative stress, and inflammation.<sup>3</sup> These free radicals play in various physiological events including gene expression, signaling pathways and cellular defense against pathogens.<sup>4</sup> In pathological conditions, such as uncontrolled hyperglycemia, free radicals are assembled in order to the activation of several pathways.<sup>5</sup> Hyperglycemia

stimulates protein kinase C (PKC) and poly-ADP ribose polymerase (PARP) pathways; as well as it increases production of advanced glycation outcomes, polyol and hexosamine pathways. These pathways are stimulated or increased in order to mitochondrial superoxide overproduction.<sup>6</sup> Furthermore, free radical overload and formation of oxidative stress lead to antioxidant defense system attenuation in tissues during diabetes.<sup>7,8</sup> Diabetes-induced oxidative damage in different organs including the cardiovascular system, as manifested by increased MDA and also decreased antioxidant enzymes activities.<sup>9</sup> Exercise training has been reported to reverse oxidative stress and provide alleviating effects on hyperglycemia

\*Corresponding Author: Roya Naderi, Email: r\_naderi\_s@yahoo.com

© 2019 The Author (s). This is an open access article distributed under the terms of the Creative Commons Attribution License (<http://creativecommons.org/licenses/by/4.0>), which permits unrestricted use, distribution, and reproduction in any medium, provided the original work is properly cited.

and hyperlipidemia in the cardiomyocytes.<sup>10</sup> Recently, Dietary plants, identified from herbal medicine are providing an opportunity for the appearance of new types of therapeutics.<sup>11</sup> Among them, garlic (*Allium sativum*) has been utilized in herbal medicine for its unique antioxidant and anti-inflammatory properties.<sup>11</sup> Garlic may markedly modulate antioxidants status in the blood and heart of type 1 diabetic rats.<sup>6</sup> Although the combination effect of voluntary exercise and garlic in diabetic heart related to oxidative stress and lipid parameters have not been elucidated yet. According to above, in this study, we decided to evaluate the combination effect of garlic and voluntary exercise performance on histological parameters, cholesterol level and oxidative markers in the blood and heart of type 1 diabetic rats.

## Materials and Methods

### Animals and experimental design

Male Wistar rats (200-250 g) were housed under controlled environmental conditions and maintained on a 12h light-dark cycle in an air-conditioned room and stable temperature (22±1°C) room with food and water provided ad libitum. Thirty-five animals were randomly assigned to five experimental groups (n = 7).<sup>6</sup>

Control: Animals that received 0.4 mL of sodium citrate buffer, pH 4.5.

Diabetes: Animals that received a single dosage of 50 mg/kg of STZ intraperitoneally (i.p).

Diabetes + Garlic: STZ (50 mg/kg, i.p) was administered to animals by a single injection. After confirmation of diabetes, 250 mg/kg of homogenized garlic was fed by oral gavage 6 days a week for a period of 6 weeks.<sup>6,12</sup>

Diabetes+Exercise: STZ (50 mg/kg, i.p) was administered to animals by a single injection. After confirmation of diabetes, voluntary running wheel exercise was performed for the animals for 6 weeks.

Diabetes+Garlic+Exercise: Diabetic rats that received garlic homogenate (250 mg/kg) 6 days a week by gavage and performed voluntary exercise simultaneously for 6 weeks.

Diabetes was induced with a single injection of STZ (50 mg/kg) (Sigma Chemical Co., St Louis, MO, USA) intraperitoneally. STZ dissolved in 0.4 mL of sodium citrate buffer, pH 4.5. To confirm the induction of diabetes, 72 hours later after the STZ injection, blood glucose level was measured by a glucometer (Elegance, CT-X10., Frankenberg, Germany). The fasting glucose concentration of more than 300 mg/dL was considered diabetic.<sup>12</sup>

### Preparing Garlic Homogenate

Garlic (*Allium sativum*) bulbs were obtained from a local market. Cloves were peeled, cut off, blend by a mixing machine and form a paste, afterwards, suspended in distilled water. The garlic homogenate was provided freshly each day.<sup>12</sup>

### Voluntary exercise

The animals in the voluntary exercise groups were housed in a separate cages with stainless-steel running wheels (1.00 m circumference, TajhizGostar) and were subjected free access to the wheel 24 hours per day for 6 weeks. The wheels were attached to a permanent sensor for counting of revolutions. Running distance was monitored daily. If the running distance was less than 2000 m/d, that animal was excluded from the study. Control rats were kept in standard holding cages without running wheels during 6 weeks.<sup>13</sup>

### Tissue processing and homogenate preparation

At the end of experiment, the animals were deeply anesthetized with pentobarbital sodium (Sigma-Aldrich; St. Louis, Missouri, United States) (35 mg/kg, i.p.). Then the thoracic cavity was disclosed and blood samples were obtained by syringes from the heart of anesthetized rats. Some blood centrifuged at 4000 ×g for 20 minutes immediately. The serum obtained and stored in tubes at -80°C for determination of cholesterol, TAC and MDA levels. Some blood as whole blood used for measuring HbA1c (glycosylated haemoglobin) level. Hearts were isolated, frozen in liquid nitrogen and stored at deep freeze (-70°C). For MDA estimation heart samples were homogenized in 1.15% KCl solution (Sigma-Aldrich; St. Louis, Missouri, United States). The homogenates were centrifuged at 1000 rpm for 1 minute at 4°C, and then stored at -80°C for later measurements.<sup>13,14</sup>

### MDA and TAC assessment

MDA as the end-product of lipid peroxidation was evaluated in the blood and tissue samples as described by the Esterbauer and Cheeseman method. Accordingly, MDA reacts with thiobarbituric acid (Sigma-Aldrich; St. Louis, Missouri, United States), and the pink pigment was produced, that has a maximum absorption at 532 nm.<sup>13,14</sup> TAC was assessed by a Randox (Crumlin, County Antrim, United Kingdom) total antioxidant kit. Accordingly, 2,2'-azino-bis(3-ethylbenzothiazoline-6-sulfanate) (ABTS) is incubated with peroxidase and H<sub>2</sub>O<sub>2</sub> resulting in the radical cation ABTS<sup>+</sup> production. Finally, at 600 nm a stable blue-green color was observed.<sup>13</sup>

### Detection of fasting blood glucose, HbA1c and serum total cholesterol

Blood samples were obtained from the tip of tail and glucose levels were assessed by a digital glucometer (Elegance, CT-X10., Frankenberg, Germany). HbA1c was also evaluated in whole blood by immunoturbidimetry kit (Pars Azmoon HbA1c kit, Iran) according to manufacturer's structure. Serum samples were evaluated for total cholesterol levels using an auto blood analyzer (Bayer Corp. USA). The related kit was purchased from Pars Azmoon CO, Iran.

### Histological evaluation

To perform histopathological staining, heart tissues were immediately excised and fixed in 10% buffered-formalin solution. After dehydration in ascending grades of alcohol, tissues were embedded in paraffin. To evaluate interstitial edema, congestion, leukocytosis infiltration, and myonecrosis, H&E staining was applied. Sections of 5 µm were obtained, stained and evaluated under a light microscope (Olympus BH-2, Tokyo, Japan) by a blinded pathologist. Histological changes were scored as follows: (-) none, (+) mild, (++) moderate, and (+++) severe damage.<sup>15</sup>

### Statistical analysis

Evaluating of Normality was checked by Kolmogorov-Smirnov test. Data were statistically evaluated by one-way analysis of variance (ANOVA) followed by Tukey's test. The significant level was considered at  $P < 0.05$ . Data are expressed as means  $\pm$  SEM.

### Results

#### Lipid peroxidation and total antioxidant capacity

Table 1 shows that a significant increase in MDA level ( $P < 0.001$ ) in the heart and serum of the diabetic group compared with the control group. However, 6 weeks treatment of the diabetic animals with garlic or exercise alone ( $P < 0.01$ ) and in combination ( $P < 0.001$ ) significantly decreased serum MDA level in comparison to the group with diabetes. Also garlic ( $P < 0.01$ ) and exercise ( $P < 0.001$ ) treatment and their combination ( $P < 0.001$ ) in the diabetic heart reversed MDA level. Furthermore, in the diabetic animals, combination therapy with garlic and exercise had a significant reduction in heart MDA compared to groups treated with garlic ( $P < 0.01$ ) or exercise ( $P < 0.05$ ) alone. In addition, we found that in the groups with garlic administration or exercise performance alone ( $P < 0.01$ ) or together ( $P < 0.001$ ) serum TAC level appeared to be significantly higher than that in the diabetic group. Also, combination therapy of rats with garlic and exercise had a higher TAC level ( $P < 0.05$ ) in the serum of diabetic rats compared with Diabetes+Exercise group.

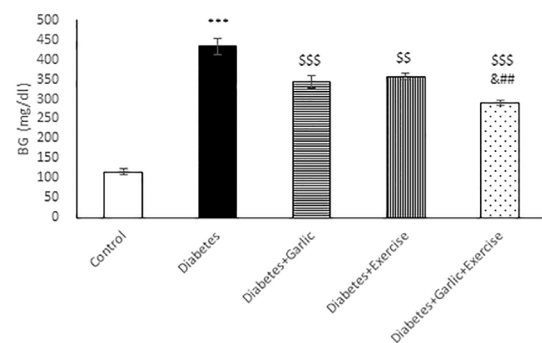
#### Detection of fasting blood glucose, HbA1c and serum total cholesterol

As shown in Figure 1, after 6 weeks of treatment, blood glucose level was significantly lower in Diabetes +

Garlic ( $P < 0.001$ ), Diabetes+Exercise ( $P < 0.01$ ), and Diabetes+Garlic+Exercise ( $P < 0.001$ ) groups than the diabetic group. Furthermore, simultaneous treatment of the diabetic group with garlic and exercise significantly decreased blood glucose level ( $P < 0.001$ ) compared to the Diabetes+Garlic ( $P < 0.05$ ) and Diabetes+Exercise ( $P < 0.01$ ) groups. HbA1c level was also evaluated in all groups; it was significantly ( $P < 0.001$ ) higher in diabetic rats compared to the control rats (Figure 2). Garlic administration or exercise training alone ( $P < 0.01$ ) or in combination ( $P < 0.001$ ) also significantly decreased HbA1C level in diabetic rats compared to the diabetes group. Total cholesterol level in the serum of diabetic group was significantly ( $P < 0.01$ ) higher than in the control rats. Garlic ( $P < 0.05$ ) and exercise training ( $P < 0.01$ ) alone and together ( $P < 0.001$ ) significantly reversed the increase in total cholesterol level in the serum of diabetic rats. Furthermore, simultaneous treatment with garlic and exercise in diabetic group significantly ( $P < 0.05$ ) decreased cholesterol level compared to Diabetes+Exercise group (Figure 3).

#### Histopathological findings

Hematoxylin and Eosin staining was done to assess the effect of garlic and voluntary exercise on heart tissue alterations in diabetic animals. According to Figure 4, there is a normal structure with heart tissue in the control group (Figure 4A). In the diabetic group, histological alterations including interstitial edema, leukocyte infiltration, as well as, myonecrosis were higher than those of the control

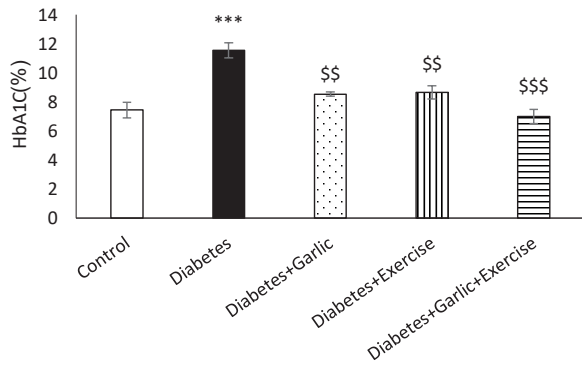


**Figure 1.** Effect of garlic and voluntary exercise on blood glucose (BG) at the end of experiment. Data are represented as the mean  $\pm$  SEM (n = 7). \*\*\*  $P < 0.001$  versus Control group. \$\$  $P < 0.01$ , \$\$\$  $P < 0.001$  versus Diabetes group. ##  $P < 0.01$  versus Diabetes + Exercise group. &  $P < 0.05$  versus Diabetes + Garlic group.

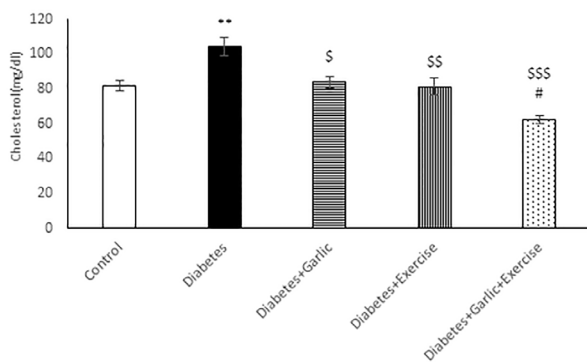
**Table 1.** Effect of garlic and voluntary exercise and their combination of changes to heart tissue

Parameters	Control	Diabetes	Diabetes + Garlic	Diabetes+ Exercise	Diabetes + Garlic +Exercise
TAC (mmol/L)	0.81 $\pm$ 0.031	0.54 $\pm$ 0.05 <sup>a</sup>	1.01 $\pm$ 0.09 <sup>c</sup>	0.91 $\pm$ 0.07 <sup>c</sup>	1.25 $\pm$ 0.11 <sup>d,e</sup>
Heart MDA (nmol/mgpr)	7.12 $\pm$ 0.55	13.6 $\pm$ 0.74 <sup>b</sup>	9.43 $\pm$ 0.79 <sup>c</sup>	8.54 $\pm$ 0.63 <sup>d</sup>	5.35 $\pm$ 0.31 <sup>d,e,f</sup>
Serum MDA (nmol/mL)	3.2 $\pm$ 0.66	7.8 $\pm$ 0.95 <sup>b</sup>	3.9 $\pm$ 0.27 <sup>c</sup>	3.9 $\pm$ 0.23 <sup>c</sup>	2.9 $\pm$ 0.18 <sup>d</sup>

<sup>a</sup>  $P < 0.05$ , <sup>b</sup>  $P < 0.001$  versus Control group. <sup>c</sup>  $P < 0.01$ , <sup>d</sup>  $P < 0.001$  versus Diabetes group. <sup>e</sup>  $P < 0.05$  versus Diabetes + Exercise group. <sup>f</sup>  $P < 0.01$  versus Diabetes + Garlic group. Total antioxidant capacity (TAC), heart and serum malondialdehyde (MDA) levels in STZ-induced diabetic rats after 6 weeks. Data are shown as means  $\pm$  SEM.



**Figure 2.** Effect of garlic and voluntary exercise on HbA1C (Glycosylated Hemoglobin) at the end of experiment. Data are represented as the mean  $\pm$  SEM (n = 7). \*\*\*  $P < 0.001$  versus Control group. \$\$  $P < 0.01$ , \$\$\$  $P < 0.001$  versus Diabetes group.

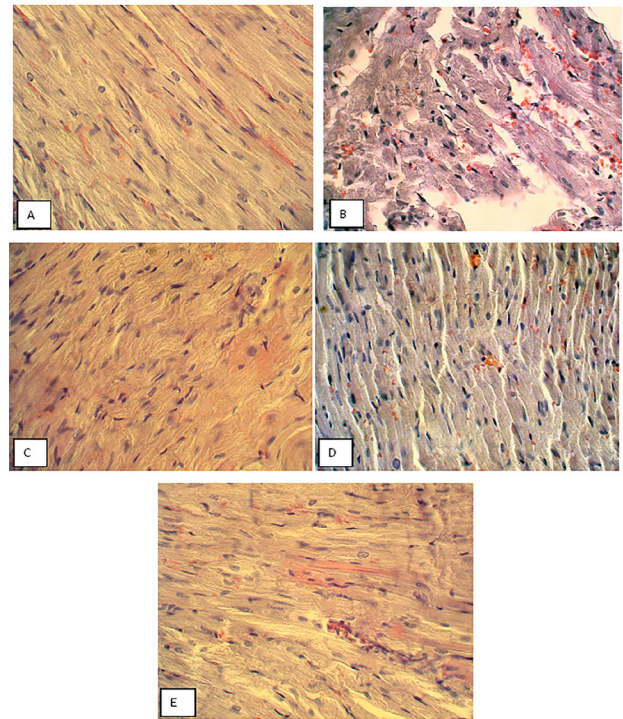


**Figure 3.** Effect of garlic and voluntary exercise on cholesterol at the end of experiment. Data are represented as the mean  $\pm$  SEM (n = 7). \*\*  $P < 0.001$  versus Control group. \$  $P < 0.05$ , \$\$  $P < 0.01$ , \$\$\$  $P < 0.001$  versus Diabetes group. #  $P < 0.05$  versus Diabetes+Exercise group.

animals (Figure 4B). Garlic consumption and voluntary exercise performance attenuated all histological changes in the heart tissue of the treated groups compared to the diabetic group (Figure 4C, D). Furthermore, simultaneous treatment with garlic and exercise resulted in a marked attenuation of interstitial edema, leukocyte infiltration, and myonecrosis in diabetic animals (Figure 4E, Table 2).

**Discussion**

The results of the present study indicated that oral administration of garlic in combination with voluntary exercise significantly reduced histological alterations in the heart of diabetic rats. These alterations probably were



**Figure 4.** Histopathological evaluation of rat cardiomyocytes in different groups at the end of the experiment. Heart sections were stained by hematoxylin and eosin (H&E) and examined by a light microscope (40  $\times$  HE).

mediated by modification in oxidative and lipid markers. We observed the significant elevation in TAC level with a reduction in MDA and cholesterol contents in both diabetes+garlic and diabetes+ exercise groups compared with the diabetic group. Moreover, our data demonstrated the favorable and additive effects of garlic in combination with voluntary exercise on histological alterations, reducing oxidative stress and cholesterol level in diabetic rats.

Diabetes mellitus is a serious chronic metabolic disease which is associated with hyperglycemia and several complications including cardiovascular disease.<sup>1</sup> In this study, the increased level of blood glucose and HbA1c in STZ-induced diabetic rats were reduced by oral administration of garlic alone and in combination with voluntary exercise. Our findings match with the studies that reported the antidiabetic and cardioprotective activity of garlic and voluntary training alone in a diabetic

**Table 2.** Comparison of histological changes of cardiomyocytes in different groups of rats (hematoxylin and eosin)

	Interstitial edema and congestion	Leukocyte infiltration	Cardiomyocyte necrosis
Control	-	-	-
Diabetes	+++	+++	+++
Diabetes+Garlic	++	++	++
Diabetes+Exercise	++	++	++
Diabetes+Garlic+Exercise	+	+	+

A minimum of 10 fields for each cardiomyocyte slide was evaluated and assigned for severity of changes using scores on a scale of (-) none, (+) mild, (++) moderate, and (+++) severe damage (n =7 for each group).



situation.<sup>16, 17</sup> Furthermore, as we reported, combined intervention is more effective in reducing blood glucose and HbA1c levels than either intervention alone. It is obvious that HbA1c demonstrates the percentage of hemoglobin bound to glucose. It is a very sensitive index for glycemic control. It has been reported that the reduction of HbA1c level resulted in the lower risk of cardiovascular complications.<sup>18</sup>

The pathogenesis of diabetic cardiomyopathy which is a multifactorial process, includes metabolic disturbances including increased oxidative stress and modulated non-oxidative glucose pathways and lipid metabolism.<sup>19</sup> Lipid peroxidation is a key marker of oxidative stress which causes tissue damage in a diabetic situation, especially in association with atherosclerosis and cardiovascular disease.<sup>18,20</sup> Indeed, free radicals are known to be associated with the formation of oxidized LDL which stimulates the release of ROS and in turn promotes atherosclerosis.<sup>21</sup> Since diabetes-induced oxidative damage has a pivotal role in heart malfunction including cardiomyopathy, it has been suggested that restoring redox balance in heart tissue can combat oxidative damage and alleviate diabetic complications.<sup>22,23</sup> So, we evaluated the combination effect of garlic and voluntary exercise as potent stimuli for the endogenous antioxidant system. In our study, garlic and voluntary exercise significantly increased antioxidant defense system potency by improving TAC activity and decreasing MDA production in cardiomyocytes. Interestingly, aside from improved oxidative stress, in this study, a parallel decrease in cholesterol level was seen following garlic and voluntary exercise in diabetic animals. This finding is the first to demonstrate antioxidative activity and cholesterol-lowering effect of garlic and voluntary exercise together in an additive manner in the heart tissue of diabetic animals. In addition, histopathology of cardiomyocytes was also performed to corroborate the findings of the biochemical investigation. According to previous studies, exercise is a modulating factor which can provide several useful effects on diabetes complication including cardiovascular disorders.<sup>9,24</sup> It has shown that moderate-intensity physical activity improves myocardial dysfunction of STZ induced diabetes.<sup>9,25</sup> Also, exercise training is a beneficial non-pharmacological therapy which can modulate oxidative stress in diabetes and improve antioxidant defenses system, mitochondrial function and physiological cardiac growth.<sup>26</sup> Exhaustive physical activity can contribute to inflammation and oxidative stress.<sup>27</sup> However, it was reported that voluntary exercise as a non-exhaustive exercise has beneficial effects on activation of the certain antioxidant defense system and substantially an increase in TAC.<sup>28</sup> Furthermore, previous studies showed that exercise improved lipid profiles of healthy,<sup>29,30</sup> and diabetic rats.<sup>31,32</sup> The molecular mechanisms by which voluntary exercise provides a protective effect on the diabetic heart are not fully elucidated. However, accumulating evidence clarified

that the redox state improvement and the increases of generation and bioavailability of NO may be involved in this process.<sup>33</sup> In addition, upregulation of taurine in exercise training could attenuate reactive oxygen species production. Taurine may be a mechanism that reduces lipid peroxides and also restores the level of SOD in the diabetic heart.<sup>34</sup> In addition, upregulation of triglyceride lipolysis, improvement of antioxidant/oxidant ratio, and modified synthesis of LDL-C or elimination rate of LDL-C from the plasma suggested for the lipid-lowering effect of exercise training in STZ induced diabetic rats.<sup>29,35, 36</sup> Moreover, multiple lines of evidence highlighted that garlic had a variety of medicinal properties including hypoglycaemic, hypocholesterolemic and hypolipidaemic activities. Also, in our previous studies, we have obtained consistent results using homogenized garlic in diabetic heart and explaining the protective effect of this popular herb in preventing oxidative stress.<sup>6</sup> Due to the beneficial effects of garlic and voluntary exercise mentioned above, in this study, we decided to explore the combination effect of garlic with voluntary exercise on oxidative and lipid markers in diabetic animals. According to our data, simultaneous treatment with garlic and voluntary exercise lead to a higher increase of TAC level and a more reduced MDA content and cholesterol level than either of them alone in the serum and heart of type 1 diabetic rats. It was claimed that garlic improves SOD, GPX, and CAT activities.<sup>6</sup> This effect could be contributed primarily to a variety of sulfur-containing compounds and their precursors.<sup>37</sup> Furthermore, bioactive components of garlic may probably chelate the metal ions (Cu, Zn, Mn) and result in scavenge the superoxide ions leading to cellular redox status balance.<sup>38</sup> In addition, it was indicated that oxidative stress caused by the production of free radicals exacerbated by hypercholesterolemia may lead to endothelial dysfunction.<sup>39</sup> Therefore we also measured cholesterol level in the serum of diabetic animals following garlic consumption and voluntary exercise performance. In general, blood lipid levels have an important role in preventing long-term complications of DM including atherosclerosis.<sup>40</sup> The mechanism of lipid-lowering effect of garlic in part is inhibition of lipogenesis and stimulation of lipolysis in mature 3T3-L1 adipocytes.<sup>41</sup> However, molecular mechanisms for the protective effect of combined garlic and voluntary exercise during diabetes is unclear and requires further investigation.

### Conclusion

In conclusion, this study demonstrated that garlic and voluntary exercise alone or together reduced blood glucose, HbA1c, cholesterol, lipid peroxidation marker and improved antioxidant defense system in rats with type 1 diabetes. In addition, combined treatment of garlic and voluntary exercise is more effective in controlling above mentioned parameters in diabetic animals. These findings briefly reported the benefits of combination effect of

garlic and voluntary exercise on cholesterol, redox state, and glycemic parameters. Therefore, we confirmed the potential value of combination therapy in diabetic individuals.

### Ethical approval

This study was agreed by the Ethics Committee on Animal Experiments of the Tabriz University of Medical Sciences under the protocol number 91.4-2.4.

### Competing interests

All authors declare no competing financial interests exist.

### Acknowledgements

This study was supported by a grant from the Drug Applied Research Centre, Tabriz University of Medical Sciences, Tabriz, Iran.

### References

- Poornima IG, Parikh P, Shannon RP. Diabetic cardiomyopathy: the search for a unifying hypothesis. *Circ Res* 2006;98(5):596-605. Doi: 10.1161/01.RES.0000207406.94146.c2
- Rains JL, Jain SK. Oxidative stress, insulin signaling, and diabetes. *Free Rad Biol Med* 2011;50(5):567-75. Doi: 10.1016/j.freeradbiomed.2010.12.006.
- Matough FA, Budin SB, Hamid ZA, Alwahaibi N, Mohamed J. The role of oxidative stress and antioxidants in diabetic complications. *Sultan Qaboos Univ Med J* 2012;12(1):5-18.
- Yaribeygi H, Mohammadi MT, Sahebkar A. Crocin potentiates antioxidant defense system and improves oxidative damage in liver tissue in diabetic rats. *Biomed Pharmacother* 2018;98:333-7. Doi: 10.1016/j.biopha.2017.12.077
- Nishikawa T, Edelstein D, Du XL, Yamagishi S, Matsumura T, Kaneda Y, et al. Normalizing mitochondrial superoxide production blocks three pathways of hyperglycaemic damage. *Nature* 2000;404(6779):787-90. Doi: 10.1038/35008121.
- Naderi R, Mohaddes G, Mohammadi M, Alihemmati A, Badalzadeh R, Ghaznavi R, et al. Preventive effects of garlic (*Allium sativum*) on oxidative stress and histopathology of cardiac tissue in streptozotocin-induced diabetic rats. *Acta Physiol Hung* 2015;102(4):380-90. Doi: 10.1556/036.102.2015.4.5
- Sies H. Oxidative stress: a concept in redox biology and medicine. *Redox Biol* 2015;4:180-3. Doi: 10.1016/j.redox.2015.01.002
- Sindhu RK, Koo JR, Roberts CK, Vaziri ND. Dysregulation of hepatic superoxide dismutase, catalase and glutathione peroxidase in diabetes: response to insulin and antioxidant therapies. *Clin Exp Hypertens* 2004;26(1):43-53.
- Naderi R, Mohaddes G, Mohammadi M, Ghaznavi R, Ghyasi R, Vatankhah AM. Voluntary Exercise Protects Heart from Oxidative Stress in Diabetic Rats. *Adv Pharm Bull* 2015;5(2):231-6. Doi: 10.15171/apb.2015.032
- Brocardo PS, Boehme F, Patten A, Cox A, Gil-Mohapel J, Christie BR. Anxiety- and depression-like behaviors are accompanied by an increase in oxidative stress in a rat model of fetal alcohol spectrum disorders: Protective effects of voluntary physical exercise. *Neuropharmacology* 2012;62(4):1607-18. Doi: 10.1016/j.neuropharm.2011.10.006
- Lanzotti V. The analysis of onion and garlic. *J Chromatogr A* 2006;1112(1-2):3-22. Doi: 10.1016/j.chroma.2005.12.016
- Naderi R, Mohaddes G, Mohammadi M, Alihemmati A, Khamaneh A, Ghyasi R, et al. The Effect of Garlic and Voluntary Exercise on Cardiac Angiogenesis in Diabetes: The Role of MiR-126 and MiR-210. *Arq Bras Cardiol* 2019;112(2):154-162. doi: 10.5935/abc.20190002.
- Mohammadi M, Ghaznavi R, Keyhanmanesh R, Sadeghipour HR, Naderi R, Mohammadi H. Voluntary exercise prevents lead-induced elevation of oxidative stress and inflammation markers in male rat blood. *ScientificWorldJournal* 2013;2013:320704. Doi: 10.1155/2013/320704
- SomiMH, HajipourB, AslNA, EstakhriR, AzarAN, ZadeMN, et al. Pioglitazone attenuates ischemia/reperfusion-induced liver injury in rats. *Transplant Proc* 2009;41(10):4105-9. Doi: 10.1016/j.transproceed.2009.09.075
- Badalzadeh R, Layeghzadeh N, Alihemmati A, Mohammadi M. Beneficial effect of trolox on diabetes-induced vascular damages in rat aorta: histopathological alterations and antioxidation mechanism. *Int J Endocrinol Metab* 2015;13(2):e25969. Doi: 10.5812/ijem.25969
- Tsai CY, Wen SY, Shibu MA, Yang YC, Peng H, Wang B, et al. Diallyl trisulfide protects against high glucose-induced cardiac apoptosis by stimulating the production of cystathionine gamma-lyase-derived hydrogen sulfide. *Int J Cardiol* 2015;195:300-10. Doi: 10.1016/j.ijcard.2015.05.111
- Woodiwiss AJ, Kalk WJ, Norton GR. Habitual exercise attenuates myocardial stiffness in diabetes mellitus in rats. *Am J Physiol* 1996;271(5 Pt 2):H2126-33. Doi: 10.1152/ajpheart.1996.271.5.H2126
- Jain N, Vijayaraghavan R, Pant SC, Lomash V, Ali M. Aloe vera gel alleviates cardiotoxicity in streptozocin-induced diabetes in rats. *J Pharm Pharmacol* 2010;62(1):115-23. Doi: 10.1211/jpp.62.01.0013
- Mahmoud AM. Exercise Amaliorates Metabolic Disturbances and Oxidative Stress in Diabetic Cardiomyopathy: Possible Underlying Mechanisms. Exercise for Cardiovascular Disease Prevention and Treatment. Springer; 2017. p. 207-30.
- Seo DY, Lee S, Figueroa A, Kwak YS, Kim N, Rhee BD, et al. Aged garlic extract enhances exercise-mediated improvement of metabolic parameters in high fat diet-induced obese rats. *Nutr Res Pract* 2012;6(6):513-9. Doi: 10.4162/nrp.2012.6.6.513
- Singh R, Devi S, Gollen R. Role of free radical in atherosclerosis, diabetes and dyslipidaemia: larger-than-life. *Diabetes Metab Res Rev* 2015;31(2):113-26. Doi: 10.1002/dmrr.2558
- Dembinska-Kiec A, Mykkanen O, Kiec-Wilk B, Mykkanen H. Antioxidant phytochemicals against type 2 diabetes. *Br J Nutr* 2008;99 E Suppl 1:Es109-17. Doi: 10.1017/s000711450896579x
- Sun X, Chen RC, Yang ZH, Sun GB, Wang M, Ma XJ, et

- al. Taxifolin prevents diabetic cardiomyopathy in vivo and in vitro by inhibition of oxidative stress and cell apoptosis. **Food Chem Toxicol** 2014;63:221-32. Doi: 10.1016/j.fct.2013.11.013
24. Hilberg T. [Physical activity in the prevention of cardiovascular diseases. Epidemiology and mechanisms]. **Hamostaseologie** 2008;28(1-2):9-12, 4-5.
25. Wisloff U, Stoylen A, Loennechen JP, Bruvold M, Rognum O, Haram PM, et al. Superior cardiovascular effect of aerobic interval training versus moderate continuous training in heart failure patients: a randomized study. **Circulation** 2007;115(24):3086-94. Doi: 10.1161/circulationaha.106.675041
26. Mahmoud AM. Exercise Amaliorates Metabolic Disturbances and Oxidative Stress in Diabetic Cardiomyopathy: Possible Underlying Mechanisms. **Adv Exp Med Biol** 2017;999:207-30. Doi: 10.1007/978-981-10-4307-9\_12
27. Ishikawa Y, Gohda T, Tanimoto M, Omote K, Furukawa M, Yamaguchi S, et al. Effect of exercise on kidney function, oxidative stress, and inflammation in type 2 diabetic KK-A(y) mice. **Exp Diabetes Res** 2012;2012:702948. Doi: 10.1155/2012/702948
28. Moningka NC, Cunningham MW, Jr., Sterling M, West CA, Verlander JW, Croker BP, et al. Effects of voluntary wheel running on the kidney at baseline and after ischaemia-reperfusion-induced acute kidney injury: a strain difference comparison. **J Physiol** 2013;591(5):1313-24. Doi: 10.1113/jphysiol.2012.244327
29. Asha Devi S, Prathima S, Subramanyam MV. Dietary vitamin E and physical exercise: II. Antioxidant status and lipofuscin-like substances in aging rat heart. **Exp Gerontol** 2003;38(3):291-7.
30. Wang JS, Lin CC, Chen JK, Wong MK. Role of chronic exercise in decreasing oxidized LDL-potentiated platelet activation by enhancing platelet-derived no release and bioactivity in rats. **Life Sci** 2000;66(20):1937-48.
31. de Lemos ET, Reis F, Baptista S, Pinto R, Sepodes B, Vala H, et al. Exercise training is associated with improved levels of C-reactive protein and adiponectin in ZDF (type 2) diabetic rats. **Med Sci Monit** 2007;13(8):Br168-74.
32. Hasliza A, Noordin M, Goh Y. Effects of exercise and dietary polyunsaturated fatty acid on blood lipid profiles of streptozotocin-induced diabetes in rats. **Pertanika Journal of Tropical Agricultural Science** 2011;34(1):151-5.
33. Peeri M, Habibian M, Azarbayjani MA, Hedayati M. Protective effect of aerobic exercise against L-NAME-induced kidney damage in rats. **Arh Hig Rada Toksikol** 2013;64(2):43-9. 10.2478/10004-1254-64-2013-2260
34. Wang GG, Li W, Lu XH, Zhao X, Xu L. Taurine attenuates oxidative stress and alleviates cardiac failure in type I diabetic rats. **Croat Med J** 2013;54(2):171-9.
35. Burneiko RC, Diniz YS, Galhardi CM, Rodrigues HG, Ebaid GM, Faine LA, et al. Interaction of hypercaloric diet and physical exercise on lipid profile, oxidative stress and antioxidant defenses. **Food Chem Toxicol** 2006;44(7):1167-72. Doi: 10.1016/j.fct.2006.01.004
36. Ravi Kiran T, Subramanyam MV, Prathima S, Asha Devi S. Blood lipid profile and myocardial superoxide dismutase in swim-trained young and middle-aged rats: comparison between left and right ventricular adaptations to oxidative stress. **J Comp Physiol B** 2006;176(8):749-62. Doi: 10.1007/s00360-006-0096-5
37. Nishimura H, Higuchi O, Tateshita K. Antioxidative activity of sulfur-containing compounds in Allium species for human LDL oxidation in vitro. **Biofactors** 2004;21(1-4):277-80.
38. Rajani Kanth V, Uma Maheswara Reddy P, Raju TN. Attenuation of streptozotocin-induced oxidative stress in hepatic and intestinal tissues of Wistar rat by methanolic-garlic extract. **Acta Diabetol** 2008;45(4):243-51. Doi: 10.1007/s00592-008-0051-x
39. Roco J, Alarcon G, Medina M, Zampini C, Isla MI, Jerez S. Oral administration of Zuccagnia punctata extract improves lipid profile, reduces oxidative stress and prevents vascular dysfunction in hypercholesterolemic rabbits. **Phytomedicine** 2018;48:104-11. Doi: 10.1016/j.phymed.2018.05.008
40. Badavi M, Abedi HA, Dianat M, Sarkaki AR. Exercise Training and Grape Seed Extract Co-Administration Improves Lipid Profile, Weight Loss, Bradycardia, and Hypotension of STZ-Induced Diabetic Rats. **Int Cardiovasc Res J** 2013;7(4):111-7.
41. Nam H, Jung H, Kim Y, Kim KH, Park SJ, et al. Aged black garlic extract regulates lipid metabolism by inhibiting lipogenesis and promoting lipolysis in mature 3T3-L1 adipocytes. **Food Sci Biotechnol** 2018;27(2):575-9. Doi: 10.1007/s10068-017-0268-y