



Case Report

Simultaneous resection of abdominal aortic aneurysm and left renal cell carcinoma: A rare case and review of the literature

Mohammad Mozafar¹, Sina Zarrintan^{1*}, R. Shane Tubbs^{2,3,4}

¹Division of Vascular & Endovascular Surgery, Department of General & Vascular Surgery, Shohada-Tajrish Hospital, Shahid Beheshti University of Medical Sciences, Tehran, Iran

²Department of Neurosurgery, Tulane University School of Medicine, New Orleans, LA, USA

³Department of Structural & Cellular Biology, Tulane University School of Medicine, New Orleans, LA, USA

⁴Department of Anatomical Sciences, St. George's University, Grenada

Article info

Article History:

Received: 25 April 2019
Accepted: 4 December 2019
published: 7 January 2020

Keywords:

Abdominal Aortic Aneurysm
Renal Cell Carcinoma
Nephrectomy

Abstract

We report a rare case of concomitant abdominal aortic aneurysm (AAA) and left renal cell carcinoma (RCC). The patient was an 81-year old man who presented with vague abdominal pain. The investigations revealed a 110*73*62 mm AAA together with 69*56 left renal mass. Open repair of AAA with left radical nephrectomy was conducted. A simultaneous procedure is safe and does not increase morbidity and mortality in selected cases.

Introduction

Concomitant renal cell carcinoma (RCC) and abdominal aortic aneurysm (AAA) is a rare entity.¹ The association between AAA and RCC raises several questions and options for surgical management of this synchronous condition are of debate and potential clinical concern.² Timing and type of procedures are decided based on patients' condition.³ In the present report, we discuss the simultaneous open repair of AAA and radical nephrectomy.

Case Report

Initial presentation. An 81-year old male patient referred to our vascular surgery clinic with a history of vague abdominal pain beginning from four months ago. The patient had diminished appetite, mild weight loss (5 kg) and generalized weakness. The patient did not have nausea, vomiting and change in bowel habits for the past four months. Anemia was present. There was not history of melena, hematemesis or hematochezia. The patient had history of hypertension and ischemic heart disease. He had also history of smoking (1 pack year) and opium use. The drug history was Nitrocontin 2.6 mg bid, losartan 25 mg daily, ASA 80 mg daily, atenolol 50 mg daily and pantoprazole 20 mg daily. The patient had a normal physical examination except for a pulsatile mass around his umbilicus. Upper and lower extremity pulses were normal.

Lab and imaging findings. The patient had a WBC count of 6000 per microliter. Hemoglobin concentration was 6.9 g/dL. Platelets were 430 000 per microliter. Electrolytes, serum creatinine, blood urea nitrogen, coagulation tests, liver functions tests and urine analysis were normal. Erythrocyte sedimentation rate (ESR) was 50 mm/h. An upper endoscopy and barium enema was conducted because of the persisting anemia. Both tests were normal. A computed tomography (CT) angiography of abdomen and pelvis was done. There was a 110*73*62 mm fusiform aneurysm in infra-renal abdominal aorta accompanied by mural thrombosis. Both common iliac arteries and their distal branches were normal (Figure 1; left). In addition, a 69*56 mm mass lesion was seen in the hilum of the left kidney. The mass had invasion to left renal vein (Figure 1; right).

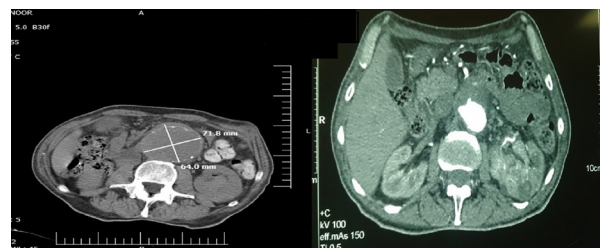


Figure 1. Computed tomography scan of the patient illustrating a 110*73*62 infra-renal abdominal aortic aneurysm together with a 69*65 mm mass lesion in left kidney.



*Corresponding Author: Sina Zarrintan, Email: s.zarrintan@yahoo.com

© 2020 The Author (s). This is an open access article distributed under the terms of the Creative Commons Attribution License (<http://creativecommons.org/licenses/by/4.0>), which permits unrestricted use, distribution, and reproduction in any medium, provided the original work is properly cited.

Surgical management. A single stage aneurysmectomy and left radical nephrectomy was planned. A midline laparotomy was conducted for transperitoneal repair of AAA. A tubular 22 mm Dacron graft was used to replace the infra-renal segment of the aorta (Figure 2). Following aneurysm repair, exploration of left kidney confirmed the presence of a 7*7 cm mass at the hilum. A left radical nephrectomy was performed (Figure 3). The patient tolerated the operation well and postoperative period was without any morbidity. The pathological examination of left kidney revealed clear cell type RCC.

Discussion

Presentation of concomitant AAA and RCC is of potential concern and clinical interest.⁴ AAA is typically increased with aging and incidence of a number of malignancies is also increased by age. Thus, association of AAA and visceral malignancies is becoming more frequent.^{2,5} The therapeutic and surgical strategies of management of AAA and RCC are controversial regarding one-stage and two-stage approaches and also the priority of each entity.¹ Nephrectomy is done by open or laparoscopic approach. AAA is approached either by open aneurysmectomy and graft replacement or by endovascular aneurysm repair (EVAR) technique.⁵⁻⁷ One-stage or simultaneous approach manages AAA (open repair or EVAR) and renal carcinoma in one operative session. However, in two-staged approach the aneurysm or renal carcinoma is managed first based

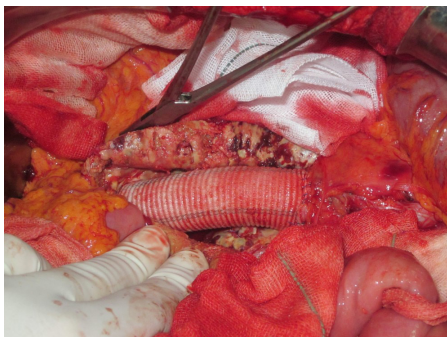


Figure 2. Open repair of abdominal aortic aneurysm by a tubular Dacron graft.

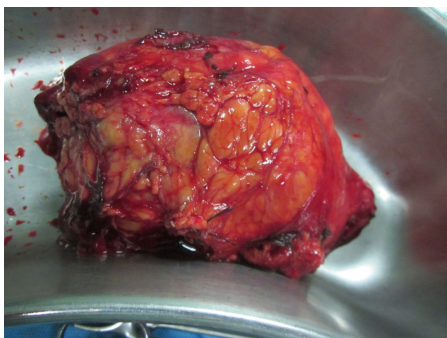


Figure 3. Left radical nephrectomy demonstrating a hilar mass lesion.

on the clinical significance of each condition.⁸⁻¹⁰

In the present article, we report a case of an 81-old male with synchronous AAA and left RCC. We conducted simultaneous open AAA repair and open radical nephrectomy. Likewise, in most of the previously reported cases, simultaneous open nephrectomy and AAA surgery have been suggested as a standard and safe treatment.^{2,6} However, in high risk and elderly patients, the procedure could be life threatening and endovascular techniques would decrease morbidity and mortality. Currently, EVAR is the primary treatment method for the repair of infra-renal AAA due to improved short-term outcomes.¹¹ In addition, moderate-quality evidence suggests that there is no difference in 30-day mortality between emergency EVAR and open repair.¹² Thus, recent reports recommend EVAR technique followed by laparoscopic nephrectomy in two stages to manage synchronous AAA and RCC. Nephrectomy is also conducted laparoscopically.^{5,7}

A comprehensive literature review revealed 94 cases of previously reported concomitant AAA and RCC cases. Table 1 demonstrates the studies reporting these cases. Of 94 reported cases, 73 patients (77.7%) had one-stage AAA and RCC management while 21 patients (22.3%) had two-stage operation. EAVR was used in 6 patients (6.4%)^{3,5,7,15} and open AAA repair was conducted in 88 patients (93.6%). Open nephrectomy was conducted in 90 patients (95.7%). Laparoscopic nephrectomy was used in two patients (2.1%).^{5,7} In one patient (1.1%), the accessory lower pole renal artery which supplied the tumor was ligated and tumor regression was evident.¹⁵ Two patients had horseshoe kidney, RCC and AAA. In one patient, a left radical nephrectomy with the division of the isthmus was conducted and AAA was reconstructed with an artificial graft.¹³ The other case had an AAA with a horseshoe kidney and an isthmus mass. Endovascular management of AAA was conducted and two accessory renal arteries believed to feed the isthmus mass were sacrificed.¹⁵ Horseshoe kidney regardless of RCC could also be associated with AAA.^{19,20} Preoperative arteriography and venography has been proposed to clarify the anatomy preoperatively.¹³ Endovascular techniques are safe and feasible in the management of synchronous AAA and horseshoe kidney even in the presence of malignancy.¹⁵

In conclusion, single-stage surgical treatment of AAA and RCC is a safe and feasible approach. AAA is repaired by open technique followed by radical or partial nephrectomy. However, current data suggest endovascular management of AAA. In this approach, laparoscopic nephrectomy is conducted either in the same admission or a few weeks later. If a gastrointestinal malignancy accompanies RCC, the priority of cancer surgery and AAA surgery should be weighed. In the cases of metastatic cancer, EVAR is used followed by chemotherapy for cancer.

Competing interests

None.

Table 1. Literature review presenting previously reported cases of concomitant abdominal aortic aneurysm and renal cell carcinoma

Author(s)	Year	Patient(s)	Procedure	AAA	Nephrectomy*
Baskin et al ⁸	1991	1	One-stage	Open	Open nephrectomy
DeMasi et al ⁶	1994	5	One-stage:4 Two-stage:1	Open	Open nephrectomy
Galt et al ⁴	1995	10	One-stage	Open	Open nephrectomy
Konety et al ⁹	1996	10	One-stage	Open	Open nephrectomy
Tsuji et al ¹⁰	1999	1	One-stage	Open	Open nephrectomy
Hafez et al ³	2000	27	One-stage: 11 Two-stage: 16	Open: 24 EVAR: 3	Open nephrectomy
Kouzai et al ^{13**}	2000	1	One-stage	Open	Open nephrectomy
Marrocco-Trischitta et al ¹⁴	2001	1	One-stage	Open	Open nephrectomy
Toursarkissian et al ^{15**}	2001	1	One-stage	EVAR	Endovascular
Illuminati et al ¹⁶	2004	1	One-stage	Open	Open nephrectomy
Veraldi et al ²	2006	12	One-stage: 10 Two-stage: 2	Open	Open nephrectomy
Somani et al ¹⁷	2009	1	One-stage	Open	Open nephrectomy
Pattaras & Milner ⁷	2009	1	Two-stage	EVAR	Laparoscopic nephrectomy
Kira et al ⁵	2012	1	Two-stage	EVAR	Laparoscopic nephrectomy
Sammur et al ¹⁸	2012	1	One-stage	Open	Accessory artery ligation
Třeška et al ¹	2014	19	One-stage	Open	Open nephrectomy
Mozafar et al	2020	1	One-stage	Open	Open nephrectomy

AAA, abdominal aortic aneurysm; EVAR, endovascular aneurysm repair.

*Partial or radical nephrectomy.

**Horseshoe kidney.

Ethical approval

Ethical approval is not necessary for retrospective studied and case presentation in our institutional policies. However, informed consent has been obtained from the patient to publish this case.

References

1. Třeška V, Hora M, Certík B, Moláček J, Houdek K, Náhlík J, et al. Simultaneous procedure in patients with abdominal aortic aneurysm and renal carcinoma. *Rozhl Chir* 2014;93(8):424-7.
2. Veraldi GF, Tasselli S, De Manzoni G, Cordiano C. Surgical treatment of abdominal aortic aneurysm with concomitant renal cell carcinoma: a single-centre experience with review of the literature. *J Cardiovasc Surg (Torino)* 2006;47(6):643-9.
3. Hafez KS, El Fettouh HA, Novick AC, Ouriel K. Management of synchronous renal neoplasm and abdominal aortic aneurysm. *J Vasc Surg* 2000;32(6):1102-10. doi: 10.1067/mva.2000.111539
4. Galt SW, McCarthy WJ, Pearce WH, Carter MF, Dalton DP, Garnett JE, et al. Simultaneous abdominal aortic aneurysm repair and nephrectomy for neoplasm. *Am J Surg* 1995;170(2):227-30. doi: 10.1016/s0002-9610(99)80292-x
5. Kira S, Sawada N, Kudou S, Zakoji H, Kaga S, Matsumoto M, et al. Successful staged management of simultaneous abdominal aortic aneurysm and renal tumor: the novel minimally invasive treatment with endovascular aneurysm repair and retroperitoneal laparoscopic radical nephrectomy in an elderly and high-risk case. *Clin Pract* 2012;2(2):e45. doi: 10.4081/cp.2012.e45
6. DeMasi RJ, Gregory RT, Snyder SO, Gayle RG, Parent FN, Wheeler JR. Coexistent abdominal aortic aneurysm

and renal carcinoma: management options. *Am Surg* 1994;60(12):961-6.

7. Pattaras JG, Milner R. Staged minimally invasive treatment of inflammatory abdominal aortic aneurysm and renal cell carcinoma. *Can J Urol* 2009;16(2):4596-8.
8. Baskin LS, McClure RD, Rapp JH, Perez S, Krupski WC. Simultaneous resection of renal carcinoma and abdominal aortic aneurysm. *Ann Vasc Surg* 1991;5(4):363-5. doi: 10.1007/BF02015298
9. Konety BR, Shuman B, Webster M, Steed DL, Bahnson RR. Simultaneous radical nephrectomy and repair of abdominal aortic aneurysm. *Urology* 1996;47(6):813-8. doi: 10.1016/S0090-4295(96)00039-8
10. Tsuji Y, Watanabe Y, Ataka K, Sasada A, Okada M. Intraabdominal nonvascular operations combined with abdominal aortic aneurysm repair. *World J Surg* 1999;23(5):469-74; discussion 474-5. doi: 10.1007/pl00012333
11. Wang LJ, Prabhakar AM, Kwolek CJ. Current status of the treatment of infrarenal abdominal aortic aneurysms. *Cardiovasc Diagn Ther* 2018 Apr;8(Suppl 1):S191-S199. doi: 10.21037/cdt.2017.10.01
12. Badger S, Forster R, Blair PH, Ellis P, Kee F, Harkin DW. Endovascular treatment for ruptured abdominal aortic aneurysm. *Cochrane Database Syst Rev* 2017;5:CD005261. doi: 10.1002/14651858.CD005261.pub4
13. Kouzai T, Takase K, Suwa Y, Moriyama M, Mou M, Kurata H, et al. Renal cell carcinoma in a horseshoe kidney with abdominal aortic aneurysm: a case report. *Hinyokika Kiyo* 2000;46(1):15-7.
14. Marrocco-Trischitta MM, Scicchitano G, Acconcia A, Stillo F. Management of synchronous abdominal aortic aneurysm and renal carcinoma associated with duplication

- of the inferior vena cava. **J Cardiovasc Surg (Torino)** 2001;42(5):683-5.
15. Toursarkissian B, Mejia A, Wholey MH, Lawler MA, Thompson IM, Sykes MT. Endovascular AAA repair in a patient with a horseshoe kidney and an isthmus mass. **J Endovasc Ther** 2001;8(6):604-8. doi: 10.1177/1526660280100800613
 16. Illuminati G, Calio' FG, D'Urso A, Lorusso R, Ceccanei G, Vietri F. Simultaneous repair of abdominal aortic aneurysm and resection of unexpected, associated abdominal malignancies. **J Surg Oncol** 2004;88(4):234-9. doi: 10.1002/jso.20149
 17. Somani BK, Nicol G, Bhavan R, Swami S, Nabi G. Abacus Research Group. Synchronous resections of intra-abdominal pathologies during radical nephrectomy. A case-linked cohort study evaluation of outcomes. **Eur J Surg Oncol** 2009;35(8):844-51. doi: 10.1016/j.ejso.2008.09.007
 18. Sammut J, Ahiaku E, Williams DT. Complete regression of renal tumour following ligation of an accessory renal artery during repair of an abdominal aortic aneurysm. **Ann R Coll Surg Engl** 2012;94(6):e198-200. doi: 10.1308/003588412X13373405384972
 19. De Caridi G, Massara M, Greco M, Mastrojeni C, Serra R, Salomone I, et al. Surgical Treatment of a Voluminous Infrarenal Abdominal Aortic Aneurysm with Horseshoe Kidney: Tips and Tricks. **Ann Vasc Dis** 2015;8(4):324-7. doi: 10.3400/avd.cr.15-00083
 20. Han A, Kim SM, Choi C, Min SI, Ha J, Min SK. Open Surgical Repair of Abdominal Aortic Aneurysm Coexisting with Horseshoe Kidney. **Vasc Specialist Int** 2015;31(2):54-7. doi: 10.5758/vsi.2015.31.2.54