

A severe *Morganella morganii* endophthalmitis; followed by bacteremia

Tayfur Demiray^{1*}, Ozlem Akkaya Aydemir¹, Mehmet Koroglu², Ahmet Ozbek², Mustafa Altindis²

¹Department of Clinical Microbiology, Sakarya Research and Training Hospital, Sakarya, Turkey

²Department of Medical Microbiology, School of Medicine, Sakarya University, Sakarya, Turkey

Received: October 2015 , Accepted: January 2016

ABSTRACT

Morganella morganii is rarely isolated from nosocomial infections. However, postoperative infections due to *Morganella* spp. were documented in literature and eye involvements of the infections usually result in severe sequels. We present a severe case infection, which was caused by *M. morganii* subsp. *morganii*, firstly appearing as conjunctivitis and complicated by bacteremia. The infectious agent isolated from both conjunctival and consecutive blood cultures. Identification and antimicrobial susceptibility tests were performed with the Vitek 2[®] automated system. The isolate was resistant to cephalosporins and carbapenems and it had ability to produce extended spectrum beta-lactamases. Patient was successfully treated with intravenous ciprofloxacin according to susceptibility test results. This is the first report of *M. morganii* infection detected as a local infection then complicated by bacteremia.

Keywords: *Morganella morganii*, Conjunctivitis, Bacteremia, Ciprofloxacin

INTRODUCTION

Morganella morganii is a Gram-negative bacillus commonly found in the environment and in the intestinal tracts of humans as normal flora. It is previously classified under the genus *Proteus*, *Proteus morganii*. Now, it belongs to genus *Morganella*. *M. morganii* is the single member of the genus with two subspecies; *M. morganii* subsp. *morganii* and *M. morganii* subsp. *sibonii* (1). Despite its wide distribution, it is relatively rare cause of invasive infection. It is mostly encountered in postoperative cases and

rarely (less than 1%) nosocomial infections as opportunistic pathogen in hospitalized patients, particularly those on antibiotic therapy such as neonatal sepsis, brain abscess, pericarditis, endophthalmitis (2-5).

Here, we present a severe case of *Morganella morganii* infection. The case is worth mentioning since the infection began as postoperative endophthalmitis and periorbital ulcerations, and complicated by bacteremia. As far as we know this is the first reported case of *M. morganii* with those complex infection characteristics.

CASE REPORT

A 76-year-old female diabetic patient admitted to ophthalmology clinic due to bilateral post-operative conjunctivitis which occurred 15 days after cataract surgery (Picture). She was suffering severe pain, photophobia and decreased vision. Signs of tense conjunctival injection and chemosis, corneal and periorbital edema, hypopyon, decreased red reflex

*Corresponding author: Dr. Tayfur Demiray

Mailing Adress: Sakarya Üniversitesi, Eğitimve Araştırma Hastanesi Klinik Mikrobiyoloji Laboratuvarı Adnan Men-
deres Caddesi, Sağlık Sokak 54100, Adapazarı, Sakarya,
Turkey

Tel: +9005304662700

Fax: +9002642552105

E-mail: tayfurdemiray@gmail.com

and visual acuity were detected in the eye examination. Conjunctival swab samples were sent to microbiology laboratory. Approximately at the 36th hour of the follow-up, patient deteriorated with presenting symptoms like dyspnea and tachycardia. Fever, low blood pressure, cardiac insufficiency and high glucose levels were primarily detected. There upon, she transferred to intensive care unit. Vital signs were as follows; body temperature 38.9 °C, arterial blood pressure 84/60 mm-Hg, respiratory rate 28/min. White blood cell count 12900/ml, hemoglobin 11,3 gr/dl, erythrocyte sedimentation rate 69 mm/hr, glucose 145 mg/dl detected as laboratory findings. Patient got monitored; cardiac supporting treatment began, and urine, sputum, blood cultures were collected. In the Gram stain of the conjunctival swab specimen, Gram-negative bacilli and inflammatory cells were observed abundantly. Both conjunctival and blood cultures yielded *M. morganii subsp. morganii*. Other cultures of the patient were negative. The Vitek 2[®] automated System (Biomérieux, France) was used for identification and antimicrobial susceptibility testing. Kirby-Bauer disc-diffusion method was also used to detect presence of extended spectrum beta lactamase (ESBL). Both of the isolates were resistant to ampicillin, ampicillin/sulbactam, cefazolin, cefuroxime, ceftriaxone, ceftazidime, meropenem and imipenem, and they produced ESBL. They were susceptible to quinolones and aminoglycosides. The patient was consulted to the department of infectious disease. Then, the patient was treated successfully with intravenous ciprofloxacin 200 mg, twice a day, according to susceptibility test results. After initiation of antimicrobial therapy, clinical response was achieved, WBC decreased to 8600/ml, and signs of sepsis regressed. At the 10th day of admittance, the patient was transferred to internal medicine department and the day of 16th, the patient was discharged healthy.

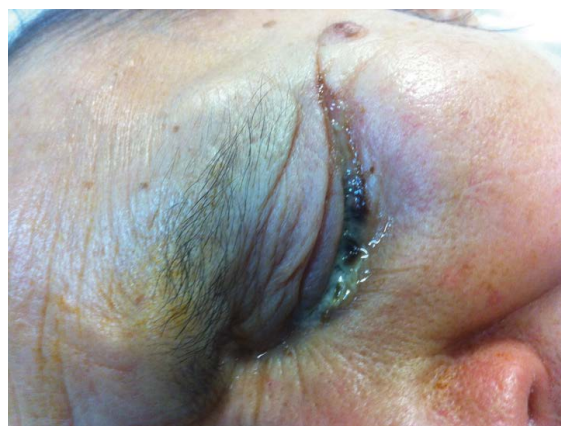
DISCUSSION

Endophthalmitis is one of the most serious ocular complication and despite the all precautions it still occurs nearly 0.1% of the patients following ophthalmic surgery (6). Most organisms that exist as normal flora implicated in endophthalmitis and peri-orbital ulcerations. Gram-negative bacteria are less commonly isolated than Gram-positive ones from

the patients with endophthalmitis. *Pseudomonas* spp., *Haemophilus* spp., *Klebsiella* spp., and *Proteus* spp. are frequent cause of Gram-negative endophthalmitis (7,8). In contrast, *M. morganii* is an uncommon isolate from normal ocular flora. Okumoto and colleagues isolated *M. morganii* from 5 of 1000 (0.5%) normal preoperative human eyes (9). It causes opportunistic infections especially in patients with risk factors such as immunosuppression, surgical trauma, malignancy, diabetes mellitus, malnutrition, long-term urinary catheterization, corticosteroid therapy, malignancy, intravenous drug use, alcoholism, and prior exposure to β -lactam antibiotics (10). In this case, previous surgery, diabetes mellitus, and exposure to β -lactam antibiotics served as predisposing factor and constituted backdrop for *M. morganii* infection.

Like other members of the *Enterobacteriaceae*, *M. morganii* has a natural resistance to β -lactam antibiotics. Many strains of *M. morganii* are resistant to the cefazolin, cefixime, cefpodoxime, and ampicillin (1, 11). The drug resistance of *M. morganii* occur due to extra genetic and/or mobile elements that carry *bla*_{CTX-M} genes producing β -lactamase (12, 13).

In our case, we detected that the isolate also had ESBL, which limited treatment choices. Resistance to carbapenems also was detected together with resistance to cephalosporins, which limited treatment options to the quinolones and aminoglycosides. Fortunately, the patient was treated with IV ciprofloxacin. It is obvious that early detection and accurate identification and antimicrobial susceptibility testing of the causative agent, is crucial to successfully treatment without any sequel such as blindness and/or death for *Morganella* infections.



Picture: Post-operative conjunctivitis caused by *M. morganii subsp. morganii*.

ACKNOWLEDGEMENTS

We would like to thank the staff of Ophthalmology Department of the Sakarya University Training and Research Hospital for obtaining patient's data.

REFERENCES

- O'Hara CM, Brenner FW, Miller JM. Classification, identification, and clinical significance of *Proteus*, *Providencia*, and *Morganella*. *Clin Microbiol Rev* 2000; 13:534-546.
- Johnson JR, Feingold M. 1998. Case of chorioamnionitis in an immunocompetent woman caused by *Morganella morganii*. *J Matern Fetal Med* 1998; 7:13-14.
- Salen PN, Eppes S. *Morganella morganii*, a newly reported, rare cause of neonatal sepsis. *Acad Emerg Med* 1997; 4:711-714.
- Sica S, Di Mario A, Salutari P, d'Onofrio G, Antinori A, Chiusolo P, Leone G. *Morganella morganii* pericarditis after resolventsple-nectomy for immune pancytopenia following allogeneic bone marrow transplantation for acute lymphoblastic leukemia. *Clin Infect Dis* 1995; 21:1052- 1053.
- Gebhart-Mueller Y, Mueller P, Nixon B. Unusual case of postoperative infection caused by *Morganella morganii*. *J Foot Ankle Surg* 1998;37:145-147.
- Jensen M, Fiscella R, Crandall A, Moshirfar M, Mooney B, Olson R, et al. Original Article: A retrospective study of endophthalmitis rates comparing quinolone antibiotics. *Am J Of Ophthalmol* [serial on the Internet]. (2005, Jan 1), 139: 141-148.
- Eifrig CW, Scott IU, Flynn HW, Miller D. Endophthalmitis caused by *Pseudomonas aeruginosa*. *Ophthalmology* 2003; 110:1714-1717.
- Scott IU, Matharoo N, Flynn HW, Miller D. Endophthalmitis caused by *Klebsiella* species. *Am J Ophthalmol* 2004;138: 662-663.
- Okumoto M, Smolin G, Belfort R, Kim HB, Siverio CE. Proteus species isolated from human eyes. *Am J Ophthalmol* 1976;81:495-501.
- Lee IK, Liu JW. Clinical characteristics and risk factors for mortality in *Morganella morganii* bacteremia. *J Microbiol Immunol Infect* 2006;39:328-34.
- Poirel L, Girlich D, Nordmann P, Guibert M, Naas T. Cloning, sequence analyses, expression, and distribution of ampC-ampR from *Morganella morganii* clinical isolates. *Antimicrob Agents Chemother* 1999;43:769-776.
- Flannery EL, Antczak SM, Mobley HL. Self-transmissibility of the integrative and conjugative element ICEPm1 between clinical isolates requires a functional integrase, relaxase, and Type IV secretion system. *J Bacteriol* 2011 ;193:4104-4112..
- Shi DS, Wang WP, Kuai SG, Shao HF, Huang M. Identification of bla KPC-2 on different plasmids of three *Morganella morganii* isolates. *Eur J Clin Microbiol Infect Dis* 2012;31:797-803.