

Bitot's Spots: Look at the Gut

Alka Sharma, Sourabh Aggarwal¹, Vishal Sharma²

Department of Medicine, Government Medical College and Hospital, Chandigarh, India,

¹Department of Internal Medicine, Western Michigan School of Medicine, Michigan, USA

²Department of Gastroenterology, Postgraduate Institute of Medical Education and Research, Chandigarh, India

Correspondence to:

Dr. Vishal Sharma,
Department of Gastroenterology,
Postgraduate Institute of Medical
Education and Research,
Chandigarh, India.
E-mail: docvishalsharma@gmail.com

Date of Submission: Nov 17, 2013

Date of Acceptance: Mar 17, 2014

How to cite this article: Sharma A, Aggarwal S, Sharma V. Bitot's Spots: Look at the Gut. *Int J Prev Med* 2014;5:1058-9.

ABSTRACT

Vitamin A deficiency (VAD) can cause a range of ocular manifestations, including night blindness, conjunctival and corneal xerosis and keratomalacia. It is an important cause of preventable blindness. Although usually a result of malnutrition, VAD can accompany malabsorption syndrome. We report a case of VAD as manifested by Bitot's spots and eventually diagnosed to have celiac disease. It is, therefore, important to consider gastrointestinal diseases causing malabsorption in the evaluation of VAD.

Keywords: Anemia, bitot's spots, celiac, malabsorption, malnutrition, vitamin A

INTRODUCTION

Vitamin A is a fat soluble vitamin which is made of a family of compounds called the retinoids. The deficiency of vitamin A may manifest with difficulty in night vision, dry skin, and hair. Whilst the most common cause of vitamin A deficiency (VAD) is malnutrition, any gastrointestinal disorder causing malabsorption of lipids can also result in VAD.

CASE REPORT

A 10-year-old boy presented with diarrhea since 1 year. He used to pass multiple stools in a day. He also complained of decreased vision in low lighting. The child was malnourished, had pallor and height for age and weight for age were lower than the 3rd percentile. He was eldest of the three siblings and belonged to a poor rural family. He also had superficial, irregularly-shaped, white lesions on the conjunctiva in both eyes [Figure 1]. Mild pitting pedal edema was noted and systemic examination was normal. Evaluation revealed low hemoglobin of 8 mg/dL (Normal 12-16 mg/dL), microcytes in peripheral smear and a mean corpuscular volume of 71 mm³, normal leukocyte count and thrombocytosis (5 lakh/mm³). The patient had low serum albumin (2.8 g/dL, Normal: 3.5-5 g/dL) and mild transaminitis (Alanine transaminase - 71 U/L, Normal: 0-35 U/L, aspartate transaminases AST- 75 U/L, 7-41 U/L) with a normal level of bilirubin. The work-up for cause of transaminitis including viral markers (surface antigen for hepatitis B and antibodies to hepatitis C virus) were nonreactive.

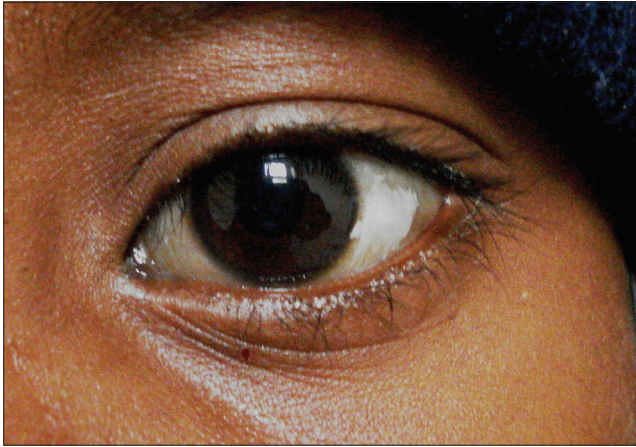


Figure 1: Bitot's spots

Upper gastroduodenoscopy showed grooving and scalloping in second part of duodenum. Duodenal biopsy revealed subtotal villous atrophy. immunoglobulin A (IgA) tissue transglutaminase was 213 U/mL (Normal: 0-8 U/mL).

DISCUSSION

Eponymised after Charles Bitot who first described them, Bitot's spots represent an ocular manifestation of VAD.^[1] VAD is an important cause of preventable blindness in the developing world. Clinical detection of Bitot's spots affords an opportunity for early diagnosis of VAD. Although VAD may have disappeared in the developed world, the condition is still common in the developing world. Since determination of levels of serum retinol are not available routinely ocular features ranging from night blindness, conjunctival xerosis and corneal xerosis, Bitot's spots and corneal ulceration and scarring may provide clinical clue to the diagnosis.

Lack of vitamin A affects the development of goblet cells in the conjunctiva resulting in accumulation of keratin debris. The Bitot's spots also demonstrate keratinization, irregular maturation, inflammatory infiltration and accumulations of Gram-positive bacilli.^[2] Generally seen as triangular spots, the Bitot's spots usually

have the tip laterally and may have a variable surface. These may be foamy and cheesy whitish lesions and are the most common indicator used to estimate VAD in community.^[3] Bitot's spots are usually due to nutritional VAD which is a common public health problem among preschool children in the developing world.^[4] Other conditions associated with systemic avitaminosis A may include reduced intake (alcoholism, mental illness, and dysphagia), disordered absorption (Crohn's disease, celiac sprue, pancreatic insufficiency, and short bowel syndrome), disordered transport (Abetalipoproteinemia) and reduced storage (liver disease).^[5] The clinical detection of Bitot's spots confirms VAD. Confirmation may be done by estimation of serum retinol or retinol binding protein levels. The efforts should be directed to evaluate the cause of VAD including reduced intake or any malabsorptive state. In the present case, a diagnosis of celiac sprue was established and patient put on gluten free diet with improvement in form of normal stool frequency and a gain of height and weight. The IgA tissue transglutaminase at 6 months was 3.8 U/mL.

REFERENCES

1. McLaren DS. Bitot's spots: A review of their significance after 100 years. *Br Med J* 1963;2:926.
2. Sommer A, Green WR, Kenyon KR. Bitot's spots responsive and nonresponsive to vitamin A. Clinicopathologic correlations. *Arch Ophthalmol* 1981;99:2014-27.
3. Darby WJ, Mcganity WJ, McLaren DS, Paton D, Alemu Z, Gebre-Medhen M. Bitot's spots and vitamin A deficiency. *Public Health Rep* 1960;75:738-43.
4. Awasthi S, Peto R, Read S, Clark S, Pande V, Bundy D, *et al.* Vitamin A supplementation every 6 months with retinol in 1 million pre-school children in north India: DEVTA, a cluster-randomised trial. *Lancet* 2013;381:1469-77.
5. Fernando-Langit A, Ilsen PF. Ocular manifestations of vitamin A deficiency. *Clin Refract Optom* 2008;19:86-93.

Source of Support: Nil, **Conflict of Interest:** None declared.