



Pustular Bacterid: Look at the Throat for Prevention over Treatment

Fariba Iraj, Bahareh Abtahi-Naeini, Hosein Heydari¹, Mohsen Pourazizi²

Department of Dermatology, Skin Diseases and Leishmaniasis Research Center, Isfahan University of Medical Sciences, Isfahan, Iran, ¹Pediatric Medicine Research Center, Qom University of Medical Sciences, Qom, Iran, ²Students' Research Committee, School of Medicine, Semnan University of Medical Sciences, Semnan, Iran

Correspondence to:

Dr. Bahareh Abtahi-Naeini, Department of Dermatology, Isfahan University of Medical Sciences, Isfahan, Iran. E-mail: bahareh.abtahi@yahoo.com

How to cite this article: Iraj F, Abtahi-Naeini B, Heydari H, Pourazizi M. Pustular bacterid: Look at the throat for prevention over treatment. *Int J Prev Med* 2015;6:51.

DEAR EDITOR,

Pustular bacterid (PB) is a pustular disorder of the hands and/or feet. It was first described by Andrews *et al.*^[1,2] There is controversy as to whether PB is a separate disease or is a variant of psoriasis pustulosa palmaris et plantaris (PPP).^[3] Until date, the etiology of PB has not been elucidated.

A 14-year-old boy presented with a 1-week history of pustules on both palms, a fever of approximately 38°C, sore throat, and cough. He had no personal or family history of psoriasis. Physical examination revealed multiple isolated 2–8 mm diameter pustules on both palms [Figure 1]. The hands and other parts of the body were spared. No fissured or geographic tongue was observed.

Laboratory tests, including routine blood, urine, and stool tests, were normal. Repeated cultures from pustular contents for microorganism were negative. Throat smears revealed many Gram-positive cocci. Throat cultures revealed *Streptococcus pyogenes*.

Pustular bacterid and acute upper respiratory tract infection were clinically diagnosed. Oral azithromycin was administered as a single daily dose for 3 days. The pustules resolved dramatically over the next 2 days. The fever, sore throat, cough, and expectoration were also relieved.

Many authors have found that PB is triggered by upper respiratory tract infections.^[4] PB has also been reported to be associated with sternocostoclavicular hyperostosis or Tietze's syndrome.^[5]

Many authors still question whether PB is a distinct disease. It is difficult to differentiate PB

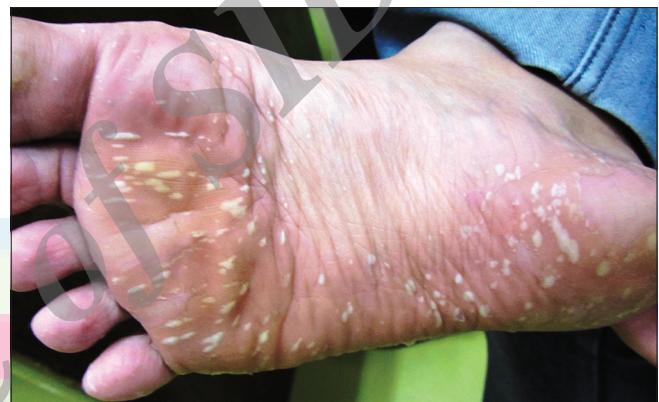

Figure 1: Pustular bacterid – Multiple, isolated 2–8 mm diameter sterile pustules on both palms

histopathologically from psoriasis PPP. PB manifests as isolated pustules with an erythematous rim, which do not destroy the ridged skin. On the rest of the integument, disseminated pustules are seen but no psoriatic stigmata.^[4]

Bacharach-Buhles *et al.* suggested that true PB had the following features: Coincidence with an infection, no personal or family history of psoriasis, isolated sterile pustules and no lesions of psoriasis vulgaris, good response to antibiotics, and a short course.^[4] Therefore, owing to the coincidence of PB with an infection, a targeted physical examination to detect the possible source of infection is necessary for accurate diagnosis and prevention over treatment.

The present case fulfilled the above-mentioned features of PB and had clinical manifestations fairly distinct from those of psoriasis PPP. No relapse of pustules occurred during a 1-year follow-up. This case provides further evidence that PB may be a distinct entity.


Received: 19 Aug 14 **Accepted:** 16 Apr 15

Published: 04 Jun 15

REFERENCES

1. Andrews GC, Machacek GF. Pustular bacteriids of the hands and feet. *Arch Derm Syphilol* 1935;32:837-47.
2. Andrews GC, Barnes MC. Pustular bacteriids and allied conditions. *South Med J* 1941;34:1260-5.
3. Murakami M, Ishida-Yamamoto A, Morhenn VB, Sayama K. Acute generalised pustular bacterid. *Lancet Infect Dis* 2013;13:655-6.
4. Bacharach-Buhles M, el Gammal S, Altmeyer P. The pustular bacterid (Andrews). Are there clinical criteria for differentiating from psoriasis pustulosa palmaris et plantaris? *Hautarzt* 1993;44:221-4.

5. Ishibashi A, Nishiyama Y, Endo M, Kawaji W, Kato T. Orthopedic symptoms in pustular bacterid (pustulosis palmaris et plantaris): Tietze's syndrome and arthritis of manubriosternal joint due to focal infection. *J Dermatol* 1977;4:53-9.

Access this article online	
Quick Response Code: 	Website: www.ijpvmjournal.net/www.ijpm.ir
	DOI: 10.4103/2008-7802.158180

Archive of SID