

Vertebral heart scale of common large breeds of dogs in Iran

Ghadiri, A.*; Avizeh, R. and Fazli, Gh.

Department of Clinical Sciences, Faculty of Veterinary Medicine, Shahid Chamran University, Ahvaz, Iran.

Key Words:

Vertebral heart size; dog; radiology.

Correspondence

Ghadiri, A.,
Department of Clinical Sciences,
Faculty of Veterinary Medicine, Shahid
Chamran University, Ahvaz, Iran.
Tel: +98(916)3114679
Fax: +98(611)3360807
E-mail: alighadiri@scu.ac.ir

Received 23 January 2008,

Accepted 13 June 2008

Abstract

In order to assess the influence of breed on the vertebral heart scale (VHS) of dogs, the VHS was measured and compared in left to right (LL) and right to left lateral (RL) views. For all dogs (n=56), the mean VHS on the RL radiographs [9.7 vertebra (v)] was significantly larger than the mean VHS on the LL radiographs (9.6 v) ($p=0.047$). Doberman dogs had higher mean values of the VHS in LL (9.9 v) and RL (10.1 v) views than all the other breeds, except in RL radiographs VHS of native dogs, although these differences were not significant. Native dogs had the lowest VHS in LL (9.4 v) and RL (9.4 v) radiographs than all of the other breeds. The mean VHS values for German shepherd dogs were 9.6 and 9.8 v and for mixed breeds of German shepherd and Doberman were 9.6 and 9.7 v in LL and RL radiographs, respectively. The mean VHS values in LL views were significantly smaller than in the RL view in Doberman and German shepherd dogs. No significant differences could be found between the VHS of LL and RL radiographs in mixed breed and native dogs.

Introduction

Radiological evaluation of the small animal thorax is one of the most important and frequently performed diagnostic tests in small animal practice. Despite the advent of echocardiography, thoracic radiography remains an integral part of the diagnosis and management of cardiac disease (Root and Bahr, 2002). Important information about heart disease is often obtained from thoracic radiographs. There are more variations in the normal canine heart than in any other organ, and the heart is inherently variable in size because of its contractility during the cardiac cycle. Additionally, there is considerable breed variation with regards to normal heart size and shape. It is important to consider the specific breed of dog whenever the heart is evaluated (Owens and Biery, 1999; Root and Bahr, 2002; Toal *et al.*, 1985; Silverman and Suter, 1975; Toombs and Ogburn, 1985).

A system of cardiac measurement was designed to take into account the inherent variation between breeds in cardiac size. The system is called the vertebral heart scale or size (VHS) and has been investigated in dogs, normal and obese cats, and ferrets by several authors. It uses the sum of the length and width of the cardiac silhouette, which is then translated into the total units of thoracic vertebral length to the nearest 0.1 vertebra (Buchanan and Bucheler, 1995; Buchanan, 2000; Litster and Buchanan 2000a; Litster and Buchanan

2000b; Sleeper and Buchanan, 2001; Stepien *et al.*, 1999).

Based on the examination of 100 clinically normal adult dogs of various breeds, the mean VHS was shown to be 9.7 ± 0.5 (mean \pm SD) and 10.2 ± 0.83 vertebrae in lateral and ventrodorsal radiographs, respectively (2, 3). Lamb *et al.* (2001) published breed-specific ranges for six breeds, in which the mean VHS was higher than 10.5 in three out of the six breeds, namely the cavalier King Charles spaniel (10.6 ± 0.5), Labrador retriever (10.8 ± 0.6) and Boxer (11.6 ± 0.8) vertebrae. In particular, boxer dogs had a larger cardiac silhouette than other breeds. Only the Doberman and the Yorkshire terrier had a normal range close to the generic reference range for the vertebral heart scale of 8.7 to 10.7 vertebrae, calculated from the data of Buchanan and Bucheler (1995). Hansson *et al.* (2005) reported that the mean VHS value in the normal cavalier King Charles spaniels was 10.8 ± 0.5 vertebrae, which is slightly above the suggested upper limit for normal heart size in most breeds.

Clearly, interbreed differences, and possibly sex, should be taken into account when evaluating the possibility of cardiomegaly on the basis of the VHS (Bavegems *et al.*, 2005; Hansson *et al.*, 2005; Lamb *et al.*, 2000; Lamb *et al.*, 2001). Therefore, the aims of this study were first to determine the reference range for the VHS of some popular large breeds of dog in Iran, and secondly, to determine whether there are significant differences between right and left lateral radiographs.

Materials and Methods

Dogs

Fifty-six healthy dogs were selected for the study from common large breed of dogs in Iran (12 German shepherd dogs, 12 Dobermans, 12 mixed breed of German shepherd and Doberman, and 20 native dogs). They were referred for a periodic health examination to the Department of Small Animal Medicine. The dogs were of various sizes with body weights between 25 and 40 kg. They were all skeletally mature (mean age 3.4 years; range: 1 to 5 yr). There were 25 females and 31 males. The clinical evaluation of all dogs included physical examination, auscultation of the heart, electrocardiography (ECG), and thoracic radiography.

Radiography

The radiographic examinations included right lateral (RL) and left lateral (LL) views. Radiographs were taken at the point of full inspiration, if possible, and the focus to film distance was 100 cm.

Radiographic measurements

Measurements were made with an adjustable caliper on each of the radiographs using the method described by Buchanan and Bucheler (1995). This involved marking the length of the long axis of the cardiac silhouette from the ventral border of the left main stem bronchus to the cardiac apex in cm. The caliper was then repositioned over the thoracic vertebrae, and the distance from the cranial edge of fourth thoracic vertebra (T4) was measured caudally. The distance of the caudal caliper point was estimated to the nearest 0.1 vertebra. The maximal short axis of the cardiac silhouette perpendicular to the long axis was measured in the same way. The measurements of the long and short axes were recorded in terms of the numbers of vertebrae covered and the two numbers were then added together to give the value of the VHS in each RL and LL views (Fig. 1).

The total lengths (cm) of three vertebrae were measured from cranial edge of T4 to caudal edge of the sixth thoracic vertebra (T6). The lengths (cm) of three sternbrae were also recorded from the cranial border of the second sternbra to the caudal end of the fourth sternbra in both the RL and LL radiographs.

Statistical analysis

Statistical analyses were performed with a computerized statistical software package (SPSS). For all measurements, the mean and the standard deviation (SD) were calculated. For each breed, a paired t-test was used to determine differences between mean averages of the VHS on the RL and LL views. Similar tests were performed to compare the mean values of the LL VHS of each breed to those of the other three breeds. These comparisons were repeated for the RL

VHS in each breed. Differences were considered to be statistically significant at $p < 0.05$.

Linear regression analyses (Pearson correlation coefficient [r]) assessed the presence of correlations between the following measurements: RL and LL cardiac long axes (mm) versus the distance from T4 to T6 (mm); RL and LL cardiac short axes (mm) versus the distance between T4 and T6 (mm); RL cardiac long and short axes (mm) versus the distance between sternbrae 2 and 4 (mm); and the sum of the RL and LL axes versus the distance from T4 to T6.

Results

Influence of breed on VHS

The cardiac measurements of all dogs in different groups are presented in Table 1. The mean (\pm SD) VHS for all dogs ($n=56$) were 9.6 ± 0.56 and 9.7 ± 0.59 vertebrae (v) in the LL and RL radiographs, respectively. The Kolmogorov-Smirnov test of normality showed that the VHS of LL (range: 8.6 - 10.9 v) and RL (range: 8.6 - 11.1 v) views had a normal distribution (Figures 2 and 3). Doberman dogs had none significantly higher mean values of the VHS in LL (9.9 ± 0.62 v) and RL (10.1 ± 0.61 v) views than all the other breeds. The exception to this was that the VHS in Doberman was significantly larger than native dogs ($p = 0.026$). Differences of the VHS on each view were not statistically significant between each breed of dogs. Native dogs had the lowest VHS in the LL (9.4 ± 0.55 v) and RL (9.4 ± 0.54 v) radiographs than the other breeds.

Influence of radiographic view on VHS

The overall mean VHS on the RL radiographs was significantly larger than the mean VHS on the LL radiographs. Additionally, the mean VHS in the LL view were significantly smaller than in the RL view in Doberman and German shepherd dogs. However, no significant differences could be found between the VHS of LL and RL radiographs in mixed breed and native dogs.

There were no significant differences between male and female dogs, cardiac long and short axes in LL and RL radiographs in each breed, or cardiac long and short axes between each group of dogs.

There was a significant correlation between the long heart axes versus the distance from T4 to T6 and the distance from sternbrae 2 to 4 in the LL and RL radiograph. The short heart axes in both radiographic views also correlated with the distance from T4 to T6 and the sternbrae 2-4 measurement (Table 2).

Discussion

In this study, VHS of 56 clinically normal dogs of popular large breeds in Iran were measured and compared in different lateral views. The use of one

Figure 1: Method for determining the vertebral heart size (VHS) measurement on a lateral thoracic radiograph. The long axis measurement of the cardiac silhouette (L) encompasses 5.3 thoracic vertebrae; the short axis measurement (S) encompasses 4.1 thoracic vertebrae. $VHS = 5.3 + 4.1 = 9.4v$. T4: cranial edge of the fourth thoracic vertebra.

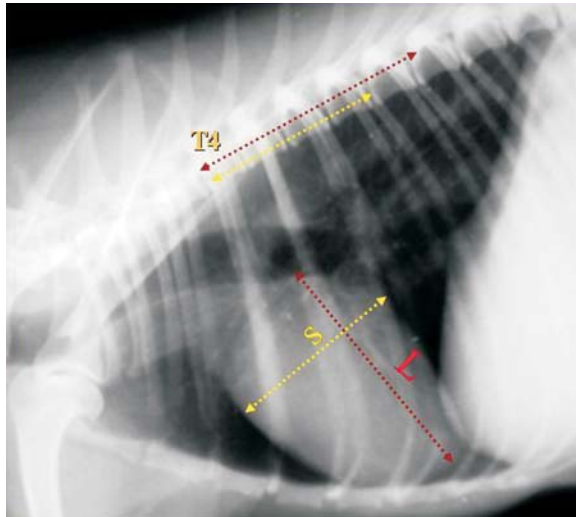


Figure 2: Distribution of vertebral heart size measurements (VHS) in the left lateral views of 56 clinically normal large breed dogs.

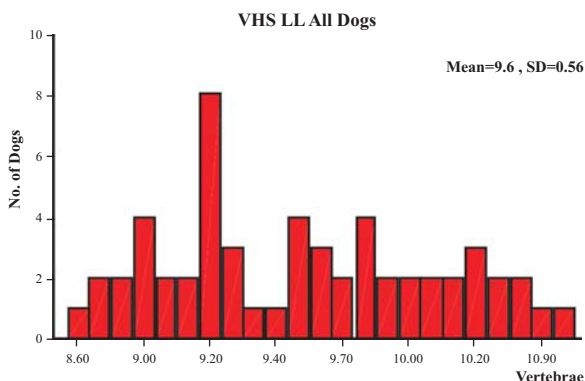


Figure 3: Distribution of vertebral heart size (VHS) measurements in the right lateral views of 56 clinically normal large breed dogs.

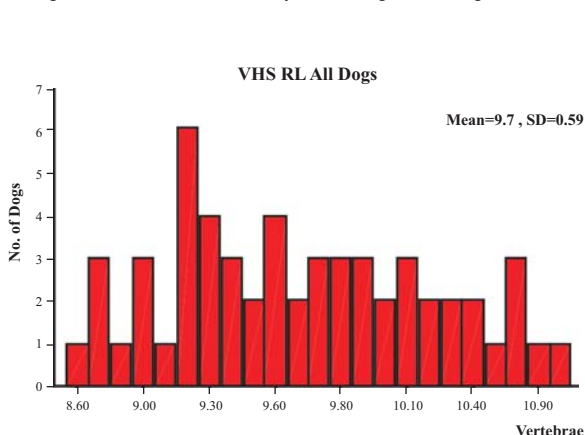


Table 1: The mean (\pm standard deviation), minimum and maximum cardiac measurements in right lateral and left lateral views of clinically normal dogs.

Breed of dog	Doberman (n=12)	German Shepherds (n=12)	Mixed breed (n=12)	Native dogs (n=20)	Total (n=56)
Measurements					
LL†, cardiac long axis (v)*	5.5 (0.36) 5 - 6	5.3 (0.31) 4.9 - 5.9	5.3 (0.31) 4.9 - 5.9	5.2 (0.38) 4.6 - 6.1	5.3 (0.37) 4.6 - 6.1
LL†, cardiac short axis (v)*	4.4 (0.28) 4.1 - 4.9	4.4 (0.22) 4.1 - 4.8	4.3 (0.11) 4.1 - 4.5	4.2 (0.31) 3.8 - 4.8	4.3 (0.27) 3.6 - 4.9
RL‡, cardiac long axis (v)*	5.6 (0.35) 5.1 - 6.1	5.4 (0.36) 4.9 - 6	5.3 (0.25) 5 - 5.8	5.2 (0.36) 4.6 - 6.3	5.3 (0.36) 4.6 - 6.3
RL‡, cardiac short axis (v)*	4.5 (0.29) 4 - 5	4.4 (0.23) 4.1 - 4.9	4.4 (0.19) 4.2 - 4.8	4.2 (0.30) 3.7 - 5	4.3 (0.29) 3.7 - 5.0
LL†, VHS (v)*	9.9 (0.62) 9.1 - 10.9	9.6 (0.57) 8.9 - 10.6	9.6 (0.37) 9.1 - 10.1	9.4 (0.55) 8.6 - 10.9	9.6 (0.56) 8.6 - 10.9
RL‡, VHS (v)*	10.1 (0.61) 9.2 - 11.1	9.8 (0.59) 9 - 10.9	9.7 (0.38) 9.2 - 10.3	9.4 (0.54) 8.6 - 10.7	9.7 (0.59) 8.6 - 11.1

*Length measured in vertebrae; † Right to left lateral; ‡ Left to right lateral.

Table 2: Correlation coefficients between cardiac measurements versus T4 to T6 vertebrae and sternbrae 2-4 in different radiographic views.

	RL view	LL view
Long heart axes vs. T4 to T6	$r=0.64^*$	$r=0.54^*$
Long heart axes vs. sternbrae 2-4	$r=0.58^*$	$r=0.52^*$
Short heart axes vs. T4 to T6	$r=0.57^*$	$r=0.62^*$
Short heart axes vs. sternbrae 2-4	$r=0.55^*$	$r=0.56^*$

* Significant correlations at $p<0.05$

breed of dog eliminated variations that could be caused by breed for measuring heart size. Cardiac measurements are likely to be useful only when the normal range is relatively narrow because standard measurements are based on dogs of one breed or similar breeds (Lamb *et al.*, 2000; Owens and Biery, 1999; Root and Bahr, 2002). Lamb *et al.* (2001) suggested that the use of breed-specific VHS values is required for the VHS method to have a high specificity for normal heart size. Also, the recognition of interbreed variations with regards to cardiac dimensions has already led to the development of breed-specific ranges for echocardiography in dogs (Nakayama, 2001; Morrison *et al.*, 1992). In our study, normal dogs of each of the other breeds had a range of values that was narrower and/or higher than that reported by Buchanan and Bucheler in 1995. In particular, Doberman dogs had a larger VHS and native dogs had a smaller VHS than other breeds. Furthermore, the mean VHS of Doberman dogs on lateral radiographs was significantly larger than the value of VHS reported previously by Buchanan and Bucheler (1995). However, the mean VHS of native dogs was significantly smaller than later study. This is in agreement with the previous observations of Lamb *et al.* (2000) and Bavegems *et al.* (2005), which showed that the value of the VHS has to be considered in the context of a specific breed of dog.

The differences of the mean VHS of German shepherds and mixed breeds of German shepherd and Doberman dogs were not significant in the report of

Buchanan and Bucheler (1995). The fact that our study showed no significant differences in the mean VHS of those two breed of dogs might be due their VHS values being very close to the reference mean VHS of 9.7 given by Buchanan and Bucheler (1995). The mean VHS values of Doberman and German shepherd dogs that were reported by Lamb *et al.* (2001) were 10 (0.6) v and 9.7 (0.7) v, respectively.

In a study on cavalier King Charles spaniel dogs, it was concluded that the VHS values for heart size can be affected by several factors (Hansson *et al.*, 2005). Individual variations in the actual heart size and vertebral length between breeds of dog need to be considered, as well as the presence of narrowed disc spaces. The observer who performs the measurements is also a cause of variation (Hansson *et al.*, 2005). It is also possible that part of the variability in the measurements may arise from the methods described by Buchanan and Bucheler in 1995 and Buchanan 2000, which requires observers to estimate the proportion of the last vertebra that is included in each heart measurement. However, another possibility that should be taken into consideration is that age can influence the VHS (Gaschen *et al.*, 1999; Sleeper and Buchanan, 2001). Therefore, as there are various factors that influence the VHS measurement, it would be better to use breed-specific VHS values. This eliminates the influence of various breed of dogs with different chest conformations on the mean VHS.

Native dogs in our country are not a registered breed of dog, and there is no reference range for their characteristics. However, these dogs that included Iranian herding dogs are medium-chested, just like German shepherds. In our study, the native dogs had a smaller mean VHS than other breeds of dogs; therefore, the thoracic vertebrae and heart sizes of the native dogs were, on average, slightly smaller than the other large breeds of dogs included in this study.

Buchanan and Bucheler reported in 1995 that the choice of right versus left lateral recumbency prior to radiographic examinations did not significantly influence VHS measurements. In contrast to their study, in our study, significant differences were seen between the mean VHS on the RL and LL radiographs in our overall cohort of dogs. Bavegems *et al.* (2005) reported that the mean VHS on the left-to-right lateral radiographs was significantly larger than the VHS on the right-to-left lateral radiographs of whippets. To our knowledge, there is no report that compares RL versus LL VHS in specific breeds of dogs, except for whippets. Nevertheless, we found no statistical difference between the RL and LL VHS in mixed breed and native dogs in our study. However, it should be considered that the position of the heart in the thoracic cavity, distortion, magnification, heart contractions, and respiratory movements affect the appearance of the cardiac heart silhouette in LL and RL radiographs

(Root and Bahr, 2002).

Furthermore, in accordance with the results of Buchanan and Bucheler (1995) and Bavegems *et al.* (2005), but in contrast to Lamb *et al.* (2000), no significant differences were found between males and females in any of the two radiographic views. This is in agreement with the reports of Buchanan and Bucheler and Litster and Buchanan (2001), who stated that the long and short axis dimensions on RL and LL radiographs were both correlated significantly with the T4 to T6 length and the sternbrae 2 to 4 length; therefore, an index of vertebral length has been selected by several authors as an indicator of body size.

Conclusion

The use of one breed of dog for the determination of VHS values in our study eliminated breed-specific variations. It is therefore important to consider the breed and the side of radiographic view when evaluating heart size in thoracic radiographs to avoid any erroneous interpretation of cardiac enlargement. Our study can be used as a guide in clinical practice for the evaluation of cardiac disease in common large breeds of dog in Iran.

References

1. Bavegems, V.; Van Caelenberg, A.; Duchateau, L.; Sys, S.U.; Van Bree, H. and De Rick, A. (2005) Vertebral heart size ranges specific for whippets. *Vet. Radiol. Ultrasound*. 46, 5: 400-403.
2. Buchanan, J.W.; Bucheler, H. (1995) Vertebral scale system to measure canine heart in radiographs. *J. Am. Vet. Med. Ass.* 206: 194-199.
3. Buchanan, J.W. (2000) Vertebral scale system to measure canine hearts size in radiographs. *Vet. Clin. North Am: Small Anim. Pract.* 30: 379-393.
4. Gaschen, L.; Lang, J.; Lin, S.; Ade-Damilano, M.; Busato, A.; Lombard, C.W. and Gaschen, F.P. (1999) Cardiomyopathy in dystrophin-deficient hypertrophic feline muscular dystrophy. *J. Vet. Intern. Med.* 13: 346-356.
5. Hansson, K.; Haggstrom, J.; Kvart, C. and Lord, P. (2005) Interobserver variability of vertebral heart size measurements in dogs with normal and enlarged hearts. *Vet. Radiol. Ultrasound*. 46: 122-30.
6. Lamb, C.R.; Tyler, M.; Boswood, A.; Skelly, B.J. and Cain, M. (2000) Assessment of the value of the vertebral heart scale in the radiographic diagnosis of cardiac disease in dogs. *Vet. Rec.* 146: 687-690.
7. Lamb, C.R.; Wilkeley, H.; Boswood, A. and Pfeiffer, D.U. (2001) Use of breed-specific ranges for the vertebral heart scale as an aid to the radiographic diagnosis of cardiac disease in dogs. *Vet. Rec.* 148: 707-711.
8. Litster, A.L.; Buchanan, J.W. (2000a) Radiographic and

- echocardiographic measurement of the obese cats. *Vet. Radiol. Ultrasound*. 41: 320-325.
9. Litster, A.L.; Buchanan, J.W. (2000b) Vertebral scale system to measure heart size in radiographs of cats. *J. Am. Vet. Med. Ass.* 216: 210-214.
 10. Morrison, S.A.; Moise, N.S.; Scarlett, I.; Mohammad, H. and Yeager, A.E. (1992) Effect of breed and bodyweight on echocardiographic values in four breeds of dogs of differing somatotype. *J. Vet. Intern. Med.* 6: 220-224.
 11. Nakayama, H.; Nakayama, T. and Hamlin, R.L. (2001) Correlation of cardiac enlargement as assessed by vertebral heart size and echocardiographic and electrocardiographic findings in dogs with evolving cardiomegaly due to rapid ventricular pacing. *J. Vet. Intern. Med.* 15: 217-221.
 12. Owens, J.M.; Biery, D.N. (1999) Radiographic interpretation for the small animal clinician. 2nd edition. Williams and Wilkins Company. pp: 190.
 13. Root, C.R.; Bahr, R.J. (2002) The heart and great vessels in Textbook of diagnostic veterinary radiology, Thrall DE (ed) 4th edition, W.B. Saunders Company, Philadelphia. pp: 402-419.
 14. Silverman, S.; Suter, P.F. (1975) Influence of inspiration and expiration on canine thoracic radiographs. *J. Am. Vet. Med. Assoc.* 166: 502-510.
 15. Sleeper, M.M.; Buchanan, J.W. (2001) Vertebral scale system to measure heart size in growing puppies. *J. Am. Vet. Med. Ass.* 219: 57-59.
 16. Stepien, R.L.; Benson, K.G. and Forrest, L.J. (1999) Radiographic measurement of cardiac size in normal ferrets. *Vet. Radiol. Ultrasound*. 40: 606-610.
 17. Toal, R.L.; Losonsky, J.M.; Coulter, D.B. and DeNovellis, R. (1985) Influence of cardiac cycle on the radiographic appearance of the feline heart. *Vet. Radiol.* 26: 63-69.
 18. Toombs, J.P.; Ogburn, P.N. (1985) Evaluating canine cardiovascular silhouettes: radiographic methods and normal radiographic anatomy. *Compend. Contin. Edu. Prct Vet.* 7: 579-587.