

## Infestations of *Piagetiella titan* (Menoponidae: Mallophaga) on juvenile white pelicans (*Pelecanus nocrotalus*, L.) in Urmia Lake National Park, northwest Iran.

Tavassoli, M.<sup>1\*</sup>; Salmanzadeh, R.<sup>2</sup> and Jabbari, H.<sup>2</sup>

<sup>1</sup>Department of Pathobiology, Faculty of Veterinary Medicine, Urmia University, Urmia, Iran. <sup>2</sup>Department of the Environment, West Azarbaijan, Urmia, Iran.

### Key Words:

*Piagetiella titan*; white pelican; Urmia Lake; Iran.

### Correspondence

Tavassoli, M.  
Department of Pathobiology, Faculty of Veterinary Medicine, Urmia University, Urmia, Iran.  
Tel: +98(441)2972654  
Fax: +98(441)2771926  
Email: mtavassoli2000@yahoo.com

Received: 02 February 2011,

Accepted: 01 April 2011

### Abstract

Pelecaniformes are large water birds feeding by hunting fish and living usually in the sea and in fresh water. Ectoparasitic lice of the genus *Piagetiella* are interesting from an ecological standpoint as they are found in the pouches of pelicans. Unlike chewing lice, which live on the body surface of the host, *P. titan* lives in the oral cavity of white pelicans (*Pelecanus nocrotalus*, L.). This study aimed to determine the infestation of white pelicans with *P. titan* in Urmia Lake, Northwest Iran, between June and August from 2004 to 2006. Sixty-two juvenile white pelicans at three different age groups of < 1 (n = 8), 1-2 (n = 23) and 3-7 (n = 31) weeks were investigated and 59 birds were found infested with lice. A total of 1637 lice were collected from the oral cavity and body of the birds, with the number of lice ranging from one to 112 per bird. *P. titan* were identified according to the criteria described by Price (1970), including the number of setae in various parts of body, the structures of prosternal, mesosternal and metasternal plates, the structures of female and male genitalia, presence of two ventral stout subapical setae on tibia II-III and the number of the ctenidia on femur III. This report describes *P. titan* on pelicans for the first time from Iran.

### Introduction

Pelecaniformes are large water birds feeding by hunting fish and living usually in the sea and fresh water. They have evolved into the families Pelecanidae, Anhingidae, Sulidae and Phalacrocoracidae. Pelicanidae consist of *Pelecanus occidentalis* (brown pelican), *P. erythrorhynchus* (american white pelican), *P. philippiensis* (spot-billed pelican), *P. crispus* (dalmatian pelican), *P. onocrotalus* (great white pelican), *P. conspicillatus* (australian pelican) and *P. rufescens* (pink-backed pelican) (Dalglish, 2006). *P. onocrotalus* and *P. crispus* are the only species reported from Iran (Scott, 2006). The pelican lice, including *Piagetiella* spp. (*P. titan*), and their morphological characteristics were described for the first time by Price (1970). The members of *Piagetiella* genus are unique among other lice as they are found in the pouches of pelicans.

Hellenthal *et al.* (2004) listed chewing lice and their hosts in Belgium and reported *P. titan* on white pelicans (Hellenthal *et al.*, 2004). Dik and Uslu described *P. titan* from Turkey (2006), and it has also been reported from white pelicans in France (Séguy, 1994).

The Nine Islands National Park (37° 18' N and

45°41' E), located in Urmia Lake in the West Azarbaijan province in the Northwest of Iran, has a total area of 5m150 km<sup>2</sup> and a cold and semi-arid climate. It has a maximum mean temperature of 28.3°C in August, a minimum mean temperature of -5°C in January and mean annual rainfall of about 257.2 mm.

According to the Department of the Environment of West Azarbaijan, the recorded population of white pelicans in the islands in 1973 and 1987 were 2,800 and 1,120 individuals, respectively. Their numbers have fallen to approximately 270 at the time of the study, but were still the largest colony in Iran. The aim of this study was to determine the frequency of *P. titan* infestations in white pelicans living in Urmia Lake.

### Materials and Methods

This study was carried out during 2004 and 2006 and the samples were collected from June to August in the Nine Island National Park.

The resident colony of white pelicans was visited six times during the study period, with 4 months intervals. Sixty-two juvenile pelicans were captured and their age was determined according to the criteria described by Beaver (1980). Naked young, pink in

color were classed as <1 week of age. Birds acquiring down and with gray mandibles and legs were 1-2 weeks of age. Birds with prominent down or with primary feathers erupted approximately 15 cm were 3-7 weeks of age (Beaver, 1980). A total of 62 pelican juveniles were sampled during the study period, and there were 8, 23 and 31 samples in the age groups of <1, 1-2 and 3-7 weeks, respectively.

A total of 1,637 lice were collected from the oral cavity and the body. The collected lice were preserved in a tube containing 70% ethanol and were mounted on slides after being cleared in lactophenol. Under a stereomicroscope the morphological structures and numbers of setae on the head, thorax and abdomen, the structures of mesosternal and metasternal plates, the genitalia and other morphological characteristics were examined and photos were prepared for diagnostic purposes. *P. titan* was discriminated from other species by using the criteria described previously by Price *et al.* (2003). These include a IV sternit with a short and well-developed ctenium on both sides, tibia II-III with two stout subapical setae ventrally, stigma with at least one setae, curving lateral plates, ventral terminalia with slender in female and in male genitalia being longer than 3 mm.

In this study, 62 white pelicans were sampled. In addition, 11 spoonbills (*Platalea leucorodia*), 43 Armenian gulls (*Larus armenicus*), seven slender-billed gulls (*Larus genei*), one Caspian tern (*Sterna caspia*) and 16 greater flamingoes (*Phoenicopterus ruber*) were examined.

## Results

The results showed that 59 of the 62 examined white pelicans were infested with lice. A total of 1,637 lice were collected from these infested birds, with infestations ranging from one to 112 lice per bird.

The oral cavities of the juvenile pelicans contained between one and more than 100 large (3-6 mm) biting lice (Figures 1, 2). These lice were primarily concentrated along the internal surface of the mandibles, and numerous lice were attached to the mucosa. Adult and juvenile lice were also attached at other sites in the pouch.

Lice were usually concentrated on the posterior region of the roof of the oral cavity, particularly around the opening of the eustachian tubes, at the angle of the upper and lower jaw, and along the internal surface of the lower mandibles (Figures 1, 2). No infestations were seen on other bird species.

The body of *P. titan* is dorso-ventrally flattened and its abdomen is much wider in females (Figure 3) than that in males (Figure 4), but less sclerotized. The head has an oval shape and is the broadest across the temples, but is comparably smaller than the overall body length. The palps have five segments, with the

last segment the longest and with small spines at the posterior tip. The antennae are localized in the antenna holes and do not protrude out of the head. It was found that the sternit IV has a ctenidium in both sides and that each tibia II-III have two stout subapical setae (Figure 5). Female terminalia have two slender lateral plates, while the male genitalia are longer than 3 mm. These findings are similar to those recorded by Price (1970). The ventral surface of the femur III usually have five ctenidae, but in some specimens it was observed to possess 6 ctenidae on the femur III (Figure 6). These findings, the numbers of setae on various parts of the body, the structures of prosternal (Figure 7a), mesosternal (Figure 7b), metasternal (Figure 7c) plates, female and male genitalia, and the numbers of the ctenidia on femur III were similar to those noted by Price (1970). Therefore, the lice were identified as *P. titan*.

Six of eight pelicans aged <1 week had clusters of immature and adult *P. titan* lice, usually in groups on various parts of the body and a few found in the mouth. Each cluster contained between one and 20 lice. Most lice were attached and apparently feeding, while a few were moving freely on the birds. Twenty-two of 23 birds 1-2 weeks old had parasites in the mouth. The throat pouches of 31 pelicans 3-7 weeks old were infested with *P. titan*. Fifteen birds were lightly infested (i.e. having <15 lice), whereas 16 birds were heavily infested with approximately 20 to 70 lice per bird. During the visiting period no bird carcasses were seen on the islands. The other sampled bird species were not infested with external parasites.

## Discussion

The lice living on pelicans are found in the genera *Pectinopygus*, *Colpocephalum* and *Piagetiella*. *Pectinopygus forficulatus*, *C. eucarenum* and *Piagetiella titan* have been found on white pelicans (Dalgleish, 2006). Séguy (1994) described only *P. titan* in the genus *Piagetiella* (Tetraphthalmus). He reported that this species was found in white pelicans, and also explained its features (Séguy, 1994). Samuel *et al.* (1981) reported ulcerative lesions on the body of naked birds approximately 1 week of age and in the throat pouches of older juveniles (2-7 weeks old) of infested pelicans to be due to *P. peralis*. They also reported <100 lice on lightly infested birds and 100-300 lice on heavily infested birds. This was the second report of severe ulcerative stomatitis in young pelicans due to *P. peralis* (Samuel *et al.*, 1982). Wobeser *et al.* (1974) reported heavily at high prevalence with *P. peralis* (Wobeser *et al.*, 1974). These studies showed that *P. peralis* occur on white pelicans on various areas of North America. Erosive stomatitis in white pelicans infested with *P. titan* has been reported from Konya province in Turkey (Dik, 2006). Normal populations of

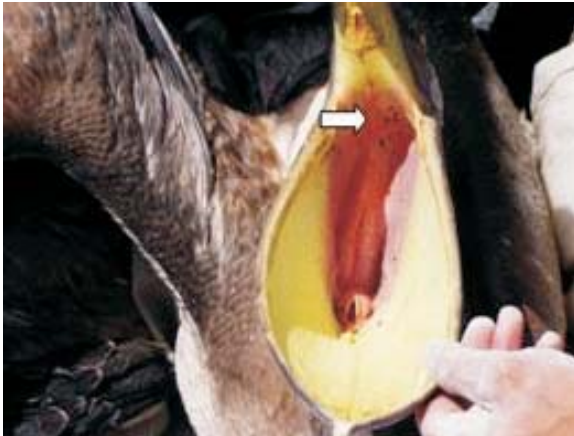

Figure 1: Lice are attached to the mucosa of the mouth.

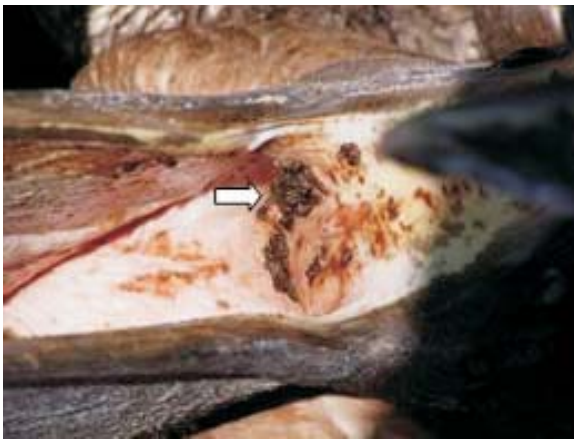

Figure 2: Concentration of lice along the internal surface of the mouth.




Figure 3: *P. titan*, female.



Figure 4: *P. titan*, male.

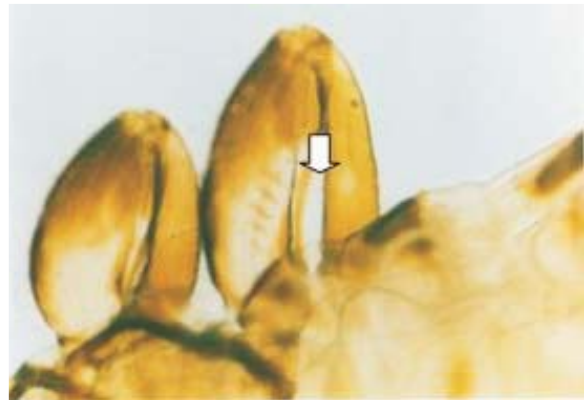


Figure 5: *P. titan*, two stout subapical setae on tibia II.

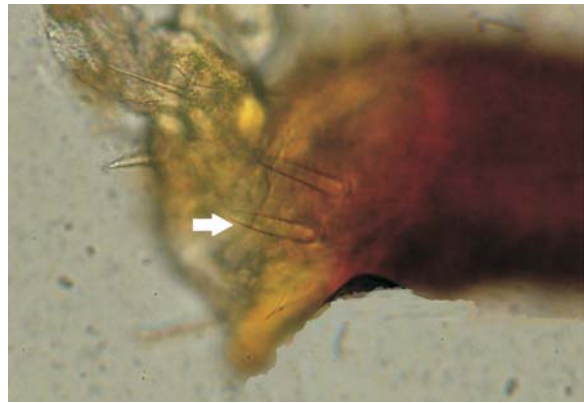


Figure 6: *P. titan*, ctenidia on femur III.

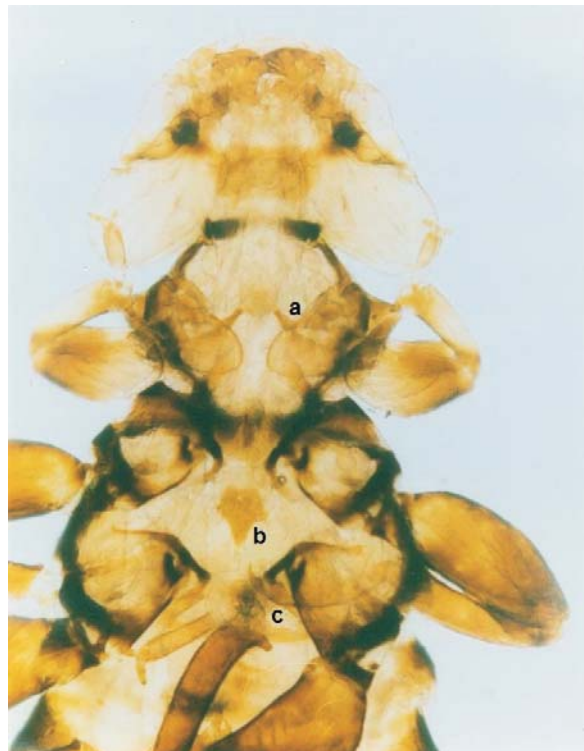

Figure 7: (a) prosternal, and (b) mesosternal plates on the sternum of *P. titan*.



biting lice apparently have little effect on their avian hosts, and populations of lice may be controlled by preening; however, heavy populations of lice may exert a serious effect on sick, captive or young birds. The close association of numbers of susceptible hosts in a colonial nesting area, and the fact that the adults of *P. titan* are located within the pouch, where they are protected from preening, might favor the development of large populations of this louse on young pelicans. This parasite can produce a severe hemorrhagic stomatitis as evidenced in white pelicans. This lesion might cause significant blood loss, and would provide a potential portal of entry for other pathogens. Wobeser *et al.* (1974) suggested that lice infestation may be a serious disease of young pelicans. However, Dik (2006) also reported erosive stomatitis in adult white pelicans (*Pelecanus onocrotalus*) to be caused by *P. titan*. We did not find any carcasses of juvenile pelicans in the study area, nor did we see any lesions on the birds as described by Wobeser *et al.* (1974), Samuel *et al.* (1981) and Dik (2006). This may be due to low infestations with lice in the studied white pelicans.

In conclusion, although chewing lice did occur on the body of their hosts, *P. titan* mainly lives in the oral cavity of white pelicans. Further studies of the epizootiology of *P. titan*, particularly as it relates to pelican productivity, are needed. This study reports *P. titan* for the first time in Iran.

### Acknowledgements

This study was financially supported by the provincial office of the Department of the Environment of West Azarbaijan, Iran.

### References

1. Beaver, R.D. (1980) Breeding behaviour of white pelicans in the Birch Mountains, northeastern Alberta. MSc. thesis, University of Alberta, Edmonton.
2. Dalglish, R.C. (2006) Birds and their associated chewing lice. Pelecanidae-Pelicans; <http://www.phthiraptera.org/Birds/Pelecanidae.html>.
3. Dik, B.; Uslu, U. (2006) The first recording of *Piagetiella titan* (Menoponidae: Mallophaga) on a White Pelicans (*Pelecanus onocrotalus*, Linnaeus) in Turkey. Turkey Parasitol Deregisi 30(2): 128-131.
4. Dik, B. (2006) Erosive stomatitis in a white pelican (*Pelecanus onocrotalus*) caused by *Piagetiella titan* (Mallophaga: Menoponidae). J. Vet. Med. Series B 53(3): 153-154.
5. Hellenthal, R.A.; Price, R.D. and Palma, R.L. (2004) Chewing lice of Belgium; <http://bchbd.naturalsciences.be/belgium/biodiversity/faunaflorahabitats/belchewinglice.pdf>.
6. Price, R.D. (1970) The *Piagetiella* (Menoponidae: Mallophaga) of the Pelicaniformes. The Canadian Entomology 102(4): 389-404.
7. Price, R.D.; Hellenthal, R.A.; Palma, R.L.; Johnson, K.P. and Clayton, D.H. (2003) The Chewing Lice: World Checklist and Biological Overview. Illinois Natural History Survey Special Publication.
8. Samuel, W.M.; Williams, E.S. and Blair, A.B. (1982) Infestation of *Piagetiella peralis* (Menoponidae: Mallophaga) on juvenile white pelicans (*Pelecanus onocrotalus*, Linnaeus). Can. J. Zoo. 60: 951-953.
9. Scott, D.A.; Ahmadi, A. (2006) An updated checklist of the birds of Iran. Podoces. 1(2): 1-16.
10. Séguy, E. (1994) Insects Ectoparasites (Mallophages, Anoploures, Siphonaptères). Faune de France 43, Paris.
11. Wobeser, G.G.; Johnson, R. and Acompanado, G. (1974) Stomatitis in a juvenile white pelican due to (*Pelecanus onocrotalus*) caused by *Piagetiella peralis* (Mallophaga: Menoponidae). J. Wild. Dis. 10:135-138.