

A comparative osteometric evaluation of some cranial indices of clinical significance in goats (*Capra hircus*) from the middle-belt regions of Nigeria

Samuel, O.M.^{1,2*}, Korzerzer, R.M.¹, Olopade, J.O.², Onwuka, S.K.²

¹Department of Veterinary Anatomy, University of Agriculture Makurdi, Benue state, Nigeria

²Department of Veterinary Anatomy, University of Ibadan, Ibadan, Oyo state, Nigeria

Key words:

skullmorphometry, goat breeds, craniofacial indices, phenotype

Correspondence

Samuel, O.M.

Department of Veterinary Anatomy,
University of Agriculture Makurdi,
Benue state, Nigeria

Tel: +234 8034654355

Fax: +234 8034654355

Email: walesamuel10@gmail.com

Received: 18 February 2013

Accepted: 15 May 2013

Abstract:

BACKGROUND: There is no comprehensive data on anatomical indices of Nigerian goats. **OBJECTIVES:** To show osteometric values of some cranial indices in Nigerian goats. **METHODS:** Sixty (60) goat skulls that were found around Makurdi, Kwande, Katsina-ala and the neighbouring Adamawa state of Nigeria, were studied by investigating the 30 craniometric values. **RESULTS:** The measured distance from the facial tuberosity to the infraorbital foramen was 2.33 ± 0.29 Cm and 1.80 ± 0.14 Cm for females and males, respectively. In addition, the distance from the medial canthus to the supraorbital foramen was 27 ± 0.31 Cm for females and 2.83 ± 0.24 Cm for males; from the lateral alveolar root to the mental foramen was 2.05 ± 0.07 Cm for females and 5.10 ± 7.28 Cm for males; and from the mandibular foramen to the ventral border of mandible was 5.90 ± 0.14 Cm for females and 5.48 ± 0.43 Cm for males. **CONCLUSIONS:** This breed of goat might be a different phenotype of the breeds that is available in Nigeria.

Introduction

The three major recognized breeds of goat in Nigeria are the West African Dwarf (WAD) (Olopade, 2006), the Red Sokoto (RS) also called the Maradi (Haummeser, 1975) goat, and the Sahel breed (SH) (Kwari, 2001). They are distributed within the country according to their known route of migrations either as the Trans Saharan through the desert or as the WAD that is known to inhabit the tropical rain forest from Liberian coast to Congo in the east (Coop, 1982). Epstein (1971) reported the Sahelian goat migrates to the West African sub region through Egypt, Nubia and the borders of Libya. These have been variously characterized by different authors over time. Some other breeds might not have been described as thoroughly and hence present differences which may pose some challenges to the clinicians with conflicting cranial data. The import-

ance of the spatial relationships of the organs and structures of the head exceeds the clinical purpose and extends to the knowledge of landmark surgical procedures (Hall, 2000) where the head serves for breed identification (Dyce et al., 2002). In making distinctions between breeds, their origin and the environmental conditions to which they may have been exposed to at some critical points of their development may have modifying effects on their phenotypic appearance (Gilbert, 2006; Sadler, 2004), making it imperative to establish standard morphologic descriptions for each established breed and its ecological type.

Previous works on the maxillofacial osteometry of goats include the works of Kene and Agbo (1998), Olopade and Onwuka (2007, 2008), and Olopade et al., (2009) on the three major breeds of goats in Nigeria, the work of Sarma (2006) on the Kagani goats in India, and the work of Uddin et al., (2009) on the Black Bengal goat in Bangladesh. However, no

information exists in the literature on the goats found in the middle belt regions of Nigeria.

This work investigates some cranial features of goats that are found in the middle belt regions of Nigeria and therefore seeks to establish the presence of this type of goat and the modifying influence of migrations and climate variations on their phenotypic appearance.

Materials and Methods

A total of sixty (60) skulls were used for this study. The animals were from the middle belt regions of Makurdi and KwandeKatsina-ala in the Benue state, and the surrounding state of Adamawa; the ages were estimated based on the dental eruptions and wears (Habel, 1975). The heads were obtained after restraining and quick decapitation. They were frozen immediately after.

The goat heads were processed individually according to the skull maceration process as described by Olopade and Onwuka (2008) and Onar et al., (1999).

The measured variables and their acronyms: 1. Distance from the facial tuberosity to the infraorbital foramen (FT-If). The highest point on the facial tuberosity to the midpoint of the infraorbital foramen

2. Distance from the medial canthus to the supraorbital foramen (MC- Sf). It was measured by caudal diagonal line from the medial canthus along the orbit to the midpoint of the supraorbital foramen on the frontal bone.

3. Supraorbital foramen to the frontal eminence (SF-Fe). Vertical line from the midpoint of the supraorbital foramen to the frontal eminence.

4. Infraorbital foramen to alveolar root of the second premolar (IF-AP₂). Vertical line from the infraorbital foramen to the cranial limit of the alveolar root of the 2nd premolar (P₂).

5. Skull length (SK-L). From the rostral border of the incisive bone to the occipital crest.

6. Skull height (SK-H). From the ventral border of the mastoid process to the frontal eminence.

7. Skull breadth (SK-B). Distance between the two orbital bony rims.

8. Distance from the lateral alveolar root to the mental foramen (LA-M). Horizontal line from the lateral alveolar root of the 4th incisor (I₄) to the

midpoint of mental foramen.

9. Maximum circumference of the right and left orbital rims (MCrO and MCIO).

10. Mental foramen to the alveolar root of the first premolar (MF-AP₁). Horizontal line from the midpoint of the mental foramen to the cranial limit of the lateral alveolar root of the 1st premolar (P₁).

11. Mental foramen to the ventral border of the mandible (MF-Vb). Vertical line from the midpoint of the mental foramen to the ventral border.

12. Mental foramen to the caudal border of mandible (MF-Cb).

13. Mandibular symphyseal length (MsL). From the lateral alveolar root of the 1st incisor (I₁) rostral limit of symphysis to the caudal limit of symphysis on the ventral aspect.

14. Mandibular symphyseal breadth (MsB). Distance measured across the lateral edge of the left 4th incisor to the lateral edge of the right incisor no. 4 measured medially.

15. Length of diastemal gap (DGL). From the lateral alveolar root of the 4th incisor to the cranial limit of the 1st premolar on the body line.

16. Interdiastemal distance (IDd). From the lateral alveolar root of the left 1st premolar (P₁) to the lateral alveolar root of the 2nd right premolar (P₂) on the medial side.

17. Inter-mental foramina distance (IMFd). Midpoint of the left mental foramen to the midpoint of the right mental foramen.

18. Mandibular thickness (Mtk). Width of the mandible at the 1st molar (M₁), second molar (M₂), and third molar (M₃).

19. Mandibular length (MDL). From the lateral alveolar root of the first Incisor (I₁) to the most caudal border of the mandible.

20. Mandibular foramen to ventral border of the mandible (MF-Vb). Vertical line from the ventral limit of mandibular foramen to the ventral border of mandible.

21. Mandibular foramen to caudal border of mandible (MF-Cb). Horizontal line from the vertical aspect of mandibular foramen to the caudal border of mandible.

22. Length of mandibular condyle (McL). Medial to lateral measurement of mandibular condyle.

23. Length of coronoid process (CRL). From the dorsal limit of the coronoid process to the base of

mandibular notch.

24. Mandibular notch to ventral border of mandible (Mn-Vb). From the ventral aspect of mandibular notch to the ventral border of mandible.

25. Height of mandible (HM). From the dorsal limit of coronoid process to the ventral border of mandible.

26. Height of mandibular body (HMB). From the alveolar root of M1 to the ventral border of mandible.

27. Inter mandibular distance (IMD). Distance between the two mandibles.

(1) At their most caudal borders

(2) At M₃

(3) At M₁

28. Foramen magnum length (FML). Rostral to caudal measurement of the foramen magnum.

29. Foramen magnum width (FMW). Maximum width of the foramen magnum.

30. Foramen magnum height (FMH). Maximum height of the foramen magnum.

Skull data collection: The skulls osteometric variables were obtained using appropriate metric instruments; the procedure and the landmarks for each variable are described below. Some of them are depicted in Figures 1-4. The results were subjected to statistical analysis using the Graph pad prism 4 statistical software.

Results

The mean distance from the facial tuberosity to the infraorbital foramen was 2.07 ± 0.22 Cm in the present goats compared to 1.60 ± 0.01 Cm for the West African Dwarf (WAD) breed, 1.77 ± 0.11 Cm for the Sahel breed (SH), 1.82 ± 1.20 Cm for the Red Sokoto (RS), and 1.85 ± 0.14 Cm for the Black Bengal goat (Olopade and Onwuka, 2007, Shawuluet al., 2008, Olopade et al., 2009 and Uddin et al., 2009). The distance from the medial canthus to the supra orbital foramen in our study was 4.47 ± 0.40 Cm while the distance from the lateral alveolar root to the mental foramen was 3.58 ± 3.68 Cm compared to 1.84 ± 0.76 Cm in the WAD, 1.96 ± 0.02 Cm in the SH, and 1.60 ± 0.34 Cm for the RS for the same landmark. These various cranial indices become important in the regional anaesthesia of the head for the rostral dental procedures of the upper jaw and the

desensitization of the cornual process for dehorning (Hall, 2000). The mean distance from the infraorbital foramen to the alveolar root of P2 in the species of this study was 2.17 ± 0.47 Cm which is longer those taken from the south eastern and south western parts of Nigeria ($1.3-1.6 \pm 0.21$ Cm) (Olopade and Onwuka, 2005b), and from the Black Bengal (1.75 ± 0.19 Cm) (Uddin et al., 2009). However, the observed dimensions in the present study are well correlated to the head to body lengths ratio of the goats as reported for the wild boar (*SusscrufuLeucomyses*) (Abe, 1989). The middle belt region falls within 6°N and 12°N of the equator. The migrating animals from east Africa pass through the northern parts of the Cameroons and enter Nigeria. The vegetation cover in these areas is known to be guinea savannah (Happold, 1989), especially in periods in which the rains begin to dwindle (November-March) but the daily temperature remains between 20°C to 26°C. The migration route taken by the nomadic pastoralists and their cattle, and the Sahelian goats, is through Niger Republic and Sudan. As they make their way from Libya (Ngereet al., 1984) through the Sahel and

Table 1. Measurements of skull parameters based on sex.

Parameter (Cm)	Male (Mean ± SD)	Female (Mean ± SD)	
1	FT-If	1.80 ± 0.14	2.33 ± 0.29
2	MC-Sf	2.83 ± 0.24	3.27 ± 0.31
3	SF-Fe	2.65 ± 0.17	2.53 ± 0.15
4	IF-AP2	2.17 ± 0.35	1.63 ± 0.32
5	SK-L	15.23 ± 1.44	17.90 ± 1.45
6	SK-H	8.63 ± 1.15	9.07 ± 1.07
7	SK-B	7.17 ± 0.25	8.83 ± 1.15
8	LA-M	5.10 ± 7.28	2.05 ± 0.07
9	McrO	12.22 ± 4.09	14.58 ± 2.89
10	MTF-ARP1	1.40 ± 0.12	1.85 ± 0.07
11	MTF-Vb	0.78 ± 0.05	0.95 ± 0.07
12	MTF-Cb	9.98 ± 0.72	12.05 ± 0.49
13	MsL	1.85 ± 0.13	2.25 ± 0.35
14	MDsB	1.53 ± 0.29	2.15 ± 0.49
15	DMGL	2.95 ± 0.29	3.55 ± 0.21
16	IDMd	1.60 ± 0.24	1.95 ± 0.07
17	IMFd	1.43 ± 0.30	1.60 ± 0.42
18	MDtkM1	1.13 ± 0.06	1.20 ± 0.00
-	MDL	11.88 ± 0.79	14.35 ± 0.78
20	MF-Vb	3.14 ± 0.37	3.20 ± 0.71
21	MF-Cb	1.98 ± 0.33	2.10 ± 0.57
22	McL	1.63 ± 0.13	1.80 ± 0.14
23	CRL	2.73 ± 0.40	3.05 ± 0.35
24	Mn-Vb	5.48 ± 0.43	5.90 ± 0.14
25	HM	7.98 ± 0.28	9.05 ± 0.64
26	HMB	2.30 ± 0.20	2.55 ± 0.35
27	IMDdM2	3.70 ± 0.16	4.40 ± 0.85
28	FML	1.85 ± 0.06	1.97 ± 0.15
29	FMW	1.88 ± 0.10	1.93 ± 0.12
30	FMH	1.73 ± 0.10	1.80 ± 0.00

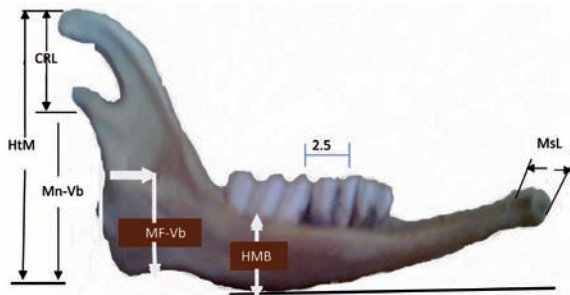


Figure 1a. Medial view of the left mandible of the goat from the middle belt region of Nigeria showing the following measurements: Mandibular foramen to the ventral border of the mandible (MF-Vb), Height of the mandible at molar 1 (HMB), Mandibular symphyseal length (MsL), Mandibular notch to the ventral border of the mandible (Mn-Vb), and the Coronoid process length (CRL).

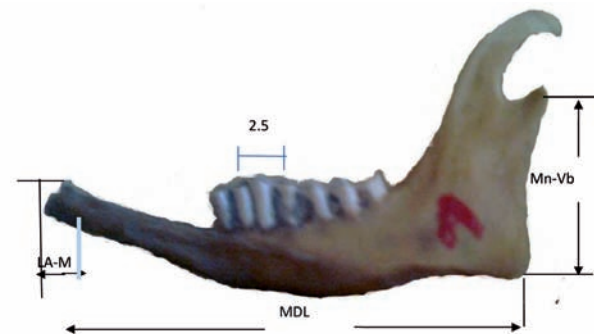


Figure 1b. Lateral view of the left mandible of the goat from the middle belt showing the measurements of mandibular length (MDL) and mandibular notch to the ventral border (Mn-Vb).

Sudan savannahs, these animals are sold to the neighbouring states of Borno, Sokoto, and Kano. Animals that are taken through this route, compared to those taken through the northern Cameroons, have limited proportions of water and pasture coupled with more prolonged harsh weather periods per year. The exposure of the pregnant dams and the young in their various stages of development to this climatic stress is hypothesised to have profound effects on their developmental potentialities (Gilbert, 2006).

The mandibular thickness in all the three breeds at Molar 1-3 revealed that the mandible had the least thickness at molar 1, which is 1.13 Cm in the breed under consideration, 1.05 Cm in the WAD, 1.03 Cm in RS, and 1.13 Cm in SH. This is the portion of the mandible that is most accessible during the oral examination and other clinical procedures (Habel, 1975). This study suggests that caution should be taken during these procedures because of the relative weakness of the mandible at molar 1 (Olopade and Onwuka, 2007).

Moreover, the foramen magnum height and width in both the RS and SH goats have similar values of 1.79 Cm and 1.85 Cm, respectively. However, in the WAD, they are 1.68 Cm and 1.60 Cm, respectively (Olopade, 2006). The foramen magnum height and width of the subject of this study was 1.76 Cm and 1.91 Cm, respectively, suggesting a divergence in morphology from the other three breeds (Simoenset

al., 1984). It should be noted that only the foramen magnum width showed a significant variation at $p < 0.05$ in this goat.

The effects of severe climatic conditions with its resultant shortage of water and the scarcity of food coupled with the long distance of travel is speculated to contribute to the relatively smaller cranial values being reported in goats of the same type but from different regions of Nigeria (Newth, 1978; Patten, 1974). These values are significantly higher in the subjects being investigated than the others reported in this work. Despite the Sahel breed of goat travelling through Tchad Republic and Northern Cameroons spill into Adamawa (with better access to water in the Tchad basins) and the Benue river, the Benue state seems to be a rallying point where goats from all the mentioned routes are sold. The influence of the culture is to an extent that the migration of the nomads are targeted to meet the sale of the animals for the religious and other festive periods which are more often in the later and drier parts of the year.

Proper classification of these goats becomes imperative where the standardization of the breed lines and the anticipated variable limits for different indices in different ecotypes/breeds needs to be specified. The interplay of the altitude, vegetation, and rainfall which is bimodal in Nigeria's vegetation zones are major contributory factors that determines the climate in these areas during which migrations occur (Happold, 1989). The Jos area has a higher altitude and therefore enjoys a higher and longer rainy periods in a year with a concomitant longer period of

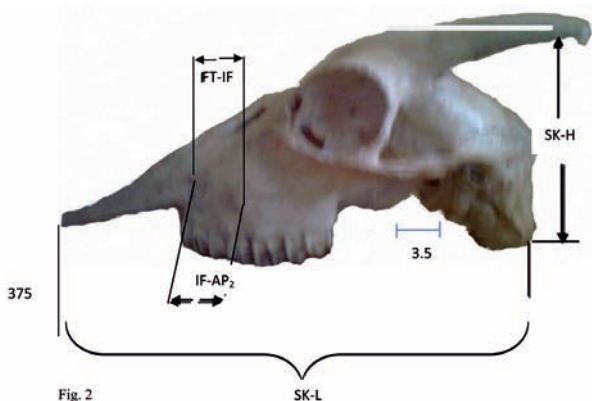


Fig. 2 SK-L

Figure 2. Lateral view of the skull of the typical middle belt goat without mandible showing measurements of the skull length (SK-L), height (SK-H), facial tuberosity to the infraprbital foramen (FT-IF), and infraorbital foramen to the alveolar margin of premolar 2.

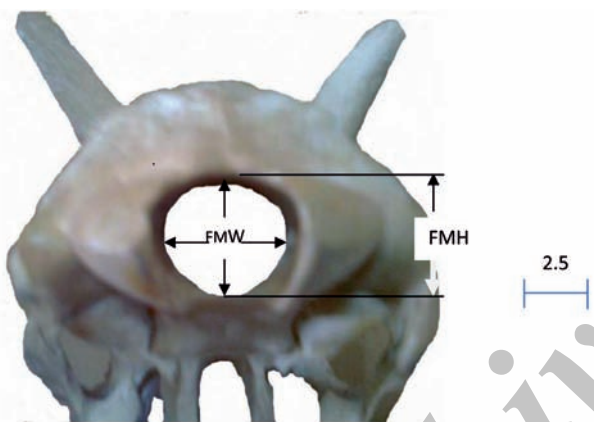


Figure 4. Caudo-rostral view of the skull of the typical middle-belt zone goat showing the foramen magnum measurements-Foramen magnum width (FMW) and Foramen magnum height (FMH).

access to good quality food and quantity of water as well as lower ambient temperatures during their breeding, gestations, and nursing seasons. These characteristics represent the influence of environment on the heredity and is thought to enhance the ontogenic variations in the phenotypic traits (Dunlop, 1963). Different ecotypes may therefore be obtained (Kwari, 2001; Otesile and Obasaju, 1982) which needs to be researched and classified.

It is therefore speculated that the present phenotypic type of the goat being studied might be one of the minor breeds or an ecotype of goats that is present in Nigeria from which there is no literary information regarding their population, size, and other peculiarities like kidding potentials (Haummeser,

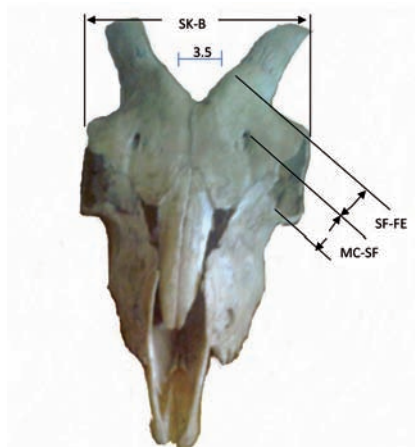


Figure 3. Rostro-frontal view of the skull of a typical middle belt goat showing the measurements of the skull breadth (SK-B), from the medial canthus to the supraorbital foramen (MC-SF), and from the supraorbital foramen to the facial eminence (SF-FE).

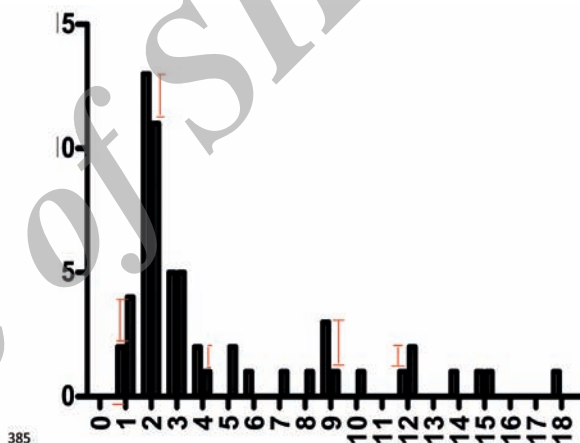


Figure 5. Histogram of the frequency distribution of parameters measured between the sexes (1-18), Black columns for females and the shaded white ones for males showing error bars.

1975) and milk yield.

Acknowledgements

The authors of this investigation would like to thank the following individuals for different roles they played without hesitation when asked at short notices, Dr.I. Nwogwu from the department of Veterinary Anatomy, University of Nigeria, Nssuka; Mr. Andrew Odammah (O.C) the senior technologist in charge of the gross Anatomy laboratory who came with us to the goat market stalls as often as called upon and my personal custodian of the skulls specimen library.

References

- Olopade J, O. (2006) Morphometric analysis of the skull of three breeds of goats in Nigeria. Ph.D Thesis department of Veterinary Anatomy, faculty of Veterinary medicine, Uni Ibadan Nigeria.
- Haumesser, J.B. (1975) Quelques aspects de le reproduction chez la cherre Rousse de maradi. Comparison avec d'autres races trop: Calesou subtropicales. Rev Elevmed Vet Pays Trop. 28: 225-234.
- Kwari, H.D. (2001) A Morphological study of the ecotypes of Sahel goats in Borno state with special reference to sexual dimorphism. Ph.d. thesis .Department of Veterinary Anatomy, Faculty of Veterinary Medicine University of Maiduguri, Maiduguri , Nigeria.
- Coop, I.E. (1982) Sheep and goat production Elsevier publishing company. 3: 45-49.
- Epstein, H. (1971) The origin of domestic animals of Africa. Africana publishing. Corp. New York, London , Munich Vol II. p.193-309.
- Hall, L.W., Clarke, K.W., Trim, C.M. (2000) Wrights Veterinary Anaesthesia and Analgesia (18th ed.). ELBS, BailliereTindall press.
- Hall, L.W., Clarke, K.W., Trim, C.M. (2000) Wrights Veterinary Anaesthesia and Analgesia (18th ed.). ELBS and BailliereTindall
- Gilbert, F., Elliot, S. (2006) Developmental biology, (8th ed.). sunderland, M.A Sinauer Sunderland press.
- Sadler, T.W. (2004) Langmans Medical embryology (8th ed.) Williams and Wilkins Lippincott.
- Kene, R.O.C., Agbo, C.N. (1998) Dental abnormalities of three breeds of Nigerian Goats. Trop Vet. 16: 15-22.
- Olopade, J.O., Onwuka, S.K. (2007) Osteometric study of the skull of Red Sokoto (maradi) goats (Capra hircus) Implications for anaesthesia of the head (Int. J. Morphol 25, 407-410).
- Olopade, J.O., Onwuka, S.K. (2008) A cranio-facial analysis of the skull of the red Sokoto (maradi) goat (Capra hircus) Eur J Ant. 12: 57-62.
- Onar, V., Mutus, R., Kavechioglu, K.O. (1999) Morphometric analysis of the foramen magnum in German shepherd Dogs, Ann Anat. 179: 563-568.
- Olopade, J.O., Samuel, O.M., Antia, R.E., Onwuka, S.K. (2009) Maxillofacial and mandibular phenotypes in the skulls of Red Sokoto and Sahel goats in Nigeria- The role of dental abnormalities. Nigerian Veterinary Journal.
- Sarma, K. (2006) Morphological and craniometrical studies of the skull of Kagani goats (Capra hircus) from Jammu region int. J Morphol. 24: 449-445.
- Uddin, M.M., Ahmed, S.S.U., Islam, K.N., Islam, M.M. (2009) Clinical Anatomy of the head region of the Black Bengal goat in Bangladesh. Int J Morphol. 27:1269-1273.
- Habel, J.A. (1975) Applied Veterinary Anatomy corrected reprinting, xvii, Edwards brothers Michigan, USA.
- Shawulu, J.C., Kwari, H.D., Olopade, J.O., Onwuka, S.K. (2008) Cranio-facial studies of different ecotypes of the Sahel Goat. Trop Vet. 26: 9-14.
- Olopade and Onwuka S.K., (2005b) Morphometric study of the skull of the West African Dwarf Goat in the South West Nigeria. Nigerian Vet J. 26: 18-21.
- Abe, M. (1989) Fundamental studies of animals of prehistoric Japan (3) Estimation of the growth stage and body size of the wild boar (Sus scrofoLeucomyses) by observation and measurement of crania. Anthropol Rep. 48: 27-63.
- Happold, D.C.D. (1989) Mammals of Nigeria, clarandon press oxford, UK.
- Ngere, L.O., Adu, I.F., Okubanjo, I.O. (1984) The Indegenious goats of Nigeria In: Animal Genetic Resources Information. UNEP/FAO, Rome. 3: 1-9.
- Simoens, R., Poles, R., Lauwers, H. (1994) Morphometric analysis of foramen magnum in Pekingese dogs. Am J Vet Res. 55: 33-9.
- Newth, R., David, R. (1978) Animal growth and Development Edward Arnolds publishers, Bedford; 18.
- Patten, M., Bradley, J. (1974) Emryology of the pig (3rd ed.). McGraw Hill Books London. p. 66-8.
- Dunlop, A.A. (1963) Interraction between heredity and environment in the Australian Merion strain X; Location- interaction in body traits and reproduction performance Australian J Agric Res. 14: 690-703.
- Otesile, E.B., Obasaju, M.F. (1982) Relationship between age rostral teeth development in Nigerian Goats. In: proceedings of the 3rd international conference in Goat production and disease University of Arizona. Tucson, USA.

ارزیابی مقایسه‌ای شاخص‌های استخوانی جمجمه درد بزهای منطقه میانی نیجریه

ساموئل* کورزرز اولویاد اونوکا

(۱) گروه آناتومی دامپزشکی، دانشگاه کشاورزی ماکوردی، بنو، نیجریه

(۲) گروه آناتومی دامپزشکی، دانشگاه ایبادان، اویو، نیجریه

(دریافت مقاله: ۳۰ بهمن ماه ۱۳۹۱، پذیرش نهایی: ۲۵ اردیبهشت ماه ۱۳۹۲)

چکیده

زمینه مطالعه: اطلاعات جامعی در خصوص شاخص‌های آناتومیکی بزهای نیجریه ای وجود ندارد. **هدف:** تعیین شاخص‌های استخوان کرانیال بزهای نیجریه می‌باشد. **روش کار:** ۶۰ استخوان جمجمه از بزهای مناطق Katsina-ala, Kwande, Makurdi نیجریه جمع آوری و شاخص‌های مرتبط با استخوان جمجمه در آنها مطالعه گردید. **نتایج:** فاصله برآمدگی صورت تا حفره فوق چشمی $2/33 \pm 0/29$ Cm در جنس ماده و $1/80 \pm 0/14$ Cm در جنس نر تعیین گردید. بعلاوه فاصله از Medial canthus تا حفره فوق چشمی معادل $27 \pm 0/31$ Cm در جنس ماده و $2/83 \pm 0/24$ Cm در جنس نر تعیین گردید. فاصله lateral alveolar root تا حفره Mental معادل $2/05 \pm 0/07$ Cm در جنس ماده و $5/10 \pm 0/14$ Cm در جنس نر تعیین گردید. فاصله حفره Mandibular تا مرز شکمی Mandible معادل $5/90 \pm 0/14$ Cm در جنس ماده و $5/48 \pm 0/43$ Cm در جنس نر اندازه گیری گردید. نتیجه‌گیری نهایی: این گونه بز ممکن است فنوتیپ متفاوتی نسبت به سایر گونه‌های موجود در نیجریه داشته باشد.

واژه‌های کلیدی: جمجمه، بز، مرفولوژی، فنوتیپ

*نویسنده مسؤول: تلفن: +۲۳۴ ۸۰۳۴۶۵۴۳۵۵؛ نمابر: +۲۳۴ ۸۰۳۴۶۵۴۳۵۵؛ Email: walesamuel10@gmail.com