

An outbreak of a mixed infection due to fungal (*Trichophyton mentagrophytes* var. *mentagrophytes*) and parasitic (*Geckobiella donnae*) agents on green iguanas

Sharifzadeh, A.¹, Khosravi, A.R.¹, Shokri, H.^{2*}, Balal, A.¹, Arabkhazaeli, F.³

¹Mycology Research Center, Faculty of Veterinary Medicine, University of Tehran, Tehran, Iran

²Department of Pathobiology, Faculty of Veterinary Medicine, Amol University of Special Modern Technologies, Amol, Iran

³Department of Parasitology, Faculty of Veterinary Medicine, University of Tehran, Tehran, Iran

Key words:

dermal co-infection, *Geckobiella donnae*, green iguana, *Trichophyton mentagrophytes* var. *mentagrophytes*

Correspondence

Shokri, H.

Department of Pathobiology,
Faculty of Veterinary Medicine,
Amol University of Special
Modern Technologies, Amol,
Iran

Tel: +98(11) 44271057

Fax: +98(11) 44271054

Email: hshokri@ausmt.ac.ir

Received: 23 December 2015

Accepted: 15 March 2016

Introduction

Many different mycotic diseases have been reported in captive reptiles. Etiological agents of cutaneous and systemic infections in reptiles are attributed to a wide variety of filamentous fungi and yeasts, although they have often been inadequately identified (Pare et al., 2006). As a rule, fungal infection of reptiles has been regarded as opportunistic, caused by normally saprophytic organisms that invade living tissue strictly under favorable circumstances for the pathogen. Predisposing factors such as suboptimal cage temperatures and inappropriate environmental conditions are of-

Abstract:

BACKGROUND: Green iguana (*Iguana iguana*) is one of the newly imported exotic pets which has been observed with increasing regularity in veterinary clinics in Iran. Despite their popularity, information about their diseases is scarce. **OBJECTIVES:** The aim of this study was to assess the pathogenic agents in green iguanas with skin disorders. **METHODS:** The animals were brought to Small Animal Hospital, Faculty of Veterinary Medicine, Tehran, Iran, with chronic pruritic dermatitis, scabs, loss of spines and deep ulcerative dermatitis located over the body. During physical exam, deposits of dry seborrhea were taken and processed for diagnosis. The clinical specimens were cultured on sabouraud dextrose agar containing chloramphenicol and cycloheximide and mycosel agar. **RESULTS:** Microscopic examination revealed fungal elements as *Trichophyton mentagrophytes* var. *mentagrophytes* and psoroptid mites as *Geckobiella donnae*. **CONCLUSIONS:** This was the first report of the presence of fungal and parasitic agents as the etiological agents of dermatological disorders in green iguanas.

ten involved (Kostka et al., 1997, Schumacher, 2003).

Dermatophytosis is caused by fungi in the genera *Microsporum*, *Trichophyton* and *Epidermophyton*. There are three ecological groups of dermatophytes: anthropophilic (mostly associated with humans), zoophilic (associated with animals) and geophilic (found in the soil) (Nweze, 2010). Dermatophytes are also reportedly cited among the most frequent cause of dermatological problems in domestic animals (Cabañes, 2000). Human beings are usually infected from animals mostly through direct contact or via fungus-bearing hair and scales from infected animals. In the last few

years, the interest in having animals as pets has increased dramatically in many countries with an increasing number of such pets co-habiting and feeding with their owners and members of their households in the majority of cases (Nweze, 2011).

Parasites, especially mites, are well-known causes of dermatological problems in reptiles. Parasitic mites are chiefly ectoparasites of the skin, mucous membranes, or feathers, but a few are endoparasites. Mites are distributed worldwide on both plants and animals and cause direct injury as well as the spread of disease (Scott et al., 2001). Mite families of importance to lizards include: Trombiculidae, Macronyssidae and Pterygosomatidae (Peterson, 2006).

Skin diseases represent one of the most important reasons for veterinary intervention in reptile medicine. Whereas most skin diseases in commonly kept reptile species are primarily caused by inappropriate husbandry and feeding, few of the infectious agents that primarily cause dermatitis are known. Green iguana (*Iguana iguana*) are probably the most popular lizards kept as pets. Readily available, they are also fairly inexpensive, especially when acquired at a small size (50-100 grams). In recent years, although increasing attention has been paid to keeping green iguanas as pet animals in Iran and allowing a close relationship with humans in indoor areas, little is known about the zoonotic hazards of this animal. In this manuscript, we will focus on fungal (*Trichophyton mentagrophytes* var. *mentagrophytes*) and parasitic (*Geckobiella donnae*) agents involved in severe and persistent dermatological problems in a green iguanas.

Materials and Methods

Green iguanas (9 months) were presented with a history of skin darkness lesions, thickening, scaling and crusting on the neck, tail and distal aspects of the legs (Fig. 1). Due to the

scaling nature of the lesions, it was suspected to have dermatophyte invasion. Clinical specimens were taken from involved cutaneous surface by scraping epidermal scales with sterile surgical blade. Direct microscopic examination was done using 10% potassium hydroxide (KOH) /dimethylsulfoxide (DMSO). The clinical specimens were cultured on sabouraud dextrose agar (Merck Co., Darmstadt, Germany) containing chloramphenicol (0.005%) and cyclohexamide (0.04%), mycosel agar and on dermatophyt test media (Merck Co., Darmstadt, Germany). The cultures were incubated at 30°C for 3 weeks.

Results

Direct microscopy showed hyphae and hyaline-septated arthroconidia (Fig. 2a) with lots of red mites in epidermal scales, suggesting mixed dermatophyte-mite co-infection. After 8 days, the colonies of *T. mentagrophytes* var. *mentagrophytes* had changed to white to cream in color, granular surface and with central folding or downy areas (Fig. 2b). Reverse pigmentation was usually a yellow to brown color. Microconidia were hyaline, single-celled, and smooth-walled and were predominantly spherical to subspherical in shape. Varying numbers of coil and spiral hyphae along with smooth, thin-walled, clavate shaped, multicelled macroconidia were also observed in lactophenol cotton blue staining. The identification of this dermatophyte was confirmed by studying the macroscopic and microscopic characteristics as well as positive hydrolysis of urea within five days and in vitro hair perforation test within 12 days and development of granular appearance on the 1% peptone agar (Merck Co., Darmstadt, Germany).

Mite identified as *Geckobiella donnae* had oligotrichous idiosoma. Dorsal idiosomal setae c3 was present. The prodorsal shield resembled an inverted pentagon with anterior sides almost parallel. There were two pairs of



Figure 1. Green iguana with thickening of dark discoloration of the skin surrounding necrosis on the right ventral abdominal region.

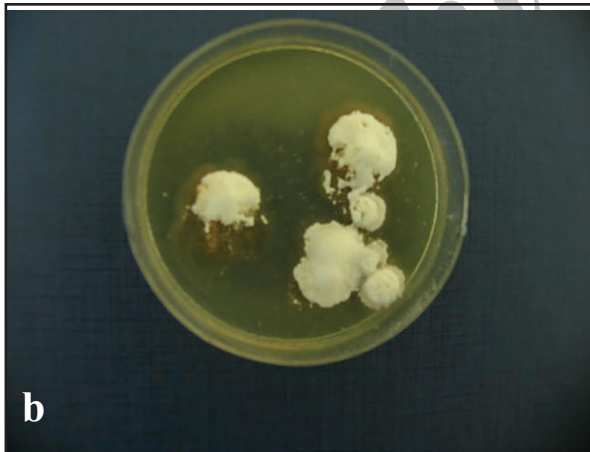



Figure 2. (a) Microscopic appearance of the isolate showing hyphae bearing arthroconidia (b) Culture of scales on Sabouraud at 30 °C.

short setae on the shield (Fig. 3a). Coxal group III-IV were considerably apart from the coxal group I-II and stout tarsi I-IV had blunt endings. Base of the capitulum was simple and one pair of ventral, slender and smooth setae

was visible behind the palps. Palps were slender and about two times longer than the length of base of gnathosoma (Fig. 3b). Seta d on femur I was branched.

Discussion

Dermatophytosis is a well-recognised zoonotic infection of keratinized structures such as nails, hair shafts, claws and stratum corneum by dermatophytes. Zoophilic dermatophytes, in particular *Trichophyton mentagrophytes* var. *mentagrophytes*, are the prominent aetiological agents (Mancianti et al., 2002). The identification of dermatophyte species is essential for appropriate diagnosis and treatment in veterinary dermatology. Routine identification of dermatophytes relies on the use of appropriate culture growth media and the examination of gross colony and microscopic morphology. Results of this study describe the first report of the occurrence of a mixed infection with *Trichophyton mentagrophytes* var. *mentagrophytes* and *Geckobiella donnae* in green iguanas in Tehran, Iran. To our knowledge this is the first report of *Trichophyton mentagrophytes* var. *mentagrophytes* being implicated in a disseminated cutaneous infection in iguanas. The isolation of the fungi in pure culture confirmed this fungus as the etiologic agent of the infections in this reptile species. In a previous study by Khosravi et al. (2012), all green iguanas were suffering from *T. mentagrophytes* var. *interdigitale* infection. Chung et al. (2014) reported a 1-year-old female green iguana presented with a nodular, darkly discolored skin lesion surrounded by necrosis in the right ventral abdominal region suffering from *Microsporium canis*. Totally, cutaneous fungal infections in iguanas are attributed to a wide variety of filamentous fungi and yeasts, which often have been inadequately identified (Pare et al., 2006). Although rodents and soil were known to harbour different *T. mentagrophytes* varieties, it was possible that husbandry was

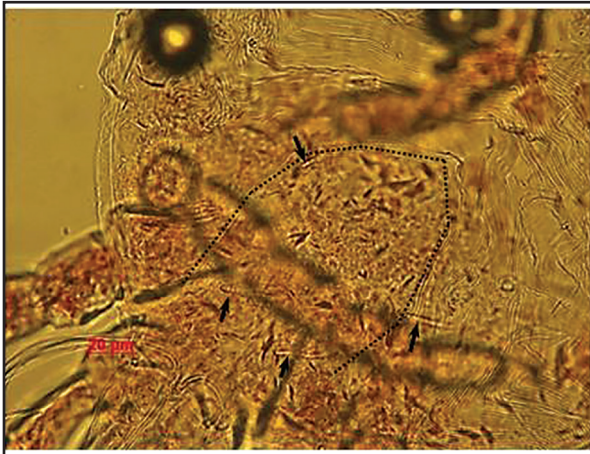

Figure 3a. Dorsal shield of *Geckobiella donnae* shaped as an inverted pentagon with anterior sides almost parallel (outlined) and 2 pairs of short setae (arrows) (x400).




Figure 3b. Gnathosoma of *Geckobiella donnae*. Note the slender and long with a pair of smooth setae visible behind them (arrows) (x400).

suboptimal, and this would be a predisposing factor contributing to the onset of infection.

Pterygosomatidae, the only family in the superfamily Pterygosomatoidea, comprises various species of bright red mites found primarily on lizards, tortoises, and arthropods all over the world. The described genera includes *Cyclurobia*, *Geckobia*, *Geckobiella*, *Hirstiella*, *Ixodiderma*, *Pterygosoma*, *Scaphothrix*, *Tetttisistlana* and *Zonurobia*, which are mostly external parasites of lizards. They attach under scales, between the toes, or in areas known as mite pockets and often are confused with chiggers. They feed on body fluids of their host and cause benign to severe pathological disorders such as anemia and intense skin irritation. Apparently, some species are vectors of protozoan diseases of lizards (Krantz and Walter, 2009). *Geckobiella* spp. (as well as other Pterygosomatids) is scansorial and not usually found in mite-pockets. These mites live under the imbricate scales of their hosts (Delfino et al., 2011). All instars of this genus are parasitic on the Iguanidae (Paredes-León et al., 2012). Parasitism by *Geckobiella* may cause problems during the molting process of their hosts and some species are potential vectors of *Plasmodium* and *Haemogregarina* (Murgas et al., 2013). The mites tend to localize around the eyes, under the chin, in the dewlap, axillary

and inguinal areas, on limbs in folds of skin associated with joints, and on the tail. They can cause irritation to the lizards, resulting in a pruritic response (Hoppmann and Barron, 2007). Previous studies in Turkey (Gazyacsi et al., 2011) and Greece (Farmaki et al., 2013) reported a number of red mites, erythema, darkness, and itching on the skin of green iguanas and *Hirstiella* spp. was diagnosed after microscopic examination. In the iguanas in the present case, mites were generally picked up from periorcular, dorsal and tail sites and skin examination showed erythema, darkness, and pruritis. This was the first report of *Geckobiella donnae* on a green iguanas in Iran and the source of the infestation in the present iguana case was not known. In summary, this case suggests that fungal and parasitic co-infection with multiple organ involvement should be included as a possible etiology in the differential diagnosis of cutaneous infections in reptiles. Moreover, it also demonstrates diagnostic techniques available to aid in identification of fungal and parasitic agents in reptiles.

Acknowledgments

This study was funded by Research Council of Faculty of Veterinary Medicine, University of Tehran, Tehran, Iran.

References

- Cabanes, F.J. (2000) Animal dermatophytosis. Recent advances. Rev Ibero Micol. 17: S8-12.
- Chung, T.H., Kim, E.J., Choi, U.S.D. (2014) Multiorgan fungal infection caused by *Microsporum canis* in a green iguana (*Iguana iguana*). J Zoo Wildl Med. 45: 393-396.
- Delfino, M.M.S., Ribeiro, S.C., Furtado, I.P., Anjos, L.A., Almeida, W.O. (2011) Pterygosomatidae and Trombiculidae mites infesting *Tropidurus hispidus* (Spix, 1825) (Tropiduridae) lizards in northeastern Brazil. Braz J Biol. 71: 549-555.
- Farmaki, R., Simou, C., Papadopoulos, E., Koutinas, A.F., Saridomichelakis, M.N. (2013) Effectiveness of a single application of 0.25% fipronil solution for the treatment of hirsitiosis in captive green iguanas (*Iguana iguana*): an open-label study. Parasitology. 140: 1144-1148.
- Gazyagci, R., Aktas, M.S., Sari, B. (2011) The first record of the mite (*Hirstiella* sp.) on a green iguana from Turkey and its therapy with fipronil-a case report. Vet Arh. 81: 793-797.
- Hoppmann, E., Barron, H.W. (2007) Dermatology in reptiles. J Exot Pet Med. 16: 210-224.
- Khosravi, A.R., Shokri, H., Rostami, A., Tamai, I.A., Erfanmanesh, A., Memarian, I. (2012) Severe dermatophytosis due to *Trichophyton mentagrophytes* var. *interdigitale* in flocks of green iguanas (*Iguana iguana*). J Small Anim Pract. 53: 286-291.
- Kostka, V.M., Hofmann, L., Balks, E., Eskens, U., Wimmershof, N. (1997) Review of the literature and investigations on the prevalence and consequences of yeasts in reptiles. Vet Rec. 140: 282-287.
- Krantz, G.W., Walter, D.E. (2009) A Manual of Acarology. (3rd ed.) Texas Tech University Press; Lubbock, Texas, USA.
- Mancianti, F., Nardoni, S., Cecchi, S., Corazza, M., Taccini, F. (2002) Dermatophytes isolated from asymptomatic dogs and cats in Tuscany, Italy during a 15-year period. Mycopathologia. 156: 13-18.
- Murgas, D.A., Dutary, S.R., Miranda, R.J. (2013) First report of *Geckobiella stamii* (Acari: Pterygosomatidae) parasitizing *Iguana iguana* (Squamata: Iguanidae) in Panama. Rev Ibér Aracnol. 22: 97-98.
- Nweze, E.I. (2010) Dermatophytoses in Western Africa: a review. Pakistan J Biol Sci. 13: 649-656.
- Nweze, E.I. (2011) Dermatophytosis in domesticated animals. Rev Inst Med Trop. 53: 95-99.
- Pare, J.A., Sigler, L., Rosenthal, K.L., Mader, D.R. (2006) Microbiology: fungal and bacterial diseases of reptiles. In: Reptile Medicine and Surgery. Mader, D.R. (ed.). (2nd ed.) Saunders Elsevier. St Louis, USA. p. 217-238.
- Paredes-Leon, R., Klompen, H., Perez, T.M. (2012) Systematic revision of the genera *Geckobiella* Hirst, 1917 and *Hirstiella* Berlese, 1920 (Acari: Prostigmata: Pterygosomatidae) with description of a new genus for American species parasites on geckos formerly placed in *Hirstiella*. Zootaxa. 3510: 1-40.
- Peterson, S. (2006) Skin Diseases of Exotic Pets. Blackwell Science. UK.
- Schumacher, J. (2003) Fungal diseases of reptiles. Vet Clin North Am Exot Anim Pract. 6: 327-335.
- Scott, D.W., Miller, W.H., Griffin, C.E. (2001) Parasitic Skin Diseases. Muller & Kirk's Small Animal Dermatology. (6th ed.) WB Saunders Co. Philadelphia, USA.

رخدادی از یک عفونت مختلط ناشی از عوامل قارچی (تریکوفایتون منتاگروفایتس واریته منتاگروفایتس) و انگلی (گلوبیلا دونا) در ایگواناهای سبز

عقیل شریفزاده^۱، علیرضا خسروی^۱، حجت اله شکری^{۲*}، اسد بالال^۱، فاطمه عرب‌خزانی^۳

(۱) مرکز تحقیقات قارچ‌شناسی، دانشکده دامپزشکی دانشگاه تهران، تهران، ایران

(۲) گروه پاتوبیولوژی، دانشکده دامپزشکی دانشگاه تخصصی فناوری‌های نوین امل، امل، ایران

(۳) گروه انگل‌شناسی، دانشکده دامپزشکی دانشگاه تهران، تهران، ایران

(دریافت مقاله: ۲ دی ماه ۱۳۹۴، پذیرش نهایی: ۲۵ اسفند ماه ۱۳۹۴)

چکیده

زمینه مطالعه: ایگوانای سبز (ایگوانا ایگوانا) یکی از حیوانات جدید آگزوتیک وارداتی است که در کلینیک‌های دامپزشکی ایران مورد توجه زیادی قرار گرفته است. علیرغم محبوبیت‌شان، اطلاعات ناچیزی در مورد بیماری آنها وجود دارد. **هدف:** هدف این مطالعه تشخیص عوامل بیماری‌زا در ایگواناهای سبز مبتلا به ضایعات پوستی بود. **روش کار:** حیوانات با علائم درماتیت خارش‌دار، دلمه، ریزش پولک، و درماتیت عمیق زخمی‌شونده در سرتاسر بدن به بیمارستان دام کوچک دانشکده دامپزشکی تهران، ایران آورده شدند. در طی معاینه بالینی، تراشه‌هایی از سبوره خشک جهت تشخیص برداشت شدند و مورد آزمایش قرار گرفتند. نمونه‌های بالینی بر روی محیط‌های سابورو دکستروز آگار حاوی کلرامفنیکل و سیکلوهگزامید و مایکوزیل آگار کشت داده شدند. **نتایج:** در آزمایش میکروسکوپی، عناصر قارچی بنام تریکوفایتون منتاگروفایتس واریته منتاگروفایتس و مایت‌های پزوروپتیده بنام گلوبیلا دونا مشاهده گردیدند. **نتیجه‌گیری نهایی:** این مورد اولین گزارش از حضور عوامل قارچی و انگلی بعنوان عوامل بیماری‌زای ناهنجاری‌های پوستی در ایگواناهای سبز بود.

واژه‌های کلیدی: عفونت توام پوستی، گلوبیلا دونا، ایگوانای سبز، تریکوفایتون منتاگروفایتس

* نویسنده مسؤول: تلفن: ۴۴۲۷۱۰۵۷ (۹۸+), شماره: ۴۴۲۷۱۰۵۴ (۹۸+), Email: hshokri@ausmt.ac.ir