

Monocephalus omphalopagus (tetrabrachius tetrapus) in a lamb

Shojaei, B.^{1*}, Nazem, M.N.¹, Sajjadian, S.M.¹, Hasanzadeh, M.¹, Jafari, H.²

¹Department of Basic Sciences, Veterinary Medicine Faculty, Shahid Bahonar University of Kerman, Kerman, Iran

²Veterinary Medicine Practitioner, Kahnouj, Kerman, Iran

Key words:

duplication, monocephalus, omphalopagus, lamb

Correspondence

Shojaei, B.

Department of Basic Sciences,
Veterinary Medicine Faculty,
ShahidBahonar University of
Kerman, Kerman, Iran

Tel: +98(34) 32112620

Fax: +98(34) 33222047

Email: bshojaei@uk.ac.ir

Received: 7 December 2015

Accepted: 24 February 2016

Abstract:

Caudal duplication is an abnormality which usually affects the digestive, urogenital and even respiratory systems. It forms a graded series from slight duplication to near separation of two fetuses caudocranially. In some conjoined twins, duplication process may cranially proceed up to the head region. This kind of developed conjoined monocephalus twin has been reported in many domestic species and is classified as thoracopagus or omphalopagus twins according to the presence of one or two hearts, respectively. A male dead conjoined monocephalus twin lamb attached from neck to thorax was used for this study. Lateral and dorso-ventral digital radiography and anatomic dissection were performed on the case. The results showed that duplication process of the gastrointestinal tract interestingly prevented cranial to the midgut, while more cranial organs such as heart, lungs and even brain were seen duplicated. Duplication anomaly has been mostly reported cranially in cattle and caudally in sheep. Nevertheless, if duplication process does not occur completely, some body organs of the resulting conjoined twin will remain unduplicated. Duplication process of this case is thought to strengthen Spencer's spherical theory.

Case history

Congenital defects are structural and functional abnormalities present at birth because of developmental disturbances. These abnormalities may interfere with development of an organ, parts of a system or the entire system (Noden and De Lahunta, 1985). Caudal duplication is an abnormality beyond locomotor and which usually affects the digestive, urogenital and even respiratory systems. It forms a graded series from slight duplication to near separation of two fetuses caudocranially (Hiraga and Dennis, 1993). In monocephalus conjoined twins, duplication process may cranially proceed up to the head region. This kind of developed conjoined monocephalus twin has

been reported in many domestic species (Abt et al., 1962; Aine and Seavers, 2009; Buhari et al., 2008; Doijode et al., 1992; Nottidge et al., 2007) and is classified as thoracopagus and omphalopagus twins according to the presence of one or two hearts, respectively (Spencer, 2000). Anatomical features of a monocephalus omphalopagus tetrabrachius tetrapus lamb are described in this report.

Clinical Presentation

A male dead conjoined monocephalus twin lamb attached from neck to thorax (Fig. 1) was referred to Anatomy Department of Veterinary Faculty, Shahid Bahonar University of Kerman, Iran. The 2.5-3 year-old ewe had another two healthy lambs in the previous parturitions

and belonged to a herd composed of 30 adult animals located in the city of Kahnouj, Kerman province, Iran. No information of drug administration or teratogen exposure of the ewe was available. The dam and lamb were not examined for the viruses known to induce congenital anomalies.

Diagnostic Testing

External anatomical examination showed two separated cervical vertebral columns which were connected to one common head. The wide thoracic skeleton was made of two sets of right and left ribs and two sternae, all in a common integumentary sheath. Two separated bodies with two umbilici in the abdominal region were seen from caudal. One set of forelimbs and hindlimbs was determined for each body.

Digital radiography (electronic hastei, EHM, 12V-24V, 1 A) was performed in lateral and dorsal recumbency, and showed a malformed head, two separate scoliotic vertebral columns, additional costal arches and two complete sets of limbs (Fig. 2).

In order to detect the extent of organ duplication, the lamb was carefully skinned and dissected. Anatomic examinations revealed that the oral and nasal cavities communicated with each other through a complete cleft palate (Fig. 3, 4). Two tongues were seen on the floor of oral cavity, each of which was connected caudally with a hyoid apparatus. Two opposite larynges were positioned mirror-like to each other and were seen between roots of the two tongues (Fig. 3). Each larynx distally continued with a trachea. Two tracheae descended along the neck to bifurcate in the common thoracic cavity and entered two sets of lungs.

The twins shared a common digestive tract down to the terminal part of the jejunum. Beyond this site, duplication of the terminal fifth of the jejunum, ileum and large intestine was observed. One pancreas was identified in the



Figure 1. Monocephalus omphalopagus (tetrabrachius tetrapus) twin lamb.

loop of the duodenum; but, two livers, a normal and a rudimentary one emptied their bile into a single duodenum.

Each lamb had a heart, an aortic arch followed by a descending aorta, and a pulmonary trunk which communicated with each other, via the persistent ductus arteriosus. Two cranial and two caudal vena cavae were present draining into the respective right atriums. Two descending aortae communicated with each other through an anonymous 4 cm vessel.

Four testes were observed at the roof of the abdominal cavity, caudal to the respective kidneys. The ureters, urinary bladder, epididymis and vas deferens were normally observed for each lamb.

Caudal bones of the skull were duplicated. Two neighboring basilar parts of the occipital bones, caudal to a common basisphenoid, formed ventral margins of two foramen magnum (Fig. 4). Each foramen magnum was laterally and dorsally surrounded by two complete occipital lateral masses (Fig. 4). Four occipital condyles were articulated with two atlases (Fig. 5). Two squamous parts of the occipital bones were observed dorsal to the respective lateral masses. On both sides of each occipital squamous bone, two parietal bones (axial and abaxial) were observed. An anonymous bone which could be the fused two axial temporal squamous bones was observed

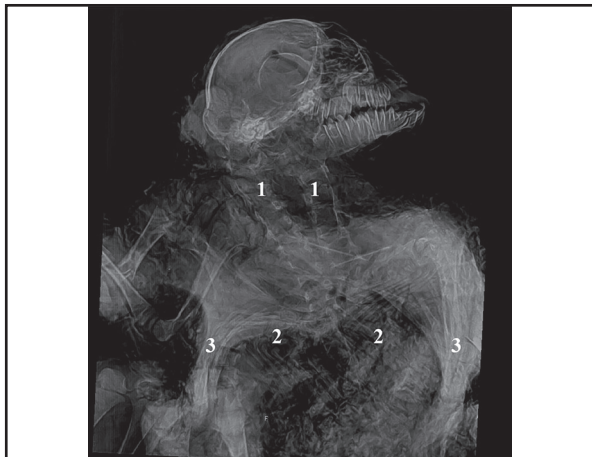

Figure 2. Radiograph of the malformed lamb. 1- Vertebral column, 2- Ribs, 3- Sternum.

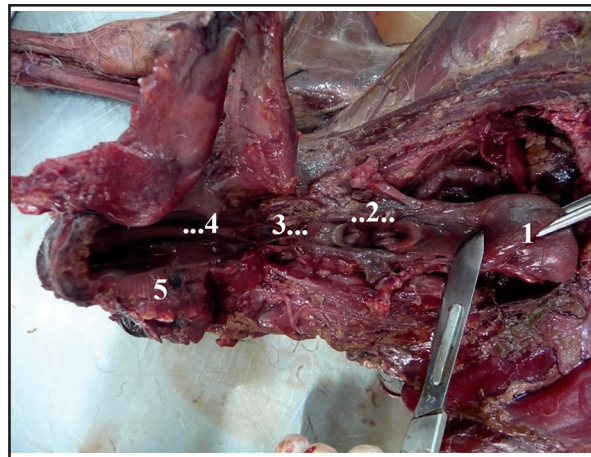


Figure 3. Dissected pharynx. 1- Greater tongue, 2- Two larynges, 3- Lesser tongue, 4- Cleft palate and Nasal Septum, 5- Hard palate.

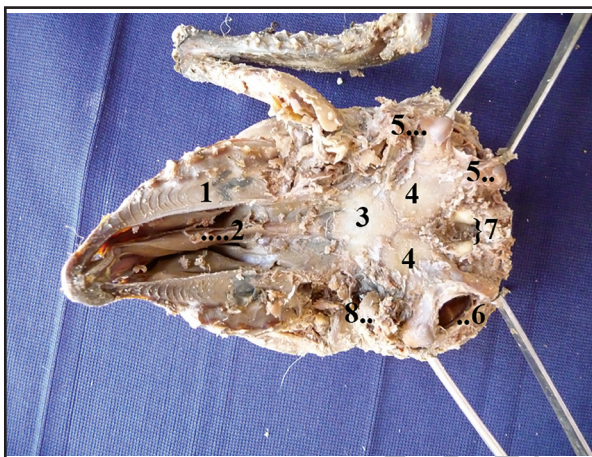


Figure 4. The ventral view of the skull. 1- Hard palate, 2- Nasal septum, 3- Basisphenoid, 4- Basisoccipitals, 5- Axial and abaxial occipital condyles of left side, 6- Foramen magnum of the right side, 7- Axial jugular processes, 8- Abaxial jugular process.

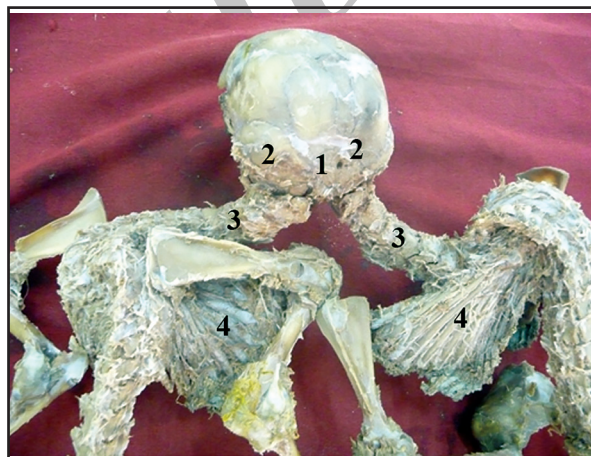

Figure 5. Skeleton of the conjoined lambs. 1- Fused two axial temporal squamous bones, 2- Parietal bone, 3- Scoliotic vertebral column, 4- The ribs which were attached to one sternum.

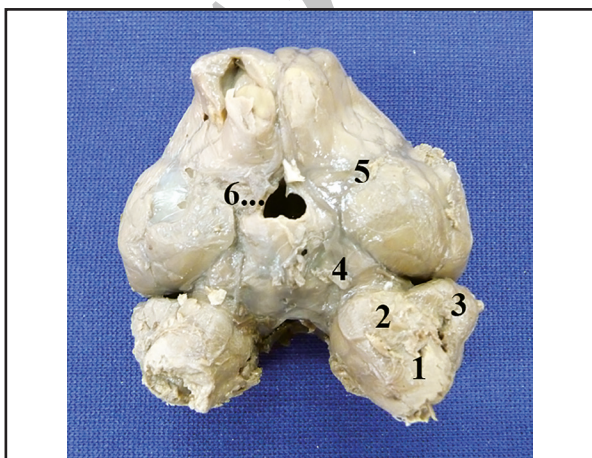


Figure 6. Ventral aspect of the brain. 1- Medulla oblongata, 2- Pons, 3- Cerebellum, 4- Mesencephalon, 5- Cerebral hemisphere, 6- Continuation of the common ventral wall of third ventricles to an infundibulum.

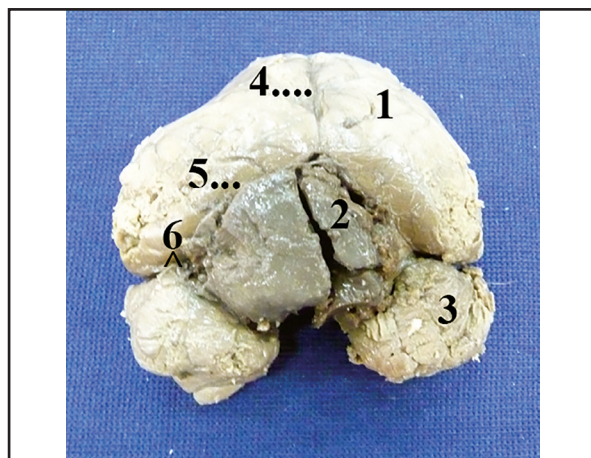


Figure 7. Dorsal aspect of the brain. 1- Abaxial cerebral hemisphere, 2- Axial cerebral hemisphere, 3- Cerebellum, 4- Longitudinal groove, 5- Bifurcated longitudinal groove, 6- Transverse groove.

between the right and left axial parietal bones (Fig. 5). Caudal to the skull, each twin had a complete set of skeleton.

Two sterna, two sets of ribs and two vertebral columns were positioned, forming a large common thoracic cavity (Fig. 5). Hereby, the diverging right and left ribs of each vertebral column were articulated with the two sterna which were situated at the midway of the two vertebral columns. In other words, each sternum was articulated with the right ribs of one vertebral column and the left of the other column.

Rhombencephalon and mesencephalon were completely duplicated (Fig. 6). Two diencephalons were also recognized with complete dorsal and abaxial walls. Axial walls of the right and left diencephalons were incompletely formed in their rostral parts, and somehow with a common ventral wall the shared third ventricle continued ventrally to an infundibulum and rostrally to the lateral ventricles. The third ventricle caudally went on to two separate cerebral aqueducts. The rostral two-thirds of the two abaxial cerebral hemispheres were separated from each other by a longitudinal groove. Beyond this, the groove was caudally bifurcated to separate large abaxial and rudimentary axial parts of both the right and left brain hemispheres (Fig. 7). There was no ventricle in the rudimentary cerebral hemispheres.

Assessments

In literature, frequency of monocephalus conjoined twins is variable among different ruminants. It has been reported rarely in goats (Corbera et al., 2005; Mitra et al., 1994; Otiang'a-owiti et al., 1997; Shojaei et al., 2012) and buffalos (Antoine et al., 1997; Thakur, 1988) and frequently in cattle (Abt et al., 1962; Hiraga and Dennis, 1993; Shojaei et al., 2010) and sheep (Dennis, 1975; Doijode et al., 1992; Hiraga and Dennis, 1993). Although the embryologic basis of the caudal duplica-

tion is unclear (Sur et al., 2013), an increased number of caudal duplication anomalies in ruminants which have been referred recently to Veterinary Faculty of Shahid Bahonar University of Kerman (Shojaei et al., 2010; Shojaei et al., 2012, and two unpublished cases of monocephalus tetrabrachius tetrapus in goat) can encourage epidemiologists to search for the causal environmental factor.

Striking similarities of the reported conjoined twins of different species have been evidence based on which researchers propose similar mechanisms for producing duplicated cases. Detailed anatomical evaluation of the referred malformed cases can provide data to better understand the underlying mechanisms. Dominguez et al. reported six similar cases of caudal duplication and introduced the term "caudal duplication syndrome" (Dominguez et al., 1993). In this syndrome, duplication of gastrointestinal tract from distal part of jejunum downward and its unduplicated proximal part are described. This phenomenon has been observed in the present case and in other reported caudal duplication cases (Bannykh et al., 2001; Kroes et al., 2002; Otiang'a-owiti et al., 1997; Shojaei et al., 2012); there may be more interest in the case of considering the extent of duplication process in the present case. In the present case, duplication of organs such as the heart, lungs and even brain, which are anatomically more cranial to some unduplicated organs such as stomach and duodenum (as gut derivatives) suggest that the duplication process of the gut did not develop as much as the other body organs did. This difference could strengthen Spencer's spherical theory, which states that "a group of conjoined twins resulting from the union of two embryonic discs (or incomplete fission in one disc) over a common yolk sac" typically share some portion of the gastrointestinal tract (Spencer, 2000). In this context, duplication of the liver as a foregut derivative in the present case which was observed as a liver enlargement in a Craniotho-

racopagus dog (Nottidge et al., 2007) might be interpreted according to the presence of two inducers (ductous venosous) for its morphogenesis (Tatsumi et al., 2007).

Duplication anomaly has been mostly reported cranially in cattle (Hiraga and Dennis, 1993) and caudally in sheep (Dennis, 1975). Nevertheless, if duplication process does not occur completely, some body organs of the resulting conjoined twin will remain unduplicated. In the present animal, duplication started in the caudal region of the body and continued to the head. Presence of two larynges, two hyoid apparatuses and two tongues along with unduplicated mandible and maxilla bones indicated that, in embryonic period, duplication process extended up to second pharyngeal arches and their derivatives, which are surrounded by unduplicated structures resulting from the first arch.

Acknowledgements

This research was financially supported by the Research Council of Shahid Bahonar University of Kerman.

References

1. Abt, D.A., Croshaw, J.E., Hare, W.C.D. (1962) Monocephalus dipygus parasiticus and other anomalies in a calf. *JAVMA*. 141: 1068-1072.
2. Aine, M.S. (2009) Monocephalus dipygus parapagus: a suspected case of complete caudal duplication in a British Blue kitten. *J Feline Med Surg*. 11: 330-331.
3. Antoine, D., Murugavel, K., Alphonse, R.M.D., Ramalingam, S., Thandavamurthy, C. (1997) Monocephalus dipygus monster in a buffalo—a case report. *Indian J Anim Reprod*. 18: 166.
4. Bannykh, S.I., Bannykh, G.I., Mannino, FL., Jones, KL., Hansen, L., Benirschke, K., Masliah, E. (2001) Partial caudal duplication in a Newborn associated with meningocele and complex heart anomaly. *Teratology*. 63: 94-99.
5. Buhari, S., Yakubu, A.S., Jibril, A., Adeyanju, J.B., Chafe, U.M. (2008) Monocephalus, thoracopagus and dipygus twins in Sokoto Red goat. *Sokoto J Vet Sci*. 7: 23-24.
6. Corbera, J.A., Arencibia, A., Morales, I., Gutierrez, C. (2005) Congenital duplication of the caudal region (monocephalus dipygus) in a kid goat. *Anat Histol Embryol*. 34: 61-63.
7. Dennis, SM. (1975) Embryonic duplications in sheep. *Aust Vet J*. 51: 83-87.
8. Doijode, SV., Thorat, N.H., Markandeya, N.M., Mamde, C.S. (1992) Monocephalus dipygus conjoined twin lamb. *Indian J Anim Reprod*. 13: 206.
9. Dominguez, R., Rott, J., Castillo, M., Pittaluga, R.R., Corriere, J.N. (1993) Caudal duplication syndrome. *Am J Dis Child*. 147: 1048-1052.
10. Hiraga, T., Dennis, S.M. (1993) Cogenital duplication. *Vet Clin North Am-Food*. 9: 145-161.
11. Kroes, HY., Takahashi, M., Zijlstra, R.J., Baert, J.A.L.L., Kooi, K.A., Hofstra, R.M.W., VanEssen, A.J. (2002) Two cases of the caudal duplication anomaly including a discordant monozygotic twin. *Am J Med Genet*. 112: 390-393.
12. Mitra, M., Basak, DN., Chakrabarti, A. (1994) Monocephalus thoracopagus tetrapus tetrabrachius monster in a Black Bengal goat. *Indian Vet J*. 71: 177-178.
13. Noden, DM., De Lahunta, A. (1985) Developmental mechanisms and malformations. In: *The Embryology of Domestic Animals*. Williams and Wilkins, (1st ed.) Baltimore, USA. p. 109-152.
14. Nottidge, H.O., Omobowale, T.O., Olopade, J.O., Oladiran, O.O., Ajala, O.O. (2007) A case of craniothoracopagus (monocephalus thoracopagus tetrabrachius) in a dog. *Anat Histol Embryol*. 36: 179-181.
15. Otiang'a-owiti, GE., Oduor-okelo, D., Kamau, G.K., Makori, N., Hendrickx, A.G. (1997) Morphology of a six-legged goat with duplication of the intestinal, lower urinary, and genital tracts. *Anat Rec*. 247: 432-438.

16. Shojaei, B., Kheirandish, R., Hasanzade, M. (2010) Monocephalus tetrapus dibrachius in a calf. *Comp Clin Pathol.* 19: 511–513.
17. Shojaei, B., Mohebbi, E., Hashemnia, Sh. (2012) Caudal duplication (monocephalus tripus dibrachius) in a kid goat. *Eur J Anat.* 16: 206-211.
18. Spencer, R. (2000) Theoretical and analytical embryology of conjoined twins: Part I, Embryogenesis. *Clin Anat.* 13: 36–53.
19. Sur, A., Kumar Sardar, S., Paria, A., (2013) Caudal duplication syndrome. *J Clin Neonatol.* 2: 101–102.
20. Tatsumi, N., Miki, R., Katsu, K., Yokouchi, Y. (2007) Neurturin-GFR α 2 signaling controls liver bud migration along the ductus venosus in the chick embryo. *Dev Biol.* 307: 14–28.
21. Thakur, SB. (1988) Dipygus monstrosity in a calf. *Indian Vet J.* 65: 440.

Archive of SID

گزارش ناهنجاری مونوسفالوس امفالوپاگوس در یک راس بره

بهادر شجاعی^{۱*} محمد ناصر ناظم^۱ سید محسن سجادیان^۱ محمد حسن زاده^۱ حجت اله جعفری^۲

(۱) گروه علوم پایه، دانشکده دامپزشکی، دانشگاه شهید باهنر کرمان، کرمان، ایران

(۲) اداره دامپزشکی کهنوج، کرمان، ایران

(دریافت مقاله: ۱۶ آذر ماه ۱۳۹۴، پذیرش نهایی: ۵ اسفند ماه ۱۳۹۴)

چکیده

ناهنجاری دوتایی شدن از سمت خلف بدن اغلب دستگاه‌های گوارش، ادراری تناسلی و حتی تنفسی را درگیر می‌کند. این ناهنجاری با طیف متفاوتی از دوتایی شدن به میزان کم تا تقریباً کامل دو حیوان گزارش شده است. در برخی از دوقلوهای به هم چسبیده، روند دوتایی شدن ممکن است تا ناحیه سر نیز کشیده شود. این نوع ناهنجاری در گونه‌های متعددی از حیوانات اهلی دیده شده است و با توجه به حضور یک یا دو قلب به نام توراکوپاگوس و یا امفالوپاگوس خوانده می‌شود. در این مطالعه یک بره مرده دوتا شده با یک سر و دو تنه که در نواحی گردن و سینه به یکدیگر اتصال داشتند مورد مطالعه قرار گرفت. تشریح ماکروسکوپی حیوان و رادیوگرافی دیجیتال آن با دو حالت گماری جانبی و پشتی - شکمی انجام شد. در حیوان مطالعه شده حاضر، دوتایی شدن دستگاه گوارش از عقب به جلو فقط تا روده پیشین جنینی دیده شد در حالی که این اتفاق در اندام‌هایی که در بدن موقعیت قدامی تری دارند، مانند قلب، ریه‌ها و حتی قسمت‌هایی از مغز دیده شد. ناهنجاری دوتایی شدن در گاو اغلب از سمت جلوی بدن و در گوسفند از سمت عقب بدن شروع شده و به طرف انتهایی دیگر بدن پیشرفت می‌کند. بسته به میزان پیشرفت روند دوتایی شدن، اندام‌هایی از بدن حیوان درگیر شده و اندام‌های دیگر مستقل باقی می‌مانند. به نظر نویسندگان، نحوه دوتایی شدن در این حیوان تئوری اسپنسر را تقویت می‌کند.

واژه‌های کلیدی: دوتایی شدن، مونوسفالوس، امفالوپاگوس، بره

* نویسنده مسؤول: تلفن: ۳۲۱۱۲۶۲۰ +۹۸(۳۴) نمابر: ۳۳۲۲۲۰۴۷ +۹۸(۳۴) Email: bshojaei@uk.ac.ir