

Evaluation of the Effects of Adipose Derived Mesenchymal Stem Cells Cultured on Decellularized Amniotic Membrane in Wound Healing of Distal Part of the Limbs in Horse

Bassim Kadhim Khashjooi¹, Seyed Mehdi Ghamsari^{1,2}, Mohammad Mehdi Dehghan^{1,2}, Saeed Farzad Mohajeri^{1,2}, Hossein Gholami², Hannaneh Golshahi³

¹Department of Surgery and Radiology, Faculty of Veterinary Medicine, University of Tehran, Tehran, Iran

²Institute of Biomedical Research, University of Tehran, Tehran, Iran

³Nanobiotechnology Research Center, Avicenna Research Institute, ACECR, Tehran, Iran

Abstract:

BACKGROUND: Equine wounds, particularly those involving the distal portion of the limbs, often undergo prolonged complex healing and may enter a non-healing state with obvious financial and welfare implications. Poor blood supply and lower levels of oxygen to the lower limbs lead to imbalance of growth factors related to wound healing. Decellular amniotic membrane has been widely used in soft tissue engineering especially skin regeneration due to its biological and mechanical properties. It is used as a scaffold for treatment of partial full thickness wound dressing.

OBJECTIVES: Evaluation of the effects adipose derived mesenchymal cells (ADMSCs) cultured on decellularized amniotic membrane (DAM) in wound healing of distal part of equine limb.

METHODS: Stem cells were isolated from adipose tissue in the base of the tail and then cultured and seeded on bovine decellular amniotic membrane. Full thickness excision wounds (2x3 cm) were created on the mid-lateral of all metatarsus of each horse aseptically. The wounds were classified into four groups: the first one covered by DAM seeded by ADMSCs, the second one dressed with only DAM, the third one treated with 1% silver sulfadiazine, and the last one as control with no treatment. Digital photographs of wounds were obtained at each bandage change while biopsy samples were obtained for histopathology at days 5, 15 and 30 after treatment.

RESULTS: Wounds treated with DAM/ADMSCs significantly demonstrated promotion of wound healing in geometric analysis of total wound area, epithelialization and wound contraction compared with the other groups ($P < 0.05$). Microscopically, re-epithelization of wounds covered by DAM/ADMSCs and DAM at day 5 was significantly more than Control group ($P < 0.05$). Fibroplasia in wounds treated with DAM/ADMSCs and DAM was higher than the group that received sulfadiazine ($P < 0.05$).

CONCLUSIONS: These results indicate positive effects of using DAM to improve the quality and speed of wound healing. Use of DAM as a scaffold for ADMSCs shows better results.

Keywords:

Amniotic membrane, Distal limb, Horse, Mesenchymal stem cells, Wounds healing

Correspondence

Seyed Mehdi Ghamsari, Department of Surgery and Radiology, Faculty of Veterinary Medicine, University of Tehran, Tehran, Iran

Tel: +98(21) 66577491, Fax: +98(21) 66913104, Email: ghamsari@ut.ac.ir

Received: 19 June 2018

Accepted: 11 September 2018

Copyright © 2018, Iranian Journal of Veterinary Medicine. This is an open-access article distributed under the terms of the Creative Commons Attribution-noncommercial 4.0 International License which permits copy and redistribute the material just in noncommercial usages, provided the original work is properly cited.

How to Cite This Article

Khashjooi, B., Ghamsari, S., Dehghan, M., Farzad Mohajeri, S., Gholami, H., Golshahi, H. (2019). Evaluation of the Effects of Adipose Derived Mesenchymal Stem Cells Cultured on Decellularized Amniotic Membrane in Wound Healing of Distal Part of the Limbs in Horse. *Iran J Vet Med*, 13(1), 11-25. doi: 10.22059/ijvm.2019.244278.1004854

Introduction

Skin wound healing is a dynamic and multifaceted process involving a series of procedures including inflammation, re-epithelization, dermal reconstruction, wound contraction, and remodeling (Sinno and Prakash et al., 2013). It is controlled by interacting signals that regulate many of the cellular and molecular proceedings (Ghar-ae-Kermani and Phan, 2001).

Large animals are considered as an outstanding model for the study of wound healing process (Theoret and Wilmink, 2013). Horses often suffer from traumatic lesion and/or surgical incisions on the distal limbs and these wounds are often contaminated and associated with widespread tissue and skin loss, so the healing often occurs by second intention and this process in the horse is usually associated with scarring and loss of function (Bischofberger et al., 2011; Gomez et al., 2004; Dart et al., 2002). Second intention contains two independent procedures: 1) contraction, and, 2) re-epithelialization. Second intention is often the only probability to close extensive and profound wounds (Souza et al., 2015; Theoret and Olutoye, 2013). However, this process is slow and may result in the formation of exuberant granulation tissues that is related to delayed closure and increased scar tissue formation on the distal limb (Theoret and Olutoye, 2013; Enoch and Leaper, 2005). Furthermore, in horses, initial inflammatory response is weak and the natural wound debridement procedure is slow, and the risk of infection is high. Therefore, after the initial phase, chronic inflammation at the site of the wound develops and leads to wound infection and also exuberant granulation occurs in most cases. Moreover, equine dis-

tal limb wounds recover slowly and usually respond poorly to conventional therapies. Granulation tissues develop more slowly, and wound stays more irregular and purulent for a longer time in horses compared to most animal species (Spaas et al., 2013; Edwards-Milewski et al., 2015; Schwartz et al., 2002; Wilmink et al., 2002; Theoret et al., 2001).

Various cell types, cytokines, chemokines, and extracellular matrix molecules at the wound site interact with many systemic factors like platelets, coagulation cascade, and humoral cell components, which facilitate the wound healing (Soo et al., 2002). Furthermore, many factors such as advanced age, various diseases (e.g., diabetes), and malnutrition can influence the efficiency of the wound healing process (Carter et al., 2003; Singer and Clark, 1999).

An important issue that must be mentioned is wounds below the knee and/or hock are resistant to healing even in the healthiest horses. This issue may be related to poor blood supply and less oxygen to the lower limbs due to the great distance between the trunk and lower limbs which result in imbalance of growth factors (Carter et al., 2003; Theoret et al., 2001; Jorgensen, 2017). This condition may form a hypoxic environment, which can result in up-regulation of pro-fibrotic mediators and exuberant granulation tissue formation that may physically disrupt wound re-epithelialization and contraction (Bischofberger et al., 2015; Dart et al., 2009). Furthermore, after induction of injury, blood supply to the wounded area is decreased due to thrombosis, swelling, and tissue loss. In addition, during second intention healing, the microvasculature is often 50% to 60% obstructed in wounds

of the equine distal limb, which delivers the most amount of oxygen and nutrient source. Therefore, the hypoxia reduces wound healing by diminishing the wound's normal antibacterial response, rate of re-epithelialization, wound contraction, and collagen synthesis (Tracey et al., 2014; Wilmlink et al., 2002; Lepault et al., 2005). Chronic non-healing wounds of the lower limb of horses have similarities to human leg ulcers (e.g. humans with diabetic foot ulcers). Therefore, effective therapy of non-healing wounds, acceleration of wound healing and scar-free healing would be valuable for both the equine and human (Carter et al., 2003).

As mentioned previously, equine distal limb wounds cannot be closed primarily and should be covered by dressing layers to control bacterial proliferation, stimulate re-epithelialization and contraction, and does not induce unwarranted antigenic reaction. In recent decade, researches demonstrate that biologic dressings can stimulate wound healing by providing and conserving a moist environment that is favorable for regeneration and migration of epithelial cells, acting as a bacterial barrier, and delaying exuberant granulation tissue formation. Interestingly, these biologic dressings can prompt a minor inflammatory response, which probably has favorable effects on wound healing (Gomez et al., 2004; Purna and Babu, 2000; May, 1991; Hunt, 1990).

Mesenchymal stromal cells (MSCs) are multipotent stromal progenitor cells that contribute to regenerative procedures by involving in the proliferative, inflammatory, homeostatic, and remodeling phases of tissue regeneration (Gnecchi et al., 2008; Aggarwal et al., 2005; Ono et al., 2004). It has been shown that MSCs and Adipose-derived stem cells (ASCs) can self-renew and could

be able to proliferate and differentiate into various cell lineages or by a paracrine effect via the secretion of growth, anti-apoptotic and anti-inflammatory factors (Choudhery et al., 2013; Abumaree et al., 2012; Ryan et al., 2007). ASCs have the highest proliferation and differentiation potential, followed by MSCs derived from bone marrow and cartilage. ASCs can stimulate human dermal fibroblast proliferation and secretion by direct cell-to-cell contact (Peng et al., 2008; Kim et al., 2007). In equines, several researchers reported that isolation and characterization of stem cells could be possible by use of equine-specific tissues (e.g. bone marrow, adipose tissue, and umbilical cord blood) (de Mattos Carvalho et al., 2009; Arnhold et al., 2007; Lee et al., 2004).

Amniotic membrane (AM) has been used as a skin substitute for treatment purpose (Lo and Pope, 2009; Kesting et al., 2008). It is the innermost layer of the placenta, with unique properties like, promotes epidermal regeneration, wound protection, accelerates wound healing, anti-inflammatory and bacteriostatic effects, anti-fibrotic properties, reduced scarring, and analgesic effects (Elheneidy et al., 2016; Mohan et al., 2017). AM does not have blood and/or lymphatic vessels, and nerves, so it has low immunogenicity properties (Singh et al., 2004). Amniotic cells produce and release growth factors, which can help keratinocyte proliferation and differentiation like epidermal growth factor (EGF) and its receptor, vascular endothelial growth factor (VEGF), and tissue inhibitors of metalloproteinase 1 and 2 (TIMP-1 and -2) (nTyszkiewicz et al., 1999; Ramakrishnan and Jayaraman, 1997).

The aim of current study was to evaluate the adipose derived mesenchymal cells

(ADMSCs) cultured on decellularized amniotic membrane (DAM) in wound healing of distal part of equine limb.

Materials and Methods

All procedures were approved by the Ethics Committee of Faculty of Veterinary Medicine, University of Tehran. All processes were carried out with due care for animal welfare.

Four healthy adult horses (two males and two females) in good general health weighing between 300-400 kg and aged 4-18 years were used in this study. There were no visible and/or palpable abnormalities of their metacarpal/metatarsal regions. Hoof care was done two weeks before the beginning of the study. Their diet consisted of alfalfa hay. Free choice commercial grain was fed as necessary to maintain body condition. Water and mineral salt were provided ad libitum.

Grouping: 3 wounds 2x3 cm were created on distal aspect regions of each limb of all 4 horse, then wounds of each horse were divided into 4 groups as the following:

- 1- Wounds treated with decellularized amniotic membrane and mesenchymal stem cells. (DAM/ADMSCs)
- 2- Wounds treated with decellularized amniotic membrane. (DAM)
- 3- Wounds treated with sulfadiazine ointment. (Sulfadiazine)
- 4- Wounds left with no treatment. (Control)

Isolation and cultivation of adipose derived mesenchymal stem cells: The region above the dorsal gluteal muscle, at the base of the tail, was chosen as the adipose tissue collection site due to the availability of the adipose tissue, the absence of large veins, and easy access. The horses were sedated

by intravenous administration of 2% xylazine (1 mg/kg body weight). In addition, subcutaneous nerve block was performed with 2% lidocaine hydrochloride around the site to be incised. The surgical site was prepared appropriately for aseptic surgery. An approximately 10 cm incision was performed parallel to and approximately 15 cm below the spinal column, permitting visualization of a layer of adipose tissue between the skin and musculature. Approximately 5 g of adipose tissue was collected and stored in a sterile 50 mL centrifuge tube containing phosphate-buffered saline (PBS) solution plus 1% penicillin/ streptomycin. Then, the skin was sutured with nylon suture in simple interrupted sutures (Carvalho et al., 2009). Equine MSCs were obtained by enzymatic digestion with collagenase according to routine protocols. Briefly, the adipose tissue was washed several times with PBS solution containing 1% penicillin-streptomycin. Then the samples were placed in petri dishes to separate fibrous tissue and blood and dice them to approximately 0.2 to 0.3 cm size with a 15-scalpel blade and surgical forceps. Then they were placed in a solution of 0.04% type 1 collagenase at 37 °C, 5.0% CO₂ for 45 min. After this period, the solution was filtered through a 150-micrometer filter to remove undigested tissue, followed by neutralization of the enzyme with DMEM (Dulbecco's modified Eagle's medium) containing 10% FBS, and then the solution was centrifuged twice at 400×g for 15 min. The supernatant was aspirated and added to PBS and homogenized for next centrifugation. A sample of cells was stained with Trypan Blue and counted using a microscope-counting chamber. Cells were cultured at a density of approximately 10 × 10³ cells/cm² in 25-cm² flasks containing

the culture medium described previously at 37 °C in a humidified atmosphere containing 95% air and 5% CO₂. The culture medium was changed every three days until a cell confluence of $\geq 80\%$ was reached (Barberini et al., 2014).

Preparation of amniotic membrane: AM was obtained from bovine placenta freshly. The tissue was washed with PBS containing antibiotics (100 U/ml penicillin and 100 µg/ml streptomycin). Then it was stored at -20 °C immediately and after 12 h, it was thawed. AM was washed with PBS, cut into pieces and put into 0.5% Triton X-100 solution containing antibiotics. This was shaken at 4 °C overnight. Then the AM pieces were washed with PBS. Decellularity of AM was confirmed by histopathology. 20 x30 mm sheaths of decellular AM were placed into the cell culture medium for cell seeding.

Wound creation: Horses were sedated with xylazine hydrochloride (0.4 - 0.6 mg/kg B.W. via I.V. route). Each horse was then anesthetized with I.V. injection of a combination of ketamine hydrochloride (2.2 mg/kg B.W.) and xylazine (1.1 mg/kg B.W.), and maintained with isoflurane inhalation for 20 to 30 min during the surgical procedure of wound creation. The metacarpi/metatarsi region was clipped and cleaned with isopropyl alcohol soaked gauze. A sterile 2×3 cm rectangular template was used to ensure consistent wound surface area. A standardized full-thickness skin wound was generated on the dorso-medial surface of each third metacarpal/metatarsal bone centered between the metacarpophalangeal and carpometacarpal joints or meta-tarsophalangeal and tarsometatarsal joints. Full-thickness skin incisions (n = 12 wounds/ horse) were created and then the dermis and subcutis

were removed. For controlling hemorrhage, sterile non-adhesive pad and bandaged with gauze-coated cotton wool and an elastic bandage were used. All wounds remained bandaged throughout the study period according to wound management protocols of the hosting facility. The wounds were gently cleaned with sterile gauze soaked in isotonic saline solution and were re-bandaged twice a week. The horses were monitored at regular intervals during experimental period.

Wound measurements: Digital photographs of the wounds were obtained at day 0, 5, 15, and 30. A standardized ruler was included in each photograph for digital calibration of the photographs. Gross evaluation of wound healing was performed based on the percent of wound contraction (WC %), area of epithelialization (AE) (cm²), and wound area (WA) (cm²).

Wound Contraction was calculated using the formula:

$$(W_0 - W_1) / W_0 * 100$$

Where

W₀ = the initial wound measurement

W₁ = the wound measurement on day of measurement

Biopsy sampling: Biopsy samples were obtained on days 5, 15, and 30 of treatment. Horses were sedated before the procedures and the biopsy sites were cleaned with saline solution and gauze. Full-thickness biopsies with 2-3 mm margin of intact skin were taken. Samples were fixed in 10% neutral-buffered formalin, embedded in paraffin, sectioned at 5 µm thickness and stained with hematoxylin and eosin (H&E) and also Masson's trichrome stain (MT) using standard procedures for light microscopy. Microscopic evaluation was performed by a pathologist. Epithelial hyperplasia, in-

flammation, granulation bed, angiogenesis, and fibroplasia were the evaluated criteria and grading was done according to Tracey et al. (2014).

Statistical analysis: Data was analyzed as a repeated measurement analysis of variance. Significance was set at P Value < 0.05.

Result

Wound Geometric Analysis: Day 5: The mean ± SD of total wound area for each treatment group in day 5 was as follows: DAM/ADMSCs, 5.03 ± 0.55 cm²; DAM, 5.52 ± 0.20 cm²; Sulfadiazine, 4.99 ± 0.13 cm²; and Control, 5.55 ± 0.17 cm². There were some significant differences among groups: Total wound area in day 5 in DAM/ADMSCs group was significantly less than in DAM group ($P=0.046$) and Control group ($P=0.0370$). In Sulfadiazine group there is a significantly lesser total wound area from DAM ($P=0.034$) and Control group ($P=0.027$). There was no significant difference between the size of wounds in groups DAM/ADMSCs and Sulfadiazine.

The mean ± SD of epithelialized area of each group in day 5 was as follows: DAM/ADMSCs, 0.22 ± 0.05 cm²; DAM, 0.17 ± 0.04 cm²; Sulfadiazine, 0.18 ± 0.05 cm²; and Control, 0.18 ± 0.02 cm². There was not any significant difference between groups.

The mean ± SD of wound contraction percentage of each group in day 5 was as follows: DAM/AMSCs, 16.24 ± 2.11%; AM, 11.38 ± 1.50 %; Sulfadiazine, 12.75 ± 2.12 %; and Control 6.74 ± 2.66 %. Significant differences were determined between DAM/ADMSCs and group DAM ($P=0.016$), group Control ($P=0.000$). Wounds dressed only with DAM ($P=0.026$) and wounds treated with sulfadiazine ($P=0.007$) both showed better wound contraction compared with

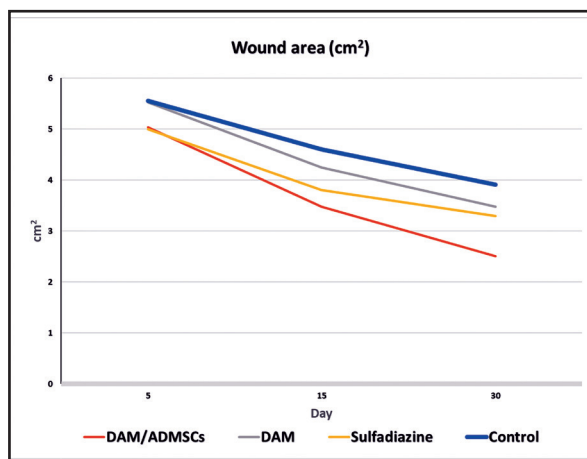


Figure 1. Wound area.

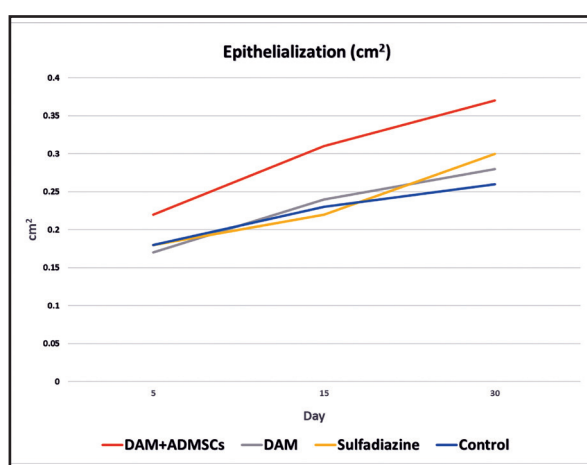


Figure 2. Epithelialized area.

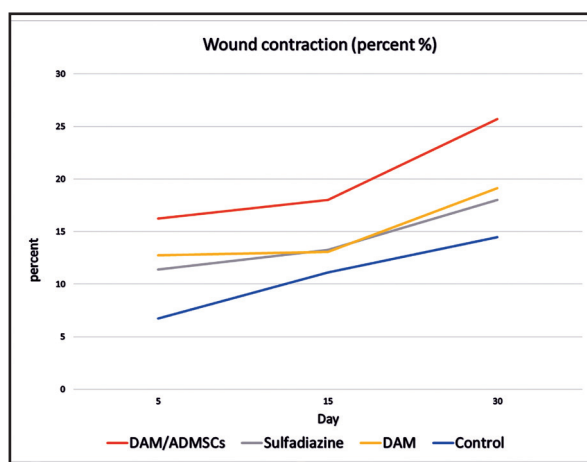


Figure 3. Wound contraction.

group Control. But any significant disagreement in wound contraction at day 5 was not shown between group DAM and Sulfadiazine.

Day 15: The mean ± SD of total wound

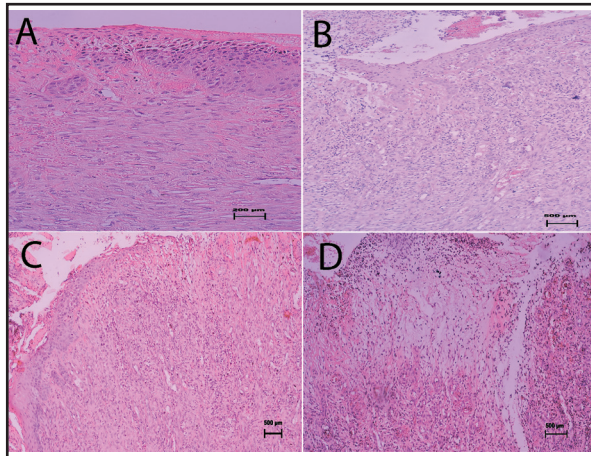


Figure 4. (a): Tissue from a wound applied by AM/MSCs obtained 5 days after wounding displays partial and focal re-epithelization at margin. In dermis relatively irregular arrangement of fibroblasts, new capillary formation, and mild to moderate congested vessels can be seen. (b) A representative tissue from a case applied by AM at day 5 after wounding displays partial re-epithelization with an immature granulation tissue with diffuse infiltration of inflammatory cells specially around newly blood vessels, and also, irregular arrangement of moderate number of active fibroblasts. (c): Tissue from a sulfadiazine-treated wound was obtained 5 days after wounding demonstrates immature, hyper granulation tissue with focal and/or diffuse infiltration of inflammatory cells in dermis. (d) Representative tissue from a control wound at day 5. Note to immature and edematous hyper granulation tissue in dermis. (H & E), Bar: a: 200µm and b-d: 500 µm.

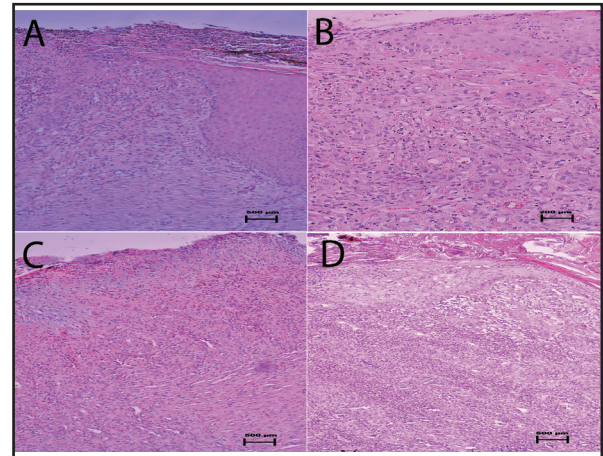


Figure 5. (a): A case with AM + MSCs treatment 15 days after wounding. Note to crusts formation and partial re-epithelization at margin of wound and also active fibroblasts, moderate amount of collagen fibers in dermis. (b): A case that received AM 15 days after wounding, demonstrates partial re-epithelization at marginal area. Note to mild infiltration of inflammatory cell in dermis. (c): Sulfadiazine-received case at day 15 after wounding. The re-epithelization is not prominent and in dermis moderate to severe infiltration of polymorphonuclear cells can be detected. (d) By day 15, the newly formed epithelium is partially at the wound margin. In dermis, an edematous granulation tissue with moderate presence of inflammatory cells particularly neutrophil exists. (H & E), Bar: a, c, and d: 500µm and b: 200 µm.

area for each treatment group in day 15 was as follows: DAM/ADMSCs, 3.47 ± 0.25 cm²; DAM, 4.24 ± 0.14 cm²; Sulfadiazine, 3.50 ± 0.21 cm²; and Control, 4.60 ± 0.17 cm². Significant differences between groups: wound size in DAM/ADMSCs group was significantly smaller than AM group ($P= 0.009$) and Control group ($P=0.011$). Similarly, wounds treated with Sulfadiazine show a significant decrease of size compared with DAM group ($P= 0.023$) and Control group ($P=0.008$).

The mean \pm SD of epithelialized area for each treatment group in day 15 was as follows: DAM/ADMSCs, 0.31 ± 0.04 cm²; AM, 0.24 ± 0.02 cm²; Sulfadiazine, 0.22 ± 0.05 cm²; and Control, 0.23 ± 0.02 cm².

Significant differences revealed that group AM/MSCs had a wider area of epithelialization than groups Sulfadiazine ($P= 0.020$) and Control ($P= 0.034$).

The mean \pm SD of wound contraction percentage of each group in day 15 was as follows: DAM/ADMSCs, $16.24 \pm 2.11\%$; DAM, $13.27 \pm 1.84\%$; Sulfadiazine, $13.08 \pm 2.83\%$; and Control $11.09 \pm 2.77\%$. Wound contraction in group DAM/ADMSCs was significantly more than groups DAM ($P=0.036$), Sulfadiazine ($P=0.030$) and Control ($P=0.006$).

Day 30: The mean \pm SD of wound size of each group in day 30 was: DAM/ADMSCs, 2.50 ± 0.06 cm²; DAM, 3.47 ± 0.07 cm²; Sulfadiazine, 3.29 ± 0.09 cm²; and Control, 3.91 ± 0.15 cm². Statistical analysis showed

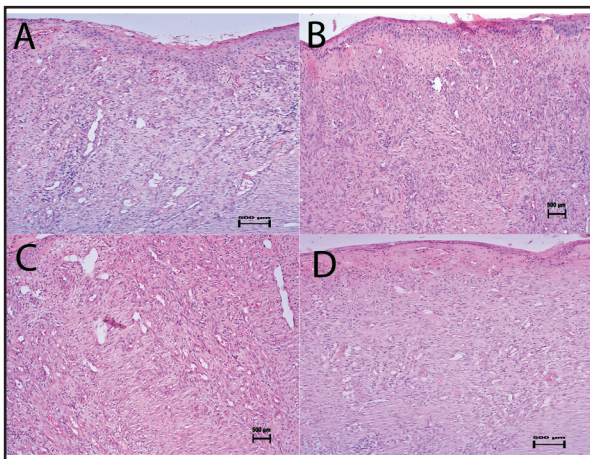


Figure 6. (a) Tissue obtained at day 30 after wounding from a case received AM+ MSCs, shows relatively epidermis reformation with moderate thickness. Extracellular matrix displays predominance of thick collagen fibers with not complete organization. (b): At day 30, in group received AM, newly formed epithelial layer and also fibroblasts proliferation and slight infiltration of inflammatory cells in dermis can be seen. (c): Tissue from a wound treated with sulfadiazine at day 30 after wounding displays relatively mature hyper granulation tissue with moderately organized interconnecting collagen fibers in dermis. (d) Tissue from a control wound 30 days after wounding shows incomplete re-epithelization. (H & E), Bar: a-d: 500 μ m.

significant differences in wound size of day 30 between all four groups ($P < 0.05$), such that DAM/ADMSCs had the least wound size compared with the other groups. DAM wound area was greater than Control but had smaller wound area than Sulfadiazine group.

The mean \pm SD of epithelialized area for each treatment group in day 30 was as follows: DAM/ADMSCs, 0.37 ± 0.06 cm²; DAM, 0.28 ± 0.02 cm²; Sulfadiazine, 0.30 ± 0.05 cm²; and Control, 0.26 ± 0.03 cm². There was a significant difference between group DAM/ADMSCs and Control ($P = 0.034$) in epithelialization (Fig 3.).

The mean \pm SD of wound contraction percentage of each group in day 30 was as follows: DAM/ADMSCs, $25.69 \pm 2.15\%$; DAM, $18.02 \pm 3.04\%$; Sulfadiazine, 19.13

$\pm 2.98\%$; and Control $14.45 \pm 2.23\%$. Wound contraction in group DAM/ADMSCs was significantly more than groups AM ($P = 0.036$), Sulfadiazine ($P = 0.030$) and Control ($P = 0.006$). (Fig 3.)

Microscopic evaluation: At day 5, the most cases received DAM and/or DAM/ADMSCs, demonstrated focal and partial re-epithelization on the upper portion of the wound edges (Fig 4.a and b). No obvious re-epithelialization was seen in cases related to the control and sulfadiazine received-groups (4. c and d). An immature, edematous hyper granulation tissue with congested vessels and focal and/or diffuse hemorrhagic area were also seen in dermis of control and sulfadiazine-received groups. Newly organized collagen bundles were not prominent in all cases in these two groups. In cases that were applied by DAM, in dermis, an edematous and immature hyper granulation tissue with diffuse infiltration of inflammatory cells around newly blood vessels with irregular arrangement of moderate number of active fibroblasts, relatively prominent neo-angiogenesis, and slight collagen deposition were detected. In cases that were applied by DAM/ADMSCs, the immature granulation tissue with diffuse infiltration of inflammatory cell with the somewhat same severity was seen compared to previous group. Irregular arrangement of fibroblasts, and new capillary formation, congested vessels, and hemorrhage was also seen in dermal layer with less severity compared to the cases in group with DAM dressing. Fibroblast and few collagen perpendicular to new blood vessel and parallel to wound surface were occupied more in deep dermis. No adnexal re-formation was detected in all cases in this time point. Statistical analysis showed that the amount of

re-epithelization in groups which received DAM and DAM/ADMSCs were more prominent compared to the control group ($P= 0.001$ and $P= 0.005$ respectively) and sulfadiazine-received group ($P= 0.001$ and $P= 0.005$ respectively). No significant differences were detected about the amount of inflammation, granulation bed, angiogenesis, and fibroplasia among different groups in this time point ($P>0.05$).

At day 15, in control group, the newly formed epithelium was partial and was confined to the edge of the wound in most cases. In dermis, an edematous granulation tissue with moderate presence of inflammatory cells particularly neutrophil and lesser amount of mononuclear cells existed (Fig 5.d). In group which received sulfadiazine, the surface was mainly covered by a layer made up of necrotic fibrinoid debris. The hyper granulation tissue was occupied by moderate to severe infiltration of polymorphonuclear cells, and large amount of neo-angiogenesis. Hemorrhage and vascular congestion were also detected in cases in this group (Fig 5.c). Better organization of fibroblasts compared to previous evaluated time point with less deposition of collagen was the other observed event. In cases that received DAM, in most cases partial re-epithelization, denuded area covered by scab and ulcer with bacterial colony were detected in superficial surface. New epithelialization covered about one-half of the wound surface. In dermal layer, edematous granulation tissue with inflammatory cell was noted with lower severity than previous time point. The granulation tissue became more mature in this time. Rich neo-vascularization was observed in the papillary layer (Fig 5.b). In addition, vascular congestion and even hemorrhage, and slight to moderate

deposition of collagen fibers were detected in sub epidermal layer. In cases with DAM/ADMSCs treatment, the surface was mainly filled with necrotic debris and fibrin (crusts); however, re-epithelization was partially at margin (Fig 5.a). In sub epidermal layer, a highly vascularized and proliferating granulation tissue, consisting of more active fibroblasts, mild to moderate amount of collagen fibers, and immature capillaries was detected. The dermis showed mild edema in upper part. An organized hyper granulation tissue formation with moderate amounts of neutrophils, eosinophil, obvious perivascular inflammation, and also, noticeable vascular congestion that was more severe than previous time point but was lesser than cases in DAM group at same time point were detected. Statistical analysis demonstrated that the amount of fibroplasia in group that received DAM and DAM/ADMSCs was higher than group which received sulfadiazine ($P= 0.01$ and $P= 0.01$ respectively).

At day 30, in group that received DAM, microscopic examination revealed the formation of epithelial cells from the edge of skin which invade the area to cover it (Fig 6.b). Dermis cellularity increased mainly due to fibroblasts proliferation and new matrix deposition, also infiltration of inflammatory cells (commonly mononuclear leukocyte type). There was a reduction in the inflammatory process. Vascular granulation tissues dominated by fibroblasts and extensive collagen deposition. At this time point, sub-epithelial healing still continued in all wound sites. Hemorrhage, congestion, neo-vascularization and edema were other detected events in this group with lower severity than two other previous time points. The reticular dermis in the wound healing area had a connective tissue arrangement

similar to the dense ordered with fibroblasts aligned in parallel. In control group, incomplete re-epithelization was detected in the margin of some cases. The severity of congestion, edema, and hemorrhage was mild (Fig 6.d). In Sulfadiazine received-group, the re-epithelization was still incomplete and was seen more in the margins. In dermis, relatively mature hyper granulation tissue with slight superficial edema was seen. The amount of neo-angiogenesis was decreased compared to previous time points. The main portion of dermis showed flabby connective tissue with moderately organized interconnecting collagen fibers running parallel to each (Fig 6.c). In group that received DAM/ADMSCs, in most cases, relatively partial epidermis reformation with moderate thickness in margin was detected. Edema below the epidermis with mild to moderate perivascular mononuclear inflammatory cell infiltrate and also eosinophil existed. Granulation tissue exhibited reduction in the number of vessels mainly in the deeper layers of the wound. Extracellular matrix showed predominance of thick collagen fibers, but still with poor organization (Fig 6.a). In some cases, it was seen that the fibrous collagenous scar tissue was so increased that it filled up the whole crater of the defects. The wound sites of these cases were devoid of the skin adnexa. In this time point, no significant differences were detected about the evaluated criteria among experimental groups ($P>0.05$).

Discussion

The amniotic membrane is a suitable substance for scaffolding in soft tissue engineering. It is the inner layer of the placenta and consists of an epithelial layer, basement membrane and a stroma without vascular

system. This unique structure and other biological and mechanical properties of the AM recommend it as a favorable wound dressing (Ian Goedert Leite Duarte et.al, 2014). AM has many properties such as antibacterial function, low antigenicity, availability and positive effects on cell proliferation and adhesion. The amniotic membrane has been widely applied as a soft tissue scaffold, especially for skin wounds and corneal lesions (Hassan Niknejad et.al, 2008). An ideal scaffold for skin tissue reconstruction requires a biocompatible surface to make a microenvironment for cell proliferation and adhesion. Decellularization of AM not only decreases the immunogenicity of this biological scaffold but also helps the exposure of its extracellular matrix biomolecules that promotes its characteristics (Ian Goedert Leite Duarte et.al, 2014).

ADMSCs are stem cells for autologous transplantation in cell therapy. Availability, great potential of differentiation into a variety of cells, as well as ordinary isolation and culture, have made ADMSCs a common source for cell therapies.

The purpose of our evaluation was to assess the possibility of use and efficacy of decellularized amniotic membrane seeded with autologous adipose derived-mesenchymal stem cells on wound healing of equine distal part of limb. The result of wound geometry demonstrates the appropriate performance of the DAM/ADMSCs in wound contraction, decrease of wound size and re-epithelialization compared with wounds treated with AM or sulfadiazine and no treated wounds. Histopathological findings showed significant differences: re-epithelialization and fibroplasia of wounds covered by DAM/ADMSCs and DAM compared with control and sulfadiazine group.

These results indicate positive effects of using DAM to improve the quality and speed of wound healing. Use of DAM as a scaffold for ADMSCs showed better results. But it seems that the use of DAM/ADMSCs with topical antibiotics (such as sulfadiazine) to reduce the infection, as well as repeating the treatment during the healing process, can lead to better results.

Acknowledgments

The authors acknowledge the support from Institute of Biomedical Research at University of Tehran, as well as Department of pathology of Faculty of Veterinary Medicine for the histological experiments. Also, Mardabad Veterinary Research and Teaching hospital acknowledged for animal studies. The authors thank Mr. Shad for his assistance in the animal surgeries.

Conflicts of interest

The author declared no conflict of interest.

References

- Aggarwal, S., Pittenger, M. F. (2005). Human mesenchymal stem cells modulate allogeneic immune cell responses. *Blood*, 105, 1815–1822. <https://doi.org/10.1182/blood-2004-04-1559> PMID: 15494428
- Arnhold, S. J., Goletz, I., Klein, H., Stumpf, G., Beluche, L. A., Rohde, C., Addicks, K., Litze, L. F. (2007). Isolation and characterization of bone marrow-derived equine mesenchymal stem cells. *Am J Vet Res*, 68, 1095–1105. <https://doi.org/10.2460/ajvr.68.10.1095> PMID: 17916017
- Bischofberger, A. S., Dart, C. M., Perkins, N. R., Dart, A. J. (2011). A preliminary study on the effect of manuka honey on second-intention healing of contaminated wounds on the distal aspect of the forelimbs of horses. *Vet Surg*, 40, 898–902. <https://doi.org/10.1111/j.1532-950X.2011.00886.x> PMID: 22380675
- Bischofberger, A. S., Tsang, A. S., Horadagoda, N., Dart, C. M., Perkins, N. R., Jeffcott, L. B., Jackson, C. J., Dart, A. J. (2015). Effect of activated protein C in second intention healing of equine distal limb wounds: A preliminary study. *Aust Vet J*, 93, 361–366. <https://doi.org/10.1111/avj.12363> PMID: 26412117
- Carter, C. A., Jolly, D. G., Worden, C. E., Hendren, D. G., Kane, C. J. M. (2003). Platelet-rich plasma gel promotes differentiation and regeneration during equine wound healing. *Exp Mol Pathol*, 74, 244–255. [https://doi.org/10.1016/S0014-4800\(03\)00017-0](https://doi.org/10.1016/S0014-4800(03)00017-0) PMID: 12782011
- Choudhery, M. S., Badowski, M., Muise, A., Harris, D. T. (2013). Comparison of human mesenchymal stem cells derived from adipose and cord tissue. *Cytotherapy*, 15, 330–343. <https://doi.org/10.1016/j.jcyt.2012.11.010> PMID: 23318344
- Dart, A. J., Cries, L., Jeffcott, L. B., Hodgson, D. R., Rose, R. J. (2002). Effects of 25% propylene glycol hydrogel (Solugel) on second intention wound healing in horses. *Vet Surg*, 31, 309–313. <https://doi.org/10.1053/jvet.2002.33585> PMID: 12094343
- Dart, A. J., Perkins, N. R., Dart, C. M., Jeffcott, L. B., Canfield, P. (2009). Effect of bandaging on second intention healing of wounds of the distal limb in horses. *Aust Vet J*, 87, 215–218. <https://doi.org/10.1111/j.1751-0813.2009.00428.x> PMID: 19489777
- Edwards-Milewski, M. L., Morello, S. L., Zhao, Q., Mattan-Bell, C. (2016). The effect of intravenous regional perfusion of the distal limb with amikacin sulfate on wounds healing by second intention in horses. *Vet Surg*, 45, 125–132. <https://doi.org/10.1111/vsu.12435> PMID: 26731602
- Elheneidy, H., Omran, E., Halwagy, A., Al-In-

- any, H., Al-Ansary, M., Gad, A. (2016). Amniotic membrane can be a valid source for wound healing. *Int J Womens Health*, 8, 225–231. <https://doi.org/10.2147/IJWH.S96636> PMID: 27390533
- Gharaee-Kermani, M., Phan, S. H. (2001). Role of cytokines and cytokine therapy in wound healing and fibrotic diseases. *Curr Pharm Des*, 7, 1083–103. <https://doi.org/10.2174/1381612013397573> PMID: 11472255
- Gnecchi, M., Zhang, Z., Ni, A., Dzau, V. J. (2008). Paracrine mechanisms in adult stem cell signaling and therapy. *Circ Res*, 103, 1204–1219. <https://doi.org/10.1161/CIRCRESAHA.108.176826> PMID: 19028920
- Gomez, J. H., Schumacher, J., Lauten, S. D., Sartin, E. A., Hathcock, T. L., Swaim, S. F. (2004). Effects of 3 biologic dressings on healing of cutaneous wounds on the limbs of horses. *Can J Vet Res*, 68, 49–55. PMID: 14979435
- Hunt, T. K. (1990). Basic Principles of Wound Healing. *J Trauma Inj Infect Crit Care*, 30, 122–128.
- Ii, G. B., Attinger, C. E. (2006). The basic science of wound healing. *Surg Oxford*, 117, 12–34. <https://doi.org/10.1097/01.prs.0000225430.42531.c2> PMID: 16799372
- Jørgensen, E., Bay, L., Bjarnsholt, T., Bundgaard, L., Sørensen, M. A., Jacobsen, S. (2017). The occurrence of biofilm in an equine experimental wound model of healing by secondary intention. *Vet Microbiol*, 204, 90–95. <https://doi.org/10.1016/j.vetmic.2017.03.011> PMID: 28532812
- Kesting, M. R., Wolff, K. D., Hohlweg-Majert, B., Steinstraesser, L. (2008). The role of allogenic amniotic membrane in burn treatment. *J Burn Care Res*, 29, 907–916. <https://doi.org/10.1097/BCR.0b013e31818b9e40>
- Kim, W. S., Park, B. S., Sung, J. H., Yang, J. M., Park, S. B., Kwak, S. J., Park, J. S. (2007). Wound healing effect of adipose-derived stem cells: A critical role of secretory factors on human dermal fibroblasts. *J Dermatol Sci*, 48, 15–24. <https://doi.org/10.1016/j.jdermsci.2007.05.018> PMID: 17643966
- Lanza, F., Campioni, D., Mauro, E., Pasini, A., Rizzo, R. (2012). Immunosuppressive properties of mesenchymal stromal cells. *Adv. Stem Cell Res*, 281–301. https://doi.org/10.1007/978-1-61779-940-2_15
- Lee, O. K., Kuo, T. K., Chen, W. M., Lee, K. Der, Hsieh, S. L., Chen, T. H. (2004). Isolation of multipotent mesenchymal stem cells from umbilical cord blood. *Blood*, 103, 1669–1675. <https://doi.org/10.1182/blood-2003-05-1670> PMID: 14576065
- Lepault, É., Céleste, C., Doré, M., Martineau, D., Theoret, C. L. (2005). Comparative study on microvascular occlusion and apoptosis in body and limb wounds in the horse. *Wound Repair Regen*, 13, 520–529. <https://doi.org/10.1111/j.1067-1927.2005.00073.x> PMID: 16176461
- Lo, V., Pope, E. (2009). Amniotic membrane use in dermatology. *Int J Dermatol*, 48, 935–940. <https://doi.org/10.1111/j.1365-4632.2009.04173.x> PMID: 19702975
- de Mattos Carvalho, A., Alves, A. L. G., Golim, M. A., Moroz, A., Hussni, C. A., de Oliveira, P. G. G., Deffune, E. (2009). Isolation and immunophenotypic characterization of mesenchymal stem cells derived from equine species adipose tissue. *Vet Immunol Immunopathol*, 132, 303–306. <https://doi.org/10.1016/j.vetimm.2009.06.014> PMID: 19647331
- May, S. R. (1991). The effects of biological wound dressings on the healing process. *Clin Mater*, 8, 243–249. [https://doi.org/10.1016/0267-6605\(91\)90037-G](https://doi.org/10.1016/0267-6605(91)90037-G) PMID: 10149129
- Mohan, R., Bajaj, A., Gundappa, M. (2017). Hu-

- man amnion membrane: potential applications in oral and periodontal field. *J Int Soc Prev Community Dent*, 7, 15–21. https://doi.org/10.4103/jispcd.JISPCD_359_16 PMID: 28316944
- Ono, I., Yamashita, T., Hida, T., Jin, H. Y., Ito, Y., Hamada, H., Akasaka, Y., Ishii, T., Jimbow, K. (2004). Local administration of hepatocyte growth factor gene enhances the regeneration of dermis in acute incisional wounds. *J Surg Res*, 120, 47–55. <https://doi.org/10.1016/j.jss.2003.08.242> PMID: 15172189
- Peng, L., Jia, Z., Yin, X., Zhang, X., Liu, Y., Chen, P., Ma, K., Zhou, C. (2008). Comparative analysis of mesenchymal stem cells from bone marrow, cartilage, and adipose tissue. *Stem Cells Dev*, 17, 761–774. <https://doi.org/10.1089/scd.2007.0217> PMID: 18393634
- Ramakrishnan, K. M., Jayaraman, V. (1997). Management of partial-thickness burn wounds by amniotic membrane: A cost-effective treatment in developing countries. *Burns*, 23, 33–36. [https://doi.org/10.1016/S0305-4179\(96\)00099-X](https://doi.org/10.1016/S0305-4179(96)00099-X)
- Ryan, J. M., Barry, F., Murphy, J. M., Mahon, B. P. (2007). Interferon- γ does not break, but promotes the immunosuppressive capacity of adult human mesenchymal stem cells. *Clin Exp Immunol*, 149, 353–363. <https://doi.org/10.1111/j.1365-2249.2007.03422.x> PMID: 17521318
- Sai K, P., Babu, M. (2000). Collagen based dressings — a review. *Burns*, 26, 54–62. [https://doi.org/10.1016/S0305-4179\(99\)00103-5](https://doi.org/10.1016/S0305-4179(99)00103-5)
- Schwartz, A. J., Wilson, D. A., Keegan, K. G., Ganjam, V. K., Sun, Y., Weber, K. T., Zhang, J. (2002). Factors regulating collagen synthesis and degradation during second-intention healing of wounds in the thoracic region and the distal aspect of the forelimb of horses. *Am J Vet Res*. 63. 1564–1570. <https://doi.org/10.2460/ajvr.2002.63.1564> PMID: 12428668
- Singer, A. J., Clark, R. A. F. (1999). Cutaneous Wound Healing. *N Engl J Med* 341, 738–746.
- Singh, R., Chouhan, U. S., Purohit, S., Gupta, P., Kumar, P., Kumar, A., Chacharkar, M. P., Kachhawa, D., Ghiya, B. C. (2004). Radiation processed amniotic membranes in the treatment of non-healing ulcers of different etiologies. *Cell Tissue Bank*, 5, 129–134. <https://doi.org/10.1023/B:CATB.0000034077.05000.29> PMID: 15241010
- Sinno, H., Prakash, S. (2013). Complements and the Wound Healing Cascade: An Updated Review. *Plast Surg Int*, 2013, 1–7. <https://doi.org/10.1155/2013/146764> PMID: 23984063
- Soo, C., Sayah, D. N., Zhang, X., Beanes, S. R., Nishimura, I., Dang, C., Freymiller, E., Ting, K. (2002). The identification of novel wound-healing genes through differential display. *Plast Reconstr Surg*, 110, 787–97; discussion 798–800. PMID: 12172140
- De Souza, M. V., Silva, M. B., De Oliveira Pinto, J., De Souza Lima, M. B., Crepaldi, J., Lopes, G. F. M., Dos Santos, H. B., De Azambuja Ribeiro, R. I. M., Thomé, R. G. (2015). Immunohistochemical expression of collagens in the skin of horses treated with leukocyte-poor platelet-rich plasma. *Biomed Res Int*, 2015. <https://doi.org/10.1155/2015/893485> PMID: 26236743
- Spaas, J. H., Broeckx, S., Van De Walle, G. R., Poletini, M. (2013). The effects of equine peripheral blood stem cells on cutaneous wound healing: A clinical evaluation in four horses. *Clin Exp Dermatol*, 38, 280–284. <https://doi.org/10.1111/ced.12068> PMID: 23517358
- Theoret, C. L., Barber, S. M., Moyana, T. N., Gordon, J. R. (2001). Expression of transforming growth factor β 1, β 3, and basic fi-

broblast growth factor in full-thickness skin wounds of equine limbs and thorax. *Vet Surg*, 30, 269–277. <https://doi.org/10.1053/jvet.2001.23341> PMID: 11340559

Theoret, C. L., Olutoye, O. O., Parnell, L. K. S., Hicks, J. (2013). Equine exuberant granulation tissue and human keloids: A comparative histopathologic study. *Vet Surg*, 42, 783–789. <https://doi.org/10.1111/j.1532-950X.2013.12055.x> PMID: 24015864

Theoret, C. L., Wilmink, J. M. (2013). Aberrant wound healing in the horse: Naturally occurring conditions reminiscent of those observed in man. *Wound Repair Regen*, 21, 365–371. <https://doi.org/10.1111/wrr.12018> PMID: 23441750

Tracey, A. K., Alcott, C. J., Schleining, J. A., Safayi, S., Zaback, P. C., Hostetter, J. M., Reinertson, E. L. (2014). The effects of Topical oxygen therapy on equine distal limb dermal wound healing. *Can Vet J*, 55, 1146–1152. PMID: 25477541

Tyszkiewicz, J. T., Uhrynowska-Tyszkiewicz, I. A., Kaminski, A., Dziedzic-Goclawska, A. (1999). Amnion allografts prepared in the Central Tissue Bank in Warsaw. *Ann Transplant*, 4, 85–90. PMID: 10853790

Wilmink, J. M., Herten, J. van, Weeren, P. R. van, Barneveld, A. (2010). Retrospective study of primary intention healing and sequestrum formation in horses compared to ponies under clinical circumstances. *Equine Vet J*, 34, 270–273. <https://doi.org/10.2746/042516402776186047> PMID: 12108745

ارزیابی اثرات سلول‌های بنیادی مزانشیمی مشتق از بافت چربی کشت داده شده بر روی پرده آمیوتیک آسلولار در التیام زخم قسمت‌های انتهایی اندام در اسب

باسم کاظم خشجوری^۱، سید مهدی قمصری^{۱،۲}، محمد مهدی دهقان^{۱،۲}، سعید فرزاد مهاجری^{۱،۲}، حسین غلامی^۲، خانه گلشاهی^۳

^۱گروه جراحی و رادیولوژی، دانشکده دامپزشکی دانشگاه تهران، تهران، ایران

^۲پژوهشکده تحقیقات زیست پزشکی، دانشگاه تهران، تهران، ایران

^۳مرکز تحقیقات ریزفناوری زیستی، پژوهشکده فناوری‌های نوین علوم پزشکی جهاد دانشگاهی - ابن سینا، تهران، ایران

(دریافت مقاله: ۲۹ خرداد ماه ۱۳۹۷، پذیرش نهایی: ۲۰ شهریور ماه ۱۳۹۷)

چکیده

زمینه مطالعه: در زخم‌های اندام حرکتی اسب، به علت خون‌رسانی ضعیف‌تر و سطح پایین اکسیژن خون در بخش‌های تحتانی اندام، عدم تعادل فاکتورهای رشد مرتبط با التیام زخم در روند التیام تأثیر منفی می‌گذارد. پرده آمیوتیک آسلولار به علت خواص زیستی و مکانیکی خاص، با ایجاد شرایط مناسب روند التیام به عنوان یک داربست برای درمان زخم استفاده می‌شود. **هدف:** این تحقیق به منظور ارزیابی اثر سلول‌های بنیادی مشتق از چربی کشت داده شده روی پرده آمیوتیک آسلولار در التیام زخم‌های قسمت تحتانی اندام حرکتی اسب، انجام پذیرفت.

روش کار: نمونه چربی از ناحیه قاعده دم اسب در شرایط آسپتیک اخذ و بلافاصله به آزمایشگاه انتقال داده شد. سلول‌ها با استفاده از روش مکانیکی و هضم آنزیمی جداسازی و پاساژ داده شدند و در مرحله بعد روی پرده آمیوتیک آسلولار کشت داده شدند. سپس پرده آمیوتیک آسلولار واجد سلول‌های بنیادی مشتق از چربی به زخم‌های تمام ضخامت ۳×۲ سانتی متری ایجاد شده در ناحیه متاتارس اندام حرکتی به صورت پوشش روی زخم قرار گرفت. زخم‌ها به چهار گروه تقسیم شدند: گروه اول درمان: پرده آمیوتیک آسلولار واجد سلول‌های بنیادی مشتق از چربی، گروه دوم درمان: پرده آمیوتیک آسلولار، گروه سوم درمان: سولفادیازین، گروه چهارم: شاهد و بدون درمان. تصویربرداری دیجیتال از زخم‌ها در هر تغییر پانسمان و اخذ نمونه‌های بیوپسی به منظور ارزیابی هیستوپاتولوژی در روزهای ۵، ۱۵ و ۳۰ پس از درمان انجام گرفت.

نتایج: در بررسی‌های ژئومتری تصاویر زخم‌ها، گروه درمان با پرده آمیوتیک آسلولار واجد سلول‌های بنیادی به طور معنی‌داری در شاخص‌های بازسازی بافت پوششی و اندازه و جمع شدگی زخم، در مقایسه با سه گروه دیگر، وضعیت بهتری را نشان داد ($P < 0/05$). در ارزیابی‌های میکروسکوپی، بازسازی بافت پوششی در روز ۵ درمان زخم، گروه‌های درمان با پرده آمیوتیک آسلولار واجد سلول‌های بنیادی و پرده آمیوتیک آسلولار به تنهایی، به طور معنی‌داری بیشتر از گروه کنترل بود ($P < 0/05$). میزان فیبروپلازی در روز ۱۵ در دو گروه درمان با پرده آمیوتیک آسلولار (با و بدون سلول بنیادی مزانشیمی) در مقایسه با گروه درمان با سولفادیازین اختلافی معنی‌دار را نشان می‌داد ($P < 0/05$).

نتیجه گیری نهایی: این نتایج نشان دهنده اثرات مثبت استفاده از پرده آمیوتیک آسلولار برای بهبود کیفیت و سرعت بهبود زخم است. استفاده از پرده آمیوتیک آسلولار به همراه سلول‌های بنیادی مزانشیمی مشتق از چربی نتایج بهتری نشان می‌دهد.

واژه‌های کلیدی:

پرده آمیوتیک، قسمت انتهایی اندام، اسب، سلول‌های بنیادی مزانشیمی، التیام زخم