

Ultrasonographic Liver Findings in a Sheep Flock Involved in Chronic Fasciolosis

Siamak Alizadeh¹, Tohid Mohammadi²

¹Department of Clinical Sciences, Faculty of Veterinary Medicine, Urmia Branch, Islamic Azad University, Urmia, Iran

²Department of Pathobiology, Faculty of Veterinary Medicine, Urmia Branch, Islamic Azad University, Urmia, Iran

Abstract:

BACKGROUND: *Fasciola hepatica* is a genus of the trematodes which mainly affects the liver of sheep and these livestock are accidentally infected by eating plants or drinking water contaminated with the metacercariae of this parasite. These parasites can cause considerable economic damage by destroying the liver and bile ducts.

OBJECTIVES: The aim of this study was to evaluate the role of ultrasonographic diagnosis in chronic hepatic fasciolosis of sheep and to provide ultrasonography views of fasciolosis in sheep's liver.

METHODS: In this cross-sectional study, 256 sheep of the Makoei breed, including 130 male (50.8%) and 126 female (49.2%) with diagnosis of chronic fasciolosis confirmed by the appearance of fluke eggs in feces and using enzyme-linked immunosorbent assay (ELISA) were referred to the Department of Radiology and Ultrasonography, Doppler ultrasound was performed. Average age of sheep was 2.1 years (minimum age 7 months and maximum age 6 years). Data were analyzed by SPSS software (version 11.5) and the statistical test was chi-square test. P value less than 0.05 was considered significant.

RESULTS: In the results, 55.6% of sheep had ascites in the abdominal cavity and in 5.7% and 11.3%, bile ducts and gallbladder were affected, respectively, and in 4.8% of sheep both the liver and the bile ducts were involved. In 22.6% of sheep, there was no abnormal finding in ultrasound. The most common site of injury was in the posterior part of the right lobe of liver. There was no significant difference between the place of involvement in the liver, age and sex of the patients.

CONCLUSIONS: According to this study, ultrasonography can play an important role in the diagnosis and follow up of sheep's chronic fasciolosis treatment.

Keywords:

Diagnosis, Fasciolosis, Liver, Sheep, Ultrasonography

Correspondence

Siamak Alizadeh, Department of Clinical Sciences, Faculty of Veterinary Medicine, Urmia Branch, Islamic Azad University, Urmia, Iran

Tel: +98(44) 33461731, Fax: +98(44) 33461731, Email: s_alizadeh01@yahoo.com

Received: 4 June 2018

Accepted: 1 October 2018

Copyright © 2018, Iranian Journal of Veterinary Medicine. This is an open-access article distributed under the terms of the Creative Commons Attribution-noncommercial 4.0 International License which permits copy and redistribute the material just in noncommercial usages, provided the original work is properly cited.

How to Cite This Article

Alizadeh, S., Mohammadi, T. (2019). Ultrasonographic Liver Findings in a Sheep Flock Involved in Chronic Fasciolosis. *Iran J Vet Med*, 13(1), 37-43. doi: 10.22059/ijvm.2018.254143.1004888

Introduction

Fasciola hepatica is one of the common causes of the disease in ruminants. Infection of cattle and sheep occurs by ingestion of the parasite infection stage in wet rangelands and areas below sea level. Symptoms of fasciolosis include anemia, weight loss and submandibular edema, and sometimes diarrhea. Diagnosis of liver contamination with this parasite is possible via observing yellow-brown eggs of the parasite in feces. One of the consequences of this parasite is the destruction of the liver tissue due to the migration of parasite larvae and the reduction of oxygen in these areas. This parasite causes a variety of clinical symptoms in sheep, which may affect the hematopoietic system, the liver, the lungs and the intestines. *Fasciola hepatica* is one of the trematodes which mainly affect the liver of sheep, and these livestock are accidentally infected by eating plants or drinking contaminated water with the metacercariae of this parasite (Mezo et al., 2004). The penetration of the worm into the intestinal wall leads to local bleeding and inflammation, then this parasite brings itself to the liver parenchyma through the peritoneum within 4-6 weeks, causing severe parenchymal degeneration and inflammation. Sometimes worms die and form cavities filled with necrotic holes, which subsequently replace scar tissue in that area (Keiser et al., 2010). Parasites often infect the liver parenchyma and never get bile ducts, However, in some cases, these parasites are also carried to the bile ducts and gallbladder and cause inflammatory reactions and dilatation of these ducts (Kaya et al., 2011). In some rare cases, immature worms migrating from the intestine to the liver may divert their pathways and

cause Ectopic Fasciolosis and affect other parts of the body including abdominal wall, pancreas, lungs, pleural space (Moazeni and Ahmadi 2016).

There are several methods for diagnosis of fasciolosis, including direct parasitological methods, indirect immunological tests, or other non-invasive methods. It is not helpful to find egg parasites in the feces at the beginning of the disease because it takes at least 4 months for the worm to mature and lay its first eggs. On the other hand, due to the frequency of laying eggs, repetition of these tests is necessary. In ectopic infections, fecal testing cannot be worthwhile. Immunological methods are mainly based on antibody measurements, and few of these tests detect antigens in the bloodstream or the antigen-antibody complexes (Keiser et al., 2012). Since clinical and laboratory findings of the fasciola may be mistaken for many other diseases, sometimes it is necessary to use other methods such as diagnostic imaging to confirm the diagnosis and evaluate the response to treatment (Scott et al., 2005). From diagnostic imaging methods, ultrasound is a non-invasive, accessible and inexpensive method for detecting injuries due to the presence of this worm in the bile ducts and may exhibit a worm-shaped structure that does not have acoustic shadowing (Martínez-Valladares et al., 2010). In ultrasonography local and stained echogenicity, liver abscess, hypoechoic or hyperechoic nodules that have spread to the thickened capsule of the liver, ecogenic mass in the gallbladder, ecogenic damages under the capsule of the liver and dilatation of the internal and external biliary ducts of the liver may be seen (Gonzalo-Orden et al., 2003). In some studies,

ultrasonography has been used to evaluate the treatment process of sheep's fasciolosis (Winkelhagen et al., 2012).

To our knowledge, some studies have exhibited findings as diagnostic imaging and sonography in some animal diseases, but this is the first study of ultrasonographic analysis of sheep flock with naturally infected fasciolosis and we intend to introduce the possibility of ultrasonography technique in non-invasive and close to accurate diagnosis of fasciolosis.

Materials and Methods

In this cross-sectional study, 256 sheep of the Makoei breed, including 130 male (50.8%) and 126 female (49.2%) with diagnosis of chronic fasciolosis were confirmed by appearance of fluke eggs in feces and, using enzyme-linked immunosorbent assay (ELISA) were referred to the Department of Radiology and Ultrasonography, Faculty of Veterinary Medicine, Islamic Azad University Urmia. Average age of sheep was 2.1 years (minimum age 7 months and maximum age 6 years). After obtaining basic information including age and sex, Doppler ultrasound was performed on the liver of each sheep with dorsal and left lateral recumbency and for each ultrasonography, at least 5 and maximum 15 min, time were considered. EUB-8500 XP ultrasound device (Hitachi Medical Corporation, Tokyo, Japan) and a convex probe with a frequency of 3.5 MHz were used for ultrasonography. Data after collecting were analyzed by SPSS software (version 11.5) and the statistical test was chi-square test. P value less than 0.05 was considered significant.

Results

According to the results, 55.6% of sheep

Table 1. The abundance of patients based on age and sex.

Total	Female	Male	Sex
Number (%)	Number (%)	Number (%)	Age (year)
106(42.7)	74(28.6)	40(14.1)	2>
113(45.6)	81(32.7)	32(12.9)	2-4
29(11.7)	18(7.3)	11(4.4)	4<
256(100)	173(68.6)	83(31.4)	Total

had ascites in the liver parenchyma along with subcapsular localized, small, confluent, multiple hypoechoic nodules with poorly defined borders (Fig/ 1) and in 5.7% and 11.3%, bile ducts and gallbladder were affected, respectively, and in 4.8%, both the liver and the bile ducts were involved (Figs. 2-3). In Table 1, the abundance of patients is shown by age and sex, and in Table 2, the types of ultrasonographic findings are given. In cases where bile ducts were involved, 11 sheep (61.1%) had duct dilatation without presence of *Fasciola* and 7 sheep (38.9%) had duct dilatation with parasites. There was no statistically significant relationship between sex and region of liver that was involved (Table 3). Also, there was no statistically significant relationship between age and region of liver that was involved (Table 4). The most common site of injury was in the posterior part of the right lobe liver (Chart 1).

Discussion

Sheep fasciolosis is a parasitic infection of the liver which, according to clinical symptoms is considered to have differential diagnosis with some other liver diseases and its diagnosis, especially of parenchymal tumors of the liver, gallbladder and biliary tract is important. In ultrasonography, small hypoechoic nodules, which are often environments and after treatment their size is reduced, suggests a liver fasciolosis (Martínez-Valladares et al., 2010). The ex-

Table 2. Distribution of ultrasound findings in patients with fasciolysis.

Ultrasound Finding	The abundance	Number	Percentage
Parenchyma involvement		112	45.2
Bile duct involvement		18	7.3
Gallbladder involvement		34	13.7
Simultaneous involvement of the liver and biliary tract		12	4.8
Non-involvement of liver and bile duct		80	29
Total		256	100

Table 3. Distribution of affected area based on the gender of patients.

Involved area	Parenchyma		Bile duct		Gallbladder		Simultaneous involvement of the liver and biliary tract		Total	
	Number	Percent	Number	Percent	Number	Percent	Number	Percent	Number	Percent
Male	7	65	7	12.2	9	15.8	4	7	57	100
Female	11	63	11	9.2	25	21	8	6.8	119	100
Total	18	63.6	18	10.2	34	19.4	12	6.8	176	100

Table 4. Distribution of age patients based on the affected area.

Involved area	Parenchyma		Bile duct		Gallbladder		Simultaneous involvement of the liver and biliary tract		Total	
	Number	Percent	Number	Percent	Number	Percent	Number	Percent	Number	Percent
Age(years)										
2>	43	56.6	10	13.2	17	22.4	6	7.8	76	100
2-4	56	69.1	7	8.6	14	17.4	4	4.9	81	100
4<	13	68.4	1	5.3	3	15.9	2	10.4	19	100
Total	112	63.6	18	10.2	34	19.4	12	6.8	176	100

tent of hypoechoic lesions is often unclear and occasionally echogenic granuloma, fluid accumulation in the subcapsule, abscess and the discontinuous echogenic lines are seen that should differentiate them from secondary contamination of the liver with metastatic and primary malignant and benign tumors of the liver. The involvement of bile ducts in different forms was present in our study. In some cases there was only a common bile duct dilatation without parasites inside it and in others, there was a dilatation of the common bile duct with parasite inside it that was seen as echogenic focal and it did not have an acoustic shadowing. The acoustic shadowing distinguishes the

parasites from the stone. It is necessary to point out that sometimes the cholesterol polyps and adenomatous polyps are seen as echogenic focal that have no acoustic shadowing, where the mobility of the parasite is a good distinction, but in these cases, it is also necessary to help with other clinical and laboratory findings. In this study, there was no racial susceptibility to infections caused by trematode and there was no increase in the prevalence of other variables such as sex and age. Trematode infections occur in all age groups, although intestinal trematode infections and schistosomiasis are more common in livestock with a lower age, but their prevalence is not higher (Mc-

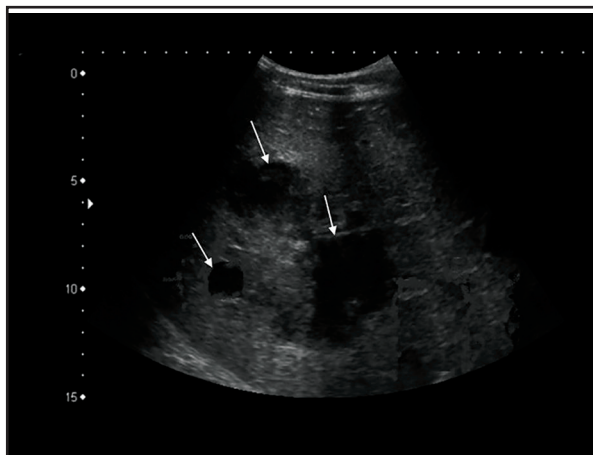


Figure 1. In this transverse sonogram, there are small, confluent, multiple hypoechoic nodules (arrows) with poorly defined borders.

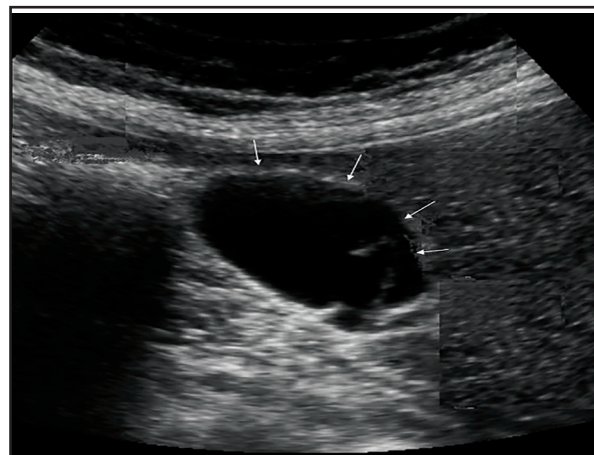


Figure 2. The presence of Fasciola with a floating echo (arrows) which does not have acoustic shadowing is evident.

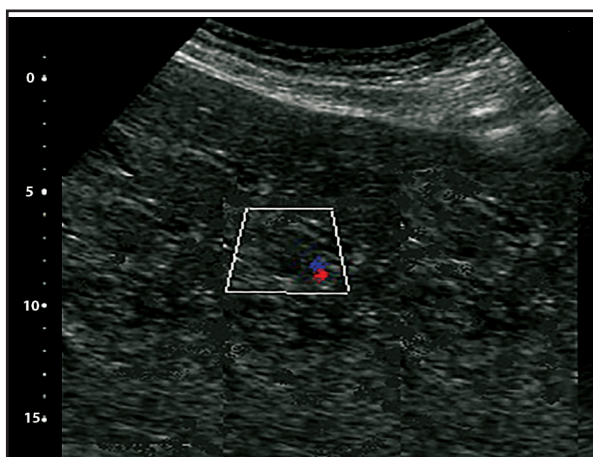


Figure 3. Color Doppler sonogram of liver tissue with hepatic fasciolosis. Parenchymal lesions have no vascularity.

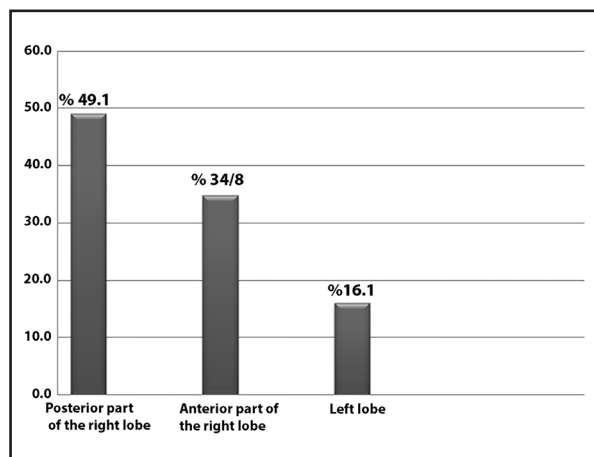


Chart 1. Distribution of the region of the liver that is damaged by the parasite.

Manus and Dalton 2006). In our study, in relation to the area involved in liver and biliary tract, there was no difference between age groups and the sex of livestock, In other words, the age and sex do not seem to be an effective factor in the type of infection. In this study, in 7 out of 18 patients with common biliary duct dilatation, fasciola was not seen (38.8%) and 11 sheep (61.2%) had this dilation along with fasciola.

Conclusion: It is suggested that in order to prevent high diagnostic costs and prevent further damage to the sheep in endemic areas of this disease, serological tests should

be used before any parasite examination begins. According to our study, the most common site of fasciolosis infection was in the posterior right lobe of the liver and it should be noted that ultrasound should not be the first step in examining this parasitic infection, but since it is easy to use, cost effective and non-invasive, and there is no risk of ionizing radiation, it can play an important role in the diagnosis and follow up of sheep's chronic fasciolosis treatment. We recommend that similar studies be performed in endemic areas of the disease in order to obtain more complete information

on the different aspects of ultrasonography of this parasitic infection.

Acknowledgments

This study was supported by Faculty of Veterinary Medicine, Urmia Branch, Islamic Azad University, Urmia, Iran.

Conflicts of interest

The author declared no conflict of interest.

References

- Arora, D., Arorab, B. (2002). Trematodes or Flukes. Medical Parasitology. CBS publishers & distributors, 64(5), 562-566.
- Ferre, I., Ortega Mora, L.M., Rojo Vázquez, F.A. (1997). Sonography during subclinical *Fasciola hepatica* infection in sheep. *Vet Parasitol*, 68(3), 261-7.
- Gonzalo Orden, M., Millán, L., Alvarez, M., Sánchez Campos, S., Jiménez, R., González Gallego, J. (2003). Diagnostic imaging in sheep hepatic Fasciolosis: ultrasound, computed tomography and magnetic resonance findings. *Parasitol Res*, 90(5), 359-64.
- Kaya, M., Beştaş, R., Çetin, S. (2011). Clinical presentation and management of *Fasciola hepatica* infection: single-center experience. *World journal of gastroenterology*. WJ.G, 17(44), 4899. PMID: 22171131
- Keiser, J., Veneziano, V., Rinaldi, L., Mezzino, L., Duthaler, U., Cringoli, G. (2010). Anthelmintic activity of artesunate against *Fasciola hepatica* in naturally infected sheep. *Res Vet Sci*, 88(1), 107-10. <https://doi.org/10.1016/j.rvsc.2009.05.007>
- Lotfy, WM., Hillyer, G.V. (2003). *Fasciola* species in Egypt. *Exp Pathol Parasitol-Sofia*, 6(2), 1-9.
- Martínez Pérez, J., Robles Pérez, D., Rojo Vázquez, F., Martínez Valladares, M. (2012). Comparison of three different techniques to diagnose *Fasciola hepatica* infection in experimentally and naturally infected sheep. *Vet Parasitol*, 190(1-2), 80-6. <https://doi.org/10.1016/j.vetpar.2012.06.002>
- Martínez Valladares, M., Del Rosario, Famularo, M., Fernández Pato, N., Castañón Ordóñez, L., Cordero Pérez, C., Rojo Vázquez, F.A. (2010). Efficacy of nitroxylnil against *Fasciola hepatica* resistant to triclabendazole in a naturally infected sheep flock. *Parasitol Res*, 107(5), 1205-11.
- McManus, D., Dalton, J. (2006). Vaccines against the zoonotic nematodes *Schistosomaja ponicum*, *Fasciola hepatica* and *Fasciolagigantica*. *Parasitology*, 133(S2), S43-S61. <https://doi.org/10.1017/S0031182006001806>
- Mezo, M., González Warleta, M., Carro, C., Ubeira, F.M. (2004). An ultrasensitive capture ELISA for detection of *Fasciola hepatica* coproantigens in sheep and cattle using a new monoclonal antibody (MM3). *J Parasitol*, 90(4), 845-52. <https://doi.org/10.1645/GE-192R>
- Moazeni, M., Ahmadi, A. (2016). Controversial aspects of the life cycle of *Fasciola hepatica*. *Exp Parasitol*, 169, 81-9. <https://doi.org/10.1016/j.exppara.2016.07.010>
- Scott, P., Sargison, N., Macrae, A., Rhind, S. (2005). An outbreak of subcutaneous fasciolosis in Soay sheep: ultrasonographic biochemical and histological studies. *Vet J*, 170(3), 325-31. <https://doi.org/10.1016/j.tvjl.2004.08.010>
- Winkelhagen, A.J., Mank, T., Vries, P.J., Soetekouw, R. (2012). Apparent triclabendazole-resistant human *Fasciola hepatica* infection, the Netherlands. *Emerg Infect Dis*, 18(6), 1028. PMID: 22607719

یافته‌های اولتراسونوگرافی کبد در یک گله گوسفند مبتلا به فاسیولوز مزمن

سیامک علیزاده^۱ توحید محمدی^۲

^۱گروه علوم درمانگاهی، دانشکده دامپزشکی، واحد ارومیه، دانشگاه آزاد اسلامی، ارومیه، ایران
^۲گروه پاتوبیولوژی، دانشکده دامپزشکی، واحد ارومیه، دانشگاه آزاد اسلامی، ارومیه، ایران

(دریافت مقاله: ۴ تیر ماه ۱۳۹۷، پذیرش نهایی: ۹ مهر ماه ۱۳۹۷)

چکیده

زمینه مطالعه: فاسیولوز لاهپاتیک‌گونه‌ای از ترماتودهایی است که عمدتاً بر کبد گوسفندان تأثیر گذاشته و این دام‌ها به طور اتفاقی با خوردن گیاهان یا مواد آشامیدنی آلوده به متاسر کر این انگل مبتلا می‌شوند. این انگل‌ها با تخریب بافت‌های کبدی و مجاری صفراوی می‌توانند باعث خسارات اقتصادی زیادی شوند.

هدف: هدف از این مطالعه ارزیابی نقش تشخیصی اولتراسونوگرافی در فاسیولوز کبدی گوسفندان و ارائه نماهای اولتراسونوگرافی فاسیولوز در کبد می‌باشد.

روش کار: در این مطالعه مقطعی-توصیفی، ۲۵۶ رأس گوسفند از نژاد ماکویی شامل ۱۳۰ رأس گوسفند نر (۵۰/۸٪) و ۱۲۶ رأس گوسفند ماده (۴۹/۲٪) که با آزمایشات شناورسازی مدفوع و دیدن تخم انگل‌ها و آزمایشات الایزا وجود بیماری فاسیولوز در آن‌ها تأیید شده بود به بخش رادیولوژی و سونوگرافی ارجاع شده و تحت سونوگرافی داپلر قرار گرفتند. میانگین سن گوسفند‌های مورد مطالعه ۲/۱ سال (حداقل سن ۷ ماه و حداکثر سن ۶ سال) بود. داده‌ها پس از جمع‌آوری با نرم افزار آماری SPSS (ویراست ۱/۱/۵) پردازش گردیدند و آزمون آماری مورد استفاده نیز آزمون آماری کای اسکور بود. P کمتر از ۰/۰۵ معنی دار در نظر گرفته شد.

نتایج: در نتایج به دست آمده ۵۵/۶٪ از گوسفندان آسیب در محوطه شکمی داشته و به ترتیب ۵/۷٪، ۱۱/۳٪ و ۴/۸٪ از آن‌ها ابتلای مجاری صفراوی، کیسه صفرا و ابتلای همزمان کبد و مجاری صفراوی داشتند و در ۲۲/۶٪ گوسفند‌ها هیچ یافته غیر عادی در سونوگرافی دیده نشد. شایع‌ترین محل آسیب، بخش خلفی لوب راست کبد بود. بین محل درگیری، سن و جنس بیماران تفاوت آماری معنی‌داری به دست نیامد.

نتیجه‌گیری نهایی: بر اساس این مطالعه اولتراسونوگرافی می‌تواند نقش مهمی در تشخیص و پیگیری درمان فاسیولوز گوسفندی داشته باشد.

واژه‌های کلیدی:

تشخیص، فاسیولوز، کبد، گوسفند، اولتراسونوگرافی