

# Hypothyroidism Effects on the Morpho-Histometrical Features of Testes in Adult Rats

Hero Sheikholeslami<sup>1</sup>, Farzam Sheikhzadeh Hesari<sup>1</sup>, Seyed Mahdi Banan Khojasteh<sup>1</sup>, Nazli Khajehnasiri<sup>2</sup>, Ali Dastranj<sup>3</sup>, Hassan Morovvati<sup>4</sup>

<sup>1</sup>Department of Animal Biology, Faculty of Natural Sciences, University of Tabriz, Tabriz, Iran

<sup>2</sup>Department of Biological Sciences, Faculty of Basic Sciences, Higher Education Institute of Rab-Rashid, Tabriz, Iran

<sup>3</sup>Women's Reproductive Health Research Center, Tabriz University of Medical Sciences, Tabriz, Iran

<sup>4</sup>Department of Basic Sciences, School of Veterinary Medicine, University of Tehran, Tehran, Iran

## Abstract:

**BACKGROUND:** Up until now, the effect of thyroid hormones on the male reproductive organ, after puberty, is not well understood.

**OBJECTIVES:** In the present study, the morpho-histometrical effects of thyroid hormone deficiency on the adult-male rat reproductive organs were investigated.

**METHODS:** Thirty adult male rats were randomly divided into three groups (n=10): control, hypothyroid, and hypothyroid which receives Levothyroxine. After 4-months we examined the number of spermatogonia cells, primary spermatocytes, and Sertoli cells, as well as the seminiferous tubules epithelium thickness, area of seminiferous tubules, and the diameter and thickness of testis artery walls.

**RESULTS:** No significant difference was observed between the hypothyroid and control rats in terms of the area of seminiferous tubules, the number of spermatogonia cells, primary spermatocytes, and Sertoli cells. Moreover, the epithelium thickness of seminiferous tubules and the diameter and thickness of artery walls were significantly decreased in hypothyroid group compared with the control rats.

**CONCLUSIONS:** These observations are consistent with the hypothesis that hypothyroidism can affect the male fertility and declare that it may influence male reproduction by reducing the testis blood flow.

## Keywords:

Artery, Hypothyroidism, Male reproductive cells, Seminiferous tubules

## Correspondence

Farzam Sheikhzadeh hesari, Department of Animal Biology, Faculty of Natural Sciences, University of Tabriz, Tabriz, Iran

Tel: +98(41) 33340081, Fax: +98(41) 33340800, Email: Fsheikhzadeh@tabrizu.ac.ir

Received: 23 July 2018

Accepted: 15 October 2018

Copyright © 2018, Iranian Journal of Veterinary Medicine. This is an open-access article distributed under the terms of the Creative Commons Attribution-noncommercial 4.0 International License which permits copy and redistribute the material just in noncommercial usages, provided the original work is properly cited.

## How to Cite This Article

Sheikholeslami, H., Sheikhzadeh, F., Banan Khojasteh, S., Khajehnasiri, N., Dastranj, A., Morovvati, H. (2019). Hypothyroidism effects on the morpho-histometrical features of testes in adult rats. *Iran J Vet Med*, 13(1), 69-77. doi: 10.22059/ijvm.2018.260974.1004909

## Introduction

Thyroid, as one of the most important endocrine glands, in addition to the development of the physiologic function, influences all of the tissues, especially the male reproductive tract. (et al., 2014). The thyroid gland secretes two hormones, T3 and T4 (Jannini et al., 1995), which apply the genomic and non-genomic effects, respectively, by binding to the thyroid receptors (TRs) in the target cells nucleus, cell surface, cytoplasm, and cell organelles such as mitochondria (Basset et al., 2003). TRa1 and TRb1 (thyroid receptors) have been identified in the mammals' testicular tissue Buzzard et al., 2000), which are expressed in Sertoli, Leydig, and germ cells (Romano et al., 2017). Previous reports have shown that the thyroid hormones control the proliferation and differentiation of male reproductive system cells by altering the thyroid receptor gene expression (Krajewska-kulak et al., 2013). T3 stops the proliferation of the Sertoli cells during the development and maturation periods (Anbalagan et al., 2010 & Buzzard et al., 200) and is considered as one of the factors which initiate the differentiation of the Leydig cells with unknown mechanism (Singh et al., 2012).

Compared to Leydig and germ cells, matured Sertoli cells express a large number of thyroid receptors, especially TRa1, (Wagner et al, 2009 & Orth et al., 1998) and they are anatomically juxtaposed to spermatogonia germ cells and support the spermatogenesis process (Taha et al., 2012). Thus, it seems that the thyroid receptors located on the Sertoli cells mediate the major thyroid effects on mammalian testis (Orth et al., 1998).

Previous studies have reported that thyroid disorders can change the gonadal

function and have negative effects on the hypothalamic–pituitary–gonadal axis, normal morphology of the reproductive system cells, and reproduction (Krassas et al., 2010). Kumar et al. (2014) reported that the normal function of thyroid is a prerequisite for normal function of the male genital tract, and thyroid disorders endanger the men's sexual health( Kumar et al., 2014). Other researchers have also reported that hypothyroidism in men drastically affects the sperms' morphology, besides reducing their number and ability( Kumar et al., 2014 & Krassas et al., 2008 ); furthermore, it should be noted that the thyroid hormones increase the blood supply by increasing the production of nitric oxide and increasing the diameter of vessels in several organs( Cai et al., 2015), so that the genital tissues are probably affected in the same way. Since thyroid receptors are widely distributed in the testis especially in the Sertoli cells and normal thyroid function is important to maintain normal reproduction, we tested the histomorphological changes of the testis in response to hypothyroidism.

## Materials and Methods

Thirty adult male Wistar rats ( $250 \pm 50$  g) were obtained from the Animal House of the Pasteur Institute of Tehran, Iran, and then randomly divided into three groups (n=10): Control, Hypothyroidism, Hypothyroidism +Levothyroxine. All the rats had the same conditions in terms of temperature conditions, 12 hours of darkness, and 12 hours of lighting; besides, all of them had access to adequate water and food. All the ethical considerations such as proper animal breeding, including adequate food and water, favorable temperature, etc., were observed.

**Hypothyroidism induction:** To induce hypothyroidism, 20 rats underwent the effect of anti-thyroid medication Propylthiouracil (PTU) with concentration 0.5 g/L of drinking water for five weeks (Ayatollahi et al., 2015). After, six weeks, the amount of thyroid hormones in blood of the rats in the test and control groups and ensuring the development of hypothyroidism in the test group. Ten rats with hypothyroidism received levothyroxine with concentration of 1mg/L of drinking water for eight weeks Sheikhzadeh et al., 2014.

**Sample collection:** After 90 days, the all animals were anesthetized by ketamine (100 mg/kg) and xylazine (5 mg/kg)(La et al., 2017). After anesthesia, by opening the ventricular area, the testes were removed from the scrotum, and since in most cases the testes are located inside a ventricular chamber, they were led to the outside of the ventricle and then sliced longitudinally.

**Pathological and histometrical study of seminiferous tubules and testicular vessels:** In the laboratory, after paraffin molding of the specimens by microtome device, some 5 micron-thick sections were cut serially, and then the tissue sections were prepared for investigation by hematoxylin-eosin staining. Histometry of the testicular tissue in each of the test groups was evaluated using micrometer eyepiece at 40x magnification. In each of the studied groups, 10 seminiferous tubes were randomly selected in each sample, and the two perpendicular diameters were calculated. Then, the average diameter of each seminiferous tube in each field of view was calculated using the formula for the area of an ellipse; also, thickness and diameter of the vascular epithelium were measured through a similar method. In addition to these parameters, the

number of spermatogonia, primary spermatocytes, and Sertoli cells were counted. In order to count these cells in each section, 10 fields of view were randomly selected from each sample, and examined; so that, a total of 300 microscopic fields of 30 sections prepared from the three groups were examined in order to investigate the above-mentioned factors. The average diameter of the toxic nephrosis tubes in each field of view was calculated using the formula for area of an ellipse due to their oval shape.

Area of an ellipse = half of the small diameter  $\times$  half of the big diameter  $\times$  pi ( $\pi$ )

**Data Analysis:** Comparisons between groups were made by one-way ANOVA analysis using SPSS statistical program (version 16). The mean  $\pm$  SEM are reported in the text and  $P < 0.05$  was considered statistically significant.

## Results

Comparing the number of spermatogonia, primary spermatocytes, and Sertoli cells between the groups showed no significant difference, and only the number of Sertoli cells in the hypothyroidism group was slightly reduced compared to the control group, so that such reduction in the thyroxine group reached to that in the control group (Fig 1,2).

Results of the analysis of diameter of seminiferous tubules among the groups indicated no significant change (Fig.3 a). The thickness of the seminiferous epithelium in the hypothyroidism group was significantly reduced compared to the control group ( $P=0.042$ ) (df=19); furthermore, in the thyroxine treatment group, it was also increased in comparison with the hypothyroidism group, but it is not significant (Fig.3 b).

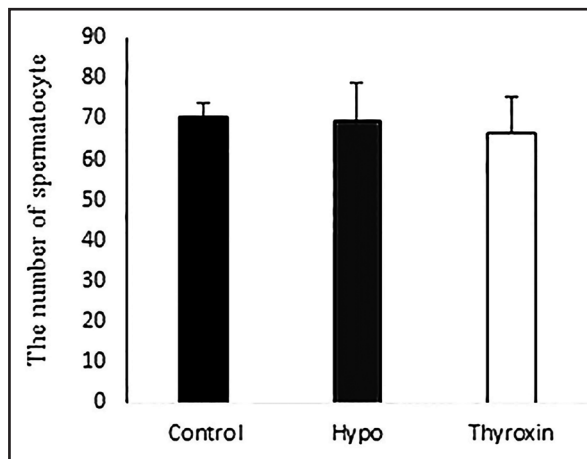
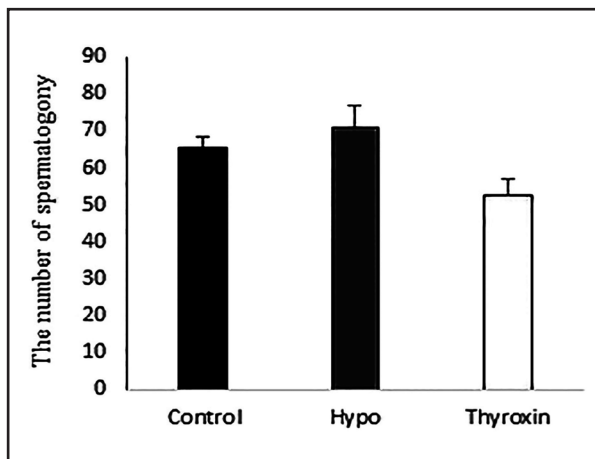


Figure 1. a: The number of spermatogonia and b: primary spermatocyte. The data presents mean ± SEM  $P \leq 0.05$ .

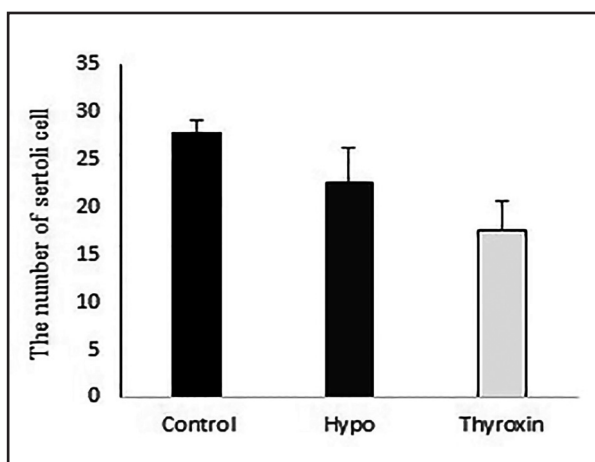


Figure 2. The number of sertoli cells. The data presents mean ± SEM,  $P \leq 0.05$ .

Diameter of vessels in the hypothyroidism group was reduced compared to the control group ( $P= 0.039$ ) ( $df=20$ ). The changes in diameter of vessels in the thyroxine group compared to hypothyroidism group showed a significant increase ( $P= 0.024$ ) ( $df=20$ ) (Fig.4a).

Comparing the thickness of vessels' wall in the hypothyroidism group indicated a significant reduction compared to the control group ( $P=0.0009$ ) ( $df=73$ ); furthermore, the thyroxine treatment group demonstrated significant changes compared to the control group ( $P=0.031$ ) ( $df=73$ ). The changes in the thyroxine group compared to the hypothyroidism group were also significant

( $P=0.001$ ) ( $df=73$ ); (Fig.4b).

### Discussion

In the present study, the effects of thyroid hormones on the adult male rat testis morpho-histometrical feature were investigated. Based on the results, eightweeks' induction of hypothyroidism by Propylthiouracil in adult male rats did not change the number of spermatogonia cells, primary spermatocytes, and sertoli cells, significantly.

Tahmaz et al., In 2000, who induced hypothyroidism in adult rats, obtained similar results to present study findings and acknowledged that there is no significant difference in the number of spermatogonia and primary spermatocyte cells between the hypothyroidism and control groups ( Yamamoto et al., 2005). Other study reported that in adult rats with hypothyroidism, the number of spermatogonia cells, primary spermatocytes, and sertoli cells were decreased significantly, which was not consistent with the findings of the present study (Krassas et al., 2008). It seems that the reason for this inconsistency in the results is due to the duration of the disease because it is one of the factors which can influence the alteration in the male reproductive system so that some researchers believe that long-term hypothy-

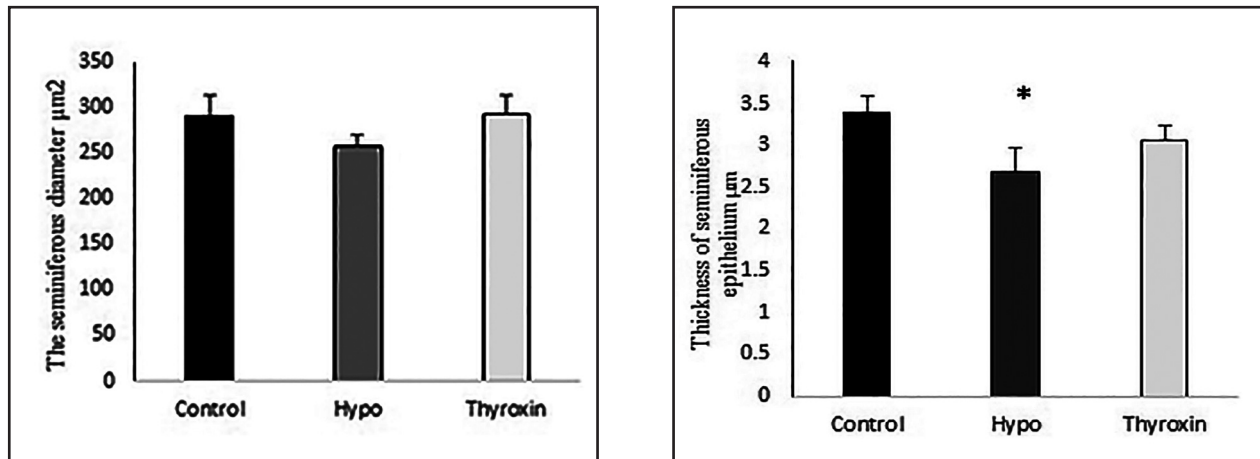


Figure 3. a: The seminiferous diameter, and b: thickness of seminiferous epithelium. The data presents mean ± SEM,  $P \leq 0.05$ . \* $P < 0.05$  one-way ANOVA vs control group.

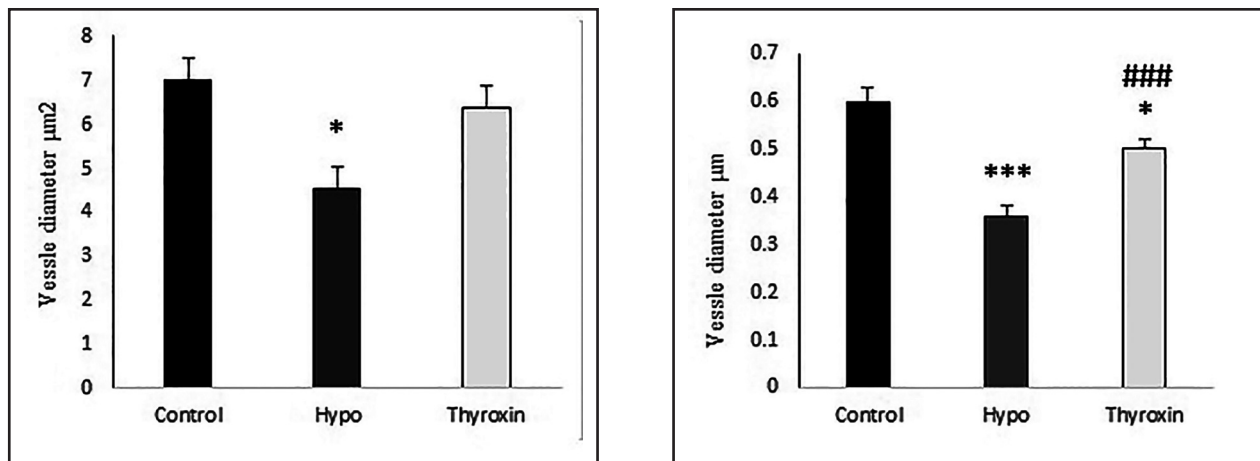


Figure 4. a: The testes vessel diameter, and b: thickness of the testes vessel. The data presents mean ± SEM,  $P \leq 0.05$ , \*\*\* $P < 0.001$  one-way ANOVA vs control group. # $P < 0.05$ , ### $P < 0.001$  one-way ANOVA vs hypothyroidism group.

roidism can reduce the number of cells by activating apoptotic pathways (Wanger et al., 2009).

Induction of hypothyroidism reduced the number of Sertoli cells in comparison with the control group. Sertoli cells express a large number of thyroid-hormone receptors that by binding to them and increasing the intracellular protein levels can lead to the survival of Sertoli cells and normal spermatogenesis (Sahoo et al., 2017). Consequently, it appears that injection of Propylthiouracil and eventually lowering the serum levels of thyroid hormones have led to a decline in the number of Sertoli cells in hypothyroidism group.

In the present study, we have shown that there is no significant change in the mean area of seminiferous tubules between the three experimental groups. It is worth noting that in the hypothyroidism group, a slight decrease was observed in the area of seminiferous tubules compared to the control group, but thyroxin therapies maintain the area of these tubules as the control group. The results of this study are consistent with the findings of Francavilla et al. (1991) who reported a decrease in the diameter of the seminiferous tubules in neonatal rats in response to hypothyroidism (Francavilla et al. 1991). This disagreement is probably due to different effects of this hormone on the



morphology of the genital tract during the different periods (neonatal and adult) of life (Sahoo et al., 2008).

Epithelium thickness of seminiferous tubules was significantly decreased in the hypothyroidism group compared to the control rats. Thyroxin has largely neutralized this reduction in the treatment group, but it is not significant statically. Previous studies have shown that long-term hypothyroidism leads to a reduction in the thickness of the germinal epithelium and therefore, many germ cells are exposed to apoptosis (Damber et al., 1992).

Another finding of the present study was the reduction of vascular diameter and wall thickness in the hypothyroidism group compared to the control group. Thyroxin therapies improved the thickness of the vascular wall compared to hypothyroidism group and also increased the thickness of the vascular wall in comparison to the control rats. Previous reports have shown that thyroid hormones directly affect endothelial and smooth muscle cells and reduction in the level of these hormones results in disturbances in the vasodilatation process (Cai et al., 2015). In addition, thyroid hormones increase shear stress in the level of vascular endothelial cells, and then shear stress, as one of the main stimulants of nitric oxide, increases nitric oxide production. The testicular microvascular smooth muscle is expressed as androgen receptors. On the other hand, testosterone also affects the testis blood vessels ability of vasomotion Damber et al., 1992-. According to previous works, the decline in the level of thyroid hormones (hypothyroidism group) by disrupting the testicular vasodilation has a negative effect on testicular blood flow, thus it may prevent enough testosterone from reaching testicu-

lar tissue.

**Conclusion:** The present study has shown that induction of hypothyroidism after four months had no significant effect on the number of male reproductive system cells, however significant histometrical changes were observed on the epithelium thickness of seminiferous tubules, vascular wall thickness, and vascular diameter. Thus these findings may explain the part of thyroid hormones deficiency effects on adult male fertility.

**Compliance with ethical standards (Funding):** This research did not receive any specific grant from any funding agency in the public, commercial or not-for-profit sector.

### Acknowledgements

The author would like to thank the members of the Physiology Section of University of Tabriz for the valuable support and help for the preparation of the present paper.

### Conflicts of interest

The author declared no conflict of interest.

### References

- Anbalagan, J., Sashi, AM., Vengatesh, G., Stanley, JA., Neelamohan, R., Aruldas, MM. (2010). Mechanism underlying transient gestational-onset hypothyroidism-induced impairment of posttesticular sperm maturation in adult rats. *Fertil Steril*, 93(8), 2491-7. <https://doi.org/10.1016/j.fertnstert.2010.02.005> PMID: 20303481
- Ayatollahi, S, Hashemi, M., Kazemi Oskuee, R. (2015). Synthesis of efficient gene delivery systems by grafting p.egylated alkylcarboxylate chains to PAMAM dendrimers: evaluation of transfection efficiency and cyto-tox-

- icity in cancerous and mesenchymal stem cells. *J Biomater Appl*, 30(5), 632-48. <https://doi.org/10.1177/0885328215599667> PMID: 26265706
- Bassett, JD., Harvey, CB., Williams, GR. (2003). Mechanisms of thyroid hormone receptor-specific nuclear and extra nuclear actions. *Mol Cell Endocr*, 213(1), 1-1. <https://doi.org/10.1016/j.mce.2003.10.033>
- Buzzard, J.J., Morrison, JR., O'Bryan, MK., Song, Q., Wreford, NG. (2000). Developmental expression of thyroid hormone receptors in the rat testis. *Biol Reprod*, 2000 Mar 1, 62(3), 664-9. <https://doi.org/10.1095/biolreprod62.3.664> PMID: 19082768
- Buzzard, JJ., Wreford, NG., Morrison, JR. (2003). Thyroid hormone, retinoic acid, and testosterone suppress proliferation and induce markers of differentiation in cultured rat Sertoli cells. *Endocrinology*, 144(9), 3722-31 <https://doi.org/10.1210/en.2003-0379> PMID: 12933640
- Cai, Y., Manio, MM., Leung, GP., Xu, A., Tang, EH., Vanhoutte, PM. (2015). Thyroid hormone affects both endothelial and vascular smooth muscle cells in rat arteries. *Eur J Pharmacol*, 747, 18-28. <https://doi.org/10.1016/j.ejphar.2014.11.036> PMID: 25489922
- Damber, JE., Maddocks, S., Widmark, A., Bergh, A. (1992). Testicular blood flow and vasomotion can be maintained by testosterone in Leydig cell-depleted rats. *Int J Androl*, 15(5), 385-93. <https://doi.org/10.1111/j.1365-2605.1992.tb01353.x> PMID: 1428197
- Francavilla, S., Cordeschi, G., Properzi, G., Di Cicco, L., Jannini, EA., Palmero, S., Fugassa, E., Loras, B., D'armiento M. (1991). Effect of thyroid hormone on the pre-and post-natal development of the rat testis. *J Endocrinol*, 129(1), 35-NP. PMID: 1903146
- Gao, Y., Lee, WM., Cheng, CY. (2014). Thyroid hormone function in the rat testis. *Front Endocrinol*, 5, 188-198. <https://doi.org/10.3389/fendo.2014.00188> PMID: 25414694
- Jannini, EA., Ulisse, S., D'Armiento, M. (1995). Thyroid hormone and male gonadal function. *Endocr Rev*, 16(4), 443-59. <https://doi.org/10.1210/edrv-16-4-443>
- Krajewska-Kulak, E., Sengupta, P. (2013). Thyroid function in male infertility. *Front Endocrinol*, 4, 174-184. <https://doi.org/10.3389/fendo.2013.00174> PMID: 29737216
- Krassas, GE., Papadopoulou, F., Tziomalos, K., Zeginiadou, T., Pontikides, N. (2008). Hypothyroidism has an adverse effect on human spermatogenesis: a prospective, controlled study. *Thyroid*, 18(12), 1255-9. <https://doi.org/10.1089/thy.2008.0257> PMID: 19012472
- Krassas, GE., Poppe, K., Glinoer, D. (2010). Thyroid function and human reproductive health. *Endocr Rev*, 31(5), 702-55. <https://doi.org/10.1210/er.2009-0041>
- Kumar, A., Shekhar, S., Dhole, B. (2014). Thyroid and male reproduction. *Indian J Endocrinol Metab*, 18(1), 23. PMID: 24701426
- La Vignera, S., Vita, R., Condorelli, RA., Mongioi, LM., Presti, S., Benvenega, S., Calogero, A E. (2017). Impact of thyroid disease on testicular function. *Endocrine*, 58(3), 397-407.
- Orth, JM., Gunsalus, GL., Lamperti, AA. (1988). Evidence from sertoli cell-depleted rats indicates that spermatid number in adults depends on numbers of Sertoli cells produced during perinatal development. *Endocrinology*, 122(3), 787-94. <https://doi.org/10.1210/endo-122-3-787> PMID: 3125042
- Romano, R M., Gomes, SN., Cardoso, NC. S., Schiessl, L., Romano, MA., Oliveira, A. (2017). New insights for male infertility revealed by alterations in spermatid function and differential testicular expression of thyroid-related genes. *Endocrine*, 55(2), 607-

617. PMID: [27066791](#)
- Sahoo, DK., Roy, A., Bhanja, S., Chainy, GB. (2008). Hypothyroidism impairs antioxidant defence system and testicular physiology during development and maturation. *Gen Comp Endocrinol*, 156(1), 63-70. <https://doi.org/10.1016/j.ygcen.2007.11.007> PMID: [18093587](#)
- Sahoo, SK., Dandapat, J., Chainy, GB. (2017). Differential expression of apoptotic proteins in seminiferous tubule cells of adult rats by neonatal exposure to 6-n-propyl-2-thiouracil (PTU), a thyroid disrupting chemical. *Indian J Exp Biol*, 55, 634-641.
- Sheikhzadeh, F., Khajehnasiri, N., Banan Khojasteh, SM., Ghadiri Soufi, F., Dastranj, A. (2014). Attenuation of phosphorylated connexin-43 protein levels in diabetic rat heart by regular moderate exercise. *Arch Iran Med*, 17, 569-573. PMID: [25065281](#)
- Singh, R., Hamada, AJ., Agarwal, A. (2012). Thyroid hormones in male reproduction and fertility. *Open Re-prod Sci J*, 3, 98-104.
- Taha, M., Mahmood, S., Yahia, G. (2012). Effect of hypothyroidism on sperms characteristics in testes and epididymides of male albino rats. *Reproduction*, 25(3), 102-108.
- Wagner, MS., Wajner, SM, Maia, AL. (2009). Is there a role for thyroid hormone on spermatogenesis? *Mi-crosc Res Tech*, 72(11), 796-808. <https://doi.org/10.1002/jemt.20759> PMID: [19637394](#)
- Yamamoto, T., Fukushima, T., Kikkawa, R., Yamada, H., Horii, I. (2005). Protein expression analysis of rat testes induced testicular toxicity with several reproductive toxicants. *J Toxicol Sci*, 30(2), 111-26. PMID: [15928459](#)



## تأثیر هیپوتیروئیدیسم بر ویژگی‌های مورفو-هیستومتریکی بیضه در رت‌های بالغ

هیرو شیخ‌الاسلامی<sup>۱</sup> فرزام شیخ‌زاده<sup>۱</sup> سید مهدی بانان خجسته<sup>۱</sup> نازی خواجه نصیری<sup>۲</sup> علی دسترنج<sup>۳</sup> حسن مروتی<sup>۴</sup>

<sup>۱</sup>گروه علوم جانوری، دانشکده علوم طبیعی، دانشگاه تبریز، تبریز، ایران  
<sup>۲</sup>گروه علوم زیستی، دانشکده علوم پایه، موسسه آموزش عالی ریح رشید، تبریز، ایران  
<sup>۳</sup>مرکز تحقیقات سلامت باروری زنان، دانشگاه علوم پزشکی تبریز، تبریز، ایران  
<sup>۴</sup>گروه علوم پایه، دانشکده دامپزشکی، دانشگاه تهران، تهران، ایران

(دریافت مقاله: ۱ مرداد ماه ۱۳۹۷، پذیرش نهایی: ۲۳ مهر ماه ۱۳۹۷)

## چکیده

زمینه مطالعه: تا کنون اثر هورمون‌های تیروئیدی بر اندام تولیدمثلی نر در دوره بعد از بلوغ مورد توجه و مطالعه قرار نگرفته است. هدف: در بررسی حاضر اثر اختلال هورمون‌های تیروئیدی بر ویژگی‌های مورفو-هیستومتریکی اندام تولیدمثلی نر بالغ مورد بررسی قرار گرفت.

روش کار: ۳۰ سر موش صحرایی نر بالغ به طور تصادفی به سه گروه (n=۱۰) کنترل، هیپوتیروئیدی و هیپوتیروئید دریافت کننده لووتیروکسین تقسیم شدند. بعد از ۴ ماه تعداد سلول‌های اسپرماتوگونی، اسپرماتوسیت اولیه و سرتولی مورد بررسی قرار گرفت در ضمن ضخامت اپی‌تلیوم مجرای سمی نفروز، مساحت مجرای سمی نفروز و قطر و ضخامت شریان‌های بیضه نیز مورد ارزیابی واقع شد. نتایج: تفاوت معنی‌داری بین گروه هیپوتیروئیدیسم و گروه کنترل در تعداد سلول‌های اسپرماتوگونی، اسپرماتوسیت اولیه، سرتولی و مساحت مجرای سمی نفروز مشاهده نشد. بعلاوه ضخامت مجرای سمی نفروز، قطر و ضخامت دیواره شریان‌ها در گروه هیپوتیروئیدیسم نسبت به موش‌های صحرایی نر کاهش معنی‌دار داشت. نتیجه گیری نهایی: نتایج حاصل در تأیید این مطلب است که هیپوتیروئیدیسم توانایی باروری مردان را تحت تأثیر قرار می‌دهد و احتمالاً این کاهش توانایی از طریق کاهش جریان خون بیضه میانجی‌گری می‌شود.

واژه‌های کلیدی:

شریان، هیپوتیروئیدیسم، سلول‌های تولید مثلی نر، مجرای سمی نفروز