

Therapeutic Effects of Parenteral Vitamin C (Ascorbic Acid) on Struvite Crystalluria in Domestic Male Cats

Abdolali Malmasi¹, Tara Nazar¹, Mohammad Mojtahedzadeh^{1*}, Saeid Bokaei², Roshanak Mokhtari³, Shabnam Babazadeh¹, Soheil Tavallaie¹

1 Department of Internal Diseases, Faculty of Veterinary Medicine, University of Tehran, Tehran, Iran

2 Department of Food Hygiene, Faculty of Veterinary Medicine, University of Tehran, Tehran, Iran

3 Department of Surgery and Radiology, Faculty of Veterinary Medicine, University of Tehran, Tehran, Iran

Abstract

BACKGROUND: Struvite crystals (Magnesium Ammonium Phosphate) are one of the most common causes of urolith formation in cats. Presence of these crystals in urea leads to urinary obstruction and idiopathic cystitis. The prevalence of urinary crystals has increased in recent years, thus there has been a growing interest in development of noninvasive, fast responsive therapies. Vitamin C is a safe compound with antioxidant properties. This vitamin is known as urine acidifier as well. Since struvite crystals are more soluble in acidic pH, it could be expected that vitamin C application could improve crystals dissolution as well as their disposal. It could also prevent other complications.

OBJECTIVES: This study was designed to analyze the effects of vitamin C in reducing the rate and intensity of struvite crystals with current long term therapies such as diet alteration, acidifier's applications and diuretics.

METHODS: Ten male domestic cats with clinical signs of lower urinary tract disease were selected. Struvite crystalluria was confirmed by urine analysis and ultrasonography. Cats were divided to treatment and control groups each containing 5 cats. Both groups were treated by conventional therapies for two weeks, however, during the 1st week the treatment group received injectable vitamin C (100 mg/kg, every 24h, SC) and the control group received oral DL Methionine (200mg/cat, every 8h), in addition to conventional therapies. Urine was collected at days 0, 7 and 14 and its pH, specific gravity and number of crystals were calculated. Presence of floating echogenic foci was evaluated using ultrasound.

RESULTS: Significant decrease in struvite crystalluria was observed in both groups. However, in group treated by vitamin C this decrease was faster and more effective. In addition, in case of obstruction, vitamin C showed better therapeutic effects.

CONCLUSIONS: According to these results, vitamin C injection could be a therapeutic approach in treatment of urinary tract obstructions where fast response is needed to avoid further complications. Oral methionine seems to be a suitable choice for prophylaxis in patients with moderated signs and relatively high urine pH or continuing therapy to prevent recurrence of disease.

KEYWORDS: Crystalluria, Domestic cat, Feline Lower Urinary Tract Disease (FLUTD), Struvite crystals, vitamin C

Correspondence

Mohammad Mojtahedzadeh, Department of Internal Diseases, Faculty of Veterinary Medicine, University of Tehran, Tehran, Iran

Tel: +98(21) 66920035, Fax: +98(21)66438327, Email: M.mojtahedzade@ut.ac.ir

Received: 2019-04-11

Accepted: 2019-06-25

Copyright © 2019. This is an open-access article distributed under the terms of the Creative Commons Attribution- 4.0 International License which permits Share, copy and redistribution of the material in any medium or format or adapt, remix, transform, and build upon the material for any purpose, even commercially.

How to Cite This Article

Malmasi, A., Nazar, T., Mojtahedzadeh, M. B., Saeid, ., Mokhtari, R., Babazadeh, S., & Tavallaie, S. (2019). Therapeutic Effects of Parenteral Vitamin C (Ascorbic Acid) on Struvite Crystalluria in Domestic Male Cats. Iranian Journal of Veterinary Medicine, 13(3), 233-242.

Introduction

The classic term of FUS (feline urological syndrome) and the most recent FLUTD (feline lower urinary tract disease) are broad terms that are used to describe a number of conditions associated with micturition, which include hematuria, pollakiuria and Periuria. The terms of obstructive uropathy and non-obstructive uropathy are also used to classify cases of FLUTD depending on the presence or absence of urethral obstruction.

Feline lower urinary tract disease (FLUTD), formerly known as 'Feline urologic syndrome, FUS, is now more commonly called 'Feline Idiopathic Cystitis (FIC'. Idiopathic cystitis in cats is a serious disease which may cause obstruction in male urethra and can be life-threatening.

Major causes of FLUTD that have been identified include urolithiasis and the formation of urethral plugs. In many cases, however, no specific cause of disease may be evident.

Struvite is the most common crystal nowadays and is a material that is comprised of magnesium, ammonium and phosphate. Increasing ionic concentrations of urinary minerals is the driving force underlying crystal formation. As the mineral concentration increases, urine becomes thermodynamically unstable and struggles to keep its contents in solution. Finally, concentration reaches to a level at which minerals can no longer remain dissolved and are forced out of solution as a solid phase (crystal formation)(Osborne et al., 1996).

Urethral plugs are composed of varying combinations of a protein colloid matrix and crystalline matrix (Osborne et al., 1992, 1996). When the urine becomes saturated with a solute or solutes, crystals may form, aggregate, and grow. Other substances (e.g., cell debris, bacteria, and foreign bodies) must be present

to act as a nidus for crystal precipitation to occur (Kavanagh, 2006). Many factors contribute to the saturation of the urine with a given solute or solutes, including urine volume, pH, concentrations of the solute, and urolith promoters and inhibitors

Alkaline urine by affecting hydrogen phosphate (H_3PO_4) makes hydrogen ions out of the compound and increases the amount of phosphate ion (PO_4^-) in urine. Crystalluria is used as a urine solubility detector and a risk factor for urinary stones and plugs formation. (Lulich et al, 2010).

Lower urinary tract signs (LUTS) are a set of clinical conditions with similar symptoms related to inappropriate urine elimination including anuria, pollakiuria, stranguria, dysuria, hematuria and periuria. A majority (i.e., 55 to 69%) of cats with LUTS have feline idiopathic cystitis (FIC; Kruger et al., 1991; Gerber et al., 2005). Some other causes are urolithiasis (13 to 28%), urethral obstruction (10 to 21%), and urinary tract infections (UTI; 1 to 8%).

Urethral obstruction usually occurs in male cats and is most often caused by the formation of urethral plugs, passage of uroliths from the urinary bladder into the urethra or inflammation and swelling associated with feline idiopathic cystitis and likely urethritis.

Rising incidence of urinary crystalluria in recent years and the role of these compounds in plug formation followed by complications such as idiopathic cystitis, search for treatment with lowest invasion that can relieve the symptoms in a short time, have gained considerable attention.

Vitamin C is an essential nutrient for humans and certain other animal species. This vitamin has multiple functions in the body. Based on studies, vitamin C is a urinary acid-

ifier (Carlsson, Wiklund, Engstrand, Weitzberg, & Lundberg, 2001).

Since struvite crystals are relatively soluble in acidic urine, it is expected that with the injection of vitamin C in cats, crystals could be dissolved in a short period of time. In addition, vitamin C is an antioxidant and can stimulate immune system. This drug (medication) can prevent lower urinary tract infections and other diseases.

As there have been no previous studies regarding the therapeutic effects of Vit C in dissolving struvite crystals, this research was designed to evaluate its role in rapid treatment of FLUTD and struvite crystalluria compared with conventional medications (diet modifications or urinary oral acidifiers).

Immediate treatment of severe FLUTD cases, especially simultaneously with urethral obstruction in male cats is very important and is considered as an emergency. Conventional treatment of FLUTD includes urethral catheterization along with bladder flushing, using diuretic drugs, antibiotic therapy (if needed), dietary modification and urinary acidifiers.

As there is currently no treatment protocol for resolving urinary stones and plugs and most therapeutic approaches are just supportive and symptomatic, using parenteral compounds that can dissolve these deposits faster was suggested. Using oral acidifiers such as DL-methionine is associated with problems such as palatability and also time limitation as compared with more rapid subcutaneous drug absorption and entering into the blood flow and bladder.

This study was designed to compare the effects of parenteral urinary acidifier like Vitamin C with oral urinary acidifiers on rapid urinary crystals dissolution.

Materials and Methods

Ten male cats with lower urinary tract symptoms such as dysuria, anuria, polyuria, pollakiuria, periuria, cystitis and hematuria that were referred to the Small Animal Hospital of Tehran University were selected

The cats were randomly divided into two groups: experimental group (5 cats) and control group (5 cats). History of each group, including age, breed, weight and type of food were recorded.

Presence of crystals and identifying their type was confirmed by microscopic analyses of urine sediments. Urine pH was checked by pH meter and urine specific gravity (USG) was measured with refractometer. Crystal precipitation in urinary bladder was also confirmed by ultrasonography. After confirming the FLUTD by the presence of related clinical signs and U/A including the microscopic observation of struvite crystals, alkaline pH and increased SG and the precipitation of crystals in ultrasonography of the bladder, the cats were randomly divided into two groups as mentioned before to evaluate two different therapies: group 1 (5 cats) and group 2 (5 cats)

Group 1 (conventional): This group was treated with oral conventional urine acidifier D/L methionine (170 mg/Kg TID for one week), oral and intravenous diuretic (furosemide 2mg/kg BID for 7 days) and catheterization (in the case of cystitis and obstruction) and diet modification.

Group 2 (Vit C): This group received vitamin C (100 mg/Kg, SC) SID for 7 days and the same conventional therapies including oral and intravenous diuretic (furosemide 2mg/kg BID for 7 days), catheterization (in the case of cystitis and obstruction), v and diet modification.

Urinary analysis, ultrasonography and

clinical examinations for both groups were performed on days 0, 7, 14.

Sterile urine samples through catheterization or cystocentesis on days 0, 7 and 14 of the study were collected and sent to the laboratory for measuring pH, USG and identifying crystals types.

The crystals were counted using low magnitude lens ($\times 100$ LPF) and their type was evaluated with high magnitude lens ($\times 400$ HPF). The severity of Crystalluria was directly observed by light microscopy. Based on the number of struvite crystals in each LPF, a 1-3 plus numerical value was assigned to each sample.

On days 0, 7 and 14 of the study, to evaluate accumulation of crystals or debris in urinary bladder (floating echogenic foci) and changes in the wall thickness, abdominal ultrasonography was performed. 2mm thickness was considered normal and any changes beyond this measure were regarded as abnormal.

Data Analysis

To investigate the effects of vitamin C on urinary parameters and ultra-sonographic findings such as bladder wall thickness in both groups, the independent sample t-test was selected. Paired sample t-test was used for evaluating the effects of each treatment on the factors examined on days 0,7,14. Presence of echogenic foci in urinary bladder was analyzed by McNemar test. All data were analysed by SPSS 17 (SPSS Inc. Chicago, Ill, USA).

Results

The cats were either Persians or DSH. The mean age of cats was 29 ± 7.36 months and mean weight was 3.0 ± 8.33 Kg. All cats, except one, had been fed dry food. Three of 10 cats were neutered. Five cats had hematuria

and complete obstruction.

Results showed that the group treated with Vitamin C had a significant decrease in urine pH at days 7 and 14 ($P < 0.05$). While this reduction in group treated with oral methionine was not significant at days 7 and 14.

Although struvite Crystalluria in both treated groups were significantly decreased at days 7 and 14 ($P < 0.05$), no struvite crystals were observed in the urine sediment of four cats of the group treated with Vitamin C (elimination of crystalluria: 80 %); in the group treated with oral methionine average urine struvite crystals remained 1+ on days 7, 14.

Comparison between crystalluria severity in experimental and control groups demonstrated that Vitamin C significantly reduced crystalluria in comparison with oral methionine at days 7 and 14 (Figs. 1 and 2).

Bladder wall thickness was evaluated on days 0, 7 and 14 and data analysis did not show any influence on cats of both groups ($P > 0.05$) (Fig.3).

Based on bladder ultrasonography, although urinary echogenic foci on days 7 and 14 were reduced in both groups, statistical analyses with McNemar test did not show significant differences between two groups ($P > 0.05$).

USG analyses showed that the urine specific gravity on day 7 in both groups had decreased but it was not significant. Mean USG measurements on days 0,7,14 of this study did not show any statistical differences ($P > 0/05$) (Table 1).

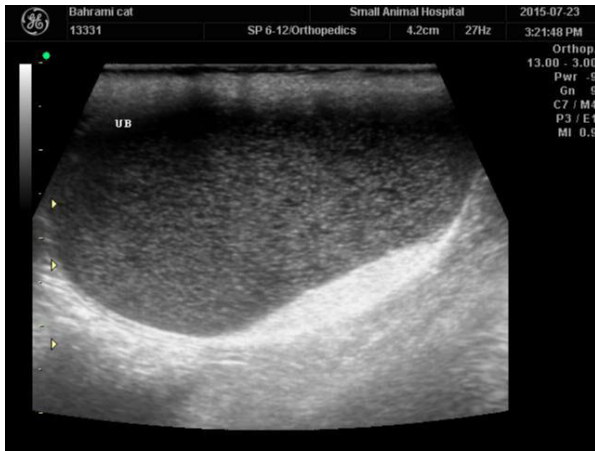

Figure 1.

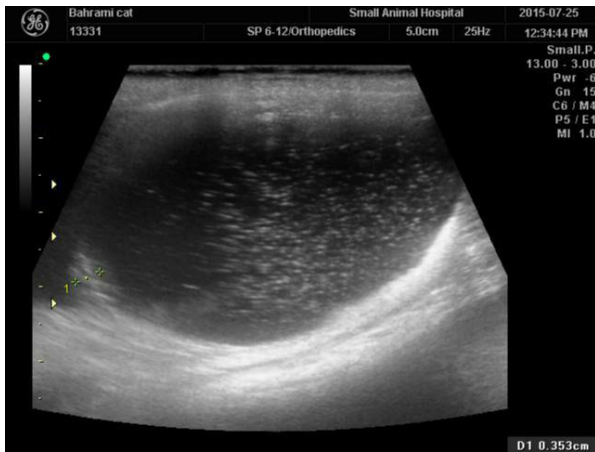
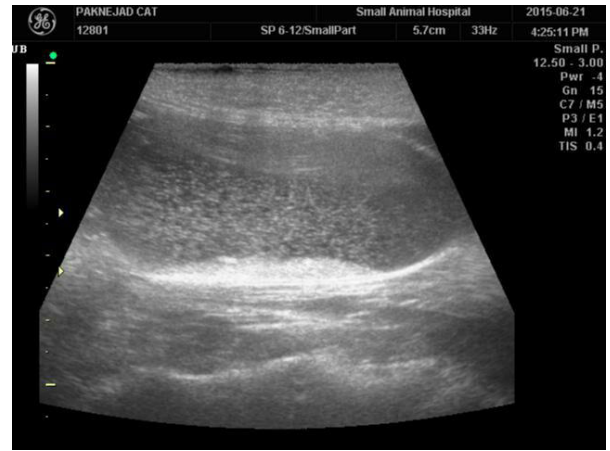

Figure 2.

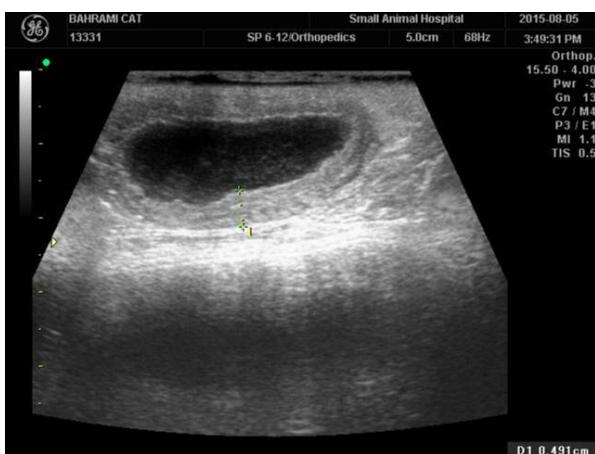
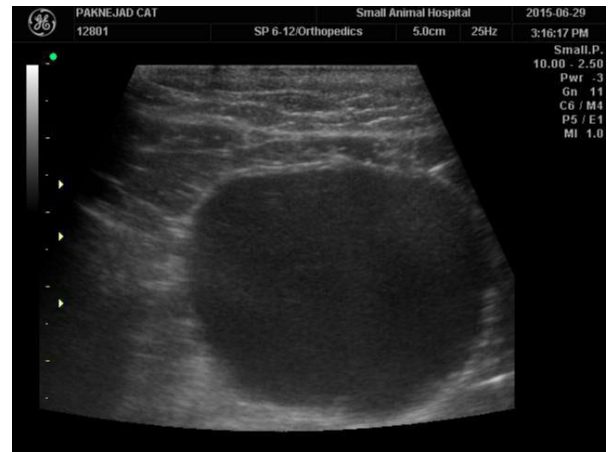

Figure 3.

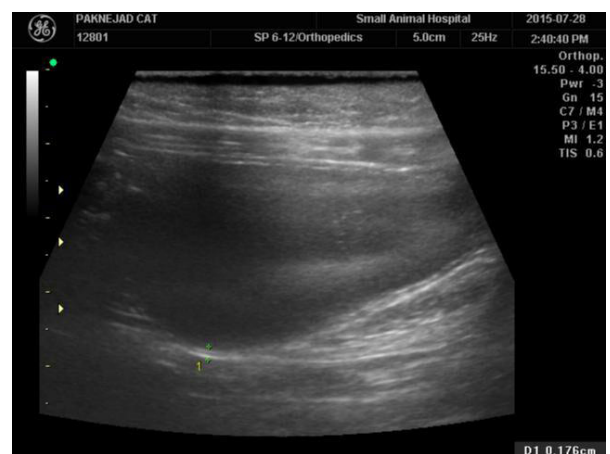

Table 1. Mean USG measurements

Factor	group	Day0	Day7	Day14
pH	1	7.04±0.26	5.44±0.17	5.92±0.04
	2	6.7±0.09	6.5±0.14	6.44±0.12
Crystal	1	2.4±0.24	0.2±0.2	0.2±0.2
	2	2.4±0.24	1±0.32	1.2±0.2
USG	1	1.031±0.007	1.028±0.005	1.031±0.007
	2	1.041±0.003	1.032±0.008	1.038±0.007

Discussion

The lower urinary tract feline diseases are receiving more attention as the number of cats with an indoor lifestyle increases as well as multi-cat households.

Although struvite crystalluria in cats is normal, when coupled with clinical symptoms it can be a indication of struvite stones, idiopathic cystitis and urinary tract infections. Lower urinary tract disease in cats is fairly common and urethra obstruction can be life-threatening. (Buffington, 2011; Ettinger & Feldman, 2010). In this study, 90% of the referred cats were fed dry foods. Role of food humidity in formation of calcium oxalate stones has been reported in different studies. Food moisture reduces crystalloid substrates and urine mineral concentration (Lekcharoensuk et al., 2001).

Vitamin C is an essential vitamin with many known properties. This vitamin can acidify urine (Traxer, Huet, Poindexter, Pak, & Pearle, 2003). As struvite crystals are relatively soluble in acidic pH, in this study we evaluated the effects of parenteral (SC) vitamin C for a week on urinary factors such as pH and crystalluria compared with classic treatment with a urinary acidifier (oral methionine).

Ammonium chloride has also been shown to be an effective urinary acidifier in the cat (Taton and others 1984a), and largely pre-

vented urinary tract obstruction and urolith formation in a group of cats fed a diet containing 0.37 per cent magnesium (dry matter). In the present study, injection of vitamin C significantly reduced urine pH on day seven which remained constant up to day 14.

A key factor in control of struvite uroliths on both theoretical and experimental grounds is urine pH (Taton and others 1984a, Tarttelin 1987, Buffington 1988).

In this study, in group treated with vitamin C injections, pH reduction was greater and faster than usual treatment with oral methionine ($P>0.05$).

Average urine pH on day 7 was decreased from 7 to 5.5 in group1 that represents rapid influence on urine pH, whereas oral methionine did not show significant decrease in urinary pH ($P>0.05$).

USG was measured on days 0, 7 and 14 and no significant changes were seen, neither in group 1 nor in group 2.

Buckley showed that increasing diet humidity can reduce USG and consequently incidence of calcium oxalate will decrease, however, the effect of USG on struvite was less clear, with no significant difference between treatment groups (Buckley, Hawthorne, Colyer, & Stevenson, 2011). It seems urine specific gravity is not the determining factor in the severity of struvite crystalluria, however, more studies are needed for accu-

rate understanding of this issue.

Struvite crystalluria can be seen in normal cats (Schaer, 2009) so crystalluria has no clinical importance, but along with other symptoms of lower urinary tract infections it seems serious and should be treated.

In this study, a significant reduction in struvite crystalluria was detected in both treatment groups on days 7 and 14. This reduction in the group treated with vitamin C was found to be faster and more effective and on day 7 crystalluria reached to zero in all treated cases except one cat. But in group 2 crystalluria remained positive (1+) till day 14. These results reflect the impacts of vitamin C injections in cases of severe crystalluria, obstruction and urinary struvite stones compared with methionine. Methionine can be efficient in cases with mild crystalluria or in those that the urine must be kept acidic.

In addition, reducing pH can be effective in treatment and prevention of urinary bacterial infections, which is a risk factor for the formation of struvite stones (Carlsson, et al., 2001).

On day 14 no significant changes in crystalluria compared with day 7 were seen in both groups. However, in group treated with vitamin C, crystalluria remained at similar rate on days 7 and 14. On the other hand, in group treated with methionine a slight increase in average crystalluria was observed on day 14 compared to day 7 which may show the need for long term therapy with this medication.

In this study, two other factors including bladder wall thickness (mm² <) and floating echogenic foci in bladder ultrasound were investigated in the treatment groups on days 0, 7 and 14. In present study cystitis mostly remained unchanged in cats. Cases that had thickened urinary wall bladder did not change till day 14, which can indicate the need of other treatments to reduce bladder

inflammation. Therefore, in order to better understand the effects of vitamin C on the bladder wall thickness further studies under controlled conditions are warranted.

Conclusions

Floating echogenic foci in the bladder can be due to the presence of blood, fat droplets or crystals (Nyland & Mattoon, 2002). Ultrasonography cannot distinguish these particles (Chew & Buffington, 2014). The presence of these particles in bladder could lead to struvite stone formation risk (Dvorska & Saganuwan, 2015).

In the present study, although echogenic foci were reduced in both treated groups on days 7 and 14, statistically they were not significant. The results showed that vitamin C and methionine both had similar effects on reducing echogenic foci, however, further studies in the same and controlled conditions for more accurate evaluations of these 2 compounds are needed.

Acknowledgments

We would like to gratitude Dr. Shabnam Babazadeh, and Mr. Alireza Ghovati for their patience and support during our research.

Conflicts of Interest

The authors declared no conflict of interest.

References

- Buffington, C., Rogers, Q., & Morris, J. (1999), Diet therapy in cats with lower urinary tract disorders, *J Am Vet Med Assoc*, 626-630
- Buffington CAT, Chew DJ, Woodworth BE. (1999) Feline interstitial cystitis. *J Am Vet Med Assoc.*; 215:682-687. PMID: 10476717
- Buffington ,A ., ROGERSQ, . R., MORRIS7,. G. & COOKN, . E.(1985) Feline struvite urolithiasis: magnesium effect depends on urinary pH.

- Feline Practice 15, 29-33
- Cameron, M. E., Casey, R. A., Bradshaw, J. W. S., Waran N. K. Gunn-Moore, D. A. ,(2004), A study of environmental and behavioral factors that may be associated with feline idiopathic cystitis PMID: 15049572
- Cannon, A. B., Westropp, J. L., Ruby, A. L., & Kass, P. H. (2007). Evaluation of trends in urolith composition in cats: 5,230 cases (1985–2004) *J Am Vet Med Assoc*, 231(4), 570-576. PMID: 17696857 DOI: <https://doi.org/10.2460/javma.231.4.570>
- Carney HC, Sadek TP, Curtis TM, et al. (2014) AAFP and ISFM guidelines for diagnosing and solving housesoiling behavior in cats. *J Feline Med Surg.* ;16:579–598. <https://doi.org/10.1177/1098612X14539092>
- Cervigni M, van Ophoven A. Intravesical therapy. Nordling J, Wyndaele J-J, Van de Merwe JP, et al.(2013) Bladder pain syndrome. Springer Publishing: New York, USA; 307–315.
- Charrua A, Pinto R, Taylor A, et al.(2013) Can the adrenergic system be implicated in the pathophysiology of bladder pain syndrome/interstitial cystitis A clinical and experimental study. *NeuroUrol Urodyn.*;34:489–496. PMID: 2437568 DOI: <https://doi.org/10.1002/nau.22542>
- Cooper ES, Lasley E, Daniels J, et al. Incidence of urinary tract infection at presentation and after urinary catheterization in feline urethral obstruction. *J Vet Emerg Crit Care* 2013; 23(S1):S13. Issn Print: 1479-3261
- Hall J, Hall K, Powell LL, Lulich J. Outcome of male cats managed for urethral obstruction with decompressive cystocentesis and urinary catheterization: 47 cats (2009-2012). PMID: 25427645 DOI: <https://doi.org/10.1111/vec.12254>
- Defau PA Va d Mael I Duchatea L, et al. (2011) Risk factors and clinical presentation of cats with feline idiopathic cystitis. *J Feline Med Surg.*;13:967–975. PMID: 22075439 DOI: <https://doi.org/10.1016/j.jfms.2011.08.001>
- Dorsch R, Remer C, Sauter-Louis C, et al. (2014) Feline lower urinary tract disease in a German cat population. *Tierärztliche Praxis Klein-tiere.*;42:231–239. PMID: 25119631
- Edward S. Cooper, VMD, MS, DACVECC, Tammy J. Owens, DVM, Dennis J. Chew, DVM, DACVIM, and C. A. Tony Buffington, DVM, PHD, DACVN(2015) A protocol for managing urethral obstruction in male cats without urethral catheterization/*J Am Vet Med Assoc*/doi: <https://doi.org/10.2460/javma.237.11.1261> PMID: 21118011
- Eggertsdottir AV, Lund HS, Krontveit R, et al.(2007) Bacteriuria in cats with feline lower urinary tract disease: a clinical study of 134 cases in Norway. *J Feline Med Surg*;9:458–465. PMID: 17693110 DOI: <https://doi.org/10.1016/j.jfms.2007.06.003>
- Ettinger, S. J., & Feldman, E. C. (2017). *Textbook of Veterinary Internal Medicine (Vol. 2 chapter:334)*: ElsevierHealth Sciences
- Ettinger, S. J., & Feldman, E. C. (2010). *Textbook of Veterinary Internal Medicine (7 ed. Vol. 2)*: ElsevierHealth Sciences
- Finco, D. R., Barsantij, . A. & Crowell W., A. (1985) Characterisation of magnesium-induced urinary disease in the cat and comparison with feline urologic syndrome. *Am J Vet Res* 46, 391-400 PMID: 3994104
- Hague DW, Stella JL, Buffington CA.(2013) Effects of interstitial cystitis on the acoustic startle reflex in cats. *Am J Vet Res.*;74:144–147. doi: <https://doi.org/10.2460/ajvr.74.1.144> PMID:23270359
- Hugonnard M, Chalvet-Monfray K, Dernis J, et al. Occurrence of bacteriuria in 18 catheterised cats with obstructive lower urinary tract disease: a pilot study. *J Feline Med Surg* 2013; 15(10):843–848. PMID :23400682 DOI: <https://doi.org/10.1177/1098612X13477414>
- Holme, D, . (1977) Research into the feline urological syndrome. In: *The Kal Kan Symposium for the Treatment of Dog and Cat Diseases*. Kal Kan, Vernon, California. pp 40-45
- Konkle KS, Berry SH, Elliott MN, et al.(2012) Comparison of an interstitial cystitis/bladder pain syndrome clinical cohort with symptomatic community women from the RAND Interstitial Cystitis Epidemiology study. *J Urol*

- .;187:508–512. PMID: 22177158 DOI: <https://doi.org/10.1016/j.juro.2011.10.040>
- Kruger JM, Osborne CA, Goyal SM, et al. (1991) Clinical evaluation of cats with lower urinary tract disease. *Am Vet Med Assoc.*;199:211–216. PMID: 1653776
- Navratilova E, Xie JY, King T, Porreca F. (2013) Evaluation of reward from pain relief. *Ann N Y Acad Sci* 1282:1–11 PMID: 23496247 DOI: [10.1111/nyas.12095](https://doi.org/10.1111/nyas.12095)
- Nickel JC, Herschorn S, Whitmore KE, et al. (2014) Pentosan polysulfate sodium for treatment of interstitial cystitis/bladder pain syndrome: insights from a randomized, double-blind, placebo-controlled study. *J Urol.*;193:857–862. PMID: 25245489 DOI: <https://doi.org/10.1016/j.juro.2014.09.036>
- Niesters M, Martini C, Dahan A. (2013) Ketamine for Chronic Pain: Risks and Benefits. *Br J Clin Pharmacol* PMID: 23432384 DOI: <https://doi.org/10.1111/bcp.12094>
- Osborn CE., A., Polzind, . J., Kruger, . M., Lulich J, . P., Johnstong, . R. & O'Brient, . D. (1989) Relationship of nutritional factors to the cause, dissolution and prevention of feline uroliths and urethral plugs. *Veterinary Clinics of North America: Small Anim Pract* 19, 561-581 PMID: 2658291
- Palma, D., Langston, C., Gisselman, K., & McCue, J. (2009). Feline struvite urolithiasis. *Compend Contin Edu Pract Vet*, 31, 542-552 PMID: 20180225
- Rich, L. I. & Fabricant C. ,G. (1974) Experimental production of urolithiasis in male cats. *J Am Vet Med Assoc* ;158, 974-980 PMID: 4930309
- Rich, L. J. & Kirk, R. W. (1969) The relationship of struvite crystals to urethral obstruction in cats. *J Am Vet Med Assoc* , 153-157 PMID: 5812575
- Tatong, . F., Hamard, . W. & Lewis, L D. (1984a) Urinary acidification in the prevention and treatment of feline struvite urolithiasis. *J Am Vet Med Assoc* 184, 437-443 PMID: 6698875
- Tatong, . F., Hamard, . W. & Lewis L, . D. (1984b) Evaluation of ammonium chloride as a urinary acidifier in the cat. *J Am Vet Med Assoc* ;79, 773-778 PMID: 6698874
- Tarttelimn, F. (1987) Feline struvite urolithiasis: factors affecting urinary pH may be more important than magnesium levels in food. *Vet Rec*; 121, 227-230 PMID: 3672831
- Warren J W. (2014) Bladder pain syndrome/ interstitial cystitis as a functional somatic syndrome. *J Psych Res.*;77:510–515. PMID: 25455811 DOI: <https://doi.org/10.1016/j.jpsychores.2014.10.003>
- Walker AD, Weaver AD, Anderson RS, Crighton GW, Fennell C et al (1977), *J Small Anim Pract*: 18 :2830
- Walker AK, Kavelaars A, Heijnen CJ, et al. (2014) Neuroinflammation and comorbidity of pain and depression. *Pharmacol Rev.*;66:80–101. PMID: 24335193 doi: <https://doi.org/10.1124/pr.113.008144>
- Weinstock JV. (2015) Substance P and the regulation of inflammation in infections and inflammatory bowel disease. *Acta Physiol (Oxf).*;213:453–461 PMID: 25424746 DOI: <https://doi.org/10.1111/apha.12428>
- Wu CH, Buffington CA, Fraser MO, et al. (2011) Urodynamic evaluation of female cats with idiopathic cystitis. *Am J Vet Res* ;72:578–582. PMID: 21453161 doi: <https://doi.org/10.2460/ajvr.72.4.578>

بررسی میزان تاثیر تزریق ویتامین C تزریقی در کاهش میزان و شدت کریستال‌های استروویت در مقایسه با پروسه‌های درمانی طولانی مدت معمول

عبدالعلی ملماسی^۱، تارا نظری^۱، محمد مجتهدزاده^۱، سعید بکایی^۲، روشنک مختاری^۳، شبنم بابازاده^۱، سهیل تولایی^۱

^۱ گروه بیماری‌های داخلی، دانشکده دامپزشکی، دانشگاه تهران، تهران، ایران
^۲ گروه بهداشت و کنترل مواد غذایی، دانشکده دامپزشکی، دانشگاه تهران، تهران، ایران
^۳ گروه جراحی و رادیولوژی، دانشکده دامپزشکی، دانشگاه تهران، تهران، ایران

(دریافت مقاله: ۲۲ فروردین ماه ۱۳۹۸، پذیرش نهایی: ۰۴ تیر ماه ۱۳۹۸)

چکیده

زمینه مطالعه: کریستال‌های استروویت (منیزیم آمونیوم فسفات) یکی از شایع‌ترین علل تشکیل سنگ‌های دستگاه ادراری در گربه‌ها هستند. این کریستال‌ها از علل شایع انسداد ادراری و ایجاد سیستیت ایدیوپاتیک هستند. در سال‌های اخیر، بروز کریستال‌های ادراری افزایش یافته و جستجو برای یافتن درمان‌هایی که بتوانند با کم‌ترین تهاجم و در کوتاه‌ترین زمان به نتیجه برسند، اهمیت ویژه‌ای پیدا کرده‌اند. ویتامین C یک ترکیب دارای خواص آنتی‌اکسیدانی و نسبتاً بی‌خطر برای موجود زنده است. علاوه بر خواص بیولوژیک متعدد، این ویتامین به عنوان اسیدی‌کننده‌ی ضعیف ادرار نیز شناخته می‌شود. از آنجایی که کریستال‌های استروویت در pH اسیدی محلول هستند، انتظار می‌رود استفاده از ویتامین C، علاوه بر کمک به انحلال و دفع کریستال‌ها از عوارض بعدی آن‌ها جلوگیری کند.

هدف: تعیین سرعت اثر تزریق ویتامین C در کاهش میزان و شدت کریستال‌های استروویت در مقایسه با پروسه‌های درمانی طولانی مدت معمول (تغییر رژیم غذایی، استفاده از اسیدی‌کننده‌های ادراری خوراکی و داروهای مدر) در موارد کریستالوری استروویتی در گربه‌های خانگی انجام شد.

روش کار: ۱۰ گربه با علائم بیماری دستگاه ادراری تحتانی مانند دیس‌اوری انتخاب شدند. پس از تأیید حضور کریستال‌ها در ادرار با کمک سونوگرافی و انجام آزمایش‌های ادراری، گربه‌ها به دو گروه اصلی و کنترل (هر یک شامل ۵ گربه) تقسیم‌بندی شدند. هر دو گروه به مدت دو هفته با روش‌های معمول درمانی شامل استفاده از داروهای مدر، تغییر رژیم غذایی و در صورت لزوم استفاده از آنتی‌بیوتیک‌ها درمان شدند با این تفاوت که در هفته‌ی اول گروه اصلی ویتامین C ی تزریقی (۱۰۰ mg/kg زیرجلدی) و گروه کنترل دی‌ال متیونین خوراکی (۲۰۰ mg/cat هر هشت ساعت) در کنار درمان قراردادی دریافت کردند. از گربه‌ها در روزهای صفر، هفت و ۱۴ مطالعه نمونه‌گیری انجام شد و pH ادرار، وزن مخصوص، نوع و تعداد کریستال‌های استروویت محاسبه شد. حضور کانون‌های شناور اکوژن در سونوگرافی مثانه نیز بررسی گردیدند.

نتایج: کاهش قابل توجه کریستالوری استروویتی در هر دو گروه تحت درمان، مشاهده شد. ولی در گروه تحت درمان با ویتامین C، کاهش pH و به طبع آن کاهش کریستالوری در مدت زمان کوتاه‌تر و مؤثرتری روی داد. به علاوه در موارد انسداد مجاری ادراری درمان با ویتامین C تأثیر بهتری نشان داد. نتیجه‌گیری نهایی: بر اساس نتایج این مطالعه، استفاده از ویتامین C تزریقی در موارد انسداد مجاری ادراری که نیاز به پاسخ سریع برای جلوگیری از عوارض بعدی انسداد است توصیه می‌شود. همچنین از قرص‌های متیونین می‌توان به منظور پیشگیری در بیماران با علائم نه‌چندان حاد با pH نسبتاً بالای ادرار و کریستالوری استروویتی خفیف و یا ادامه‌ی درمان به منظور جلوگیری از عود مجدد استفاده کرد.

نتیجه‌گیری نهایی: بر اساس نتایج این مطالعه، استفاده از ویتامین سی تزریقی در موارد انسداد مجاری ادراری که نیاز به پاسخ سریع برای جلوگیری از عوارض بعدی انسداد است توصیه می‌شود. همچنین از قرص‌های متیونین می‌توان به منظور پیشگیری در بیماران با علائم نه‌چندان حاد با pH نسبتاً بالای ادرار و کریستالوری استروویتی خفیف و یا ادامه‌ی درمان به منظور جلوگیری از عود مجدد استفاده کرد.

واژه‌های کلیدی:

ویتامین سی، استروویت، کریستالوری، سندرم دستگاه ادراری تحتانی، گربه