

A Case Report of Dermatofibroma in a Persian Leopard in Golestan National Park, Iran

Somayeh Namroodi¹, Seyed Mohammad Hoseini^{2*}, Hadi Alijani³, Reza Amani³, Siavash Roshanian⁴

¹Department of Environmental Sciences, Faculty of Fisheries and Environmental Sciences, Gorgan, Iran. University of Agricultural Sciences and Natural Resources, Gorgan, Iran

²Department of Veterinary Pathobiology, Babol Branch, Islamic Azad University, Babol, Iran

³Young Researchers and Elite Club, Babol Branch, Islamic Azad University, Babol, Iran

⁴Golestan Office of the Environment Department, Gorgan, Iran

Abstract

Dermatofibroma is a common skin benign cutaneous tumor with many variants based on alterations in the morphology and composition of its diverse elements. The cause of dermatofibroma is unknown, it was historically attributed to being a reactive response to some traumatic lesion to the skin which is associated with itching and pain. This tumor usually appears on the limbs, especially the end extremities, in young adults. In the present study, a middle-aged Persian leopard was accidentally killed because of a car incident in the Golestan National Park, Iran. Following necropsy, skin mass on the right toe was observed and after sampling was transferred to the laboratory. After routine histopathological and immunohistochemical processes, Dermatofibroma was diagnosed microscopically with non-capsulated, circumscribed, hypocellular dermal nodule in a spiral pattern. According to the results of this study immunohistochemical staining revealed positivity for CD34. There is limited information about the Dermatofibroma in leopards. To our knowledge, this is the first report of Dermatofibroma in the Persian leopard.

KEYWORDS: Dermatofibroma, Immunohistochemistry, Histopathology, Leopard

Correspondence

Seyed Mohammad Hoseini, Department of Veterinary Pathobiology, Babol Branch, Islamic Azad University, Babol, Iran

Tel: +98 9122316192, Fax: +98 (11) 32334135, Email: Dr_hosseini2323@yahoo.com

Received: 2019-12-12

Accepted: 2020-02-24

Copyright © 2020. This is an open-access article distributed under the terms of the Creative Commons Attribution- 4.0 International License which permits Share, copy and redistribution of the material in any medium or format or adapt, remix, transform, and build upon the material for any purpose, even commercially.

How to Cite This Article

Namroodi, S., Hoseini, M., Alijani, H., Amani, R., Roshanian, S. (2020). A Case Report of Dermatofibroma in a Persian Leopard in Golestan National Park, Iran. Iranian Journal of Veterinary Medicine, 14(2):215-220

Introduction

Dermatofibroma is a common dermal nodule that is unexplained (Campanacci, 2013). Dermatofibroma is most frequently found in the skin and soft tissues of cats, occasionally found in horses and mules, and rarely in other domestic species' skin, including dogs. Dermatofibroma is usually asymptomatic, but itching and pain are often noted. Dermatofibroma is the most common of all painful skin tumors (Crisan et al., 2014). The exact mechanism for the development of Dermatofibroma is unknown. Rather than a reactive tissue change, evidence that Dermatofibroma may be a neoplastic process is demonstrated by its clonal proliferative growth (Chen et al., 2000). The cause of Dermatofibroma is unknown, it was historically attributed to being a reactive response to some traumatic lesion to the skin (e.g. arthropod bite) (Reich et al., 2017). Clonality, by itself, is not necessarily synonymous with a neoplastic process; it has been demonstrated in inflammatory conditions, including atopic dermatitis, lichen

sclerosis, and psoriasis. Dermatofibroma tumor genesis may be due to distorted protein kinase C activity (Płaszczycza et al., 2014).

Case Report

Clinical presentation

A seven-year-old female Persian leopard was dead because of accidents a road-kill in Golestan National Park, Iran, in May 2014. Following necropsy, skin mass on the sideline of the right toe was observed. The mass was dissected in necropsy. The resected mass sample was grayish-white in color and measured $2 \times 2 \times 1.5$ cm, with necrosis at the cut surface (Figure 1). The sample was fixed in 10 % buffered formalin. Serial sections of the formalin-fixed, paraffin-embedded sample were produced and serial sections were cut, using a rotary microtome (Leitz, 1512, Germany) at $5 \mu\text{m}$. The samples were stained by routine hematoxylin and eosin (HandE) and CD34 immunohistochemical staining.



Figure 1. Grayish-white dermal nodule on the right toe in Persian leopard (arrow).

Assessments

Histopathologic examination showed a non-capsulated, circumscribed and clear demarcated dermal nodule. The nodule contained hypocellular and hyalinized thick bundles of collagen. The collagen bundles were shaped in a whorled pattern with prominent clefts. Lymphocyte infiltration was observed between the bundles of collagen (Figure 2). Immunohistochemistry is a powerful microscopy-based technique that is important in the differential diagno-

sis of dermatofibroma. In this study, immunohistochemical staining revealed positivity for CD34 (Figure 3). Dermatofibroma was diagnosed according to the results of histopathological and immunohistochemical findings. To our knowledge, this is the first report of dermatofibroma in the Persian leopard. Previous studies have reported CD-positive fibroma in dermatofibrosarcoma, sclerotic fibroma and lip (Alawi and Freedman, 2004; McNiff et al., 2005; Wang and Sarma, 2007).

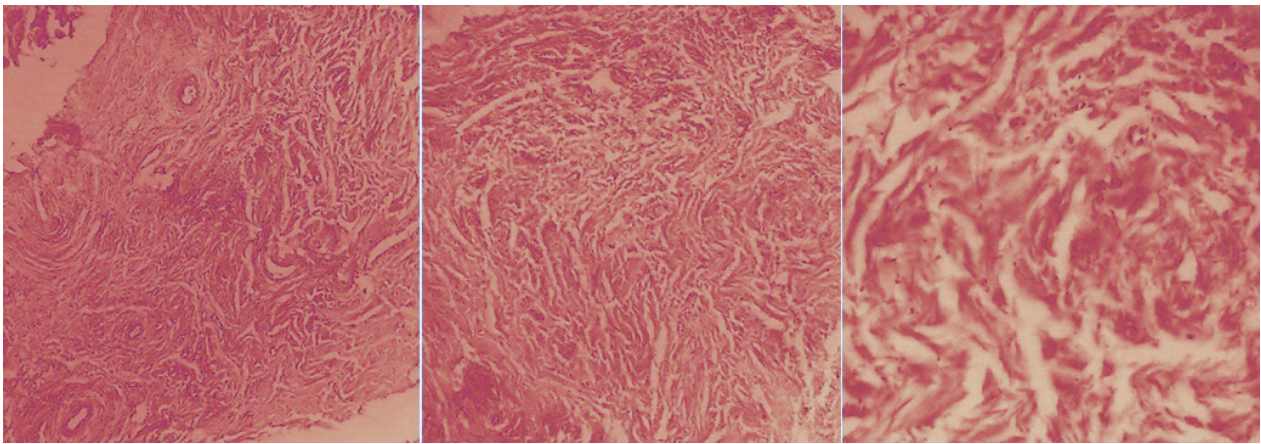


Figure 2. Prominent hypocellular, necrosis and hyalinized eosinophilic thick bundles of collagen in a whorled pattern. HandE staining. 10x, 40x.

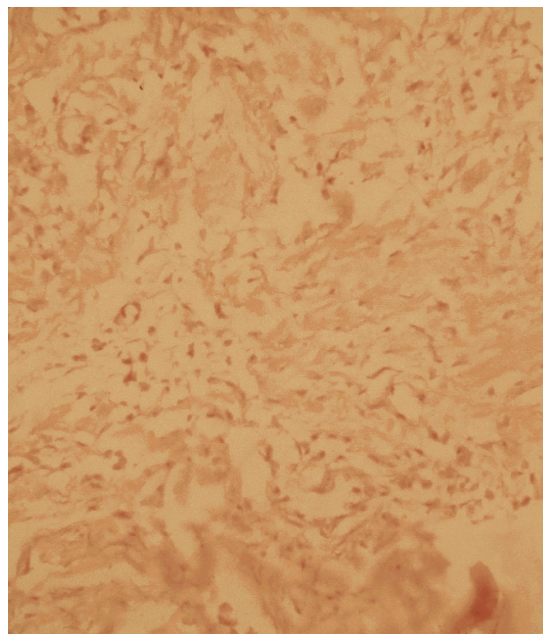


Figure 3. Immunohistochemistry of the tumor cells. The cells were positive for CD34.

Discussion

Feline dermatofibroma and fibropapilloma have many similarities with each other and with equine sarcoids. The sarcoids most commonly occur in the head, neck, ventral abdomen and limbs (Won et al., 2018). In 2001, Schulman et al. observed that feline fibropapilloma occurred in 12 of 18 cats of known age which were less than 5 years old, and two of the tumors were in the head, neck, ventral abdomen, and limbs (Schulman et al., 2001).

A fibroma is a common nodule that occurs in dogs and cats, a lesion already described (Kiehl and Mays, 2016); Also, various methods including surgery, radiotherapy and electrochemotherapy, are used in the treatment of skin tumors (Spugnini et al., 2013; Tozon et al., 2016). Sundberg et al. have reported cutaneous fibroma in white-tailed and mule deer (Sundberg et al., 1985). Yeruham and Perl have also reported a case of fibroma in a cow (Yeruham and Perl, 2001). Movassaghi and Mohammadi have reported an unusual cutaneous fibroma in a heifer (Movassaghi and Mohammadi, 2009). In a study that was done on Korean Indigenous cattle with dermal painful nodules, dermal fibroma resulting from an increase in collagen-producing fibrocytes in the dermis after the histopathological examination was observed (Jang et al., 2008).

In this study, Dermatofibroma was detected in the Persian leopard with histopathological signs and has been observed on the hands. There is limited information about the Dermatofibroma in leopards. To our knowledge, this is the first report of Dermatofibroma in a Persian leopard. Recognition and pathological diagnosis of tumors are very important to supplement the clinical approaches. Additional studies of

these tumors may help in the understanding of oncogenesis' causes.

Acknowledgments

The authors sincerely want to thank Ms. Eslami for her help in laboratory experiments. We are also grateful to Mr. Mahmood and Masoud Shakiba and Mr. Kheirabadi for managing accessibility to Persian leopard' corpse.

Conflicts of Interest

The authors declared that there are no conflicts of interest.

References

- Alawi, F., Freedman, P.D. (2004) Sporadic sclerotic fibroma of the oral soft tissues. *Am J Dermatopathol.* 26: 182-187. <https://doi.org/10.1097/00000372-200406000-00002>.
- Campanacci, M. (2013) Bone and soft tissue tumors: clinical features, imaging, pathology and treatment. Springer Science and Business Media.
- Chen, T.C., Kuo, T., Chan, H.L. (2000) Dermatofibroma is a clonal proliferative disease. *J Cutan Pathol.* 27: 36-39. <https://doi.org/10.1034/j.1600-0560.2000.027001036.x>. PMID: 10660130
- Crisan, D., Solovastru, L.G., Crisan, M., Badea, R. (2014) Cutaneous histiocytoma-histological and imaging correlations. A case report. *Medical ultrasonography.* 16: 268-270. <http://dx.doi.org/10.11152/mu.2013.2066.163.dc1>. PMID: 25110771.
- Jang, J.S., Kim, J.H., Shin, T.K., Cho, G.J., Kwon, O.D. (2008) A case of cutaneous fibroma in a Korean indigenous cattle. *J Vet Clin.* 25: 200-201.
- Kiehl, A.R., Mays, M.B. (2016) Atlas for the Diagnosis of Tumors in the Dog and Cat. John Wiley and Sons. <http://dx.doi.org/10.1002/9781119050766>.
- McNiff, J.M. Subtil, A., Cowper, S.E., Lazova, R., Glusac, E.J. (2005) Cellular digital fibromas: distinctive CD34-positive lesions that may mimic dermatofibrosarcoma protuberans. *J Cutan*

- Pathol. 32: 413-418. <https://doi.org/10.1111/j.0303-6987.2005.00358.x>.
- Movassaghi, A.R., Mohammadi, G.H. (2009) An unusual cutaneous fibroma in a heifer. *Comp Clin Pathol.* 18: 207-208. <http://dx.doi.org/10.1007/s00580-008-0790-7>.
- Płaszczycza, A., Nilsson, J., Magnusson, L., Brosjö, O., Larsson, O., von Steyern, F.V. et al. (2014) Fusions involving protein kinase C and membrane-associated proteins in benign fibrous histiocytoma. *Int J Biochem Cell Biol.* 53: 475-481. <https://doi.org/10.1016/j.biocel.2014.03.027>. PMID: 24721208.
- Reich, D., Psomadakis, C.E., Buka, B. (2017) *Dermatofibroma*. Springer, Cham. https://doi.org/10.1007/978-3-319-18627-6_50.
- Schulman, F.Y., Krafft, A.E., Janczewski, T. (2001) Feline cutaneous fibropapillomas: clinicopathologic findings and association with papillomavirus infection. *Vet Pathol.* 38: 291-296. <https://doi.org/10.1354%2Fvp.38-3-291>. PMID: 11355659.
- Spugnini, E.P., Di Tosto, G., Salemme, S., Pecchia, L., Fanciulli, M., Baldi, A. (2013) Electrochemotherapy for the treatment of recurring aponeurotic fibromatosis in a dog. *Can Vet J.* 54: 606-609. PMID: 24155455.
- Sundberg, J.P., Williams, E.S., Hill, D., Lancaster, W.D., Nielsen, S.W. (1985) Detection of papillomaviruses in cutaneous fibromas of whitetailed and mule deer. *Am J Vet Res.* 46: 1145-1149. PMID:2408523.
- Tozon, N., Tratar, U.L., Znidar, K., Sersa, G., Teisie, J., Cemazar, M. (2016) Operating procedures of the electrochemotherapy for treatment of tumor in dogs and cats. *J Visual Exp.*116: 1-7. <https://dx.doi.org/10.3791%2F54760>. PMID: 27805594.
- Wang, J., Sarma, D. (2007) CD34-positive Fibroma of the Lip. *Int J Dermatol.* 6: 1-3. <https://doi.org/10.5580/19a5>.
- Won, K.Y., Park, S.Y., Jin, W., Lew, B.L. (2018) Dermatofibroma: sonographic findings and pathologic correlation. *Acta Radiologica.* 59: 454-459. <https://doi.org/10.1177%2F0284185117721263>. PMID: 28791883.
- Yeruham, I., Perl, S. (2001) Case report: fibroma in the end of the tail of a cow. *Berl Munch Tierarztl Wochenschr.* 114: 142-143. PMID: 11314587.

گزارش وقوع درماتوفیبروما در پلنگ ایرانی در پارک ملی گلستان ایران

سمیه نمرودی^۱، سید محمد حسینی^{۲*}، هادی علیجانی^۳، رضا امانی^۳، سیاوش روشنیان^۴^۱گروه محیط زیست، دانشکده شیلات و محیط زیست، دانشگاه علوم کشاورزی و منابع طبیعی گرگان، گرگان، ایران^۲گروه پاتوبیولوژی، واحد بابل، دانشگاه آزاد اسلامی، بابل، ایران^۳عضو باشگاه پژوهشگران جوان و نخبگان، واحد بابل، دانشگاه آزاد اسلامی، بابل، ایران^۴کارشناس اداره محیط زیست گلستان، گرگان، ایران

(دریافت مقاله: ۲۰ آذر ماه ۱۳۹۸، پذیرش نهایی: ۵ اسفند ماه ۱۳۹۸)

چکیده

درماتوفیبروما یک تومور پوستی خوش خیم رایج است که بر اساس تغییرات مورفولوژی و ترکیب عناصر متنوع آن به انواع مختلفی تقسیم می شود. علت درماتوفیبروما ناشناخته است که از لحاظ تاریخیچه یک پاسخ واکنشی نسبت به برخی ضایعات پوستی است که با خارش و درد همراه می باشد. این تومور معمولاً در قسمت انتهایی اندام ها در بالغین جوان ظاهر می شود. در مطالعه حاضر، به طور تصادفی یک پلنگ ایرانی میانسال به دلیل برخورد با ماشین در پارک ملی گلستان ایران کشته شد. بعد از کالبدگشایی، یک توده پوستی در پنجه راست مشاهده شده که پس از نمونه برداری به آزمایشگاه انتقال یافت. پس از انجام فرآیندهای معمول هیستوپاتولوژیک و ایمونوهیستوشیمی، درماتوفیبروما بدون کپسول، محدود و همراه با ندول پوستی هایپوسلولار با الگوی مارپیچی تشخیص داده شد. همچنین براساس نتایج رنگ آمیزی ایمونوهیستوشیمی نشانگر CD۳۴ مثبت بود. اطلاعات محدودی در مورد درماتوفیبروما در پلنگ وجود دارد. بر اساس اطلاعات ما، این اولین گزارش از درماتوفیبروما در پلنگ ایرانی است.

واژه‌های کلیدی:

درماتوفیبروما، پلنگ، ایمونوهیستوشیمی، هیستوپاتولوژی، گلستان.