

Original Article

**Macrostructure of the Cranial Cervical Ganglion in the River Buffalo
(*Bubalus Bubalis*)**

Gholamreza Najafi^{1*}
Farhad Soltanolinejad¹
Hossein Dehghani²

¹*Department of Basic Sciences, Faculty of Veterinary Medicine,
Urmia University, Urmia, Iran*

²*Graduated from Faculty of Veterinary, Urmia University, Urmia, Iran*

Received: 21 October 2010, Accepted: 22 February 2011

Abstract

The autonomic nervous system consists of a vast range of nerves and ganglions. Anatomical studies have demonstrated that the sympathetic innervations of the head and neck are affected by the neurons that ramify from the cranial cervical ganglion (CCG). The CCG is the end of the sympathetic cervical trunk, which runs with the vagal nerve during its cervical course. In this study sixteen adult (2 - 5 year) river buffalo of both sexes (eight male, eight female) weighing around 250 - 450 kg were dissected to investigate the weight, situation and arrangement of nerve branches of the cranial cervical ganglion bilaterally. The ganglions showed a fusiform shape and reddish in color. The cranial cervical ganglion covered by the digastricus muscle. It lies in dorsal region of the base of epiglottic cartilage, ventromedial to tympanic bulla and ventrally to atlantic fossa, and medial of the occipital artery. This study showed that the cranial cervical ganglions in river buffalo were well-developed structure. The main branches of cranial cervical ganglion included the internal carotid, external carotid and jugular nerves.

Key words: Cranial cervical ganglion, Autonomic nervous system, Internal carotid nerve, River buffalo.

***Corresponding author:**

Golamreza Najafi, DVM, DVSc

Department of Basic Sciences, Faculty of Veterinary Medicine, Urmia University, Urmia, Iran.

E-mail address: g.najafi@mail.urmia.ac.ir

Introduction

In the mammals, the autonomic nervous system consists of a vast range of nerves and ganglions. Many ganglions can be easily observed as protrusions or thickness of nervous chain or arrange of various nerves. Cranial cervical ganglion provides sympathetic input to the head and neck. Postganglionic sympathetic fibers of the cranial cervical ganglion innervate smooth muscles and glands in the head region. The postganglionic fibers from the cranial cervical nerves are extended to the adventitia of all cranial arteries. The cranial cervical ganglion is a well-vascularized structure and consists of large cell bodies with prominent fine Nissl bodies, which surrounded by abundant small glial cells, which called satellite cells.^{2,3} The Cranial cervical ganglion is a fusiform grayish-pink ganglion and is about 2 to 3 cm in length and 3 mm to 1 cm in diameter in horse. In horse the cranial cervical ganglion is located at the cranial extremity of each cervical sympathetic trunk, and lies closely opposite the internal carotid artery. Each ganglion is related to caudal face of the guttural pouch, ventrally located to atlantoccipital articulation.⁴ Cranial cervical ganglion in dog lies deeply in the tympanic bulla and in proximal portion of cranial nerves IX, X, XI and XII. In the ruminants, the fusiform cranial cervical ganglion is located medial in the jugular process of the occipital bone, ventromedial to the tympanic bulla.³ A large portion of the postganglionic fibers leaving the ganglion continue as plexuses along the arteries of the head region. For example, quite prominent bundles of fibers can be observed going to both external and internal carotid arteries.⁵

Nerves from each ganglion include internal carotid, external carotid, jugular nerves, branches to the thyroid gland, guttural branches joining the vagus, glossopharyngeal, hypoglossal and first cervical nerves and their accessories. In

domestic ruminants no branches of the cranial cervical ganglion have been followed to the heart.³

The purpose of the present study was to describe the location, arrangement and distribution of postganglionic nerves of the cranial cervical ganglion and to provide morphological basis for further research in comparative neuroanatomy.

Materials and Methods

The study was performed on sixteen adult (2-5 years old) River buffalo of both sexes (eight male and eight female) weighing 250–450kg. The common carotid, external carotid and occipital arteries were revealed by simple dissection method. Afterwards, cranial cervical ganglions were approached. Dissection was performed on the anatomical structures of the related area and the cranial cervical ganglion and related fibers were exposed. In sixteen buffalo the average weight, length and width of the cranial cervical ganglions were measured by digital calipers and photographs were taken using a SONY DSC-H50 camera.

Statistical analyses were performed on all data using the *t*-test to compare quantitative parameters referring to paired organs.

Results

Because the cranial cervical ganglion covered by caudal belly of the digastric muscle, for more clear observation of the ganglia, the muscle was removed. It was located cranio-ventrally of the atlantal fossa, medial of the jugular process, base of epiglottic cartilage, and medial to the occipital artery. Finally, the cranial cervical ganglion was found caudal to the internal and external carotid arteries. Cranial cervical ganglion was situated superficial to the rectus capitis ventralis major muscle and deep to proximal part of the XI and XII cranial nerves. There were no obvious differences in the topography

of ganglions between left and right sides (Fig 1 and 2).

The ganglia presented as a well-developed structure was fusiform shape and reddish in color (Fig 1). The average weight (0.230 ± 0.022 gm) , length (12.42 ± 0.610 mm) , width (3.645 ± 0.049 mm) and thickness (3.110 ± 0.032 mm)of the ganglion in male buffalo was respectively. In female buffalo average weight, length, width and thickness of the cranial cervical ganglion was 0.261 ± 0.033 gm, 10.89 ± 0.553 mm, 3.97 ± 0.050 mm and 4.001 ± 0.040 mm, respectively (Table 1).

Nerves from each cranial cervical ganglion include internal carotid nerve, external carotid nerve and jugular nerve (Fig 3). The first larger branch of the cranial cervical ganglion was the external carotid nerve as a single branch arising from the caudomedial border of the cranial cervical ganglion. The external carotid nerve originating from the external carotid plexus followed the smaller arteries arising from the external carotid artery and formed some smaller plexuses along those arteries. A fine branch from external carotid nerve supplied carotid body (Fig 4).

The internal carotid nerve was the direct prolongation of the ganglion, in caudolateral pole of ganglion and ascended beside the internal carotid artery and entered the cranial cavity. It lets out several bundles to form the internal carotid plexus. Third branch of the cranial cervical ganglion was jugular nerve originating from the caudal pole of the ganglion, mounted under the vagal and glossopharyngeal nerves (Fig 4).

This nerve splits into several branches near the jugular foramen. From the lateral outline of caudal part of the ganglion, branches reached to the common carotid artery.

Discussion

In the domestic animals, the cervical and thoracic autonomic innervation is derived

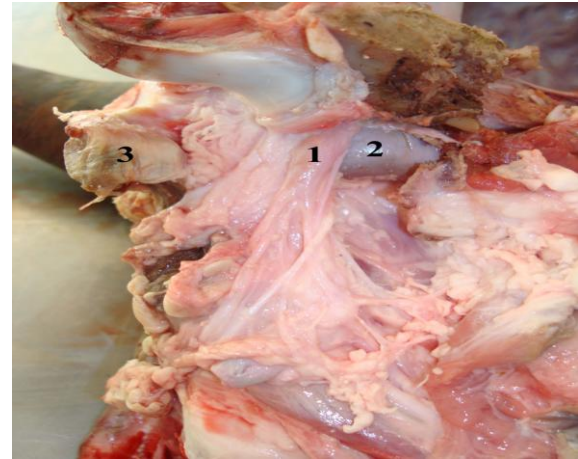


Fig 1. Ventral condyloid and atlantal fossa after removing regional muscles 1.Cranial cervical ganglion 2. Retroarticular process 3. Digastric muscle

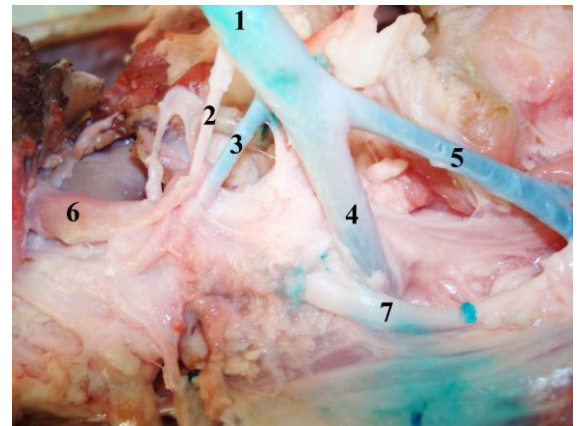


Fig 2. Ventral condyloid and atlantal fossa after removing regional muscles 1. Common carotid artery 2.Obliterated internal carotid artery 3. Occipital artery 4. External carotid artery 5. Lingo facial artery 6. Cranial cervical ganglion 7. Glossopharyngeal nerves

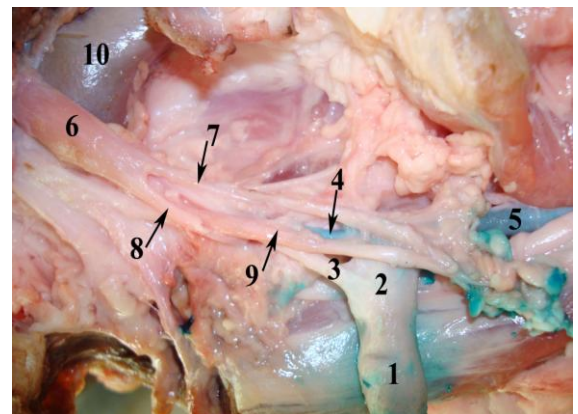


Fig 3. Ventral condyloid and atlantal fossa after removing regional muscles 1.Common carotid artery 2. Carotid sinus 3. Internal carotid artery 4. External carotid artery 5. Lingo facial artery 6. Cranial cervical ganglion 7. External carotid branch nerve 8. Jugular branch nerve 9. Glossopharyngeal nerves 10. Retroarticular process

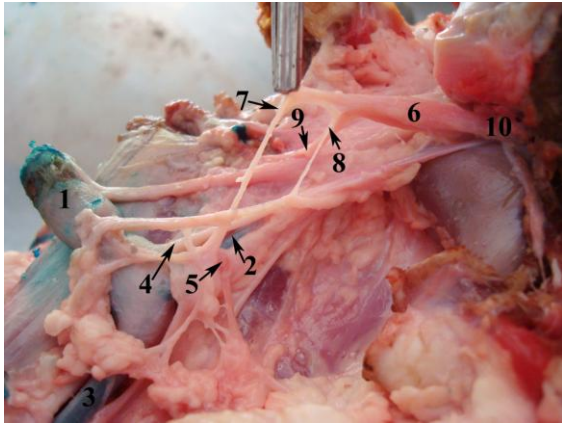


Fig 4. Ventral condyloid and atlantal fossa after removing regional muscles 1.common carotid artery 2. External carotid artery 3. lingofacial artery 4. Internal carotid artery 5. Carotid body 6. Cranial cervical ganglion 7. External carotid branch nerve 8. Communicating branch from external carotid branch nerve 9. Jugular branch nerve 10. Internal carotid branch nerve

from cervical and thoracic sympathetic chain ganglia and from parasympathetic vagus nerve branches. The cervical sympathetic trunks of ruminants extend from the cervicothoracic ganglion to the cranial cervical ganglion via the ansa subclavia and vago-sympathetic trunk. Grossly visible ganglia in ox include the vertebral and cranial cervical ganglion. The shape of the cranial cervical ganglion was fusiform and its color is reddish similar to the other ruminants.^{3,6}

The cranial cervical ganglion was located at the cranial region of the neck and covered by the digastricus muscle. The topography of the ganglion generally resembles to those of in other ruminants.^{3,6} The main fibers of the ganglia included the internal carotid, external carotid and jugular nerves as the results showed by Getty and Howard.^{3,7} Howard et al., 1979 showed that, internal carotid nerve ramified to several branches from cranial

part of the cranial cervical ganglion in horse, dog and young sheep. These branches form the internal carotid plexus, circumscribing the internal carotid artery and run along with this artery towards the cranial cervical ganglion. Internal carotid nerve had several branches in all sheep. A nerve branch ramifies from cranial cervical ganglion to the cervical nerves in dog horse, pig, Guinea-pig and camel.^{3,7-10} In dog, this branch sends branches to the first, second and third cervical nerves.⁷

There is sometimes an additional branch in horse and dog, originating directly from the cranial cervical ganglion, extending to the second cervical nerve.³. In present study, two-three branches of internal carotid nerve were originated from the central part of the ganglion and reached to cervical nerves.

The jugular branch documented in the literature was said to be either a single branch or two separate branches.⁶ In this study, the jugular nerve was a single branch originating from the caudal pole of the ganglion and passing upward under the vagus and glossopharyngeal nerves.

The external carotid nerve is another major nerve trunk originating from cranial cervical ganglion. In this study, it was a single branch that originating from the cranial cervical ganglion and follows smaller arteries.

Acknowledgement

We thank the Faculty of Veterinary Medicine, Urmia University for providing the research materials for this study.

Table 1. Measurements (weight, length, width and thickness) of the cranial cervical ganglion (CCG) of the male and female River Buffalo

	Weight (gm)	Length(mm)	Width(mm)	Thickness (mm)
male	0.230 ± 0.022	12.42 ± 0.610	3.645 ± 0.049	3.110 ± 0.032
female	0.261 ± 0.033	10.89 ± 0.553	3.97 ± 0.050	4.001 ± 0.040

There was no significant difference between male and female group ($P < 0.05$)

References

1. König H.E, Liebich, H.G. Veterinary Anatomy of Domestic Mammals 2nd Edn, Schattner, 2004; 530-533.
2. Junquera L.C, Carnerio J. Basic Histology, 11th Edn, MCGraw-Hill, 2005; 174-179.
3. Getty R. Sisson and Grossman's the anatomy of the domestic animals 5th Edn W.B. Saunders Company, 1975; 1: 1151-1155.
4. Özgel O, Kurtul I, et al. On the Gross anatomy of the cranial cervical ganglion of the donkey (*Equus asinus*) in Turkey, 2004; 284: 261-266.
5. Evans H.E, Christensen G.C. Anatomy of the dog 2nd Edn W.B. Saunders Company 1979; 1044-1045.
6. Dyce K.M, Sack W.O, et al. Textbook of veterinary anatomy 2nd Edn . W.B. Saunders Company, 1996; 314-326.
7. Howard E, George. Anatomy of the Dog. 2nd Edn, W.B.Saunders Company, 1979; 1044-1045
8. Kabak M, Gultiken M.E. Arterial supply of the superior cervical ganglion in the Guinea-pig (*Cavia porcellus*): Anat Histol Embryol, 2006; 356: 393-398.
9. Kabak M, Orhan I.O, et al. Macro-anatomical investigations of the cranial cervical ganglion in domestic pig (*Sus scrofa domestica*): Anat Histo Embryo, 2005; 34: 199-202.
10. Sheng C, Jian-Ling W, et al. The gross anatomy of the cranial cervical ganglion and its branches in the bactrian camel (*Camelus bactrianus*): Vet. Res. Comm, 1998; 221:1-5.